

PEDIATRICS

OFFICIAL JOURNAL OF THE AMERICAN ACADEMY OF PEDIATRICS

Remestemcel-L Therapy for COVID-19-Associated Multisystem Inflammatory Syndrome in Children

Allison Ross Eckard, Kenneth M. Borow, Elizabeth H. Mack, Elizabeth Burke, Andrew M. Atz

DOI: 10.1542/peds.2020-046573

Journal: *Pediatrics*

Article Type: Case Report

Citation: Ross Eckard A, Borow KM, Mack EH, Burke E, Atz AM. Remestemcel-L therapy for COVID-19-associated multisystem inflammatory syndrome in children. *Pediatrics*. 2021; doi: 10.1542/peds.2020-046573

This is a prepublication version of an article that has undergone peer review and been accepted for publication but is not the final version of record. This paper may be cited using the DOI and date of access. This paper may contain information that has errors in facts, figures, and statements, and will be corrected in the final published version. The journal is providing an early version of this article to expedite access to this information. The American Academy of Pediatrics, the editors, and authors are not responsible for inaccurate information and data described in this version.

Remestemcel-L Therapy for COVID-19-Associated Multisystem Inflammatory Syndrome in Children

Allison Ross Eckard,¹ Kenneth M. Borow,² Elizabeth H. Mack,¹
Elizabeth Burke,³ Andrew M. Atz¹

¹Medical University of South Carolina, Department of Pediatrics, Charleston, SC, USA; ²Borow Consulting Group, Bryn Mawr, PA, USA; ³Mesoblast, Inc., New York, NY, USA

Correspondence and reprints: Allison Ross Eckard, MD, Department of Pediatrics and Medicine, Divisions of Infectious Diseases, Medical University of South Carolina, 135 Rutledge Ave, Suite 1217, Charleston, SC 29425; Phone: 843-792-9909; Fax: 843-792-5127; E-mail: eckarda@musc.edu

Conflicts of Interest Disclosures: KMB is a consultant to Mesoblast, Inc. EB is an employee of Mesoblast, Inc. All other declare no conflicts of interest.

Funding Sources: Mesoblast, Inc. provided remestemcel-L at no cost to the patients.

Role of Funder: Mesoblast designed the study and approved the final manuscript. They had no role in data collection, data management, or initial manuscript preparation. They provided the investigational drug to study participants at no charge, but they provided no other financial support for study conduction or manuscript preparation.

Abbreviations:

MIS-C—Multisystem inflammatory syndrome in children

KD—Kawasaki disease

LV—left ventricular

IVIg—intravenous immunoglobulin

MSCs—mesenchymal stromal cells

MUSC—Medical University of South Carolina

Table of Contents Summary: We present the first two patients with COVID-19-associated multisystem inflammatory syndrome in children ever treated with remestemcel-L, a promising investigational mesenchymal stromal cell therapy.

Contributors' Statements

Dr. Eckard supervised and participated in the acquisition of data, analyzed and interpreted data, drafted the initial manuscript, and revised the manuscript for important intellectual content.

Drs. Atz and Mack participated in the acquisition of data, analyzed and interpreted data, and critically reviewed and revised the manuscript for important intellectual content.

Dr. Borow and Ms. Burke conceptualized and designed the study, designed the data collection instruments, analyzed and interpreted data, and critically reviewed and revised the manuscript for important intellectual content.

All authors approved the final manuscript as submitted and agree to be accountable for all aspects of the work.

Abstract

Multisystem inflammatory syndrome in children (MIS-C) is a serious post-infectious immune dysregulation associated with COVID-19 that may present with severe and life-threatening cardiovascular dysfunction, hemodynamic instability, shock, and multisystem organ failure. Optimal treatment is unknown. Current standard of care consists of nonspecific anti-inflammatory and anti-thrombotic therapies. Interventions that target MIS-C's distinctive clinical features and immunophenotype are indicated. Remestemcel-L, an investigational mesenchymal stromal cell therapy, is a promising candidate for treatment of MIS-C due to its beneficial anti-inflammatory, immunomodulatory, endothelial function, and vascular stabilizing effects which align well with the pathophysiology of MIS-C. Here, we present the first two patients with life-threatening MIS-C ever treated with remestemcel-L under an expanded access program. Both were previously healthy children without any indication of prior COVID-19 infection or exposure. They presented with severe clinical illness including myocardial dysfunction, hemodynamic instability, hypotension, acute kidney injury, and shock. At the time of hospital admission, both had negative PCR tests and positive serology for SARS-CoV-2. Both children received standard of care MIS-C treatment. Although they showed some clinical improvement, left ventricular ejection fraction remained reduced and inflammatory biomarkers significantly elevated. When treated with two intravenous doses of remestemcel-L separated by 48 hours, rapid normalization of left ventricular ejection fraction, notable reductions in biomarkers of systemic and cardiac inflammation, and improved clinical status occurred. Neither child experienced adverse effects associated with remestemcel-L administration. This treatment appears promising as a novel immunomodulatory cellular therapy for children with clinically-significant cardiovascular manifestations of MIS-C.

The global COVID-19 pandemic, caused by the novel coronavirus, SARS-CoV-2, has caused devastating worldwide morbidity and mortality.^{1,2} Many adults, particularly those with underlying conditions and/or advanced age, are at high risk of life-threatening disease. In contrast, children rarely develop severe illness or die from COVID-19 disease.³ One exception is multisystem inflammatory syndrome in children (MIS-C), a rare but serious complication of SARS-CoV-2. Many children with MIS-C develop severe or life-threatening illness, often characterized by overwhelming systemic inflammation, coagulopathy, myocardial dysfunction, shock, and multisystem organ failure.⁴⁻⁷

Clinical Features and Pathophysiology of MIS-C

Pathophysiology of MIS-C is thought to be a post-infectious immune dysregulation caused by SARS-CoV-2. Every organ system in the body can be affected. Common clinical presentations include persistent fever, rash, conjunctivitis, myalgias, gastrointestinal manifestations, and neurocognitive symptoms.^{4,7} Clinical findings may include shock, myocardial dysfunction, arrhythmias, acute respiratory failure, and acute kidney injury. Laboratory abnormalities often show lymphocytopenia, neutrophilia, elevated inflammatory markers (e.g., C-reactive protein, D-dimer), and elevated cardiac markers (e.g., troponin, B-type natriuretic protein).

While the syndrome shares characteristics with Kawasaki disease (KD) and macrophage activation syndrome, MIS-C has a unique immunophenotype and is considered a discrete disease.⁸ One important distinction is the high frequency of cardiovascular involvement, especially myocardial and endothelial dysfunction (e.g., decreased left ventricular (LV) function, hypotension, and activation of coagulation cascades).^{6, 7, 9} The high frequency of distinctive and often severe cardiovascular manifestations in MIS-C raises the need for more targeted treatments beyond the traditional therapies used in KD (e.g., intravenous immunoglobulin (IVIG), aspirin, steroids).¹⁰

Rationale for Administration of Remestemcel-L in MIS-C

Remestemcel-L is an investigational therapy comprised of culture-expanded allogeneic mesenchymal stromal cells (MSCs) derived from bone marrow of unrelated adult donors. These cells, part of the mesenchymal lineage cell line, have important properties that align well with the pathophysiology of MIS-C, including beneficial anti-inflammatory, immunomodulatory, endothelial function, and vascular stabilizing effects. The biological basis for mesenchymal

lineage cells' salutary effects involves the secretion of multiple paracrine factors, such as anti-inflammatory cytokines that reduce inflammation, growth factors that can enhance tissue repair, and angiogenic growth factors that improve endothelial function in both coronary and peripheral arteries.¹¹⁻²⁰

The pattern of anti-inflammatory mediators released by MSCs is in specific response to the inflammatory environment encountered and is likely mediated through differential activation of damage- and pathogen-associated molecular pathogen receptors expressed on their cell surfaces, including toll-like receptors.^{21,22} Thus, MSCs have more precise immunomodulatory targets than non-specific therapies like IVIG and steroids. Yet, unlike single pathway-targeted therapies such as interleukin-1 or interleukin-6 inhibitors, MSCs have a wider set of beneficial effects that align well with the pathologic derangements associated with MIS-C.

MSCs have been evaluated for treatment in a variety of immune-mediated and inflammatory conditions. To date, approximately 1100 people, including 311 children, have received investigational remestemcel-L. Collectively, the data suggest that remestemcel-L has a favorable efficacy and safety profile, including among children with steroid-resistant acute graft-versus-host disease.^{23,24} Thus, based on MSC's anti-inflammatory, immunomodulatory, and beneficial effects on endothelial function, as well as remestemcel-L's safety data in children, this therapy holds promise as an effective and novel treatment for MIS-C.

Clinical Summary

Here, we present the first two patients with MIS-C ever treated with remestemcel-L under an intermediate-size expanded access program (NCT04456439). Legal guardians provided written permission to share their children's health information.

Both patients (patient #1: 4-year-old non-Hispanic, Black male; patient #2: 10-year-old non-Hispanic, Black female) presented to the Medical University of South Carolina (MUSC), Charleston, SC during August-September 2020 and met the Centers for Disease Control and Prevention's definition of MIS-C.⁴ Detailed clinical data are depicted in Table 1. They had strikingly similar presentations: both were previously healthy children who experienced a preceding illness of ~5 days duration consisting of high fever (39.0-40.6°C), gastrointestinal symptoms, and generalized malaise. Patient #1 presented to an outside hospital emergency department three times during the first four days of illness and was sent home with a “viral syndrome” diagnosis each time. Patient #2 was admitted to an outside hospital pediatric intensive care unit for 3 days with acute renal insufficiency before transfer.

When both children presented to our institution, they had severe clinical illness including hemodynamic instability, hypotension, acute kidney injury, and shock requiring vasopressors. Both children had significant myocardial dysfunction characterized primarily by decreased biventricular function (requiring inotropes in patient #2). Cardiac injury/congestion and systemic inflammation/coagulation biomarkers were markedly elevated. Patient #2 also had mental status changes and significant respiratory distress (secondary to poor cardiac function and fluid overload) which necessitated intubation. Despite the fact that neither child had a known exposure to someone with COVID-19 nor reported any symptoms suggestive of COVID-19 in the preceding four weeks, both had positive IgG antibodies against SARS-CoV-2 nucleocapsid and spike proteins with a negative SARS-CoV-2 PCR. Multiplex respiratory viral PCR panels and blood and urine cultures were also negative.

During the initial days of hospitalization at our institution, both children received current standard of care MIS-C treatment including IVIG, steroids, aspirin, and anti-coagulants. While

they showed some improvement in overall clinical status, many important clinical and laboratory parameters remained markedly abnormal, especially direct and indirect measures of cardiac dysfunction/injury (e.g., decreased LV function/need for inotropes; elevated levels of BNP and troponin-I), systemic/cardiac/endothelial inflammation (e.g., elevated levels of C-reactive protein, procalcitonin, ferritin, and total white blood cell count), and endothelial dysfunction (e.g., hypotension/need for vasopressors; elevated levels of D-dimer and fibrinogen). Thus, they were considered for remestemcel-L treatment under the expanded access program and met inclusion/exclusion criteria.

Legal guardians provided written informed consent for study participation. Both children received two intravenous infusions of remestemcel-L separated by 48 hours (patient #1: MUSC hospital days 5 and 7; patient #2: MUSC hospital days 3 and 5). Each infusion contained 2 million cells/kg body weight administered over 60 minutes. Logistical issues related to cell preparation and administration necessitated patient 1's second dose be given 24 hours earlier than outlined in the study, representing a minor protocol deviation approved by the sponsor. For consistency between cases, the same time interval was utilized for patient #2. Neither child experienced any adverse effects associated with remestemcel-L administration.

Both children showed rapid normalization of their LV ejection fraction and B-type natriuretic protein as well as improvement in D-dimer that were temporally-associated with remestemcel-L treatment (Figure 1). In addition, serial echocardiographic imaging showed reduction in the severity of pan-valvular regurgitation as well as increases in LV end systolic volume. The latter observation is consistent with improvement in LV contractile state that was temporally-associated with the cell therapy administration. Of note, neither child exhibited coronary artery dilation nor a hemodynamically-significant pericardial effusion at any point.

Both children developed rebound hypertension after resolution of their hypotension, potentially reflecting the interaction between restored cardiac output and continued systemic endothelial dysfunction. Patient #2 required prolonged pharmacological treatment for her hypertension. Patient #1 had an accompanying bradycardia which resolved shortly after his first dose of remestemcel-L. He also developed symptomatic anemia on hospital days 7-8 which was treated with packed red blood cells. This complication was determined to be secondary to a low baseline hemoglobin related to his underlying condition combined with frequent blood draws required for laboratory monitoring and unrelated to remestemcel-L.

The children continued to show clinical and laboratory improvements and were well-appearing by day of discharge (MUSC hospital day 9 and 10, respectively). Both children continue to be followed as outpatients and are doing well (to date, both are ≥ 90 days out from first remestemcel-L dose). Importantly, both children tolerated remestemcel-L well with no adverse effects, consistent with remestemcel-L's previously-reported favorable safety profile in children.²⁴

Discussion

Although both children were showing some level of clinical improvement when they received the experimental product, the data suggest that remestemcel-L contributed to further improvements in myocardial and endothelial function and promoted additional reductions in systemic and cardiac inflammation. Within one day of his first remestemcel-L treatment, patient #1's D-dimer levels decreased from levels that were above the measurable range to values that were rapidly approaching normal. The most likely mechanisms of action that facilitated these improvements include multi-targeted, beneficial anti-inflammatory effects that promote endothelial function and protect cardiomyocytes from apoptosis and fibrosis.

The mesenchymal lineage cells in remestemcel-L are part of the body's armamentarium for repairing damaged tissue and restoring normal function. When administered intravenously as described here, MSCs traffic to various organs and lymphoid tissue involved in the inflammatory process and downregulate production of pro-inflammatory cytokines, promote production of anti-inflammatory cytokines, and enable recruitment of naturally-occurring anti-inflammatory cells to affected tissues. Mesenchymal stromal cells produce sustained anti-inflammatory effects, including conversion of Th17 cells to anti-inflammatory FOXP3 T-regulatory cells and conversion of inflammatory M1 macrophages to anti-inflammatory M2 macrophages.^{19,21,22} In addition, they have shown beneficial effects on endothelial dysfunction in pre-clinical and clinical studies.^{18,20} Based on these properties and our successful treatment in two children, remestemcel-L may be a promising and effective treatment for MIS-C, especially in children with significant cardiovascular involvement.

Our two cases highlight several critical themes regarding MIS-C. First, it can develop quickly as a life-threatening illness with cardiovascular collapse in previously healthy children. Second, as shown in our patients who had multiple encounters with various healthcare providers prior to their admission to MUSC, the diagnosis of MIS-C is challenging and can be overlooked. This may be particularly true when traditional KD features like rash, conjunctivitis, and mucous membrane involvement are absent like in our two cases. Nevertheless, it is important to consider MIS-C in the differential diagnosis for any child who presents with an acute viral-like syndrome, especially in a child with a fever and elevated inflammatory markers. Prompt recognition and initiation of MIS-C treatment is crucial. Third, long-term effects of MIS-C are largely unknown; however, permanent sequelae are likely in some children. In our cases, patient #2 still required anti-hypertensives and patient #1's LV ejection fraction declined to the low normal range weeks

after hospital discharge. Although speculative, our two patients may have fared far worse without remestemcel-L treatment.

Interestingly, the remestemcel-L doses were given 48 hours apart in these two cases, representing a slightly shorter time interval than what has been previously utilized for steroid-resistant graft-versus-host disease. Although this alternative dosing schedule was unplanned, the concept of a “rapid sequence” of doses may actually be beneficial in MIS-C given its very rapid disease progression and hyperacute inflammatory state. The shorter interval between doses appeared safe and efficacious in our two children and should be considered in the design of future trials for MIS-C and other acute inflammatory conditions.

Multisystem inflammatory syndrome in children has emerged as another consequence of the devastating COVID-19 pandemic. There are currently no standardized or approved treatments for MIS-C. And, yet, with the continuing surge of COVID-19 cases worldwide, cases of MIS-C will likewise climb. Remestemcel-L exhibits beneficial effects relative to the cardiac and vascular pathophysiology associated with MIS-C and an excellent safety profile in children. This therapy holds promise as a novel treatment for MIS-C.

Acknowledgments

We thank Dr. Michelle Hudspeth and our investigational drug services for sharing their experience and expertise in using remestemcel-L in children with graft versus host disease. We thank the families of these children for their willingness to participate in the study and to share their stories about MIS-C and remestemcel-L.

References

1. Huang C, Wang Y, Li X, et al. Clinical features of patients infected with 2019 novel coronavirus in Wuhan, China. *Lancet*. 2020;395(10223):497-506.
2. Ssentongo P, Ssentongo AE, Heilbrunn ES, Ba DM, Chinchilli VM. Association of cardiovascular disease and 10 other pre-existing comorbidities with COVID-19 mortality: a systematic review and meta-analysis. *PLoS One*. 2020;15(8):e0238215.
3. Jiehao C, Jin X, Daojiong L, et al. A case series of children with 2019 novel coronavirus infection: clinical and epidemiological features. *Clin Infect Dis*. 2020;71(6):1547-1551.
4. CDC COVID-19 Response Team. Coronavirus disease 2019 in children - United States, February 12-April 2, 2020. *MMWR Morb Mortal Wkly Rep*. 2020;69(14):422-426.
5. DeBiasi RL, Song X, Delaney M, et al. Severe coronavirus disease-2019 in children and young adults in the Washington, DC, metropolitan region. *J Pediatr*. 2020;223:199-203.
6. Belhadjer Z, Meot M, Bajolle F, et al. Acute heart failure in multisystem inflammatory syndrome in children (MIS-C) in the context of global SARS-CoV-2 pandemic. *Circulation*. 2020;142(5):429-436.
7. Shekerdemian LS, Mahmood NR, Wolfe KK, et al. Characteristics and outcomes of children with coronavirus disease 2019 (COVID-19) infection admitted to US and Canadian pediatric intensive care units. *JAMA Pediatr*. 2020;174(9):868-873.
8. Consiglio CR, Cotugno N, Sardh F, et al. The immunology of multisystem inflammatory syndrome in children with COVID-19. *Cell*. 2020;183(4):968-981.
9. Feldstein LR, Rose EB, Randolph AG. Multisystem inflammatory syndrome in children in the United States. Reply. *N Engl J Med*. 2020;383(18):1794-1795.
10. Newburger JW, Takahashi M, Burns JC. Kawasaki disease. *J Am Coll Cardiol*. 2016;67(14):1738-49.
11. Aggarwal S, Pittenger MF. Human mesenchymal stem cells modulate allogeneic immune cell responses. *Blood*. 2005;105(4):1815-22.
12. Amarnath S, Foley JE, Farthing DE, et al. Bone marrow-derived mesenchymal stromal cells harness purinergic signaling to tolerize human Th1 cells in vivo. *Stem Cells*. 2015;33(4):1200-12.
13. Auletta JJ, Eid SK, Wuttisarnwattana P, et al. Human mesenchymal stromal cells attenuate graft-versus-host disease and maintain graft-versus-leukemia activity following experimental allogeneic bone marrow transplantation. *Stem Cells*. 2015;33(2):601-14.
14. Bartholomew A, Sturgeon C, Siatskas M, et al. Mesenchymal stem cells suppress lymphocyte proliferation in vitro and prolong skin graft survival in vivo. *Exp Hematol*. 2002;30(1):42-8.
15. Klyushnenkova E, Mosca JD, Zernetkina V, et al. T cell responses to allogeneic human mesenchymal stem cells: immunogenicity, tolerance, and suppression. *J Biomed Sci*. 2005;12(1):47-57.
16. Robles JD, Liu YP, Cao J, et al. Immunosuppressive mechanisms of human bone marrow derived mesenchymal stromal cells in BALB/c host graft versus host disease murine models. *Exp Hematol Oncol*. 2015;4:13.
17. Tobin LM, Healy ME, English K, Mahon BP. Human mesenchymal stem cells suppress donor CD4(+) t cell proliferation and reduce pathology in a humanized mouse model of acute graft-versus-host disease. *Clin Exp Immunol*. 2013;172(2):333-48.

18. Borow KM, Yaroshinsky A, Greenberg B, Perin EC. Phase 3 DREAM-HF trial of mesenchymal precursor cells in chronic heart failure. *Circ Res*. 2019;125(3):265-281.
19. Le Blanc K, Ringden O. Immunomodulation by mesenchymal stem cells and clinical experience. *J Intern Med*. 2007;262(5):509-25.
20. Dooley LM, Abdalmula A, Washington EA, et al. Effect of mesenchymal precursor cells on the systemic inflammatory response and endothelial dysfunction in an ovine model of collagen-induced arthritis. *PLoS One*. 2015;10(5):e0124144.
21. Hinden L, Shainer R, Almogi-Hazan O, Or R. Ex vivo induced regulatory human/murine mesenchymal stem cells as immune modulators. *Stem Cells*. 2015;33(7):2256-67.
22. Liotta F, Angeli R, Cosmi L, et al. Toll-like receptors 3 and 4 are expressed by human bone marrow-derived mesenchymal stem cells and can inhibit their t-cell modulatory activity by impairing notch signaling. *Stem Cells*. 2008;26(1):279-89.
23. Kurtzberg J, Prockop S, Chaudhury S, et al. Study 275: Updated expanded access program for remestemcel-l in steroid-refractory acute graft-versus-host disease in children. *Biol Blood Marrow Transplant*. 2020;26(5):855-864.
24. Kurtzberg J, Abdel-Azim H, Carpenter P, et al. A phase 3, single-arm, prospective study of remestemcel-l, ex vivo culture-expanded adult human mesenchymal stromal cells for the treatment of pediatric patients who failed to respond to steroid treatment for acute graft-versus-host disease. *Biol Blood Marrow Transplant*. 2020;26(5):845-854.

Table 1. Detailed Clinical Course

A. Patient #1

	hospital admission										hospital discharge										outpatient										
	↓										↓										↓										
Days since symptom onset	6	7	8	9	10	11	12	13	14											32-40											
Hospital admission day	1	2	3	4	5	6	7	8	9											--											
MSC treatment day	-4	-3	-2	-1	0*	+1	+2**	+3	+4											+22-33†											
Standard of care MIS-C treatment	IVIG		IVIG																												
	methylprednisolone						prednisolone														prednisolone										
	LMWH																														
	high-dose ASA																				low-dose ASA										
Key blood laboratory findings‡																															
Total WBC, 10 ³ /mm ³	32.9	42.6	38.7	22.2	18.8	21.0	23.5	18.5	26.8											17.2											
Neutrophils, 10 ³ /mm ³	29.6	40.1	35.6	16.2	14.8	11.8	12.0	12.6	19.8											15.0											

Lymphocytes, 10³/mm³	1.65	0.85	2.49	3.77	1.13	5.88	8.45	4.44	2.95		3.63
Platelets, 10³/mm³	102	108	112	79	152	163	201	227	274		116
Hemoglobin, g/dl	12.1	8.1	7.6	9.0	9.6	9.5	7.9	5.2	8.7		10.6
C-reactive protein, mg/liter	571	415	--	147	87	62	37	31	14		<0.2
ESR, mm/hr	>100	81	--	--	32	--	--	26	--		6
Procalcitonin, ng/ml	>100	--	--	--	14.8	--	--	2.0	--		--
D-dimer, µg/ml	12.2	16.7	15.9	>20	>20	>20	17.0	8.5	2.6		<0.43
Fibrinogen, mg/dl	831	807	588	302	230	167	149	144	154		189
Ferritin, ng/ml	417	369	333	244	274	262	202	299	258		16.3
LDH, U/liter	1230	408	--	--	395	--	--	243	--		--
Troponin-I, ng/ml	0.02	0.01	0.02	0.01	--	--	--	--	--		--
BNP, pg/ml	1057	1339	3691	4465	785	153	240	47.4	--		<10.0
Creatinine, mg/dl	4.5	1.4	0.5	0.5	0.4	0.4	0.3	0.3	0.3		0.3
Urea nitrogen, mg/dl	83	54	22	30	31	28	19	24	16		11
AST, U/liter	169	177	57	38	29	25	28	29	--		22

ALT, U/liter	66	77	45	36	29	25	25	24	--		27
Key echocardiogram findings											
LV ejection fraction, %	--	57.6	42.3	51.2	--	64.1	--	67.8	--		59.2
LV end systolic volume, ml	--	19.6	37.7	37.0	--	20.3	--	19.6	--		23.2
LV end diastolic volume, ml	--	46.4	65.3	75.9	--	56.5	--	60.9	--		56.8
Main clinical findings	hypotension, tachycardia; epi/norepi- nephrine		intermittent bradycardia, hypertension			anemia; PRBCs			clin- ically well		clinically well
	tachypnea (remained in room air; SpO ₂ 96- 100%)										

B. Patient #2

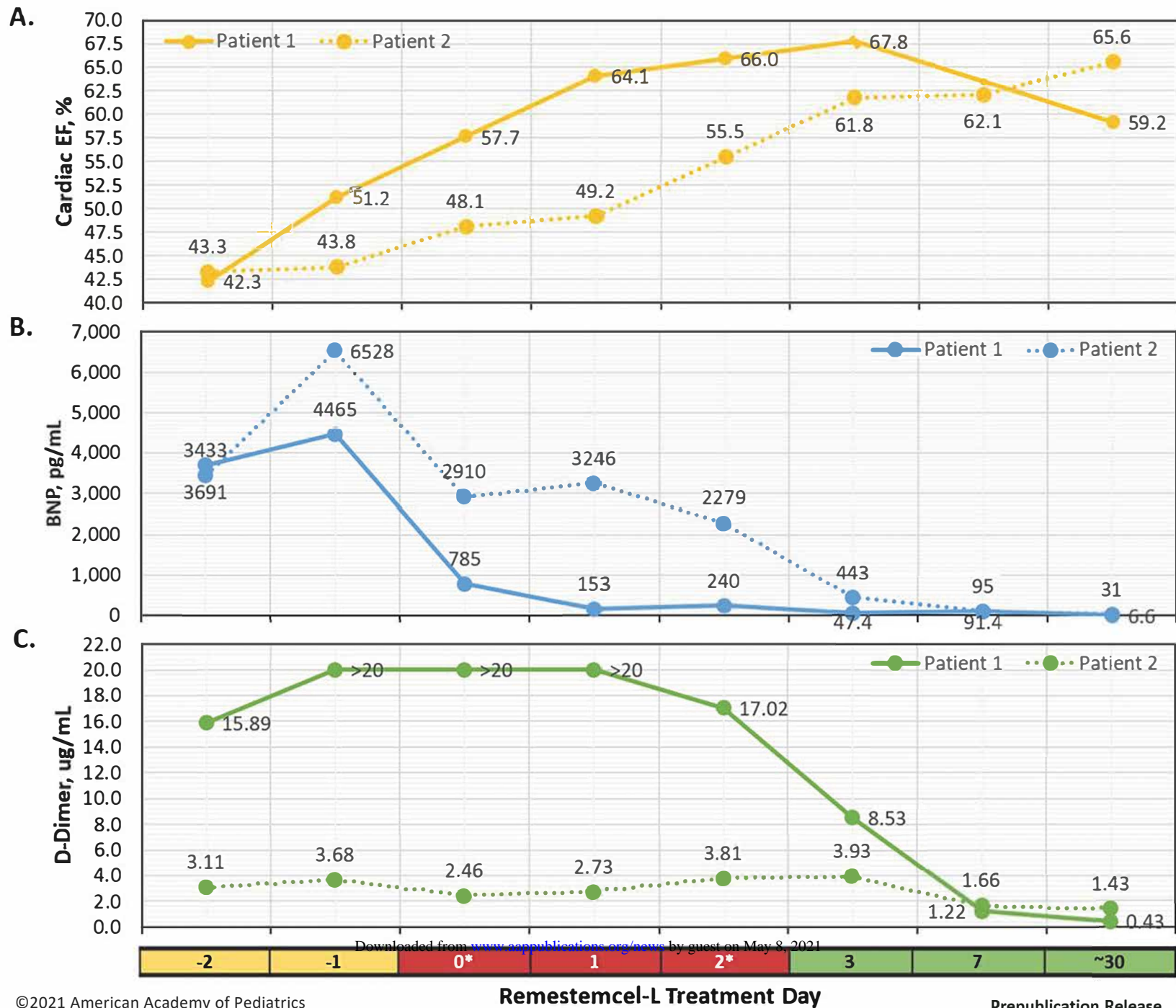
	OSH admission		transfer to MUSC										hospital discharge		outpatient
	↓		↓										↓		↓
Days since symptom onset	3	4	5	6	7	8	9	10	11	12	13	14		33	
Hospital admission day	1	2	3	4	5	6	7	8	9	10	11	12		--	
MSC treatment day	-4	-3	-2	-1	0*	+1	+2**	+3	+4	+5	+6	+7		+26	
Standard of care MIS-C treatment			IVIG	IVIG											
			methylprednisolone				prednisolone					prednisolone			
			LMWH												
			low-dose ASA		high-dose ASA		low-dose ASA					low-dose ASA			
Key blood laboratory findings [‡]															
Total WBC, 10 ³ /mm ³			31.1	16.1	17.7	16.1	22.6	21.7	22.0	17.2	--	18.2		8.2	
Neutrophils 10 ³ /mm ³			26.5	14.8	15.0	14.4	18.5	17.8	18.5	15.1	--	15.7		4.16	
Lymphocytes, 10 ³ /mm ³			1.56	0.53	0.65	0.81	2.03	2.17	1.32	0.86	--	1.28		2.78	

Platelets, 10³/mm³	197	249	170	193	312	342	354	352	--	375	193
Hemoglobin, g/dl	11.1	9.3	8.1	8.7	10.1	10.1	10.0	10.0	--	10.0	11.4
C-reactive protein, mg/liter	198	231	137	72	48	25	15	8.6	--	2.7	2.0
ESR, mm/hr	>100	--	--	--	--	--	--	--	--	--	30
Procalcitonin, ng/ml	29.2	31.6	18.1	7.3	2.5	0.86	0.61	0.36	--	0.09	--
D-dimer, µg/ml	3.1	3.7	2.5	2.7	3.8	3.9	3.3	2.4	--	1.7	1.4
Fibrinogen, mg/dl	876	891	726	572	532	427	384	382	--	312	--
Ferritin, ng/ml	1057	1786	1251	733	783	749	814	803	--	956	322
LDH, U/liter	754	--	--	--	--	--	--	--	--	--	--
Troponin-I, ng/ml	20.0	13.2	9.7	8.8	7.4	5.8	3.5	2.4	--	1.1	0.01
BNP, pg/ml	3433	6528	2910	3246	2279	443	160	93	--	95	31
Creatinine, mg/dl	4.3	3.6	2.5	1.8	1.5	1.1	0.8	0.8	--	0.6	0.8
Urea nitrogen, mg/dl	48	47	49	52	44	30	27	21	--	17	12
AST, U/liter	86	34	--	27	31	33	41	47	--	32	18
ALT, U/liter	72	47	--	31	29	28	36	47	--	46	25

Key echocardiogram findings													
LV ejection fraction, %		43.3	43.8	48.1	49.2	--	61.8	--	--	--	61.1		65.6
LV end systolic volume, ml		64.7	61.8	59.7	58.8	--	40.1	--	--	--	39.2		36.8
LV end diastolic volume, ml		114	110	115	116	--	105	--	--	--	103		107
Main clinical findings		hypotension; epi/norepinephrine			hypertension; nicardipine → lisinopril					hypertension; lisinopril			
		poor cardiac output; milrinone				clinically			clinically				
		respiratory distress; intubated			well			well					

*first remestemcel-L infusion; **second remestemcel-L infusion; †laboratory and echocardiogram data obtained on MSC treatment day 26 and day 33, respectively; ‡Conversion to SI units follows in parentheses for each laboratory measurement: total WBC, neutrophils, lymphocytes, platelets to cells x10⁹/liter (0.001); hemoglobin to mmol/liter (0.6206); D-dimer to mg/liter (1.0); fibrinogen to g/liter (0.01); ferritin, procalcitonin, troponin-I to µg/liter (1.0); LDH, AST, ALT to µkat/liter (0.01667); creatinine to µmol/liter (88.4); urea nitrogen to mmol/liter (0.3571); BNP to ng/liter (1.0). N.B. laboratory and echocardiogram numbers with bolded font represent abnormal values deemed clinically relevant. OSH, outside hospital; MUSC, Medical University of South Carolina; MSC, mesenchymal stromal cells; MIS-C, multisystem inflammatory syndrome in children; IVIG, intravenous immunoglobulin; LMWH, low-molecular-weight heparin; ASA, aspirin; WBC, white blood cells; ESR, erythrocyte sedimentation rate; LDH, lactate dehydrogenase; BNP, B-type natriuretic protein; AST, aspartate aminotransferase; ALT, alanine aminotransferase; LV, left ventricular; PRBCs, packed red blood cells.

Figure 1. Changes in key parameters depicted by remestemcel-L treatment day. Changes in LV ejection fraction (A), BNP (B), and D-dimer (C) based on remestemcel-L treatment day. Both children showed rapid normalization in LV ejection fraction and BNP, as well as improvement in D-dimer that were temporally-associated with the cell therapy. To convert BNP and D-dimer to ng/liter and mg/liter, respectively, multiply by 1.0. *first remestemcel-L infusion; **second remestemcel-L infusion. LV, left ventricular; BNP, B-type natriuretic protein.



Remestemcel-L Therapy for COVID-19-Associated Multisystem Inflammatory Syndrome in Children

Allison Ross Eckard, Kenneth M. Borow, Elizabeth H. Mack, Elizabeth Burke and Andrew M. Atz

Pediatrics originally published online February 12, 2021;

Updated Information & Services

including high resolution figures, can be found at:
<http://pediatrics.aappublications.org/content/early/2021/02/11/peds.2020-046573.citation>

Permissions & Licensing

Information about reproducing this article in parts (figures, tables) or in its entirety can be found online at:
<http://www.aappublications.org/site/misc/Permissions.xhtml>

Reprints

Information about ordering reprints can be found online:
<http://www.aappublications.org/site/misc/reprints.xhtml>

American Academy of Pediatrics

DEDICATED TO THE HEALTH OF ALL CHILDREN®



PEDIATRICS[®]

OFFICIAL JOURNAL OF THE AMERICAN ACADEMY OF PEDIATRICS

Remestemcel-L Therapy for COVID-19-Associated Multisystem Inflammatory Syndrome in Children

Allison Ross Eckard, Kenneth M. Borow, Elizabeth H. Mack, Elizabeth Burke and Andrew M. Atz

Pediatrics originally published online February 12, 2021;

The online version of this article, along with updated information and services, is located on the World Wide Web at:

<http://pediatrics.aappublications.org/content/early/2021/02/11/peds.2020-046573.citation>

Pediatrics is the official journal of the American Academy of Pediatrics. A monthly publication, it has been published continuously since 1948. Pediatrics is owned, published, and trademarked by the American Academy of Pediatrics, 345 Park Avenue, Itasca, Illinois, 60143. Copyright © 2021 by the American Academy of Pediatrics. All rights reserved. Print ISSN: 1073-0397.

American Academy of Pediatrics

DEDICATED TO THE HEALTH OF ALL CHILDREN[®]

