

# PEDIATRICS

OFFICIAL JOURNAL OF THE AMERICAN ACADEMY OF PEDIATRICS

## Toddler With New Onset Diabetes and Atypical Hemolytic Uremic Syndrome in the Setting of COVID-19

Faraz Alizadeh, MD, Amanda O'Halloran, MD, Areej Alghamdi, MBBS, Charlotte Chen, DO, Maria Trissal, MD, PhD, Avram Traum, MD, Danielle DeCoursey, MD, MPH

**DOI:** 10.1542/peds.2020-016774

**Journal:** *Pediatrics*

**Article Type:** Case Report

**Citation:** Alizadeh F, O'Halloran A, Alghamdi A, et al. Toddler with new onset diabetes and atypical hemolytic uremic syndrome in the setting of COVID-19. *Pediatrics*. 2020; doi: 10.1542/peds.2020-016774

This is a prepublication version of an article that has undergone peer review and been accepted for publication but is not the final version of record. This paper may be cited using the DOI and date of access. This paper may contain information that has errors in facts, figures, and statements, and will be corrected in the final published version. The journal is providing an early version of this article to expedite access to this information. The American Academy of Pediatrics, the editors, and authors are not responsible for inaccurate information and data described in this version.

## Toddler With New Onset Diabetes and Atypical Hemolytic Uremic Syndrome in the Setting of COVID-19

Faraz Alizadeh<sup>a,b</sup>, MD, Amanda O'Halloran<sup>a,b</sup>, MD, Areej Alghamdi<sup>a,b</sup>, MBBS, Charlotte Chen<sup>a,b</sup>, DO, Maria Trissal<sup>a,b</sup>, MD, PhD, Avram Traum<sup>a,b</sup>, MD, Danielle DeCoursey<sup>a,b</sup>, MD, MPH.

### Affiliations:

<sup>a</sup>Boston Children's Hospital, Boston, Massachusetts

<sup>b</sup>Harvard Medical School, Boston, Massachusetts

Amanda O'Halloran is now with the Children's Hospital of Philadelphia, Philadelphia, PA.

**Address Correspondence to:** Faraz Alizadeh MD, Department of Medical Critical Care, Boston Children's Hospital, 300 Longwood Ave, Boston, MA 02115, Faraz.Alizadeh@childrens.harvard.edu, 702-439-1890

**Funding Source:** No external funding for this manuscript

**Financial Disclosure:** None of the authors have any financial relationships relevant to this article to disclose

**Conflict of Interest:** None of the authors have any conflict of interests to disclose

### Abbreviations:

- Atypical hemolytic uremic syndrome (aHUS)
- Diabetic ketoacidosis (DKA)
- Pediatric intensive care unit (PICU)
- Disseminated intravascular coagulation (DIC)
- Thrombotic microangiopathies (TMAs)
- Thrombotic thrombocytopenic purpura (TTP)

### Table of Contents Summary:

The case of a 16-month-old male with numerous comorbidities who developed COVID-19, diabetic ketoacidosis with new onset diabetes and atypical hemolytic uremic syndrome.

**Contributor's Statement Page**

Dr. Alizadeh participated in clinical care of the patient, conceptualized the manuscript and the clinical implications of the case, drafted the initial manuscript, and reviewed/revise the manuscript.

Drs. DeCoursey and Traum participated in the clinical care of the patient, conceptualized the manuscript and the clinical implications of the case, and reviewed/revise the manuscript.

Dr. Trissal participated in the clinical care of the patient, created and reviewed the hematology slide and reviewed/revise the manuscript.

Drs. O'Halloran, Alghamdi, and Chen participated in the clinical care of the patient and reviewed/revise the manuscript.

All authors approved the final manuscript as submitted and agree to be accountable for all aspects of the work.

## Abstract

This is a novel case of a 16-month-old male with a history of prematurity with intrauterine growth restriction, severe failure to thrive, microcephaly, pachygyria, agenesis of the corpus callosum and postnatal embolic stroke, who presented with new-onset diabetes mellitus with diabetic ketoacidosis in the setting of SARS-CoV-2 infection, with a course complicated by atypical hemolytic syndrome (aHUS). This patient demonstrated remarkable insulin resistance in the period prior to aHUS diagnosis which resolved with the first dose of eculizumab therapy. There is increasing evidence that COVID-19 is associated with thrombotic disorders and that microangiopathic processes and complement-mediated inflammation may be implicated. This case report describes a pediatric patient with COVID-19 and a new complement-mediated microangiopathic thrombotic disease. As whole exome sequencing and extensive workup returned without a clear etiology for aHUS, this is likely a COVID-19 triggered case of aHUS versus an idiopathic case that was unmasked by the infection.

## Introduction

SARS-CoV-2, the virus responsible for COVID-19, typically affects adults and presents with severe respiratory disease.<sup>1</sup> Children typically have milder forms of the disease.

Shekerdeman *et al* reported that of the 48 children admitted to 46 North American pediatric intensive care units (PICUs) from March 14<sup>th</sup> to April 3<sup>rd</sup>, 2020 with COVID-19, 83% had pre-existing conditions and most had respiratory symptoms.<sup>2</sup> Three children in this cohort presented with diabetic ketoacidosis (DKA), which mimics reports in adults.<sup>3,4</sup> Not only does diabetes appear to be a risk factor for COVID-19, the virus appears to trigger new cases of diabetes and complicate management of existing diabetes.<sup>5-7</sup>

COVID-19 is also associated with a pro-thrombotic state with increased risk of thrombosis and disseminated intravascular coagulation (DIC).<sup>8,9</sup> While other viruses, such as H1N1 Influenza, have been associated with thrombotic microangiopathies (TMAs) and infection can be a relapse trigger in patients with TMA due to atypical hemolytic uremic syndrome (aHUS), there has not yet been definitive evidence linking COVID-19 with TMAs. Autopsy of

patients with COVID-19 revealed that 3 out of 21 patients had generalized TMAs.<sup>10</sup> There is growing speculation that TMAs play a large role in COVID-19.<sup>11-13</sup>

In this case, we describe a toddler who presented with COVID-19, DKA and aHUS treated with eculizumab. This is the first COVID-19 presentation of its kind.

## Case

This is a case of a 16-month-old male with history of prematurity at 34 weeks' gestation, intrauterine growth restriction, severe failure to thrive, microcephaly, pachygyria, agenesis of the corpus callosum, postnatal embolic stroke with residual cranial nerve IV palsy, retinopathy of prematurity and multiple dysmorphisms without a unifying genetic disorder (prior chromosomal microarray revealed large areas of homozygosity). He was in his usual state of health until a day prior to presentation when he developed fever, emesis and respiratory distress. On presentation he was toxic appearing with fever, tachycardia, and tachypnea. Laboratory evaluation revealed a metabolic acidosis with venous pH of 7.0, PCO<sub>2</sub> of 17 mmHg, bicarbonate of 4 mmol/L, anion gap of 40, glucose of 805 mg/dL, elevated beta-hydroxybutyric acid, and hemoglobin A1c of 9.5%, confirming the diagnosis of DKA. Antibody testing obtained on admission revealed positive glutamic acid decarboxylase, zinc transporter 8 and IA-2 antibodies, confirming Type 1 Diabetes without anti-insulin antibodies. Additional labs revealed a white blood cell count of 33,000 with neutrophil predominance, elevated procalcitonin of 3 ng/mL (normal range <0.09), and hypernatremia (sodium 158 mmol/L). Chest x-ray was unremarkable and nasopharyngeal SARS-CoV-2 PCR testing was positive.

He was admitted to the PICU for DKA management, including an insulin infusion at 0.1 units/kg/hour for approximately 24 hours before he was transitioned to subcutaneous insulin. As

his initial tachypnea improved with correction of his acidosis, no oxygen, ventilatory support or COVID specific therapies were administered. The patient was transferred to the endocrinology wards on hospital day 4 and while on subcutaneous insulin he developed rapidly rising insulin requirement (Figure 1a). Additional evaluation was unremarkable for other endocrinopathies. On hospital day 6, he required re-admission to the PICU for hypernatremia secondary to hypovolemia from hyperglycemia-associated osmotic diuresis. He received fluid resuscitation and was placed back on an insulin infusion for 4 days due to insulin resistance and high insulin requirements. His insulin requirement peaked at 3.5 units/kg/day, 11 days after admission, as he became increasingly ill from aHUS (details below). His total daily insulin dose decreased to 0.5-1 units/kg/day following eculizumab administration. Ultimately, he was discharged on a subcutaneous insulin with a total daily dose of 1 units/kg/day.

Despite having normal hemoglobin and thrombocytosis on admission, he developed progressive thrombocytopenia and anemia on days 4-5 of admission, with platelets falling below 100K cells/uL on hospital day 10 (Figure 1b). Workup revealed reticulocytosis (13%), undetectable haptoglobin, elevated LDH (peak 3,190 u/L) and hyperbilirubinemia (peak bilirubin 1.5 mg/dL) suggestive of hemolysis. Peripheral blood smear revealed abundant schistocytes suggestive of a microangiopathic process and macrothrombocytopenia suggesting appropriate bone marrow response to peripheral platelet clearance (Figure 2). Additional abnormalities included elevated fibrinogen (peak 557 mg/dL), elevated ferritin (peak 1493 ng/mL) and rising BUN and creatinine (peak at 39 mg/dL and 0.39 mg/dL, respectively, up from baseline of 5 mg/dL and 0.1 mg/dL). C3 and C4 were normal (142 mg/dL and 19 mg/dL, respectively).

Initial differential diagnosis included thrombotic thrombocytopenic purpura (TTP), aHUS, and less likely DIC (as he had an elevated fibrinogen and his infectious symptoms had

resolved). Given the possibility of congenital TTP (hereditary ADAMTS13 deficiency), empiric fresh frozen plasma was trialed without improvement and testing ultimately revealed normal ADAMTS13 activity<sup>14</sup>. Clinically, the patient developed severe hypertension, rising BUN and creatinine, lower extremity swelling, hematuria, and nephrotic-range proteinuria (urine protein to creatine ratio of 36 mg/mg). Kidney ultrasound revealed normal sized echogenic kidneys. Echocardiogram demonstrated a structurally normal heart with normal function and a moderate pericardial effusion. His hypertension was initially refractory to calcium channel blockers, including simultaneous administration of amlodipine and nicardipine infusion due to inadequate blood pressure control while gradually increasing the dose of amlodipine. Ultimately, his hypertension was responsive to a labetalol infusion and diuresis. His final enteral antihypertensive regimen included amlodipine and labetalol.

Given clinical suspicion for aHUS with acute kidney injury, on hospital day 14, he was empirically treated with eculizumab (a monoclonal antibody which binds C5a, preventing terminal complement complex C5b-9) while awaiting complement functional studies. Following the first dose of eculizumab, his progressive anemia and thrombocytopenia improved. Pre-eculizumab bloodwork revealed a low CH50 complement activity level of 3 units (normal range 60-144), with elevated Factor H, Factor I, Bb fragment level, and soluble C5b-9 (sMAC) levels (0.45 mg/L, normal <0.3). No Factor H autoantibody was detected. Upon discharge, he was scheduled to continue receiving eculizumab therapy every three weeks for aHUS.

Given his atypical COVID-19 presentation, an immunology workup was performed and was reassuring against a primary immunodeficiency. Additionally, whole-exome sequencing, including mitochondrial and complement gene sequencing, did not reveal any known genetic disorders.

## Discussion

This is the first case report of a child with COVID-19 developing both DKA and aHUS. Given the patient's underlying dysmorphisms and comorbidities, we suspected a genetic syndrome predisposing him to both Type 1 Diabetes and aHUS. However, despite initial neonatal testing revealing numerous areas of homozygosity, whole-exome sequencing did not reveal any known genetic defects.

This presentation of COVID-19 with new-onset DKA was particularly notable for extraordinary insulin resistance which developed days after resolution of his ketoacidosis. This patient's total daily insulin dose peaked twice, first during DKA treatment and again on hospital days 11-12 prior to aHUS diagnosis. While it is clear that diabetes is a risk factor for mortality with COVID-19, the virus also may cause significant hyperglycemia, above what would be expected with stress hyperglycemia.<sup>6,7,15</sup> As a hyperinflammatory state is a hallmark of COVID-19, this hyperglycemia may result from insulin resistance in the context of inflammation. Many inflammatory markers - including IL-6, IL-1 $\beta$ , TNF- $\alpha$ , monocyte chemoattractant protein-1, inducible protein 10, and C3 - have been linked with insulin resistance.<sup>6,16-21</sup>

This patient was also found to have a TMA characterized by hemolytic anemia and thrombocytopenia. While there is a prior report of autoimmune hemolytic anemia triggered by COVID-19, this patient's Coombs testing was negative.<sup>22</sup> Initially TTP was high on the differential diagnosis given the patient's history of postnatal stroke, which is a known complication of congenital TTP. However, his normal ADAMTS13 activity and complement functional panel ruled out TTP making a diagnosis of aHUS more likely. There have been numerous reports of infectious triggers for aHUS and TMA, including H1N1 Influenza virus.<sup>23,24</sup> Given the timing of aHUS following SARS-CoV-2 infection and negative genetic evaluation, it



is likely that COVID-19 was an infectious trigger for this patient's condition although an idiopathic etiology is still possible.<sup>25</sup>

The patient in this case report did not receive anticoagulation and did not develop thrombosis. The use of combined dipyridamole and therapeutic dosing of unfractionated heparin in HUS has been studied and is associated with mild bleeding that did not require anticoagulation discontinuation.<sup>26</sup> Patients with COVID-19, a high sepsis-induced coagulopathy score and elevated D-dimer display decreased overall mortality when treated with prophylactic anticoagulation.<sup>27</sup> Given the benefits of prophylactic anticoagulation in COVID-19 and the lack of a significant increase in bleeding events in anticoagulated HUS patients, the benefits of low molecular weight heparin would have outweighed the risks for this patient.

The association between aHUS and COVID-19 described here are unclear at this time. There is evidence that COVID-19 causes a pro-thrombotic state and there are case reports suggesting complement-mediated inflammation and thrombotic microangiopathic processes may play a larger role in COVID-19.<sup>8,9,28</sup> Campbell *et al.* describe autopsy findings which reveal diffuse microvascular thrombi without viral infiltrates.<sup>11</sup> Additionally, mouse models deficient in C3 demonstrated reduced respiratory distress and pulmonary inflammation when infected with SARS-CoV (related virus to novel SARS-CoV-2), suggesting the complement system is instrumental in the hyperinflammatory response in SARS-CoV.<sup>29</sup> In another mouse model with MERS-CoV infection, elevated levels of C5a and C5a-9 complex were reported, providing further evidence of the role of complement.<sup>30</sup> Furthermore, with the SARS-CoV 2009 outbreak, complement activation, particularly C3 and C5a, was directly involved with the development of acute lung injury.<sup>29-31</sup> One case series from the COVID-19 pandemic reported improvement in inflammatory markers with multidrug combination therapy including eculizumab.<sup>32</sup> While the

patient in this report had respiratory symptoms secondary to acidosis rather than COVID-19, his development of a complement-mediated TMA may support these prior reports and models suggesting the complement pathway underlies the development of critical illness with COVID-19. Further research should be directed at assessing the role of complement in COVID-19 and its association with hyperinflammatory and prothrombotic states.

### Acknowledgments

We would like to acknowledge Drs. Matthew Heeney and Jeremi Carswell for their support in the clinical care of this patient and in manuscript preparation.

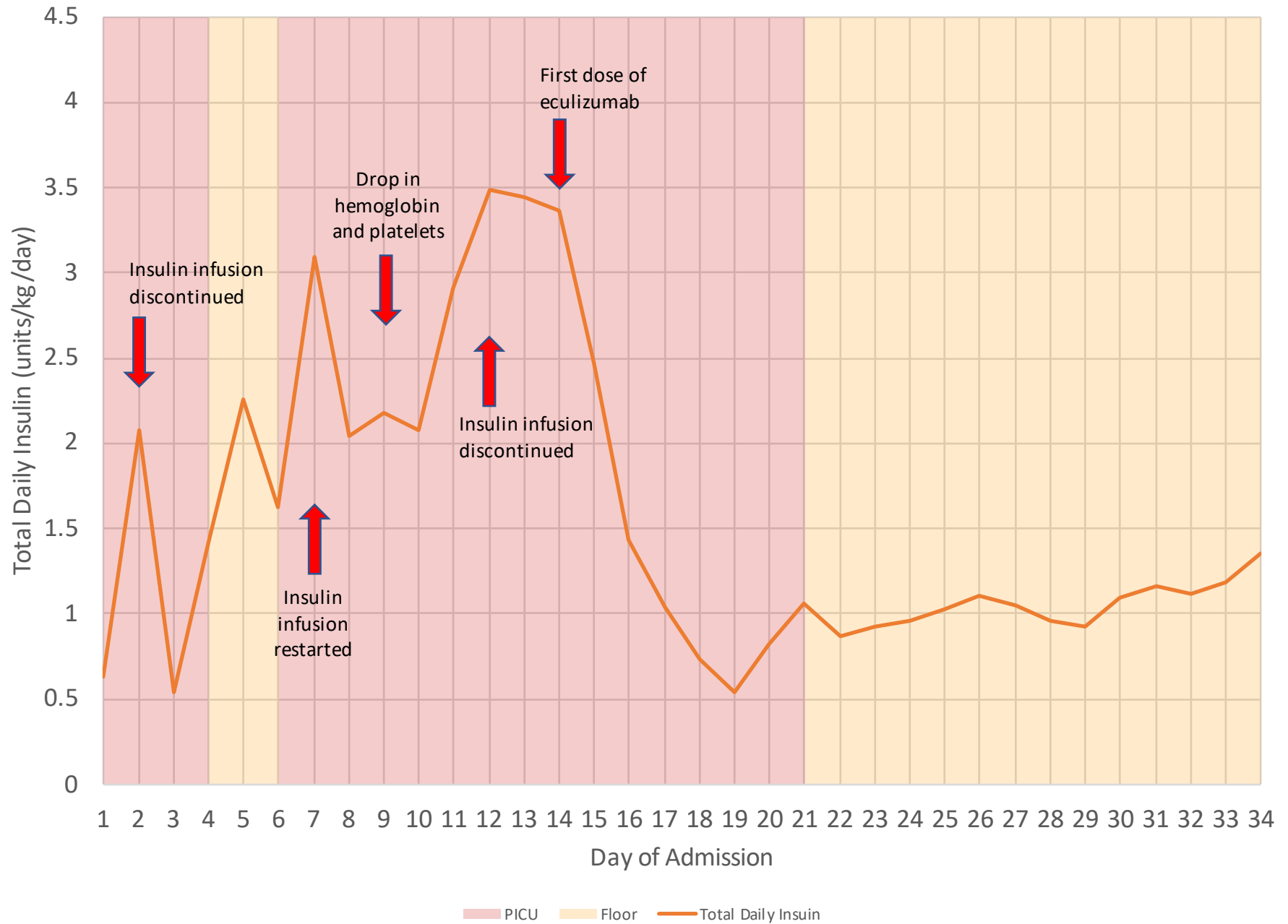
### References

1. Wu Z, McGoogan JM. Characteristics of and Important Lessons from the Coronavirus Disease 2019 (COVID-19) Outbreak in China: Summary of a Report of 72314 Cases from the Chinese Center for Disease Control and Prevention. *JAMA - J Am Med Assoc.* 2020;323(13):1239-1242. doi:10.1001/jama.2020.2648
2. Shekerdemian LS, Mahmood NR, Wolfe KK, et al. Characteristics and Outcomes of Children With Coronavirus Disease 2019 (COVID-19) Infection Admitted to US and Canadian Pediatric Intensive Care Units. *JAMA Pediatr.* May 2020. doi:10.1001/jamapediatrics.2020.1948
3. Li J, Wang X, Chen J, Zuo X, Zhang H, Deng A. <scp>COVID</scp> -19 infection may cause ketosis and ketoacidosis. *Diabetes, Obes Metab.* April 2020:dom.14057. doi:10.1111/dom.14057
4. Kim NY, Ha E, Moon JS, Lee Y-HH, Choi EY. Acute Hyperglycemic Crises with Coronavirus Disease-19: Case Reports. *Diabetes Metab J.* 2020;44(2):349-353. doi:10.4093/dmj.2020.0091
5. Ma WX, Ran XW. The Management of Blood Glucose Should be Emphasized in the Treatment of COVID-19. *Sichuan Da Xue Xue Bao Yi Xue Ban.* 2020;51(2):146-150. doi:10.12182/20200360606
6. Pal R, Bhadada SK, Singh AK, Gupta R, Ghosh A, Misra A. COVID-19 and diabetes

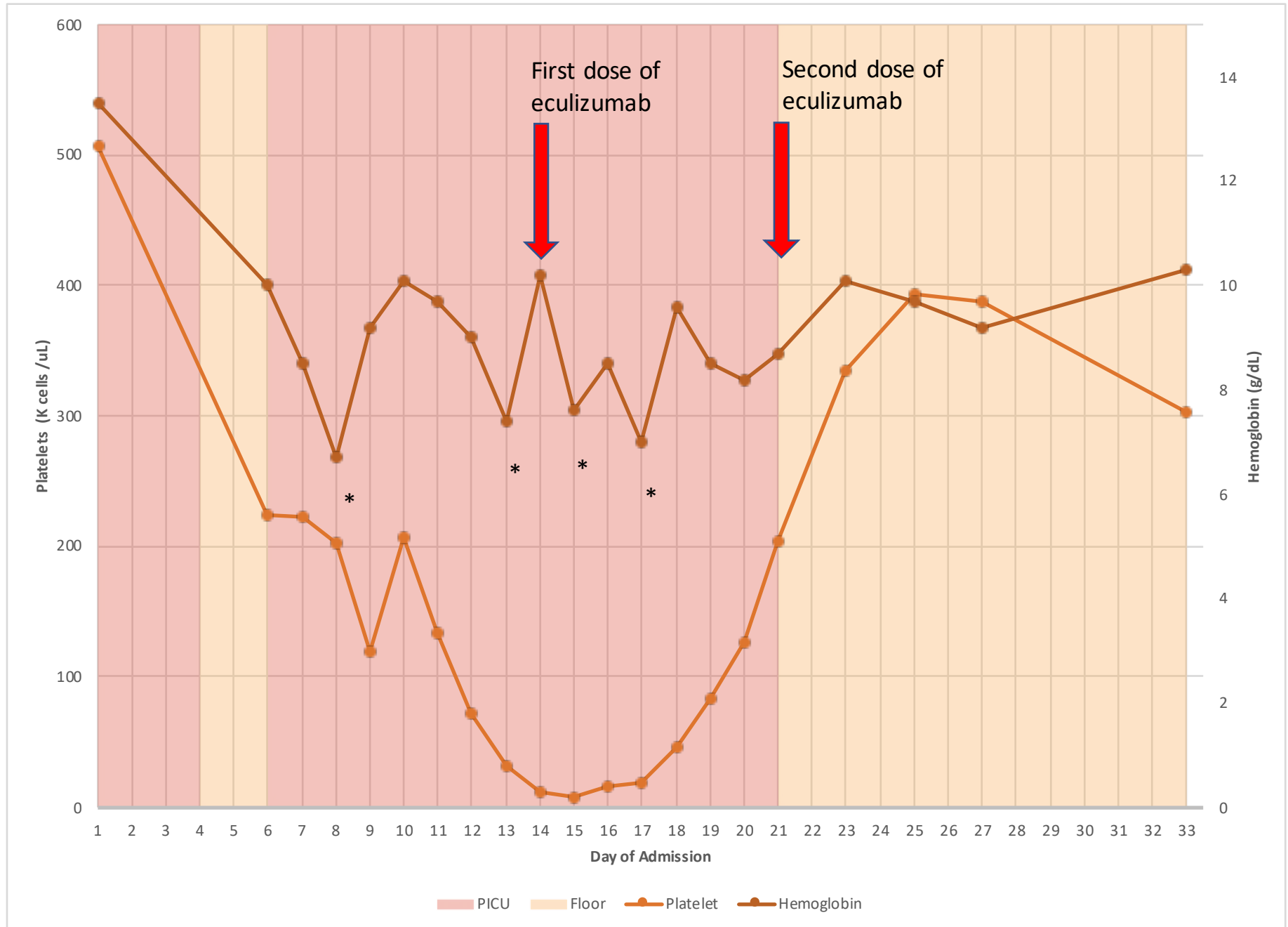
- mellitus: An unholy interaction of two pandemics. *Diabetes Metab Syndr Clin Res Rev.* 2020;14(4):513-517. doi:10.1016/j.dsx.2020.04.049
7. Gupta R, Ghosh A, Singh AK, Misra A. Clinical considerations for patients with diabetes in times of COVID-19 epidemic. *Diabetes Metab Syndr Clin Res Rev.* 2020;14(3):211-212. doi:10.1016/j.dsx.2020.03.002
  8. Connors JM, Levy JH. COVID-19 and its implications for thrombosis and anticoagulation. *Blood.* April 2020. doi:10.1182/blood.2020006000
  9. Helms J, Tacquard C, Severac F, et al. Intensive Care Medicine High risk of thrombosis in patients in severe SARS-CoV-2 infection: a multicenter prospective cohort study High risk of thrombosis in patients in severe SARS-CoV-2 infection: a multicenter prospective cohort study. *Intensive Care Med.* 2020. doi:10.1007/s00134-020-06062-x
  10. Menter T, Haslbauer JD, Nienhold R, et al. Post-mortem examination of COVID19 patients reveals diffuse alveolar damage with severe capillary congestion and variegated findings of lungs and other organs suggesting vascular dysfunction. *Histopathology.* May 2020;his.14134. doi:10.1111/his.14134
  11. Campbell CM, Kahwash R. Will Complement Inhibition be the New Target in Treating COVID-19 Related Systemic Thrombosis? *Circulation.* April 2020. doi:10.1161/circulationaha.120.047419
  12. Gavriilaki E, Brodsky RA. Severe COVID-19 infection and thrombotic microangiopathy: success does not come easily. *Br J Haematol.* May 2020;bjh.16783. doi:10.1111/bjh.16783
  13. Henry BM, Vikse J, Benoit S, Favalaro EJ, Lippi G. Hyperinflammation and derangement of renin-angiotensin-aldosterone system in COVID-19: A novel hypothesis for clinically suspected hypercoagulopathy and microvascular immunothrombosis. *Clin Chim Acta.* 2020;507:167-173. doi:10.1016/j.cca.2020.04.027
  14. Alwan F, Vendramin C, Liesner R, et al. Characterization and treatment of congenital thrombotic thrombocytopenic purpura. *Blood.* 2019;133(15):1644-1651. doi:10.1182/blood-2018-11-884700
  15. Huang I, Lim MA, Pranata R. Diabetes mellitus is associated with increased mortality and severity of disease in COVID-19 pneumonia – A systematic review, meta-analysis, and meta-regression: Diabetes and COVID-19. *Diabetes Metab Syndr Clin Res Rev.* 2020;14(4):395-403. doi:10.1016/j.dsx.2020.04.018
  16. Jager J, Grémeaux T, Cormont M, Le Marchand-Brustel Y, Tanti JF. Interleukin-1 $\beta$ -induced insulin resistance in adipocytes through down-regulation of insulin receptor substrate-1 expression. *Endocrinology.* 2007;148(1):241-251. doi:10.1210/en.2006-0692
  17. Senn JJ, Klover PJ, Nowak IA, Mooney RA. Interleukin-6 induces cellular insulin resistance in hepatocytes. *Diabetes.* 2002;51(12):3391-3399.

- doi:10.2337/diabetes.51.12.3391
18. Borst SE. The role of TNF- $\alpha$  in insulin resistance. *Endocrine*. 2004;23(2-3):177-182. doi:10.1385/ENDO:23:2-3:177
  19. Chang CC, Wu CL, Su WW, et al. Interferon gamma-induced protein 10 is associated with insulin resistance and incident diabetes in patients with nonalcoholic fatty liver disease. *Sci Rep*. 2015;5(1):1-11. doi:10.1038/srep10096
  20. Koistinen HA, Koivisto VA, Ebeling P. Serum complement protein C3 concentration is elevated in insulin resistance in obese men. *Eur J Intern Med*. 2000;11(1):21-26. doi:10.1016/S0953-6205(99)00064-3
  21. Sartipy P, Loskutoff DJ. Monocyte chemoattractant protein 1 in obesity and insulin resistance. *Proc Natl Acad Sci U S A*. 2003;100(12):7265-7270. doi:10.1073/pnas.1133870100
  22. Lopez C, Kim J, Pandey A, Huang T, DeLoughery TG. Simultaneous Onset of COVID-19 and Autoimmune Hemolytic Anemia. *Br J Haematol*. May 2020. doi:10.1111/bjh.16786
  23. Allen U, Licht C. Pandemic H1N1 influenza A infection and (atypical) HUS-more than just another trigger? *Pediatr Nephrol*. 2011;26(1):3-5. doi:10.1007/s00467-010-1690-z
  24. Bitzan M, Zieg J. Influenza-associated thrombotic microangiopathies. *Pediatr Nephrol*. 2018;33(11):2009-2025. doi:10.1007/s00467-017-3783-4
  25. Goodship THJ, Cook HT, Fakhouri F, et al. Atypical hemolytic uremic syndrome and C3 glomerulopathy: conclusions from a “Kidney Disease: Improving Global Outcomes” (KDIGO) Controversies Conference. In: *Kidney International*. Vol 91. Elsevier B.V.; 2017:539-551. doi:10.1016/j.kint.2016.10.005
  26. Van Damme-Lombaerts R, Proesmans W, Van Damme B, et al. Heparin plus dipyridamole in childhood hemolytic-uremic syndrome: A prospective, randomized study. *J Pediatr*. 1988;113(5):913-918. doi:10.1016/S0022-3476(88)80031-3
  27. Tang N, Bai H, Chen X, Gong J, Li D, Sun Z. Anticoagulant treatment is associated with decreased mortality in severe coronavirus disease 2019 patients with coagulopathy. *J Thromb Haemost*. 2020;18(5):1094-1099. doi:10.1111/jth.14817
  28. Risitano AM, Mastellos DC, Huber-Lang M, et al. Complement as a target in COVID-19? *Nat Rev Immunol*. April 2020:1-2. doi:10.1038/s41577-020-0320-7
  29. Gralinski LE, Sheahan TP, Morrison TE, et al. Complement activation contributes to severe acute respiratory syndrome coronavirus pathogenesis. *MBio*. 2018;9(5). doi:10.1128/mBio.01753-18
  30. Jiang Y, Zhao G, Song N, et al. Blockade of the C5a-C5aR axis alleviates lung damage in hDPP4-transgenic mice infected with MERS-CoV article. *Emerg Microbes Infect*. 2018;7(1). doi:10.1038/s41426-018-0063-8

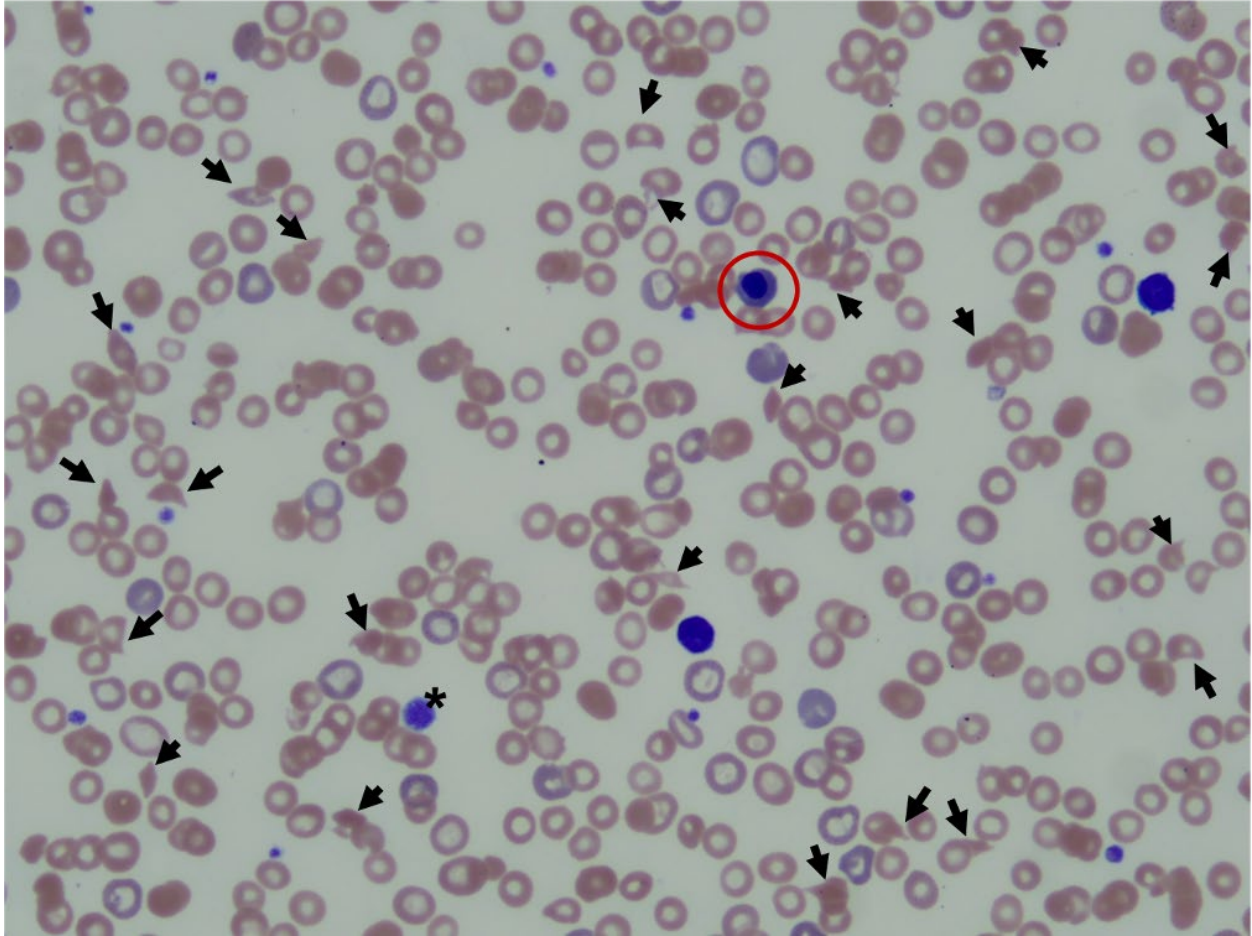
31. Wang R, Xiao H, Guo R, Li Y, Shen B. The role of C5a in acute lung injury induced by highly pathogenic viral infections. *Emerg Microbes Infect.* 2015;4(5):e28. doi:10.1038/emi.2015.28
32. Diurno F, Numis FG, Porta G, et al. Eculizumab treatment in patients with COVID-19: preliminary results from real life ASL Napoli 2 Nord experience. *Eur Rev Med Pharmacol Sci.* 2020;24(7):4040-4047. doi:10.26355/eurrev\_202004\_20875



**Figure 1A.** Total daily insulin dose over hospital course. Note, light red shaded areas represent days when the patient was in the ICU. Light orange shaded regions represent days when the patient was on the pediatric wards.



**Figure 1b.** Hemoglobin and platelets over hospital course. Note, \* indicated blood transfusion of packed red blood cells either for a hemoglobin level below 7 g/dL or in anticipation of a significant drop on a day with many blood draws. Light red shaded areas represent days when the patient was in the ICU. Light orange shaded regions represent days when the patient was on the pediatric wards.



**Figure 2.** Representative Peripheral Blood Smear. Abundant schistocytes (black arrow heads), increased size distribution of platelets including giant platelets (\*) and polychromasia with nucleated red cells (red circle) suggestive of a destructive peripheral microangiopathic process.



**Toddler With New Onset Diabetes and Atypical Hemolytic Uremic Syndrome in the Setting of COVID-19**

Faraz Alizadeh, Amanda O'Halloran, Areej Alghamdi, Charlotte Chen, Maria Trissal, Avram Traum and Danielle DeCoursey

*Pediatrics* originally published online October 9, 2020;

**Updated Information & Services**

including high resolution figures, can be found at:  
<http://pediatrics.aappublications.org/content/early/2020/10/06/peds.2020-016774.citation>

**Permissions & Licensing**

Information about reproducing this article in parts (figures, tables) or in its entirety can be found online at:  
<http://www.aappublications.org/site/misc/Permissions.xhtml>

**Reprints**

Information about ordering reprints can be found online:  
<http://www.aappublications.org/site/misc/reprints.xhtml>

American Academy of Pediatrics

DEDICATED TO THE HEALTH OF ALL CHILDREN®



# PEDIATRICS<sup>®</sup>

OFFICIAL JOURNAL OF THE AMERICAN ACADEMY OF PEDIATRICS

## **Toddler With New Onset Diabetes and Atypical Hemolytic Uremic Syndrome in the Setting of COVID-19**

Faraz Alizadeh, Amanda O'Halloran, Areej Alghamdi, Charlotte Chen, Maria Trissal, Avram Traum and Danielle DeCoursey

*Pediatrics* originally published online October 9, 2020;

The online version of this article, along with updated information and services, is located on the World Wide Web at:

<http://pediatrics.aappublications.org/content/early/2020/10/06/peds.2020-016774.citation>

Pediatrics is the official journal of the American Academy of Pediatrics. A monthly publication, it has been published continuously since 1948. Pediatrics is owned, published, and trademarked by the American Academy of Pediatrics, 345 Park Avenue, Itasca, Illinois, 60143. Copyright © 2020 by the American Academy of Pediatrics. All rights reserved. Print ISSN: 1073-0397.

American Academy of Pediatrics

DEDICATED TO THE HEALTH OF ALL CHILDREN<sup>®</sup>

