

Detection of a 22q11.2 Deletion in Cardiac Patients Suggests a Risk for Velopharyngeal Incompetence

Donna M. McDonald-McGinn, MS*‡; Deborah A. Driscoll, MD*§; Beverly S. Emanuel, PhD*‡; Elizabeth Goldmuntz, MD‡||; Bernard J. Clark III, MD‡||; Cynthia Solot, MA¶; Marilyn Cohen¶; Patricia Schultz, BSN¶; Donato LaRossa, MD¶#; Peter Randall, MD¶#; and Elaine H. Zackai, MD*‡§

ABSTRACT. *Objective.* Conotruncal cardiac anomalies frequently occur in patients with DiGeorge or velocardiofacial syndrome. Additionally, these patients may have overt or submucousal cleft palate, as well as velopharyngeal incompetence (VPI). Previous studies have demonstrated that the majority of these patients have a submicroscopic deletion of chromosome 22q11.2. We hypothesized that a subpopulation of newborns and children with congenital heart defects caused by a 22q11.2 deletion are at a high risk for having unrecognized palatal abnormalities. Therefore, we proposed to evaluate a cohort of patients with conotruncal cardiac malformations associated with a 22q11.2 deletion to determine the frequency of palatal abnormalities.

Methods. We identified 14 deletion-positive patients with congenital cardiac defects who had no overt cleft palate. Of the 14 patients evaluated for the 22q11.2 deletion, 8 patients were recruited from a previous study looking for deletions among patients with isolated conotruncal cardiac anomalies. Informed consent was obtained in these cases. The remaining patients had the deletion study on a clinical basis, ie, conotruncal cardiac defect and an absent thymus, immunodeficiency, or minor dysmorphism appreciated by the clinical geneticist. These patients were evaluated by a plastic surgeon and speech pathologist looking for more subtle palatal anomalies such as a submucousal cleft palate, absence of the musculus uvuli, and VPI. Some patients underwent videofluoroscopy or nasendoscopy depending on their degree of symptoms and age. VPI was not ruled out until objective evaluation by a speech pathologist and plastic surgeon was obtained. In addition, the child had to be old enough to provide an adequate speech sample.

Results. Of the 14 patients evaluated, 6 patients older than 1 year were found to have VPI. It is noteworthy that 3 of these patients were older than 5 years and had remained unrecognized until this study. The remaining 6 patients had inconclusive studies based on their age (younger than 26 months) and their inability to participate in adequate speech evaluations. Two of these patients, however, had histories of nasal regurgitation suggesting VPI and, in addition, had incomplete closure of the velopharyngeal mechanism during crying and swallowing observed during nasendoscopic examination—

consistent with the diagnosis of VPI. Thus, 8 of 14 patients evaluated had evidence of VPI by history and examination. The remaining 6 patients will require further study when they are older before a definitive palatal diagnosis can be made.

Conclusions. A significant number of patients with a 22q11.2 deletion in a cardiac clinic may have unrecognized palatal problems. Recognition of such abnormalities will afford patients the opportunity for intervention as needed, ie, speech therapy and/or surgical intervention. Notably, two of our patients with findings suggesting VPI were infants and will, therefore, be afforded the opportunity for close follow-up and early intervention. Furthermore, three school-aged children had palatal abnormalities that were unrecognized until this study. Thus, we recommend 22q11.2 deletion studies in patients with conotruncal cardiac malformations, followed by extensive palatal and speech evaluations when a deletion is present. *Pediatrics* 1997;99(5). URL: <http://www.pediatrics.org/cgi/content/full/99/5/e9>; *chromosome 22q11.2 deletion, DiGeorge syndrome, velocardiofacial syndrome, conotruncal anomaly face syndrome, Opitz G/BBB syndrome, conotruncal cardiac anomalies, cleft palate, velopharyngeal incompetence.*

ABBREVIATIONS. DGS, DiGeorge syndrome; FISH, fluorescence in situ hybridization; VCFS, velocardiofacial syndrome; VPI, velopharyngeal incompetence.

Cardiac anomalies are often observed in association with other malformations and as a feature of well-defined genetic syndromes. Frequently, the cardiac abnormality is the first presenting sign of a genetic disorder and may remain the predominant medical problem in the child's early years. Because of this, attention to or recognition of other problems may be overlooked. Diagnosis of a syndrome may not be made until later in life, if at all. In many cases, the early diagnosis of a syndrome is beneficial in guiding the total treatment of the child as well as in providing the family with accurate genetic counseling.

Conotruncal cardiac anomalies, including interrupted aortic arch type B, truncus arteriosus, and tetralogy of Fallot, are seen as part of DiGeorge syndrome (DGS). Additionally, some patients may have a conoventricular septal defect or a right-sided aortic arch with aberrant subclavian arteries.¹ DGS is a developmental field defect of the third and fourth pharyngeal pouches, which often includes thymic and parathyroid gland aplasia or hypoplasia, mild facial dysmorphism, and palatal abnormalities.^{2,3} The

From the Divisions of *Human Genetics and Molecular Biology, †Cardiology, and ‡Plastic and Reconstructive Surgery, Children's Hospital of Philadelphia; and Departments of ‡Pediatrics, §Obstetrics and Gynecology, and #Surgery, University of Pennsylvania School of Medicine, Philadelphia. Received for publication Feb 5, 1996; accepted May 20, 1996.

Reprint requests to (D.M.M.-M.) Division of Human Genetics and Molecular Biology, Children's Hospital of Philadelphia, 34th Street and Civic Center Boulevard, Philadelphia, PA 19104.

PEDIATRICS (ISSN 0031 4005). Copyright © 1997 by the American Academy of Pediatrics.

etiology of DGS is heterogeneous. There have been reports of autosomal dominant, autosomal recessive, and X-linked inheritance as well as an association with maternal diabetes.⁴⁻⁶ In addition, cytogenetic abnormalities have been observed in patients with DGS. Many of the chromosomal abnormalities observed in affected children have been unbalanced translocations, which result in monosomy 22pter→q11.⁷⁻¹⁶ More recently, high-resolution cytogenetic analysis and molecular studies using DNA dosage analysis or fluorescence in situ hybridization (FISH) have demonstrated that the vast majority of patients with DGS have interstitial or submicroscopic deletions within chromosomal region 22q11.2.¹⁷⁻²¹ We have detected microdeletions of 22q11.2 in approximately 90% of patients with DGS referred for molecular analysis.^{20,21} Studies have shown that FISH using chromosome 22q11.2-specific probes is an efficient method for the detection of 22q11.2 deletions and can be recommended as an adjunct to routine cytogenetic analysis.^{20,22}

Conotruncal defects, predominantly tetralogy of Fallot and conoventricular septal defects, have also been seen in association with velocardiofacial syndrome (VCFS).²³ VCFS has been described as an autosomal dominant disorder in which, in addition to having cardiac anomalies, patients may present with overt or submucousal cleft palate, velopharyngeal

incompetence (VPI), facial dysmorphism, and learning disabilities.²⁴⁻²⁷ Overlap between the features of DGS and VCFS, including cardiac anomalies, cleft palate, hypocalcemia, and immunodeficiency, suggested a common etiology and pathogenesis.²⁷⁻²⁹ Similar deletions of 22q11.2 have been detected in the majority of patients with VCFS.^{20,21,30,31}

Because facial dysmorphism is either not appreciated or evident in the newborn period, the diagnosis of DGS or VCFS is frequently dependent on the presence of other findings, such as hypocalcemia, immunodeficiency, and overt cleft palate in patients with conotruncal cardiac malformations. In the absence of these clues, the diagnosis may be difficult. Furthermore, a submucousal cleft palate or VPI without overt cleft palate is often unrecognized in the preverbal child and may remain undetected in the older child, particularly if there is a learning disability. Therefore, children who continue to have these unrecognized problems may remain untreated, missing the opportunity for early speech intervention and/or early surgical correction.

We hypothesized that a subpopulation of newborns and children with congenital heart defects and a 22q11.2 deletion are at high risk for having unrecognized palatal abnormalities. Therefore, we proposed to evaluate a cohort of patients with conotruncal cardiac malformations associated with a 22q11.2

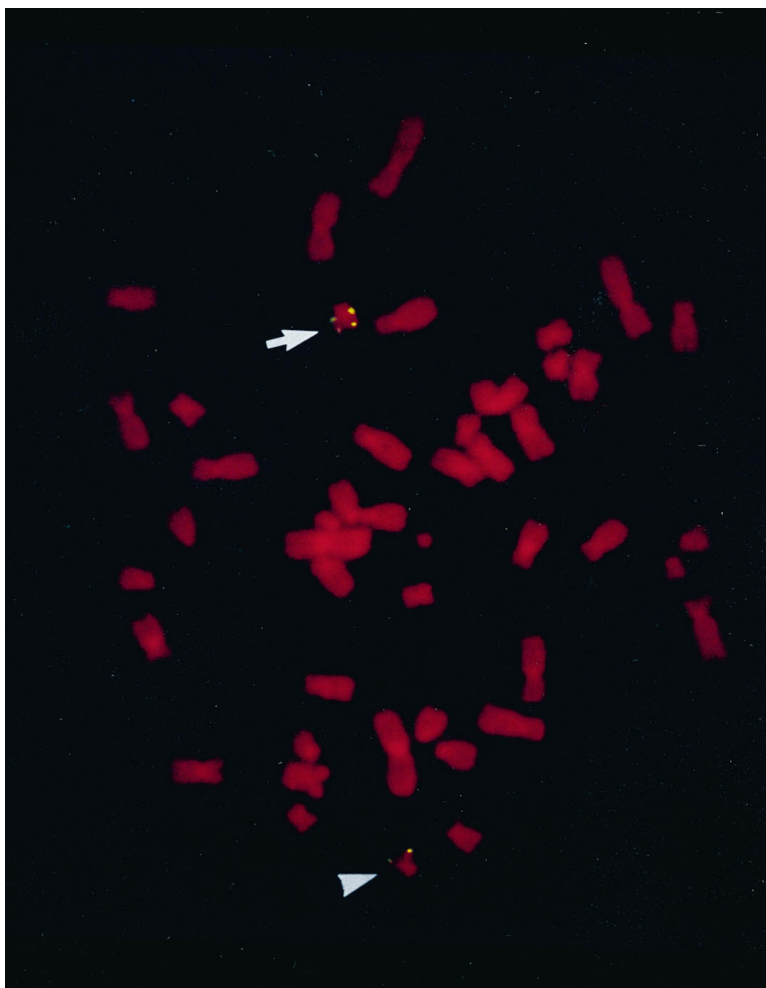


Fig 1. Fluorescence in situ hybridization demonstrates one normal chromosome 22 (arrow) and one deleted chromosome 22 (half arrow).

TABLE 1. Cardiac Findings in 14 Patients With 22q11.2 Deletion Referred for Palatal Evaluation

Finding	n
Truncus arteriosus	1
Interrupted aortic arch	3
Tetralogy of Fallot	4
Ventricular septal defect	4
Right-sided aortic arch	1
Interrupted aortic arch with truncus arteriosus	1

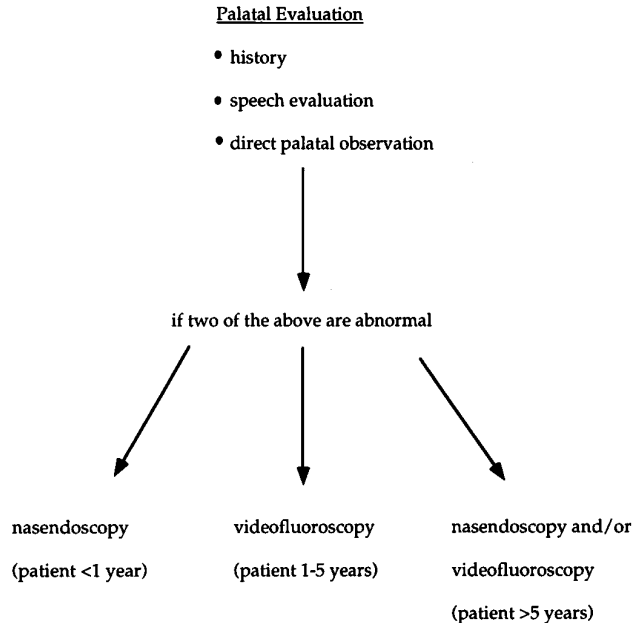


Fig 2. Flow diagram of palatal evaluation.

deletion to determine the frequency of palatal abnormalities.

METHODS

Patients with conotruncal cardiac anomalies underwent studies for the detection of a microdeletion of chromosome 22q11.2 (Fig 1) as previously described.²⁰ Children with an overt cleft palate were excluded from the present study. The first 14 cardiac patients with 22q11.2 deletions were referred for palatal evaluations (Table 1). Eight patients were recruited from a previous study looking for deletions among patients with isolated conotruncal cardiac anomalies.³² The remaining patients had the deletion study on a clinical basis, ie, conotruncal cardiac anomaly and an absent thymus, immunodeficiency, or minor dysmorphia appreciated by the clinical geneticist. These patients are also enrolled in a long-term prospective study to examine phenotype-genotype correlations.

Palatal evaluations were performed by a plastic surgeon and speech pathologist using standard history, physical examination, and speech evaluation. As indicated in Fig 2, patients underwent videofluoroscopy and/or nasendoscopy (Fig 3). VPI was not ruled out until objective evaluation by a speech pathologist and plastic surgeon was obtained. In addition, the child had to be old enough to provide an adequate speech sample.

RESULTS

Of the 14 patients evaluated, 7 were older than 1 year. Of these 7 patients, 6 were found to have VPI (Table 2). It is noteworthy that 3 of these patients, older than 5 years, were unrecognized until this study. One of the 3 patients subsequently has undergone a pharyngoplasty, whereas surgical intervention has been recommended for the other 2

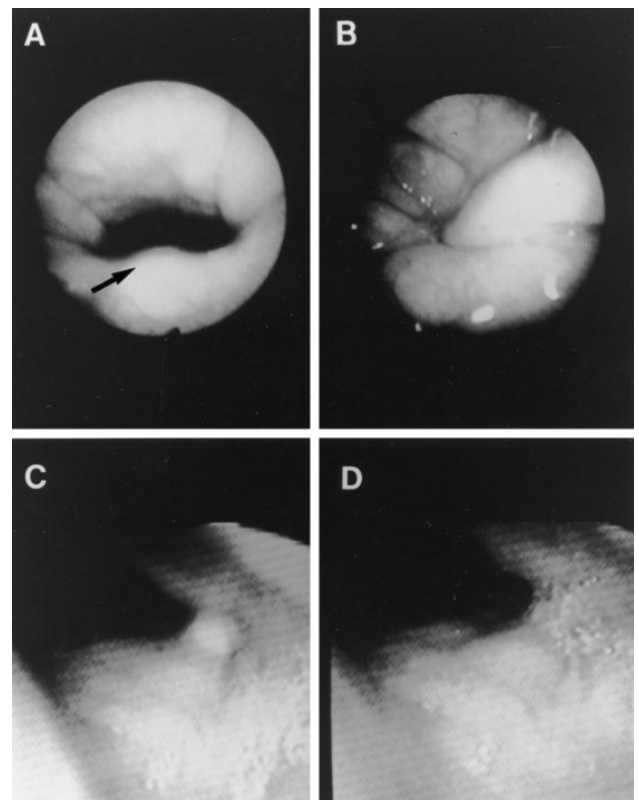


Fig 3. With nasendoscopy, a normal velopharyngeal port is visualized at rest, demonstrating a normal musculous uvuli (A, arrow) and a normal closure during crying or swallowing (B). An abnormal velopharyngeal port is visualized at rest, demonstrating the absence of the musculous uvuli (C) and an abnormal attempt at closure during crying or swallowing (D).

TABLE 2. Results of Palatal Evaluations in 14 Patients With Cardiac Anomalies and 22q11.2 Deletion

Age, y	Velopharyngeal Incompetence		
	Present	Absent	Inconclusive
<1 (n = 7)	2*	...	5
1-5 (n = 4)	3	0	1
>5 (n = 3)	3	0	0

* Determined by history of nasal regurgitation and nasendoscopy, with full speech evaluation to follow.

patients. Although it is generally difficult to diagnose VPI in children younger than 1 year, 2 patients in this age group had histories of nasal regurgitation suggesting VPI. In addition, incomplete closure of the velopharyngeal mechanism during crying and swallowing was observed during nasendoscopic examination—consistent with the diagnosis of VPI. However, these 2 patients will still require complete speech evaluations before the initiation of treatment plans, which most likely will include surgical correction and speech therapy. Six patients, younger than 26 months, were considered too young to assess to our satisfaction, based on our inability to perform complete speech evaluations. Thus, a total of 8 of 14 patients evaluated had evidence of VPI by history and examination. The remaining 6 patients will require further study when they are older before a definitive palatal diagnosis can be made.

Facial dysmorphism was discernible in some of the infants and was subtle, consisting of prominent ears, a bulbous nasal tip, and malar flatness, features seen with a 22q11.2 deletion (Fig 4). Dysmorphism was more apparent in some of the preschool-aged children (Fig 5) and school-aged children (Fig 6), in particular the bulbous nasal tip and prominent nasal root.

DISCUSSION

Studies by us and others have reported an association among DGS, VCFS, and chromosome 22q11.2 deletions.^{17,18,30,31} The commercial availability of a FISH assay for the detection of this deletion has made definitive diagnosis possible in most patients with clinical histories of DGS or VCFS. In addition, such studies may now be helpful in patients with conotruncal cardiac anomalies for the purpose of treatment and recurrence risk counseling. If a 22q11.2 deletion is detected, patients may be offered clinical evaluations before a problem becomes evident and, thus, may be offered early intervention. For example, it is noteworthy that two of our patients with findings suggesting VPI were infants and will, therefore, be afforded the opportunity for close follow-up and early intervention as indicated. These two patients, along with the other five in the younger age group, will provide us with unbiased prospective data to determine the efficacy of early recognition of and intervention for palatal abnormalities. Furthermore, it is of interest that the three school-aged

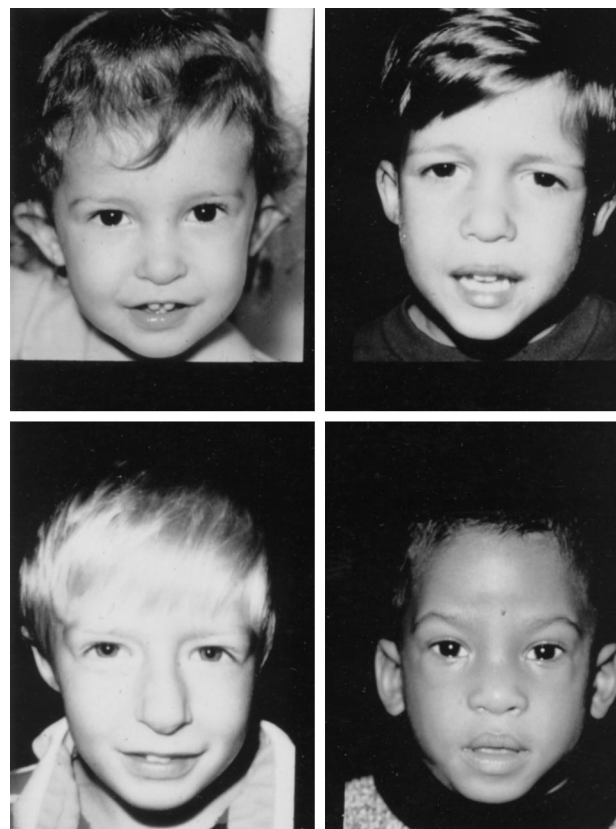

Fig 5. Four preschool-aged children with the 22q11.2 deletion have varying degrees of facial dysmorphism, including the emergence of a prominent nasal root.

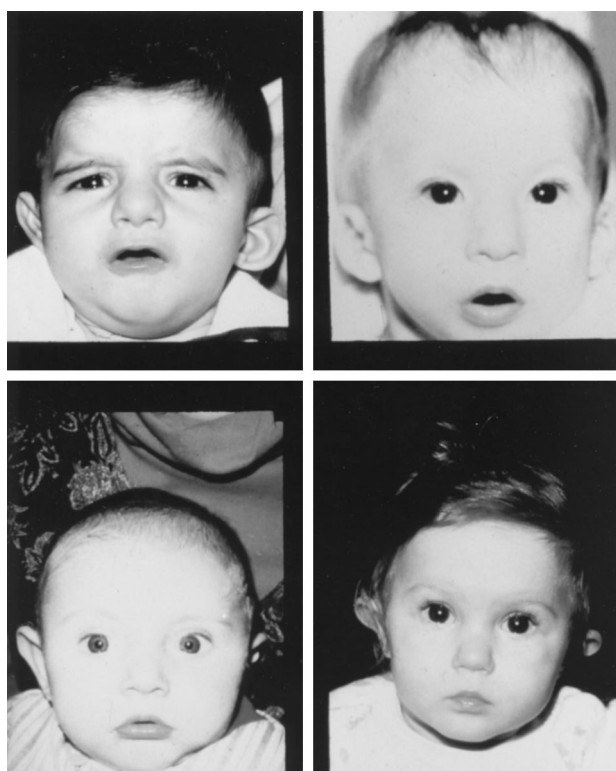


Fig 4. Four infants with diagnoses of a 22q11.2 deletion have subtle dysmorphism, including prominent ears, a bulbous nasal tip, and malar flatness.

children (older than 5 years) had unrecognized palatal abnormalities until this study.

With regard to recurrence risk, all 14 patients had de novo deletions of chromosome 22q11.2. Therefore, the recurrence risk to the parents of these 14 children is extremely small, assuming a very low but undefined risk for germ line mosaicism. The affected individuals have a 50% chance of passing the deletion chromosome 22 to their offspring. As adults, they will have the option of prenatal diagnosis, because this deletion may be detected in cultured cells obtained by either amniocentesis or chorionic villus sampling. In addition, some of the structural abnormalities associated with 22q11.2 deletions, including cleft palate and cardiac malformations, may be detected by prenatal ultrasonography and echocardiography.

In summary, this study indicates that there may be a significant number of patients with conotruncal cardiac anomalies, within the cardiac clinic, in whom unrecognized palatal problems exist. Deletion studies of patients with conotruncal malformations seem warranted, followed by extensive palatal and speech evaluation when a 22q11.2 deletion is present. Long-term prospective studies of these patients will be required to determine the outcome of early recognition and intervention.

Fig 6. Three school-aged children with the 22q11.2 deletion have bulbous nasal tips and prominent nasal roots with varying degrees of ear malformations.



ACKNOWLEDGMENTS

This study was supported in part by grants DC02027 and HL51533 from the National Institutes of Health, a grant from the Cleft Palate Foundation, and by funds from Oncor.

REFERENCES

1. VanMierop LHS, Kutsche LM. Cardiovascular anomalies in DiGeorge syndrome and importance of neural crest as a possible pathogenetic factor. *Am J Cardiol.* 1986;58:133-137
2. DiGeorge AM. Discussion on a new concept of the cellular basis of immunology. *J Pediatr.* 1965;67:907-908
3. Conley ME, Beckwith JB, Mancor JFK, Tenckhoff I. The spectrum of DiGeorge syndrome. *J Pediatr.* 1979;94:883-890
4. Lammer EJ, Opitz JM. The DiGeorge anomaly as a developmental field defect. *Am J Med Genet.* 1986;29:113-127
5. Wilson TA, Blethan SL, Vallone A, et al. DiGeorge anomaly with renal agenesis in infants of diabetic mothers. *Am J Med Genet.* 1993;47:1078-1082
6. Novak RW, Robinson HB. Coincident DiGeorge anomaly and renal agenesis and its relation to maternal diabetes. *Am J Med Genet.* 1993;50:311-312
7. Back E, Stier R, Bohsen N, Adlung A, Hameister H. Partial monosomy 22pter-11 in a newborn with the clinical features of trisomy 13 syndrome. *Ann Genet.* 1980;23:244-288
8. De la Chapelle A, Herva R, Koivisto M, Aula O. A deletion in chromosome 22 can cause DiGeorge syndrome. *Hum Genet.* 1981;57:253-256
9. Kelley RI, Zackai EH, Emanuel BS, Kistenmacher M, Greenberg F, Punnett H. The association of the DiGeorge anomalad with partial monosomy of chromosome 22. *J Pediatr.* 1982;101:197-200
10. Greenberg F, Crowder WE, Paschall V, Colon-Linares JC, Lubianski B, Ledbetter DH. Familial DiGeorge syndrome and associated partial monosomy of chromosome 22. *Hum Genet.* 1984;65:317-319
11. Greenberg F, Elder FFB, Haffner P, Northrup H, Ledbetter DH. Cytogenetic findings in a prospective series of patients with DiGeorge anomaly. *Am J Hum Genet.* 1988;43:605-611
12. Augusseau S, Jouk S, Jalbert P, Prieur M. DiGeorge syndrome and 22q11 rearrangements. *Hum Genet.* 1986;74:206
13. Bowen P, Pabst H, Berry D, Collins-Nakai R, Hoo JJ. Thymic deficiency in an infant with a chromosome t(18;22)(q12.2→1.2)pat arrangement. *Clin Genet.* 1986;29:174-177
14. El-Fouly MH, Higgins JV, Kapur S, Matisoff DN, Costa-Fox M. DiGeorge sequence in an infant with deletion of chromosome 22 and dup(9p) due to adjacent type II disjunction. *Am J Med Genet.* 1991;38:569-578
15. Faed FJW, Robertson J, Swanson Beck J, Carter JI, Bose B, Madlon MM. Features of DiGeorge syndrome in a child with 45,XX,-3,-22,+der(3)t(3;22)(p251). *J Med Genet.* 1987;24:225-234
16. Pivnick EK, Wilroy RS, Summit JB, Tucker B, Herro JG, Tharapel AT. Adjacent-2 disjunction of a maternal t(9;22) leading to duplication 9pter→q22 and deficiency of 22pter→q11.2. *Am J Med Genet.* 1990;37:92-96
17. Driscoll DA, Budarf ML, Emanuel BS. A genetic etiology for DiGeorge syndrome: consistent deletions and microdeletions of 22q11. *Am J Hum Genet.* 1992;50:924-933
18. Carey AH, Kelley D, Halford S, et al. Molecular genetic study of the frequency of monosomy 22q11 in DiGeorge syndrome. *Am J Hum Genet.* 1992;51:964-970
19. Wilson DI, Cross IE, Goodship JA, et al. A prospective cytogenetic study of 36 cases of DiGeorge syndrome. *Am J Hum Genet.* 1992;51:957-963
20. Driscoll DA, Salvin J, Sellinger B, et al. Prevalence of 22q11 microdeletions in DiGeorge and velocardiofacial syndromes: implications for genetic counseling and prenatal diagnosis. *J Med Genet.* 1993;30:813-817
21. Driscoll DA, Goldmuntz E, Emanuel BS. Detection of 22q11 deletions in patients with conotruncal cardiac malformations, DiGeorge, velocardiofacial and conotruncal anomaly face syndromes. In: Takao A, Clark E, eds. *Proceedings of the Fourth International Symposium on Congenital Heart Disease.* 1995
22. Desmaze C, Scambler P, Prieur M, et al. Routine diagnosis of DiGeorge syndrome by fluorescent in situ hybridization. *Hum Genet.* 1993;90:663-665
23. Young D, Shprintzen RJ, Goldberg RB. Cardiac malformations in the velo-cardio-facial syndrome. *Am J Cardiol.* 1980;46:643-647
24. Shprintzen RJ, Goldberg RB, Lewin ML, et al. A new syndrome involving cleft palate, cardiac anomalies, typical facies, and learning disabilities: velo-cardio-facial syndrome. *Cleft Palate Craniofac J.* 1978;5:56-62
25. Shprintzen RJ, Goldberg RB, Young D, Wolford L. The velo-cardio-facial syndrome: a clinical and genetic analysis. *Pediatrics.* 1981;67:167-172
26. Lipson AH, Yuille D, Angel M, et al. Velocardiofacial (Shprintzen) syndrome: an important syndrome for the dysmorphologist to recognize. *J Med Genet.* 1991;28:596-604
27. Shprintzen RJ, Wang F, Goldberg R, Marion R. The expanded velo-cardio-facial syndrome: additional features of the most common clefting syndrome. *Am J Hum Genet.* 1985;37:A77. Abstract
28. Goldberg R, Marion R, Borderon M. Phenotypic overlap between velo-cardio-facial syndrome and DiGeorge sequence. *Am J Hum Genet.* 1985;37:A54. Abstract
29. Stevens CA, Carey JC, Shigeoka AO. DiGeorge anomaly and velo-cardio-facial syndrome. *Pediatrics.* 1990;85:526-530
30. Driscoll DA, Spinner NB, Budarf ML, et al. Deletions and microdeletions of 22q11.2 in velo-cardio-facial syndrome. *Am J Med Genet.* 1992;44:261-268
31. Kelley D, Goldberg R, Wilson D, et al. Confirmation that the velo-cardio-facial syndrome is associated with haplo-insufficiency of genes at chromosome 22. *Am J Med Genet.* 1993;45:308-312
32. Goldmuntz E, Driscoll D, Budarf ML, et al. Microdeletions of chromosomal region 22q11 in patients with congenital conotruncal cardiac defects. *J Med Genet.* 1993;30:807-812

Detection of a 22q11.2 Deletion in Cardiac Patients Suggests a Risk for Velopharyngeal Incompetence

Donna M. McDonald-McGinn, Deborah A. Driscoll, Beverly S. Emanuel, Elizabeth Goldmuntz, Bernard J. Clark III, Cynthia Solot, Marilyn Cohen, Patricia Schultz, Donato LaRossa, Peter Randall and Elaine H. Zackai

Pediatrics 1997;99:e9

DOI: 10.1542/peds.99.5.e9

Updated Information & Services

including high resolution figures, can be found at:
<http://pediatrics.aappublications.org/content/99/5/e9>

References

This article cites 29 articles, 6 of which you can access for free at:
<http://pediatrics.aappublications.org/content/99/5/e9#BIBL>

Permissions & Licensing

Information about reproducing this article in parts (figures, tables) or in its entirety can be found online at:
<http://www.aappublications.org/site/misc/Permissions.xhtml>

Reprints

Information about ordering reprints can be found online:
<http://www.aappublications.org/site/misc/reprints.xhtml>

American Academy of Pediatrics

DEDICATED TO THE HEALTH OF ALL CHILDREN™



PEDIATRICS®

OFFICIAL JOURNAL OF THE AMERICAN ACADEMY OF PEDIATRICS

Detection of a 22q11.2 Deletion in Cardiac Patients Suggests a Risk for Velopharyngeal Incompetence

Donna M. McDonald-McGinn, Deborah A. Driscoll, Beverly S. Emanuel, Elizabeth Goldmuntz, Bernard J. Clark III, Cynthia Solot, Marilyn Cohen, Patricia Schultz, Donato LaRossa, Peter Randall and Elaine H. Zackai

Pediatrics 1997;99:e9

DOI: 10.1542/peds.99.5.e9

The online version of this article, along with updated information and services, is located on the World Wide Web at:

<http://pediatrics.aappublications.org/content/99/5/e9>

Pediatrics is the official journal of the American Academy of Pediatrics. A monthly publication, it has been published continuously since 1948. Pediatrics is owned, published, and trademarked by the American Academy of Pediatrics, 141 Northwest Point Boulevard, Elk Grove Village, Illinois, 60007. Copyright © 1997 by the American Academy of Pediatrics. All rights reserved. Print ISSN: 1073-0397.

American Academy of Pediatrics

DEDICATED TO THE HEALTH OF ALL CHILDREN™

