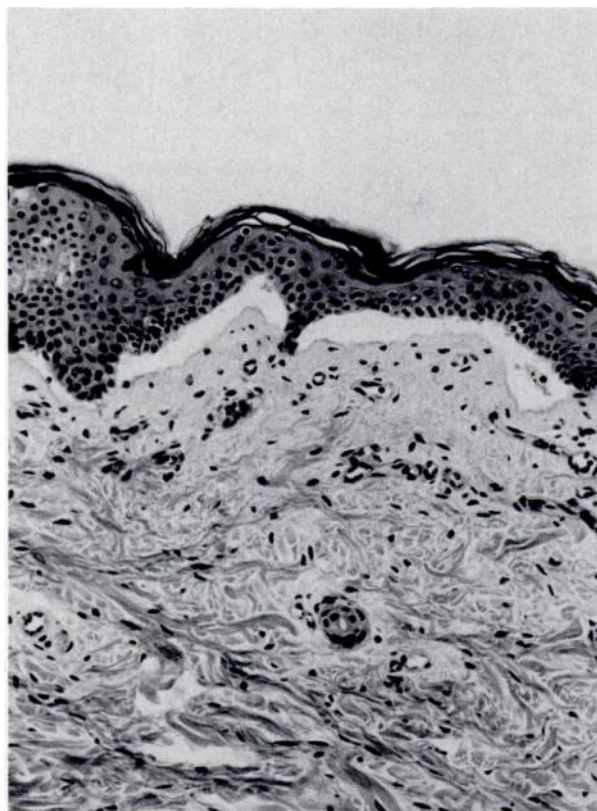


18. Butzler JP: *Campylobacter enteritis*, in Holme T, Holmgren J, Merson MH, (eds): *Acute Enteric Infections in Children, New Prospects for Treatment and Prevention*. Amsterdam, Elsevier/North-Holland Biomedical Press, 1981, pp 63-72
19. Yolken RH, Kim HW, Clem T, et al: Enzyme-linked immunosorbent assay (ELISA) for detection of human reovirus like agent for infantile gastroenteritis. *Lancet* 1977;2:263-267
20. *NCHS Growth Curves for Children Birth-18 Years, United States*, US Department of Health, Education, and Welfare publication (PHS) 78-1650. Hyattsville, Md, National Center for Health Statistics, 1977
21. Nalin DR, Levine MM, Mata L, et al: Oral rehydration and maintenance of children with rotavirus and bacterial diarrhoeas. *Bull WHO* 1979;57:453-459
22. Sharifi J, Ghavami F: Oral rehydration therapy of severe diarrheal dehydration. *Clin Pediatr* 1984;23:87-90
23. Pizarro D, Posada G, Mata L: Treatment of 242 neonates with dehydrating diarrhea with an oral glucose-electrolyte solution. *J Pediatr* 1983;102:153-156
24. Pizarro D, Posada G, Levine MM: Hypernatremic diarrheal dehydration treated with "slow" (12-hour) oral rehydration therapy: A preliminary report. *J Pediatr* 1984;104:316-319
25. Pizarro D, Posada G, Villavicencio N, et al: Hypernatremic and hyponatremic dehydration treated with oral glucose/electrolyte solution (90 mmol/L sodium). *Am J Dis Child* 1983;137:730-734
26. Mahalanabis D, Patra FC: In search of a super oral rehydration solution: Can optimum use of organic solute-mediated sodium absorption lead to the development of an absorption promoting drug? *J Diar Dis Res* 1983;1:76-81
27. Pizarro D: En busca de la solución ideal para la rehidratación por vía oral. *Bol Med Hosp Infant Mex* 1985;42:3-8
28. Phillips SF, Code CF: Sorption of potassium in the small and large intestine. *Am J Physiol* 1966;211:607-613
29. Ware S: Hypernatraemia and "glucose water". *Lancet* 1976;1:494

ERRATUM

In the article, "Junctional Epidermolysis Bullosa of the Larynx," by Kenna and Stool (*Pediatrics* 1986;78:172-174), the figure below should be substituted for the one actually printed, with the following legend: Stratified epithelium of skin biopsy demonstrating epidermal-dermal separation.



ERRATUM
Pediatrics 1987;79:195

Updated Information & Services

including high resolution figures, can be found at:
<http://pediatrics.aappublications.org/content/79/2/195>

Permissions & Licensing

Information about reproducing this article in parts (figures, tables) or in its entirety can be found online at:
<http://www.aappublications.org/site/misc/Permissions.xhtml>

Reprints

Information about ordering reprints can be found online:
<http://www.aappublications.org/site/misc/reprints.xhtml>

American Academy of Pediatrics

DEDICATED TO THE HEALTH OF ALL CHILDREN®



PEDIATRICS®

OFFICIAL JOURNAL OF THE AMERICAN ACADEMY OF PEDIATRICS

ERRATUM

Pediatrics 1987;79;195

The online version of this article, along with updated information and services, is located on the World Wide Web at:

<http://pediatrics.aappublications.org/content/79/2/195>

Pediatrics is the official journal of the American Academy of Pediatrics. A monthly publication, it has been published continuously since 1948. Pediatrics is owned, published, and trademarked by the American Academy of Pediatrics, 345 Park Avenue, Itasca, Illinois, 60143. Copyright © 1987 by the American Academy of Pediatrics. All rights reserved. Print ISSN: 1073-0397.

American Academy of Pediatrics

DEDICATED TO THE HEALTH OF ALL CHILDREN®

