

# PERFORATION OF THE RECTUM OR COLON IN INFANCY DUE TO ENEMA

By Thomas V. Santulli, M.D.

*Department of Surgery, College of Physicians and Surgeons, Columbia University, and the Surgical Service of the Babies Hospital, New York*

**T**RAUMATIC perforation of the rectum or colon in adults has been reported after the introduction into the rectum of compressed air, foreign bodies, sigmoidoscopes, enema tips, cleansing enemas and diagnostic barium enemas.<sup>1-14</sup> Zheutlin and associates<sup>9</sup> in 1952 reported three cases of perforation of the colon after barium enema and reviewed 50 others which were compiled from a questionnaire sent to 100 teaching centers of radiology. They commented on the infrequency of the complication, the high mortality and the importance of immediate surgery.

In 1957, Hartman and Hills<sup>10</sup> reported two cases of perforation of the colon of infants after barium enema in the only paper that the author was able to find in reviewing the literature on traumatic perforation of the rectum or colon in infancy and childhood. This is somewhat surprising since the complication has been encountered nine times on the Surgical Service of the Babies Hospital in New York City in the past 13 years.

Because of the apparent rarity of this condition in the younger age group and its catastrophic effects, it seemed worthwhile to present this experience. The review has served to emphasize the inherent dangers of a common procedure which is regarded as simple and innocuous.

## CLINICAL AND PATHOLOGIC FEATURES

Immediately after perforation of the rectum or colon there was evidence of collapse, manifested by pale or dusky color, cold and clammy skin, restlessness or lethargy, tachypnea, tachycardia, and hypotension. The tachypnea often progressed to marked re-

spiratory embarrassment with grunting and cyanosis. Two of the patients showed rather marked abdominal distension. There was a sudden drop in temperature in all of the patients, sometimes to 34.5°C in the youngest. The sudden appearance of hypothermia was ominous.

Roentgenographic examination of the abdomen was diagnostic, the pneumoperitoneum being evident in the upright and lateral projections (Fig. 1). When a contrast agent was used it could be seen free in the peritoneal cavity (Figs. 2 and 3).

Table I presents the salient features of each case. The ages of the nine patients were 1 day to 1 year; six were less than 1 week old, and two of these were premature. Eight were males; one was female.

The rectum and colon were considered to have been normal in three cases; in six there were other pathologic findings: megacolon in three; meconium plug in one; meconium ileus in one and imperforate anus in one.

The cleansing enema was the cause, or inciting trauma, in four cases; one of these followed irrigation of a colostomy. In four others, the diagnostic enema (barium in two and Hypaque<sup>®</sup> sodium in two) was the inciting trauma and in one the perforation was produced by a catheter used to rupture a congenital anal membrane (Type II form of imperforate anus).

Five of the perforations occurred in the Babies Hospital; four of the patients were admitted after perforation had occurred at other hospitals.

Radiologists administered the barium (or Hypaque<sup>®</sup> sodium) in the four cases in which perforation followed diagnostic

Presented at the Annual Meeting of the American Academy of Pediatrics, October 19, 1958.  
ADDRESS: Babies Hospital, 3975 Broadway, New York 32, New York.

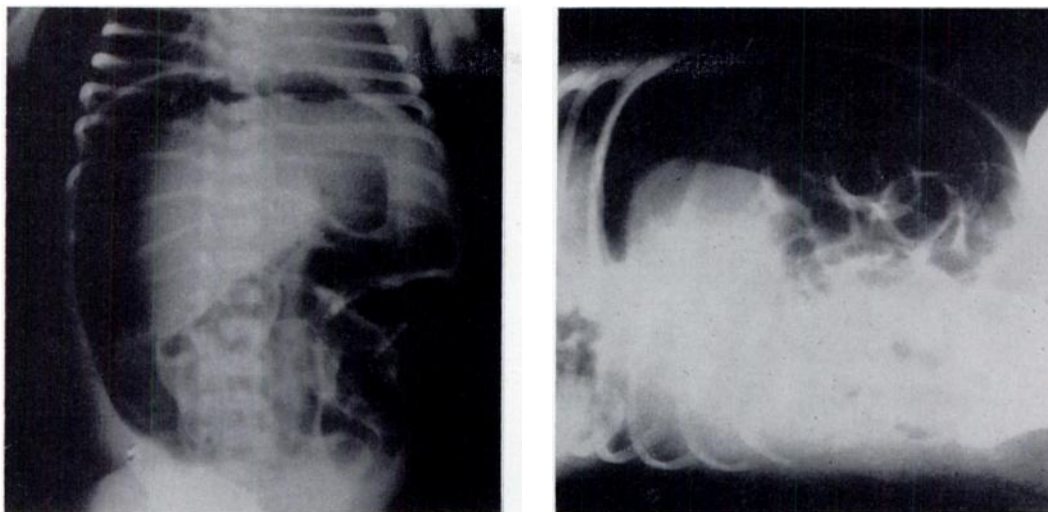


FIG. 1. A and B. Case 7. Upright and lateral projections showing pneumoperitoneum.

enema. Nurses gave the cleansing enemas which were implicated in two of the cases. Physicians were responsible for two of the perforations which followed cleansing enemas and one that occurred during rupture of an anal membrane with a catheter.

Most of the perforations were found at

the rectosigmoid level on the anterior (anti-mesenteric) aspect of the bowel. The usual finding was a tear of the serosa and muscularis starting at the rectosigmoid area, which extended proximally for several centimeters, and a smaller mucosal perforation in the center of this tear. In some cases

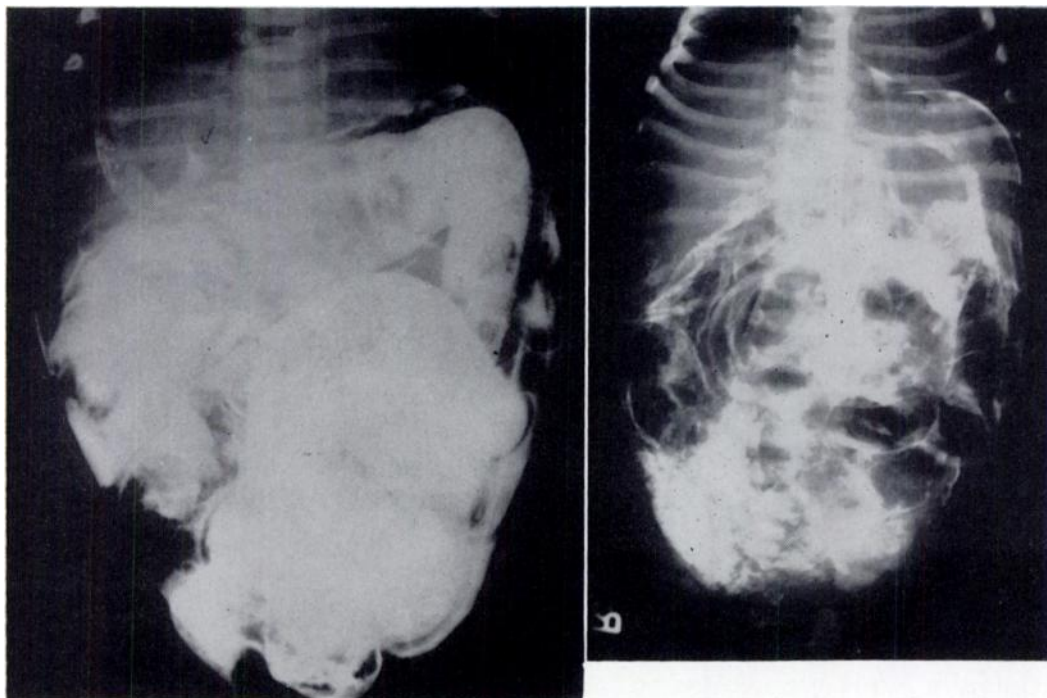


FIG. 2 (Left). Case 4. Barium enema. Note barium free in peritoneal cavity.

FIG. 3 (Right). Case 1. Perforation of rectosigmoid colon showing barium in peritoneal cavity.

TABLE I  
PERFORATIONS OF RECTUM OR COLON DUE TO ENEMAS

Case No.	Age	Year	Cause	Other Pathologic Findings in Colon	Location	Size of Perforation (cm)
1	5 days	1946	Barium enema	None	Mid-sigmoid, posterolateral	1.5
2	6 days	1951	Cleansing enema	Congenital megacolon	Rectosigmoid, anterior	0.7
3	4 weeks	1952	Irrigation of sigmoid colostomy	Congenital megacolon	Descending colon, anterior	0.5
4	7 weeks	1954	Barium enema	Congenital megacolon	Rectosigmoid, anterior	3.5
5	2 days	1955	Hypaque® sodium enema	None	Rectosigmoid, posterior	0.7
6	6 days	1956	Hypaque® sodium enema	Meconium ileus	Rectosigmoid, anterior	?
7	2 days	1956	Perforation of anal membrane by catheter + enema	Imperforate anus, type II	Rectosigmoid, anterior	5
8	1 year	1958	Cleansing enema	Five days after closure of colostomy (for type IV imperforate anus)	Descending colon (above colostomy closure)	0.3
9	3 days	1958	Cleansing enema	Meconium plug	Lower rectum	0.1

there was hemorrhage or collection of air in the subserosa surrounding the perforation. The size of the perforation was 0.1 to 5 cm.

#### PROGNOSIS AND TREATMENT

Mortality after perforation of the rectum or colon is high. Burt's review<sup>1</sup> of 48 cases of pneumatic perforation revealed a mortality of 80% in the nonoperative cases and 44% in those surgically treated. Andresen<sup>6</sup> reported a mortality of 47% in a review of 94 cases of perforation after proctoscopy. Pratt and Jackman<sup>3</sup> encountered a 40% mortality in 20 cases collected from the literature in which perforation was caused by enema tips. In 53 cases of perforation due to barium enema in adults,<sup>9</sup> the mortality was 51%. Most authors have stressed the importance of early surgical intervention and the increased mortality which followed delay in operation. Six of the nine patients at the Babies Hospital succumbed; three survived (Cases 1, 2, 8).

Infection introduced into the peritoneal cavity by contaminated stool is the lethal factor. The barium alone does not affect

mortality<sup>11</sup> but plays an important role in the formation of subsequent intraperitoneal adhesions.<sup>9</sup> It is of interest that barium will remain in the peritoneal cavity for years (Fig. 4), whereas some of the iodized contrast agents (Hypaque® sodium; Renografin®; Urokon® etc.) are quickly absorbed.

Treatment consists of immediate operation with closure of the perforation, if possible, and proximal colostomy. In Case 1 mere closure of the perforation resulted in recovery. This is not recommended; proximal colostomy should always be done. Drainage of the peritoneal cavity is usually not indicated. The importance of adequate preparation of the patient for operation, antibiotics, and proper supportive measures as oxygen, blood transfusions and appropriate fluid replacement, is evident.

#### DISCUSSION

Burt<sup>1</sup> showed that the average pressure required to rupture the bowel was 210 mm Hg and that intestinal segments of children supported higher pressures before rupturing. The intraluminal pressure exerted by the ordinary barium enema with the barium

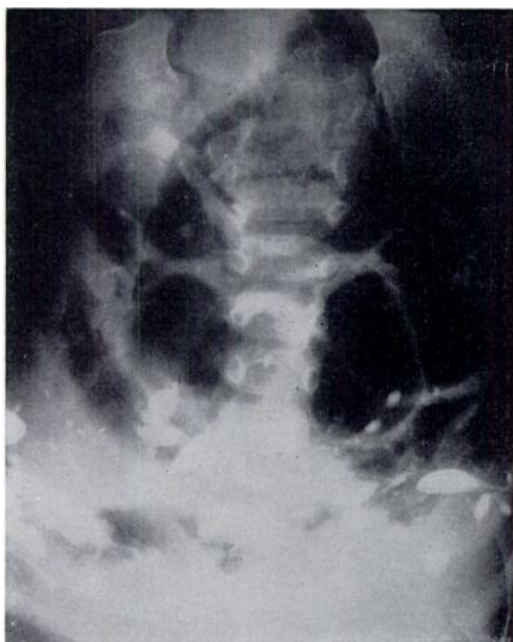


FIG. 4. Case 1. Two years after perforation of rectosigmoid colon by barium enema. Barium is still seen in peritoneal cavity.

can at a height of 3 feet (.9 m) is 76.6 mm Hg.<sup>11</sup> It seems unlikely, then, that intraluminal pressure alone is responsible for perforation of the normal bowel during barium enema or during the usual cleaning enema administered by gravity pressure. Emphasis has been properly placed on the danger of over-distention of the balloon of the rectal catheter at the rectosigmoid level where the intestine is relatively fixed by the peritoneal reflection.<sup>10</sup> This is probably the mechanism of rupture during the performance of a diagnostic barium enema. In other cases, actual perforation of the wall of the bowel by a catheter or enema tip must be regarded as the direct cause.

The relatively small size of the bowel and the short distance from anus to rectosigmoid area are important factors in the mechanism of perforation in infants, particularly when one considers that the procedure is often done in an unco-operative and struggling patient.

In reviewing the technic of administration of the enema or passage of the rectal tube in the cases of perforation reported here,

several factors were disclosed. In some patients the catheter or its attached balloon was too large or the tube was introduced too far into the rectum. In other cases, persistence in trying to fill the entire colon when it was unnecessary in relation to the information sought, and the inability to satisfactorily control movements of the patient (and catheter) during fluoroscopic visualization in the dark room were important contributing factors to the accident.

It seems clear from the cases presented and from those reported in the literature that perforation is a threat which must be recognized if we are to continue to pass rectal tubes and if the barium enema is to assume the more important diagnostic role it deserves in neonatal intestinal obstruction. It behooves us, therefore, to be aware of the dangers inherent in this simple procedure and to observe the necessary precautions in order to avoid this complication.

#### SUMMARY

Nine cases of perforation of the rectum or colon in infancy due to enema are presented and the scant literature is reviewed.

Although rare, perforation is a catastrophic complication of a simple procedure which carries a high mortality.

The mechanism of perforation and the factors contributing to the complication are discussed.

#### REFERENCES

1. Burt, C. A. V.: Pneumatic rupture of the intestinal canal. *Arch. Surg.*, **22**:875, 1931.
2. Hamit, H. F.: Perforation of the colon after barium enema and air contrast studies. *Am. Surgeon*, **21**:1226, 1955.
3. Pratt, J. H., and Jackman, R. J.: Perforation of the rectal wall by enema tip. *Proc. Staff Meet., Mayo Clin.*, **20**:277, 1945.
4. Ault, G. W.: Perforation of the rectum with enema tips. *Tr. Am. Proct. Soc.*, **40**:203, 1939.
5. Davis, C., Jr.: Enema tube perforation of the colon. *Ann. Surg.*, **126**:377, 1947.
6. Andresen, A. F. R.: Perforations from proctoscopy. *Gastroenterology*, **9**:32, 1947.



7. Kaufman, P. A., and Swerdlow, H.: Bowel perforation following enema through a permanent colostomy. *Arch. Surg.*, **67**: 612, 1953.
8. Greene, E. I., and Greene, J. M.: Traumatic perforation of the colon in a patient with a colostomy. *J.A.M.A.*, **148**: 49, 1952.
9. Zheutlin, N., Lasser, E. C., and Rigler, L. G.: Clinical studies on effect of barium in the peritoneal cavity following rupture of the colon. *Surgery*, **32**: 967, 1952.
10. Hartman, A. W., and Hills, W. J.: Rupture of the colon in infants during barium enema: report of two cases. *Ann. Surg.*, **145**:712, 1957.
11. Kleinsasser, L. J., and Warshaw, H.: Perforation of sigmoid colon during barium enema. *Ann. Surg.*, **135**:560, 1952.
12. Grant, R. B., and Murray, S. D.: Perforation of the sigmoid colon following enema. *Surgery*, **24**:867, 1948.
13. Weaver, F. M., and Holland, R. H.: Perforation of the colon. *Surgery*, **25**:613, 1949.
14. Grillo, H. C., and Nardi, G. L.: Perforation of the colon during enema into the colonic stoma. *Surg. Gynec. & Obst.*, **107**: 659, 1958.

**X-RAY DIAGNOSIS OF THE ALIMENTARY TRACT IN INFANTS AND CHILDREN**, Edward B. Singleton, M.D. Chicago, The Year Book Publishers, 1959, \$11.00.

This new monograph describes and explains the radiographic findings in the healthy and the abnormal alimentary tracts of infants and children. The author's emphasis on the important normal variants should be helpful, especially to medical students and radiologists in training. The first chapter deals with the indications for radiologic examinations, which should alert the examiner to the most probable lesions present and also suggest to him the optimal type of examination. The second chapter details the techniques of examination of the upper gastrointestinal tract (esophagus, stomach, jejunum and ileum); this short chapter is one of the most valuable in the book because it will not only facilitate examinations, but also prevent undue radiation exposure of both the patient and the examiner, if the author's methods are followed. The value of image intensification in the reduction of radiation hazards is mentioned but not sufficiently emphasized in my opinion. The technique of colonic examination is given in a later chapter.

The remainder of the book—302 pages exclusive of preface, table of contents and index—is devoted to thorough discussion and illustrations of the clinical features, morbid anatomy, radiographic findings and diagnostic probabilities in all of the important diseases and lesions

of the alimentary tract. The section on the esophagus comprises 70 pages with exceptionally clear and comprehensive presentations of the lesions at the gastro-esophageal junction and of congenital duplications of the foregut. The final chapter of 10 pages is concerned with the various types of diaphragmatic hernia and diaphragmatic eventration. Adequate reference lists are placed conveniently throughout the book at the end of each chapter.

The text is amply illustrated with 215 figures—radiographs, photographs and line drawings—which are conveniently placed near to the subject matter; and all are well chosen and carefully cropped so that the prints clearly illustrate the lesion under consideration. With a few exceptions the legends are comprehensive and add much in amplification and clarification of the text.

This is an unusually valuable book, cleanly printed and clearly illustrated. Dr. Singleton is to be congratulated for his well-balanced authoritative discussion of an important segment of pediatric radiology; and the Year Book Publishers for another fine technical job in publication of radiologic literature. One has to search hard to find any defect; it seems to me that the weak single cloth binding in a faded bluish gray color is not up to the rest of the book. Any reader who is interested in pediatric radiology will be amply rewarded in the careful perusal and use of *X-ray Diagnosis of the Alimentary Tract in Infants and Children*.

JOHN CAFFEY, M.D.

## PERFORATION OF THE RECTUM OR COLON IN INFANCY DUE TO ENEMA

Thomas V. Santulli  
*Pediatrics* 1959;23:972

### Updated Information & Services

including high resolution figures, can be found at:  
<http://pediatrics.aappublications.org/content/23/5/972>

### Permissions & Licensing

Information about reproducing this article in parts (figures, tables) or in its entirety can be found online at:  
<http://www.aappublications.org/site/misc/Permissions.xhtml>

### Reprints

Information about ordering reprints can be found online:  
<http://www.aappublications.org/site/misc/reprints.xhtml>

American Academy of Pediatrics

DEDICATED TO THE HEALTH OF ALL CHILDREN™



# PEDIATRICS®

OFFICIAL JOURNAL OF THE AMERICAN ACADEMY OF PEDIATRICS

## PERFORATION OF THE RECTUM OR COLON IN INFANCY DUE TO ENEMA

Thomas V. Santulli

*Pediatrics* 1959;23:972

The online version of this article, along with updated information and services, is located on the World Wide Web at:

<http://pediatrics.aappublications.org/content/23/5/972>

Pediatrics is the official journal of the American Academy of Pediatrics. A monthly publication, it has been published continuously since 1948. Pediatrics is owned, published, and trademarked by the American Academy of Pediatrics, 141 Northwest Point Boulevard, Elk Grove Village, Illinois, 60007. Copyright © 1959 by the American Academy of Pediatrics. All rights reserved. Print ISSN: 1073-0397.

American Academy of Pediatrics

DEDICATED TO THE HEALTH OF ALL CHILDREN™

