

Early Neonatal SARS-CoV-2 Infection Manifesting With Hypoxemia Requiring Respiratory Support

Mariateresa Sinelli, MD, Giuseppe Paterlini, MD, Marco Citterio, MD, Alessia Di Marco, MD, Tiziana Fedeli, MD, Maria Luisa Ventura, MD

We describe a case of neonatal SARS-CoV-2 infection, in an infant diagnosed 3 days after birth, and manifesting with silent hypoxemia, requiring respiratory support.

abstract

In December 2019, an emergent new coronavirus was detected in Wuhan, China, as the cause of severe pneumonia.¹ The virus, named severe acute respiratory syndrome coronavirus 2 (SARS-CoV-2), causes a disease named coronavirus disease (COVID-19) and has become a pandemic.² At the end of February, a cluster of cases was identified in Northern Italy. Since then, SARS-CoV-2 has been responsible for more than 80 000 infections among Italian adults, with ~10 neonatal cases detected. The disease seems to be mild in children and, to date, there are few reports in neonatal population. It is still not clear if there is vertical transmission of virus from mother to newborn and there is not a consensus on the appropriate infection control precautions to be used in the care of the newborn. We report a case of COVID-19 infection in a term newborn who required respiratory support after a vaginal delivery.

CASE REPORT

The infant was born at term after an uneventful pregnancy. On admission,

the mother was asymptomatic and afebrile. An uncomplicated vaginal delivery ensued resulting in an appropriate-for-gestational-age male infant. Delayed cord clamping and skin-to-skin contact were performed, as part of the routine care. Apgar scores were assigned as 9 and 10 at 1 and 5 minutes, respectively. On the second day after delivery, the mother became febrile with no respiratory symptoms. Her nasopharyngeal swab was positive for SARS-CoV-2 (qualitative polymerase chain reaction [PCR]), whereas other causes of fever were ruled out. A nasopharyngeal swab obtained that same day on the infant was also positive for SARS-CoV-2. On examination, the infant's clinical condition was good, and he demonstrated no signs of lung or organ system disease. The infant and the mother were not separated, and they were both transferred to an airborne-isolation zone to continue the follow-up. However, 48 hours after isolation, the newborn developed perioral cyanosis and poor sucking without signs of respiratory distress. Oxygen saturation on room air was 88%, respiratory rate was 15 to 20 per

Neonatal Intensive Care Unit, Fondazione Monza e Brianza per il Bambino e la sua Mamma and Azienda Socio Sanitaria Territoriale-Monza, Monza, Italy

Dr Sinelli conceptualized and designed the study, drafted the initial manuscript, and reviewed and revised the manuscript; Drs Paterlini, Citterio, Di Marco, and Fedeli collected data, conducted the analysis, and reviewed and revised the manuscript; Dr Ventura designed the data collection instruments, coordinated and supervised data collection, and critically reviewed the manuscript; and all authors approved the final manuscript as submitted and agree to be accountable for all aspects of the work.

DOI: <https://doi.org/10.1542/peds.2020-1121>

Accepted for publication Apr 29, 2020

Address correspondence to Mariateresa Sinelli, MD, Neonatal Intensive Care Unit, Fondazione MBBM-ASST-Monza, via Pergolesi 33, 20900, Monza, Italy. E-mail: mtsinnelli@gmail.com

PEDIATRICS (ISSN Numbers: Print, 0031-4005; Online, 1098-4275).

Copyright © 2020 by the American Academy of Pediatrics

FINANCIAL DISCLOSURE: The authors have indicated they have no financial relationships relevant to this article to disclose.

FUNDING: No external funding.

To cite: Sinelli M, Paterlini G, Citterio M, et al. Early Neonatal SARS-CoV-2 Infection Manifesting With Hypoxemia Requiring Respiratory Support. *Pediatrics*. 2020;146(1):e20201121

minute, heart rate was 120 beats per minute, and blood pressure was normal range. Arterial blood gas analysis demonstrated moderate hypoxia (Table 1). A complete blood count and differential and C-reactive protein were normal. An echocardiogram excluded any cardiac abnormalities. Empirical treatment with ampicillin and gentamicin was initiated but discontinued when blood and urine culture were sterile. Qualitative PCR on the nasopharyngeal swab specimen was negative for other respiratory virus (influenza A and B, parainfluenza, respiratory syncytial virus, adenovirus, metapneumovirus, rhinovirus, enterovirus, bocavirus, and minor type of coronavirus). The infant was admitted to the NICU and placed on 30% inspired oxygen via high-flow nasal cannula. Chest radiograph showed mild bilateral ground-glass opacities, and lung ultrasound did not reveal consistent abnormalities (Fig 1). After 36 hours, a chest computed tomography scan did not reveal major abnormalities. The infant's condition improved, and respiratory support was discontinued 50 hours after admission to the NICU. The infant was fed maternal expressed milk by nasogastric tube for 48 hours, after which he was able to be fully bottle-fed. The infant was discharged in good condition on day 18 of life. On days 15 and 21 of life, his qualitative PCR for COVID-19 remained positive.

DISCUSSION

In this report, we detail a case of neonatal SARS-CoV-2 infection that presented on day 5 of life with clinically significant hypoxemia without overt signs of respiratory distress that required oxygen therapy (Fig 2). Although

TABLE 1 Infant's Blood Test

Time	DOL 5 h 12	DOL 5 h 18	DOL 6 h 2
pH	7.49	7.40	7.45
Paco ₂ mm Hg	31	39.5	29.1
PaO ₂ mm Hg	48	48.2	93.9
HCO ₃ ⁻ mmol/L	23	24	19.6
BE	1.1	-0.5	-2.6
CRP mg/dL	0.1	—	0.06
WBC per mm ³	6.800	—	—
Hemoglobin g/L	17.2	—	—
Platelets per mm ³	456.000	—	—
Neutrophil count %	28	—	—
Lymphocyte count %	56	—	—

BE, base excess; CRP, C-reactive protein; DOL, day of life; WBC, white blood cell; —, not applicable.

clinical manifestations of COVID-19 among pediatric patients are generally less severe than those of adults,³ the proportion of severe and critical cases reported in children is inversely correlated with their age, with more severe cases in infants <1 year old.⁴ Nonetheless, early Chinese case series of newborns were reassuring, with researchers reporting either asymptomatic courses with only radiologic finding of disease⁵ or rarely symptomatic and uncomplicated diseases.⁶

Our case demonstrates, however, that significant hypoxemia can

occur in newborns with early SARS-CoV-2 infection. In these cases, diagnosis can be challenging because clinical manifestation of respiratory failure, such as polypnea or respiratory distress, may be absent.

Despite the large number of people with confirmed COVID-19 infection, few cases have occurred in newborn infants. Data are not sufficient at this time to allow a clear evidence-based recommendation for optimal infection control measures in newborns of mothers with COVID-19 infection. Our case report suggests that a newborn infected with SARS-CoV-2 may not demonstrate signs of respiratory distress but may have significant hypoxia that requires treatment. Pulse oximetry monitoring may be advisable before the discharge of healthy-appearing infants with positive testing result for SARS-CoV-2. In addition, parents should be trained to recognize signs of possible hypoxemia, such as poor sucking or changes in the infant's skin color.

In our patient, nasopharyngeal swab remained positive for more than 2 weeks, unlike previous reports showing rapid virological clearance.⁶ Together with previous reports of frequent asymptomatic infections, our finding suggests that newborns could be a source of horizontal

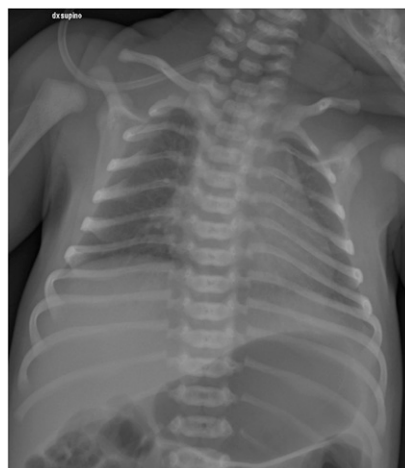

FIGURE 1 Chest radiograph of the newborn obtained on day of life 3 showing mild bilateral ground-glass opacities.

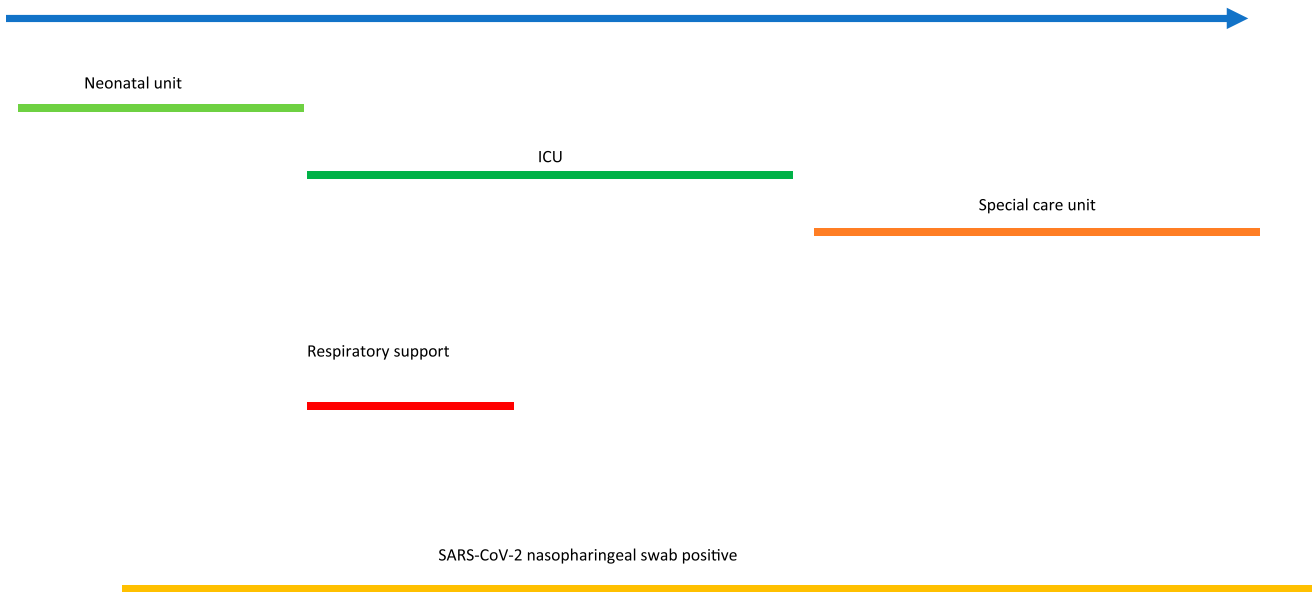


FIGURE 2
Timeline of our case report from birth to discharge. DOL, day of life.

transmission of the infection and should managed accordingly.

CONCLUSIONS

It is important to remember that in the case of neonatal SARS-CoV-2 infection, especially if it occurs in an early period of life, the disease might

have insidious onset. Based on our report, we suggest strictly monitoring infants born from infected mothers in the first week of life.

ACKNOWLEDGMENTS

Thank you to Dr Giuseppe Lapadula for his review of the article.

ABBREVIATIONS

- COVID-19: coronavirus disease
- PCR: polymerase chain reaction
- SARS-CoV-2: severe acute respiratory syndrome coronavirus 2

POTENTIAL CONFLICT OF INTEREST: The authors have indicated they have no potential conflicts of interest to disclose.

REFERENCES

1. The Novel Coronavirus Pneumonia Emergency Response Epidemiology Team. The epidemiological characteristics of an outbreak of 2019 novel coronavirus diseases (COVID-19) – China, 2020. *China CDC Weekly*. 2020; 2(8):113–122
2. World Health Organization. WHO Director-General’s statement on IHR Emergency Committee on Novel Coronavirus (2019-nCoV). January 30, 2020. Available at: [https://www.who.int/dg/speeches/detail/who-director-general-s-statement-on-ihf-emergency-committee-on-novel-coronavirus-\(2019-ncov\)](https://www.who.int/dg/speeches/detail/who-director-general-s-statement-on-ihf-emergency-committee-on-novel-coronavirus-(2019-ncov)). Accessed March 3, 2020
3. Ludvigsson J. Systematic review of COVID-19 in children shows milder cases and a better prognosis than adults. *Acta Paediatr*. 2020;109(6): 1088–1095
4. Dong Y, Mo X, Hu Y, et al. Epidemiological characteristics of 2143 pediatric patients with 2019 coronavirus disease in China. *Pediatrics*. 2020;145(6): e20200702
5. Wang S, Guo L, Chen L, et al. A case report of neonatal 2019 coronavirus disease in China [published online ahead of print March 12, 2020]. *Clin Infect Dis*. 2020. doi:10.1093/cid/ciaa225
6. Zeng L, Xia S, Yuan W, et al. Neonatal E-Onset infection with SARS-CoV-2 in 33 neonates born to mothers with COVID-19 in Wuhan, China [published online ahead of print March 26, 2020]. *JAMA Pediatr*. doi: 10.1001/jamapediatrics.2020.0878

Early Neonatal SARS-CoV-2 Infection Manifesting With Hypoxemia Requiring Respiratory Support

Mariateresa Sinelli, Giuseppe Paterlini, Marco Citterio, Alessia Di Marco, Tiziana Fedeli and Maria Luisa Ventura

Pediatrics 2020;146;

DOI: 10.1542/peds.2020-1121 originally published online May 4, 2020;

Updated Information & Services	including high resolution figures, can be found at: http://pediatrics.aappublications.org/content/146/1/e20201121
References	This article cites 4 articles, 1 of which you can access for free at: http://pediatrics.aappublications.org/content/146/1/e20201121#BIBL
Subspecialty Collections	This article, along with others on similar topics, appears in the following collection(s): Fetus/Newborn Infant http://www.aappublications.org/cgi/collection/fetus:newborn_infant_sub Neonatology http://www.aappublications.org/cgi/collection/neonatology_sub Infectious Disease http://www.aappublications.org/cgi/collection/infectious_diseases_sub Epidemiology http://www.aappublications.org/cgi/collection/epidemiology_sub
Permissions & Licensing	Information about reproducing this article in parts (figures, tables) or in its entirety can be found online at: http://www.aappublications.org/site/misc/Permissions.xhtml
Reprints	Information about ordering reprints can be found online: http://www.aappublications.org/site/misc/reprints.xhtml

American Academy of Pediatrics

DEDICATED TO THE HEALTH OF ALL CHILDREN®



PEDIATRICS®

OFFICIAL JOURNAL OF THE AMERICAN ACADEMY OF PEDIATRICS

Early Neonatal SARS-CoV-2 Infection Manifesting With Hypoxemia Requiring Respiratory Support

Mariateresa Sinelli, Giuseppe Paterlini, Marco Citterio, Alessia Di Marco, Tiziana Fedeli and Maria Luisa Ventura

Pediatrics 2020;146;

DOI: 10.1542/peds.2020-1121 originally published online May 4, 2020;

The online version of this article, along with updated information and services, is located on the World Wide Web at:

<http://pediatrics.aappublications.org/content/146/1/e20201121>

Pediatrics is the official journal of the American Academy of Pediatrics. A monthly publication, it has been published continuously since 1948. Pediatrics is owned, published, and trademarked by the American Academy of Pediatrics, 345 Park Avenue, Itasca, Illinois, 60143. Copyright © 2020 by the American Academy of Pediatrics. All rights reserved. Print ISSN: 1073-0397.

American Academy of Pediatrics

DEDICATED TO THE HEALTH OF ALL CHILDREN®

