

Rectal Levothyroxine for the Treatment of Hypothyroidism: A Case Study

Marina Ybarra, MD, MSc, Tiago Jeronimo dos Santos, MD, MPH, Claudia Teixeira Cabido Pinheiro, MD, Vaê Dichtchekekenian, MD, MSc, PhD, Durval Damiani, MD, MSc, PhD

Transient hypothyroidism can present itself as clinically asymptomatic or with few symptoms. Early treatment with levothyroxine (L-T4) prevents complications related to this disorder. We report a case of a male infant with concomitant short bowel syndrome and transient hypothyroidism treated with rectal L-T4. A 4-month-and-10-day-old boy with previous gastroschisis underwent multiple surgical approaches for small bowel resection and developed short bowel syndrome. We suspected hypothyroidism because of jaundice (direct bilirubin up to 59 mg/dL), the absence of evacuation, oral diet intolerance, and intestinal dysmotility. Because of a thyrotropin level of 34.45 μ IU/mL and a free thyroxine level of 0.64 ng/dL, the diagnosis was confirmed. Because fasting was demanding, we started the patient on rectal diluted L-T4. After 4 weeks, the patient had spontaneous peristalsis, improvement of jaundice (direct bilirubin: 4.6 mg/dL), and normalized free thyroxine and thyrotropin values. In the present case, the patient was diagnosed with hypothyroidism and was on absolute fasting. An alternative route of drug administration was warranted. We empirically prescribed rectal diluted L-T4 when intravenous and suppository L-T4 were not available. This method was proven to be safe and effective in improving the patient's clinical and biochemical status. Rectal L-T4 is a possible alternative route of administration to treat hypothyroidism in patients who are unable to take the medication orally.

Primary congenital hypothyroidism (CH) is one of the most common preventable causes of intellectual disability. It can be classified in 2 types: permanent and transient.¹ Authors of previous studies state that 10% to 40% of newborns with primary CH present with transient thyroid dysfunction.²⁻⁶ The prevalence goes up to 65% if we consider patients with a eutopic gland.⁷ Premature (<37 weeks' gestation) infants and those with very low birth weight (BW) (<1500 g) are especially at risk for hypothyroidism because of iodine deficiency.^{8,9} Early diagnosis and treatment are needed to avoid complications.

The complete mechanism of primary transient hypothyroidism

remains unknown.^{10,11} It may be caused by several underlying conditions, such as insufficient or excessive iodine intake, maternal thyrotropin receptor–blocking antibodies, maternal antithyroid drugs, and genetic defects such as dual oxidase 2 and thyrotropin-receptor mutations.^{9,12} Neonatal hyperthyrotropinemia can also play a role, including delayed maturation of the hypothalamic-pituitary axis, increased thyrotropin response to thyroid-releasing hormones, and the presence of either antithyroid antibodies, thyroid morphology abnormalities, or thyroperoxidase or thyrotropin-receptor gene-sequence variations.¹²⁻¹⁴ Oren et al¹⁵ described

abstract

Pediatric Endocrinology Unit, Children's Institute, University of São Paulo, São Paulo, Brazil

Drs Ybarra and Pinheiro conceptualized and designed the study, collected data, and drafted, reviewed, and revised the manuscript; Dr dos Santos contributed to the analysis and interpretation of the data and revised it critically for important intellectual content; Drs Dichtchekekenian and Damiani made substantial contributions to the conception and design of this manuscript and critically reviewed the manuscript for important intellectual content; and all authors approved the final manuscript as submitted and agree to be accountable for all aspects of the work.

Dr Ybarra's current affiliation is the Research Center of the Sainte-Justine University Hospital, Montreal, Canada.

DOI: <https://doi.org/10.1542/peds.2017-3317>

Accepted for publication Apr 11, 2018

Address correspondence to Marina Ybarra, MD, MSc, Children's Institute - 647, Dr. Enéas de Carvalho Aguiar Avenue - São Paulo, SP, 05403-000, Brasil. E-mail: marinaybarra@gmail.com

PEDIATRICS (ISSN Numbers: Print, 0031-4005; Online, 1098-4275).

Copyright © 2018 by the American Academy of Pediatrics

FINANCIAL DISCLOSURE: The authors have indicated they have no financial relationships relevant to this article to disclose.

FUNDING: No external funding.

POTENTIAL CONFLICT OF INTEREST: The authors have indicated they have no potential conflicts of interest to disclose.

To cite: Ybarra M, dos Santos TJ, Pinheiro CTC, et al. Rectal Levothyroxine for the Treatment of Hypothyroidism: A Case Study. *Pediatrics*. 2018; 142(2):e20173317

an incidence rate of 23% of neonatal mild hyperthyrotrophinemia (the thyrotrophin ranged 5–30 mU/L), most of which tended to be transient. The authors of guidelines recommend that children with unexplained CH and with the gland in situ be reevaluated after 3 years of age through a trial of treatment withdrawal.^{16,17}

Contraindication for oral drug intake or an absolute fasting state is a challenge that makes an alternative route of administration necessary. We report a case of a patient in an absolute fasting state who had transient hypothyroidism treated with rectally administered levothyroxine (L-T4).

PATIENT

A 4-month-and-10-day-old boy was surveilled for a prenatal diagnosis of gastroschisis. His gestational age was 30 + 2/7 weeks, whereas his BW and length were respectively 2100 g (z score: -2.95 SD) and 42.5 cm (z score: -3.9 SD), appropriate for gestational age. Apgar scores were 2 and 7 at 1 and 5 minutes, respectively.

At birth, he had a right-sided gastroschisis, classified as small, which was surgically treated on the first day of life by correction of the abdominal wall defect and resection of necrotic small bowel segments. He developed intolerance to enteral feeding, which led to a fasting regimen and the need of total parenteral nutrition (TPN) that was started on the second day of life. He remained on an orogastric tube, which continuously drained content with fecal appearance. At 42 days, he had an intestinal obstruction requiring another surgery in which adhesions were removed and stenotic segments were fixed. No iodine antiseptic solution was used during any of the procedures.

Cholestatic jaundice with a direct bilirubin level up to 59.4 mg/dL (normal level <0.2 mg/dL) occurred beginning on the 12th day of life, attributed, at that time, to the association of infection and the use of TPN. He also developed septic shock in the second month of life, which was treated with antibiotics and dopamine, and anemia, which was treated with blood transfusions on the 14th, 19th, and 58th days of life.

The persistence of intestinal dysmotility, constipation, intolerance to enteral feeding, and abdominal distention (Fig 1) motivated the study of hypothyroidism despite a normal dried blood spot newborn screening test (NBS) on postnatal day 27 (thyrotrophin = 0.7 μ IU/mL; normal level <15.0 μ IU/mL).

Serum laboratory measurements performed at 4 months of age revealed primary hypothyroidism (thyrotrophin = 10.56 μ IU/mL; normal range: 0.27–4.2 μ IU/mL; free thyroxine [fT4] = 0.73 ng/dL; normal range: 0.93–1.7 ng/dL). Five days later, thyrotrophin was 34.45 μ IU/mL and fT4 was 0.64 ng/dL (found by using the electrochemiluminescent immunoassay technique). At this time, the direct bilirubin level was 9.8 mg/dL.

The pediatric endocrinology team was called after the second measurement of thyrotrophin and indicated hormone replacement with L-T4, although the patient continued fasting with an orogastric tube. Because of the contraindication to oral drug intake and the unavailability of intravenous medication, we decided to administer the medication rectally with an initial lower dose of 12.5 μ g per day (5 μ g/kg per day). The L-T4 tablet was diluted in 3 mL of saline and administered in bolus, in the morning, with a size 8 rectal probe, which was flushed with 5 mL of water.

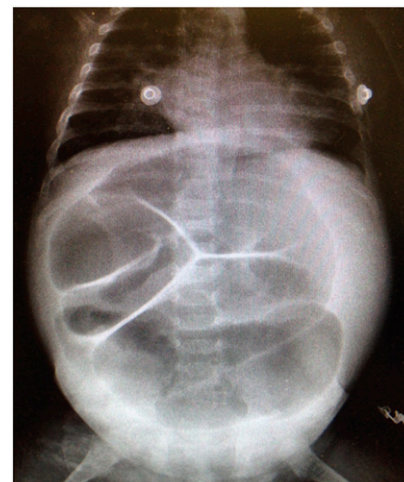

FIGURE 1

Plain radiograph of abdomen revealing several dilated intestinal segments.

After a week of treatment, the thyrotrophin level was 22.81 μ IU/mL. Hence, because the authors of current recommendations^{17,18} suggest an initial dosage of 10 to 15 μ g/kg of L-T4 for that age group, we increased the L-T4 to 25 μ g per day (10 μ g/kg per day). In 7 days, thyroid function normalized (thyrotrophin = 2.85 μ IU/mL and fT4 = 1.28 ng/dL).

Etiologic study of hypothyroidism with ultrasonography revealed a eutopic thyroid with typical morphology, dimensions, and contours. The test results for thyroperoxidase and thyroglobulin antibodies were negative. Urine iodine level was not measured. In the meanwhile, the patient was also surveilled for intestinal rehabilitation, manifesting good recovery. Parents were counseled regarding the possible causes of hypothyroidism, the importance of compliance, and the excellent prognosis when therapy is followed.

A month later, the patient showed spontaneous bowel movements, jaundice improvement (direct bilirubin = 4.62 mg/dL), and normal thyroid function tests (thyrotrophin = 0.75 μ IU/L; fT4 = 1.34 ng/dL). We were able to start L-T4 orally because of the clinical improvement. One year

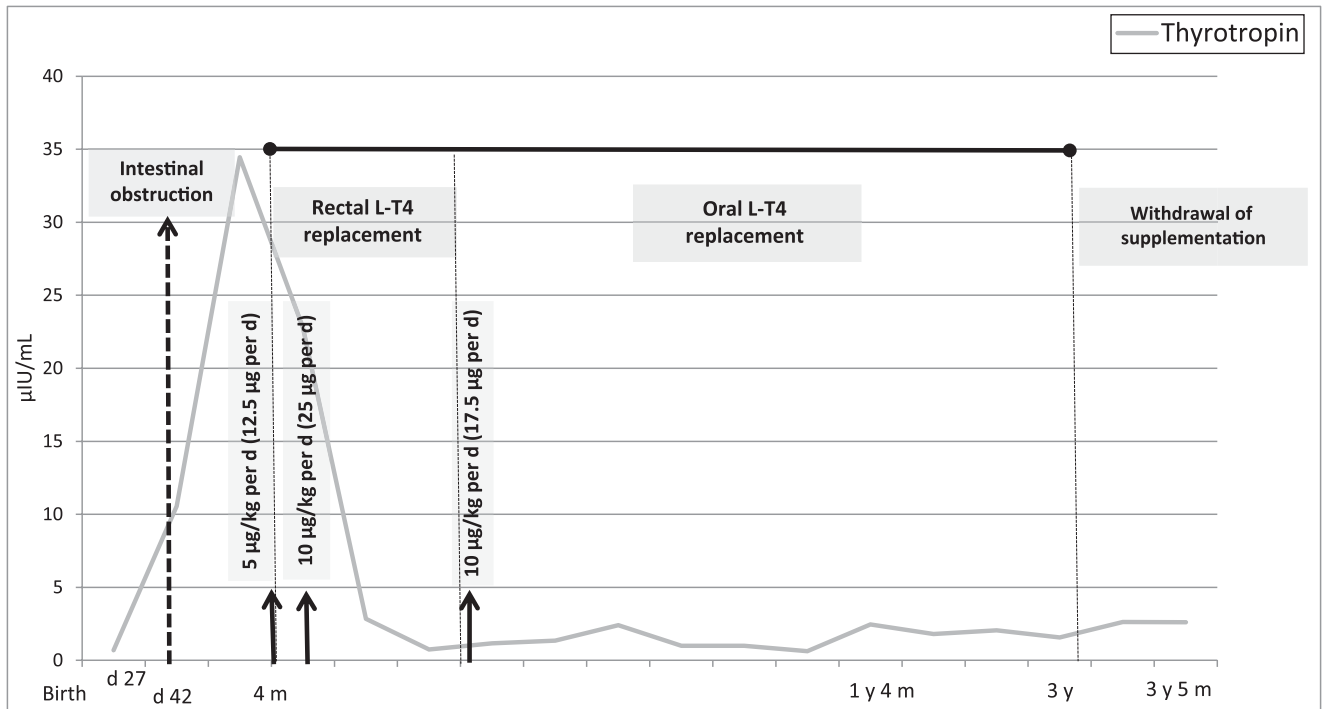


FIGURE 2

Overview of clinical, biochemical, and treatment parameters in an infant with transient hypothyroidism. BW was 2100 g (z score: -2.95); birth length was 42.5 cm (z score: -3.9). Current weight is 13300 g (z score: -1.01); current length is 93 cm (z score: -1.08).

after taking L-T4 at 17.5 µg per day (at 1.5 years of age), his thyrotropin = 2.46 µIU/mL and fT4 = 1.54 ng/dL were suitable for age, and he stepped with normal development milestones.

At the age of 3 years, we withdrew the medication and thyrotropin was 1.57 µIU/mL, which was proven to be a case of transient hypothyroidism. At that time, his weight and height were 13300 g (z score: -1.01 SD) and 93 cm (z score: -1.08 SD), respectively. After 1 year of follow-up, the patient remains with normal thyroid function without medication (Fig 2).

DISCUSSION

We report a patient with transient hypothyroidism in whom anatomical problems within the gastrointestinal tract precluded oral administration of L-T4.

He had a normal thyrotropin level on the NBS, but, at that time,

many confounding issues were presented, such as prematurity, gastrointestinal defects, sepsis, and blood transfusion.¹⁹ Prematurity could account for the possibility of transient hypothyroxinemia of prematurity, which is defined as low levels of total thyroxine and triiodothyronine with normal levels of thyrotropin. Sepsis could also have caused the euthyroid sick syndrome when the level of thyrotropin decreased into normal range.²⁰ Ford et al²¹ demonstrated that patients diagnosed with hypothyroidism in a second-routine NBS were significantly more likely to have a transient form of CH compared with those on the first screen (77% vs 17%, odds ratio 16.3, $P < .001$). Moreover, Oren et al¹⁵ demonstrated that neonatal mild hyperthyreotropinemia are more likely to be transient.

During the neonatal period, the earliest clinical sign of hypothyroidism is prolonged jaundice, by direct or indirect

hyperbilirubinemia, as observed in our patient.^{22,23} However, in our case, TPN, sepsis, and prematurity could have explained the high levels of bilirubin, which probably delayed the diagnosis of hypothyroidism.

Once hypothyroidism was detected, we considered it to be acquired or transient rather than congenital because the thyrotropin elevation was lower than expected for CH and the NBS was normal. Also, transient hypothyroidism tends to respond to a lower dosage of L-T4 than CH.^{7,15,24,25}

Kashiwagura et al²⁶ successfully administered a suppository preparation of L-T4 in patients with hypothyroidism who could not take thyroid hormones by mouth. Because our patient was incapable of receiving oral administration of L-T4 and because intravenous and suppository preparations of L-T4 were not available at our hospital, we decided to empirically administer a rectal diluted solution of L-T4. The absence of previous

data concerning rectal absorption of this solution led us to carefully start a low dose and escalate it until euthyroidism was achieved. Using this inexpensive and simple method, we normalized thyrotropin and fT4 levels and ensured improvement in the patient's symptoms, allowing oral intake within a few days.

We believe that the administration of L-T4 triggered a better clinical response, leading to his general improvement. Other factors may have contributed to his progression, such as sepsis resolution, oral ingestion, and inherent child maturation.

At the age of 3 years, we reassessed his thyroid status and successfully withdrew the medication (thyrotropin = 1.57 µIU/mL).

ACKNOWLEDGMENTS

We thank Mariza Kazue for her availability and efficiency in bibliographic research, Luiz Fernando Ybarra for reviewing this article numerous times, and Prince Kevin Danieles and Nora Young for proofreading the article.

ABBREVIATIONS

BW: birth weight
 CH: congenital hypothyroidism
 fT4: free thyroxine
 L-T4: levothyroxine
 NBS: newborn screening test
 TPN: total parenteral nutrition

REFERENCES

- Harris KB, Pass KA. Increase in congenital hypothyroidism in New York State and in the United States [published correction appears in *Mol Genet Metab*. 2008;94(1):140]. *Mol Genet Metab*. 2007;91(3):268–277
- Razavi Z, Mohammadi L. Permanent and transient congenital hypothyroidism in Hamadan West Province of Iran. *Int J Endocrinol Metab*. 2016;14(4):e38256
- Gaudino R, Garel C, Czernichow P, Léger J. Proportion of various types of thyroid disorders among newborns with congenital hypothyroidism and normally located gland: a regional cohort study. *Clin Endocrinol (Oxf)*. 2005;62(4):444–448
- Korzeniewski SJ, Grigorescu V, Kleyn M, et al. Transient hypothyroidism at 3-year follow-up among cases of congenital hypothyroidism detected by newborn screening. *J Pediatr*. 2013;162(1):177–182
- Dorreh F, Chaijan PY, Javaheri J, Zeinalzadeh AH. Epidemiology of congenital hypothyroidism in Markazi Province, Iran. *J Clin Res Pediatr Endocrinol*. 2014;6(2):105–110
- Hashemipour M, Hovsepian S, Kelishadi R, et al. Permanent and transient congenital hypothyroidism in Isfahan-Iran. *J Med Screen*. 2009;16(1):11–16
- Park IS, Yoon JS, So CH, Lee HS, Hwang JS. Predictors of transient congenital hypothyroidism in children with eutopic thyroid gland. *Ann Pediatr Endocrinol Metab*. 2017;22(2):115–118
- Bekhit OE, Yousef RM. Permanent and transient congenital hypothyroidism in Fayoum, Egypt: a descriptive retrospective study. *PLoS One*. 2013;8(6):e68048
- Bhavani N. Transient congenital hypothyroidism. *Indian J Endocrinol Metab*. 2011;15(suppl 2):S117–S120
- Rabbiosi S, Vigone MC, Cortinovis F, et al. Congenital hypothyroidism with eutopic thyroid gland: analysis of clinical and biochemical features at diagnosis and after re-evaluation. *J Clin Endocrinol Metab*. 2013;98(4):1395–1402
- Castanet M, Goischke A, Léger J, et al; Fédération Parisienne pour le Dépistage et la Prévention des Handicaps de l'Enfant. Natural history and management of congenital hypothyroidism with in situ thyroid gland. *Horm Res Paediatr*. 2015;83(2):102–110
- Parks JS, Lin M, Grosse SD, et al. The impact of transient hypothyroidism on the increasing rate of congenital hypothyroidism in the United States. *Pediatrics*. 2010;125(suppl 2):S54–S63
- Brown RS, Bellisario RL, Botero D, et al. Incidence of transient congenital hypothyroidism due to maternal thyrotropin receptor-blocking antibodies in over one million babies. *J Clin Endocrinol Metab*. 1996;81(3):1147–1151
- Calaciura F, Motta RM, Miscio G, et al. Subclinical hypothyroidism in early childhood: a frequent outcome of transient neonatal hyperthyrotropinemia. *J Clin Endocrinol Metab*. 2002;87(7):3209–3214
- Oren A, Wang MK, Brnjac L, Mahmud FH, Palmert MR. Mild neonatal hyperthyrotrophinaemia: 10-year experience suggests the condition is increasingly common but often transient. *Clin Endocrinol (Oxf)*. 2013;79(6):832–837
- Léger J, Olivieri A, Donaldson M, et al; ESPE-PES-SLEP-JSPE-APEG-APPES-ISPAE; Congenital Hypothyroidism Consensus Conference Group. European Society for Paediatric Endocrinology consensus guidelines on screening, diagnosis, and management of congenital hypothyroidism. *Horm Res Paediatr*. 2014;81(2):80–103
- Rose SR, Brown RS, Foley T, et al; American Academy of Pediatrics; Section on Endocrinology and Committee on Genetics, American Thyroid Association; Public Health Committee, Lawson Wilkins Pediatric Endocrine Society. Update of newborn screening and therapy for congenital hypothyroidism. *Pediatrics*. 2006;117(6):2290–2303
- Maciel LM, Kimura ET, Nogueira CR, et al; Brazilian Society of Endocrinology and Metabolism. Congenital hypothyroidism: recommendations of the Thyroid Department of the Brazilian Society of Endocrinology and Metabolism [in English and Portuguese]. *Arq Bras Endocrinol Metabol*. 2013;57(3):184–192
- Hemmati F, Pishva N. Evaluation of thyroid status of infants in the intensive care setting. *Singapore Med J*. 2009;50(9):875–878
- Golombek SG. Nonthyroidal illness syndrome and euthyroid sick syndrome in intensive care patients. *Semin Perinatol*. 2008;32(6):413–418

21. Ford GA, Denniston S, Sesser D, Skeels MR, LaFranchi SH. Transient versus permanent congenital hypothyroidism after the age of 3 years in infants detected on the first versus second newborn screening test in Oregon, USA. *Horm Res Paediatr.* 2016;86(3):169–177
22. Doucett JA. Jaundice and congenital hypothyroidism. *JAMA.* 1965;194(3):299–300
23. Kurtoğlu S, Coban D, Akın MA, Akın L, Yıkılmaz A. Neonatal sludge: a finding of congenital hypothyroidism. *J Clin Res Pediatr Endocrinol.* 2009;1(4):197–200
24. Kang MJ, Chung HR, Oh YJ, Shim YS, Yang S, Hwang IT. Three-year follow-up of children with abnormal newborn screening results for congenital hypothyroidism. *Pediatr Neonatol.* 2017;58(5):442–448
25. Messina MF, Aversa T, Salzano G, et al. Early discrimination between transient and permanent congenital hypothyroidism in children with eutopic gland. *Horm Res Paediatr.* 2015;84(3):159–164
26. Kashiwagura Y, Uchida S, Tanaka S, et al. Clinical efficacy and pharmacokinetics of levothyroxine suppository in patients with hypothyroidism. *Biol Pharm Bull.* 2014;37(4):666–670

Rectal Levothyroxine for the Treatment of Hypothyroidism: A Case Study
Marina Ybarra, Tiago Jeronimo dos Santos, Claudia Teixeira Cabido Pinheiro, Vaê
Dichtchekenian and Durval Damiani

Pediatrics 2018;142;

DOI: 10.1542/peds.2017-3317 originally published online July 12, 2018;

Updated Information & Services

including high resolution figures, can be found at:
<http://pediatrics.aappublications.org/content/142/2/e20173317>

References

This article cites 26 articles, 2 of which you can access for free at:
<http://pediatrics.aappublications.org/content/142/2/e20173317#BIBL>

Subspecialty Collections

This article, along with others on similar topics, appears in the following collection(s):
Endocrinology
http://www.aappublications.org/cgi/collection/endocrinology_sub
Fetus/Newborn Infant
http://www.aappublications.org/cgi/collection/fetus:newborn_infant_sub
Neonatology
http://www.aappublications.org/cgi/collection/neonatology_sub

Permissions & Licensing

Information about reproducing this article in parts (figures, tables) or in its entirety can be found online at:
<http://www.aappublications.org/site/misc/Permissions.xhtml>

Reprints

Information about ordering reprints can be found online:
<http://www.aappublications.org/site/misc/reprints.xhtml>

American Academy of Pediatrics

DEDICATED TO THE HEALTH OF ALL CHILDREN®



PEDIATRICS®

OFFICIAL JOURNAL OF THE AMERICAN ACADEMY OF PEDIATRICS

Rectal Levothyroxine for the Treatment of Hypothyroidism: A Case Study
Marina Ybarra, Tiago Jeronimo dos Santos, Claudia Teixeira Cabido Pinheiro, Vaê
Dichtchekenian and Durval Damiani

Pediatrics 2018;142;

DOI: 10.1542/peds.2017-3317 originally published online July 12, 2018;

The online version of this article, along with updated information and services, is
located on the World Wide Web at:

<http://pediatrics.aappublications.org/content/142/2/e20173317>

Pediatrics is the official journal of the American Academy of Pediatrics. A monthly publication, it has been published continuously since 1948. Pediatrics is owned, published, and trademarked by the American Academy of Pediatrics, 345 Park Avenue, Itasca, Illinois, 60143. Copyright © 2018 by the American Academy of Pediatrics. All rights reserved. Print ISSN: 1073-0397.

American Academy of Pediatrics

DEDICATED TO THE HEALTH OF ALL CHILDREN®

