

Combination Analgesia for Neonatal Circumcision: A Randomized Controlled Trial

Rana Sharara-Chami, MD,^a Zavi Lakissian, MD, MPH,^a Lama Charafeddine, MD,^a Nadine Milad, MD,^a Yaser El-Hout, MD^b

abstract

OBJECTIVES: There is no consensus on the most effective pain management for neonatal circumcision. We sought to compare different modalities.

METHODS: This is a double-blinded randomized controlled trial comparing 3 combination analgesics used during circumcision (EMLA + sucrose; EMLA + sucrose + dorsal penile nerve block [DPNB]; EMLA + sucrose + ring block [RB]) with the traditional topical analgesic cream EMLA alone. The trial was set in the normal nursery of a teaching hospital. The sample included 70 healthy male newborns, randomly assigned to intervention and control groups at a 2:1 ratio. Infants were videotaped (face and torso) during the procedure for assessment of pain by 2 blinded, independent reviewers. The primary outcome measure is the Neonatal Infant Pain Scale score. Secondary outcomes include heart rate, oxygen saturation, and crying time.

RESULTS: Neonatal Infant Pain Scale scores were significantly lower in the intervention groups (EMLA + sucrose, mean [SD]: 3.1 [1.33]; EMLA + sucrose + DPNB: 3 [1.33]; EMLA + sucrose + RB: 2.45 [1.27]) compared with the control (5.5 [0.53]). Between-group analyses showed RB + EMLA + sucrose to be significantly more effective than EMLA + sucrose; EMLA + sucrose + DPNB ($P = .009$ and $P = .002$, respectively). Interrater reliability was $\kappa = 0.843$. Significant increase in heart rate (139.27 [9.63] to 163 [13.23] beats per minute) and crying time (5.78 [6.4] to 45.37 [12.39] seconds) were noted in the EMLA group.

CONCLUSIONS: During neonatal circumcision in boys, the most effective analgesia is RB combined with oral sucrose and EMLA cream.

Departments of ^aPediatrics and Adolescent Medicine and ^bSurgery, American University of Beirut Medical Center, Beirut, Lebanon

Dr Sharara-Chami conceptualized and designed the study, reviewed the manuscript, and revised the manuscript; Dr El-Hout performed circumcisions, conceptualized and designed the study, and reviewed and revised the manuscript; Dr Sharara-Chami independently reviewed the procedure videotapes; Dr Lakissian collected the data, conducted the analyses, and drafted, reviewed, and revised the manuscript; Dr Charafeddine independently reviewed the procedure videotapes, reviewed the manuscript, and revised the manuscript; Dr Milad conceptualized the design and drafted the initial study proposal; and all authors approved the final manuscript as submitted and agree to be accountable for all aspects of the work.

This trial has been registered at www.clinicaltrials.gov (identifier NCT02990364).

DOI: <https://doi.org/10.1542/peds.2017-1935>

Accepted for publication Sep 19, 2017

Address correspondence to Yaser El-Hout, MD, Department of Surgery, American University of Beirut Medical Center, Riad El Solh, Beirut 110 72020, Lebanon. E-mail: yelhout@aub.edu.lb

PEDIATRICS (ISSN Numbers: Print, 0031-4005; Online, 1098-4275).

WHAT'S KNOWN ON THIS SUBJECT: Circumcision, a common, yet painful, procedure is often performed without analgesia or with only a eutectic mixture of local anesthetic cream. Two analgesia comparisons have shown penile nerve block to be more effective than cream analgesia or sucrose alone.

WHAT THIS STUDY ADDS: This study is a 4-arm randomized controlled trial comparing combination analgesia during neonatal circumcision. The most effective analgesia is ring block combined with oral sucrose and EMLA cream. No adverse events were noted with ring block performed by an expert.

To cite: Sharara-Chami R, Lakissian Z, Charafeddine L, et al. Combination Analgesia for Neonatal Circumcision: A Randomized Controlled Trial. *Pediatrics*. 2017;140(6):e20171935

Circumcision of newborn boys is 1 of the most frequently performed procedures in the world,¹ yet it remains 1 of the most controversial. Some view the procedure as a means of reducing the risk of sexually transmitted diseases and urinary tract infections, whereas others perceive circumcisions as unnecessary.² Circumcision remains mostly a cultural procedure. Additionally, clinicians have been unable to reach a consensus regarding analgesia during circumcision. Despite evidence to the contrary,³ some health care workers maintain that the procedure causes minimal pain that the infant will quickly forget.^{2,4} However, there is considerable evidence that newborns are capable of mature pain perception manifesting in physiologic (increased heart rate and blood pressure, decreased oxygen saturation, etc) and behavioral changes (facial expression, prolonged crying time, irritability, etc).^{5,6}

In 1999, the American Academy of Pediatrics (AAP) Task Force on Circumcision recognized “the health benefits of circumcision but did not deem the procedure a medical necessity for the well-being of the child.”¹ Given the current evidence, the AAP has restated that the “preventive health benefits of elective circumcision of newborn boys outweigh the risks of the procedure; [these] benefits justify access to this procedure for families who choose it.”⁷ However, the success of the procedure is contingent on the competency of the surgeon, sterile conditions, and the appropriate pain management.^{1,7} Furthermore, in a policy statement, the AAP Committee on Fetus and Newborn and Section on Anesthesiology and Pain Medicine⁸ reported that there are proven and safe therapies to prevent and relieve pain in neonates, which are currently underused for routine minor, yet painful, procedures. These therapies

include both pharmacological and nonpharmacological approaches.

Numerous studies have been conducted in an effort to determine the optimal pain management strategy for circumcision.³ The various combinations and the types of analgesics compared included the following: dorsal penile nerve block (DPNB), ring block (RB), and a eutectic mixture of local anesthetic (EMLA) cream and sucrose. Both DPNB and RB, if administered properly, are safe and effective measures in reducing the behavioral and physiologic indicators of pain caused by the circumcision, regardless of the surgical method used.^{2,3} There is also suggestive evidence for the efficacy of nonpharmacological techniques such as the oral administration of sucrose; however, they are recommended as analgesic adjuncts and not as the sole method of analgesia.^{7,9} To the knowledge of the investigators, there are no studies comparing 3 variations of combination analgesics. We hypothesize that EMLA alone does not provide enough pain relief and that additional combination analgesia is needed (sucrose + DPNB or RB).

METHODS

This study is a prospective double-blinded randomized controlled trial conducted to compare 3 combination analgesics (EMLA + sucrose; EMLA + sucrose + DPNB; and EMLA + sucrose + RB) with the traditional topical analgesic (EMLA) used during circumcision on healthy newborn boys. Informed parental consent was obtained for the procedure and for the enrollment of newborns into the study. The institutional review board of the American University of Beirut approved the protocol and the trial is registered on clinicaltrials.gov (identifier NCT02990364).

All healthy, late preterm and term (36–41 weeks’ gestation) newborn boys admitted to the normal nursery

at the American University of Beirut Medical Center whose parents requested circumcision were eligible for recruitment. After an infant’s first void and clearance for circumcision by the nursery pediatrician, usually between 18 and 48 hours of life, the pediatric urologist would ask for parental consent for the procedure and the study. All newborns were fed 1 to 2 hours before circumcision, and EMLA cream was applied 1 hour before circumcision. Ten minutes before the procedure, each newborn was leg-restrained in a supine position on the circumcision board and attached to a monitor that kept track of heart rate and oxygen saturation throughout the procedure; each infant was given a few minutes to settle down. All circumcisions were performed by 1 pediatric urologist by using the Gomco technique. The circumcision procedure was divided into 6 color-coded stages, which were called out by the pediatric urologist to avoid biasing the evaluating pediatricians of the perceived pain of each stage (red: stretching and clamping of the foreskin; blue: dorsal incision of the foreskin; green: lysis of adhesions between foreskin and glans; orange: tying the clamp; black: cutting the foreskin; and purple: applying the dressing). All newborns had sterile ointment gauze wrapped around the penis for 24 hours after the circumcision.

Each newborn was videotaped during the procedure. Videotaping began after the administration of the nerve block (when applicable) and excluded the surgeon and the field. The video camera captured each infant’s face and torso to record facial expression, crying time and intensity, breathing patterns, arm movements, and state of arousal. These measures are included in the Neonatal Infant Pain Scale (NIPS) (Table 1), which was used by the nurses (blinded to the analgesia used) in the normal nursery every hour for 4 hours

after each procedure. In addition, 2 pediatricians blinded to the method of analgesia independently reviewed the videotapes of each procedure to assess pain experienced during each stage of circumcision. After initial interrater reliability analysis ($\kappa = 0.487$), 47 videotapes, which had more than 3 points of disagreement, were rereviewed and rescored, yielding a final improved interrater reliability ($\kappa = 0.843$).

Outcomes

1. The use of neonatal pain assessment tools has proven highly reliable and is strongly recommended by the AAP.⁸ Many of these tools are multidimensional in nature and include a combination of physiologic and behavioral indicators of pain. The primary outcome was the NIPS score for assessing behavioral changes. The NIPS is a noninvasive, replicable, and objective tool for assessing pain responses.¹⁰ The scale yields a total score ranging from 0 to 7, in which scores more than 3 are indicative of pain. The NIPS is one of the easier tools to use and apply for health professionals working with neonates who are exposed to painful stimuli.¹¹ For the purpose of this study, the NIPS was modified (see Table 1) by removing the score for legs, because the newborns were confined first by strapping them to the circumcision board and later by the use of gentle swaddling. The tool is used to observe 5 behavioral cues over time, with a composite score of 0 to 6, to determine the amount of pain or change in pain the infant is experiencing, with 0 representing minimum pain and 6 representing maximum pain. The observed behaviors are facial expression, crying, breathing patterns, position of the arms, and state of arousal.¹² The score's

TABLE 1 Modified NIPS

	Behavior Score		
	0	1	2
Facial expression	Relaxed muscles, natural expression	Grimace: tight muscles, furrowed brow	—
Crying	Quiet or not crying	Whimper: mild moaning intermittently	Vigorous crying: loud shrill scream
Breathing patterns	Relaxed	Change in breathing: irregular, faster than usual, gagging	—
Arms	Relaxed, no muscular rigidity, occasional movements	Flexed or extended: tense, straight, and rigid; rapid extension or flexion	—
State of arousal	Sleeping or awake: quiet, peaceful, sleeping, or alert and settled	Fussy: alert, restless, and thrashing	—

—, not applicable.

interobserver validity, construct validity, concurrent validity, and internal consistency are high.¹⁰ Reliability tests were performed on the NIPS (Cronbach's $\alpha = .930$); to assess interrater reliability, the measure of agreement κ was calculated (0.834). A mean NIPS score for each newborn was then calculated by taking the mean of the 6 stages of the circumcision; and

2. Secondary outcomes included physiologic data: heart rate, oxygen saturation, crying time during the circumcision procedure, and, additionally, the respiratory rate as measured every hour for the 4 hours after circumcision. The research fellow who had neither performed the circumcision nor scored the tapes analyzed the physiologic and behavioral data.

Interventions

The drugs that were used in the study are all local anesthetics of the aminoamide group and include lidocaine and prilocaine. The control group received the traditional anesthetic, that is, topical cream EMLA, whereas the combination groups received additional anesthetic agents. Comparisons were made for the following groups:

EMLA + Sucrose

EMLA cream is a eutectic mixture of 2.5% lidocaine and 2.5% prilocaine that is used as a topical anesthetic to diminish pain from cutaneous procedures. Sixty minutes before the circumcision, 1 g of EMLA cream was applied by the nurse to the penis of the newborn and wrapped with Tegaderm dressing (Johnson & Johnson, Inc, Arlington, TX). The cream and dressing were removed before the procedure. There is sufficient evidence to support the administration of sucrose, often in conjunction with additional pharmacologic and nonpharmacologic interventions, for relief of procedural pain.¹³ It is the neonate's detection of a sweet substance, not the volume, that produces the analgesic effect. As a result, studies report that 0.05 to 0.5 mL is an adequate volume of 24% to 25% sucrose or glucose for reducing procedural pain in neonates.¹⁴ For this study, 2 mL of 25% sucrose was administered orally and intermittently via a syringe throughout the circumcision procedure by an assisting nurse.

EMLA + Sucrose + DPNB

The placement of EMLA and the administration of sucrose were the same as described for the EMLA + sucrose group. DPNB is an anesthetic technique that has been

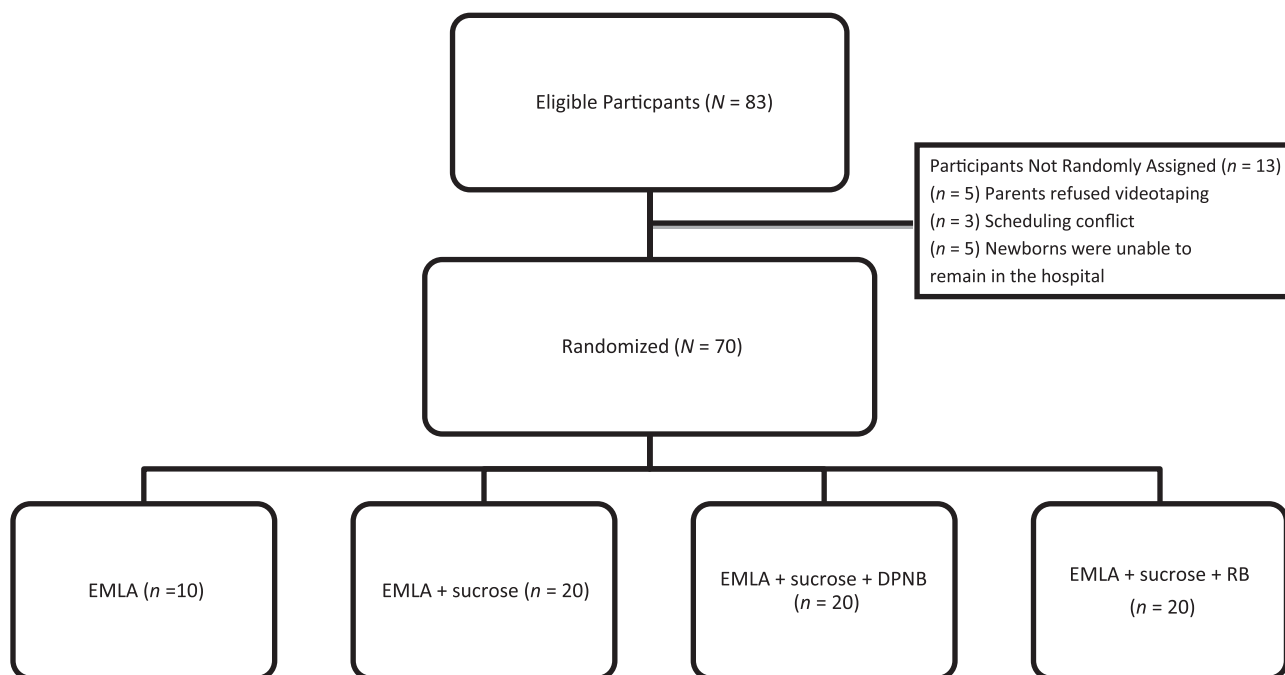


FIGURE 1
Study population.

extensively used and evaluated in the management of pain during circumcision since the late 1970s.¹⁵ The pediatric urologist administered the DPNB (2 mg/kg of 1% lidocaine without epinephrine) in equal aliquots in milliliters at the 2 and 10 o'clock positions at the base of the penis 5 minutes before the circumcision.

EMLA + Sucrose + RB

The placement of EMLA and the administration of sucrose were the same as described for the EMLA + sucrose group. RB is an anesthetic technique first described in the 1990s,^{2,16} which has also been examined for pain control during circumcision. The pediatric urologist administered the RB (2 mg/kg of 1% lidocaine without epinephrine) in a band around the penis 5 minutes before the circumcision.

Sample Size

A sample size of 70 infants was considered sufficient to demonstrate a difference and σ (s) of 1 in the category of pain, with a significance

level at 0.05 and a power of 80%. The power, when comparing between intervention groups, was 87%, and it was 70% when comparing between intervention groups and the control.

Randomization and Blinding

Randomization by blocks of 6 and 9 was used. The allocation ratio of intervention to control was 2:1. An independent statistician not involved in the study conducted the random assignment process. The random assignment list was held by the research fellow, and participants were assigned an analgesia on the basis of this list (Fig 1). The surgeon was informed of each newborn's random assignment immediately before circumcision. The nurses scoring each infants' pain after the procedure were blinded to the type of analgesia administered, as were the 2 pediatricians who evaluated the videotapes retrospectively.

Statistical Methods

Results were analyzed quantitatively by using the statistical analytics software SPSS (IBM SPSS Statistics,

IBM Corporation, Armonk, NY). First, descriptive statistical analysis was performed for primary and secondary outcomes. Multivariate analyses (assuming homogeneity of variance), repeated analysis of variance, and Dunnett's post hoc tests (Control and T3) were performed to determine if there were significant differences between the intervention groups and the control and among the intervention groups.

RESULTS

The study groups were similar in baseline characteristics, including gestational age (mean [SD]: 38.46 [1.2] weeks' gestation), birth weight (3352.7 [448.3] g), and duration of procedure (6.3 [1.09] minutes (Table 2). NIPS mean differences between the intervention groups (EMLA + sucrose: 3.10 [1.33]; EMLA + sucrose + DPNB: 3 [1.33]; EMLA + sucrose + RB: 2.45 [1.27]) and the EMLA group (5.50 [0.53]) were significantly different (Table 3). Similarly, heart rate and crying time were significantly different between

TABLE 2 Study Group Characteristics, Mean (SD)

	EMLA (<i>n</i> = 10)	EMLA + Sucrose (<i>n</i> = 20)	EMLA + Sucrose + DPNB (<i>n</i> = 20)	EMLA + Sucrose + RB (<i>n</i> = 20)	Overall
Gestational age, wk	38.50 (1.35)	38.45 (1.14)	38.65 (0.98)	38.26 (1.6)	38.46 (1.2)
Birth wt, g	3392.5 (351)	3252.11 (397.8)	3584.75 (496.8)	3178.94 (405.1)	3352.7 (448.3)
Procedural time, a min	5.63 (0.78)	6.59 (1.13)	6.31 (0.94)	6.35 (1.24)	6.30 (1.09)

^a Procedural time includes the duration between the first stage of circumcision (ie, stretching and clamping the foreskin) until the last stage (ie, application of the dressing).

TABLE 3 Primary Outcome: NIPS Score During Circumcision

	EMLA (<i>n</i> = 10)			EMLA + Sucrose (<i>n</i> = 20)			EMLA + Sucrose + DPNB (<i>n</i> = 20)			EMLA + Sucrose + RB (<i>n</i> = 20)		
	Mean (SD)	Mean (SD)	<i>P</i>	Mean (SD)	<i>P</i>	Mean (SD)	<i>P</i>	Mean (SD)	<i>P</i>	Mean (SD)	<i>P</i>	
Overall	5.50 (0.53)	3.10 (1.33)	<.001 ^a	3 (1.33)	<.001 ^a	2.45 (1.27)	<.001 ^a	3 (1.33)	<.001 ^a	2.45 (1.27)	<.001 ^a	
Stage 1	5.90 (0.31)	2.85 (2.08)	<.001 ^a	2.80 (2.41)	<.001 ^a	2.70 (2.45)	<.001 ^a	2.80 (2.41)	<.001 ^a	2.70 (2.45)	<.001 ^a	
Stage 2	5.30 (1.48)	1.55 (1.96)	<.001 ^a	1.40 (2.06)	<.001 ^a	1.40 (1.85)	<.001 ^a	1.40 (2.06)	<.001 ^a	1.40 (1.85)	<.001 ^a	
Stage 3	6	4.70 (1.30)	.060	4.55 (2.06)	.031 ^a	4.50 (1.64)	.031 ^a	4.55 (2.06)	.031 ^a	4.50 (1.64)	<.001 ^a	
Stage 4	5.80 (0.632)	4.30 (2.10)	.041 ^a	4.40 (1.73)	.020 ^a	2.25 (1.65)	<.001 ^a ; .009 ^b ; .002 ^b	4.40 (1.73)	.020 ^a	2.25 (1.65)	<.001 ^a ; .009 ^b ; .002 ^b	
Stage 5	3.80 (1.93)	1.55 (1.53)	.001 ^a	1.60 (1.60)	.001 ^a	1.20 (1.29)	<.001 ^a	1.60 (1.60)	.001 ^a	1.20 (1.29)	<.001 ^a	
Stage 6	5.80 (0.632)	3.50 (2.33)	.002 ^a	3.35 (2.32)	.001 ^a	1.95 (1.88)	<.001 ^a	3.35 (2.32)	.001 ^a	1.95 (1.88)	<.001 ^a	

^a Statistically significant difference between the current intervention group and the control group (EMLA).

^b Statistically significant difference between the current intervention group and another intervention group (EMLA + sucrose and EMLA + sucrose + DPNB, respectively).

TABLE 4 Secondary Outcomes

	EMLA (<i>n</i> = 10)			EMLA + Sucrose (<i>n</i> = 20)			EMLA + Sucrose + DPNB (<i>n</i> = 20)			EMLA + Sucrose + RB (<i>n</i> = 20)		
	Mean (SD)	Mean (SD)	<i>P</i>	Mean (SD)	<i>P</i>	Mean (SD)	<i>P</i>	Mean (SD)	<i>P</i>	Mean (SD)	<i>P</i>	
Heart rate, beats per min	163.3 (13.23)	152.03 (16.31)	.040 ^a	146.55 (15.63)	.004 ^a	139.27 (9.63)	<.001 ^{a,b} ; .030 ^b	163.3 (13.23)	.040 ^a	152.03 (16.31)	<.001 ^{a,b} ; .030 ^b	
Oxygen saturation, %	95.92 (3.37)	97.07 (2.19)	.897	98.48 (1.73)	.214	97.81 (1.6)	.439	95.92 (3.37)	.897	97.07 (2.19)	.439	
Crying time, s	45.37 (12.39)	16.47 (14.58)	<.001 ^a	11.53 (11.65)	<.001 ^a	5.78 (6.4)	<.001 ^a ; .034 ^b	45.37 (12.39)	<.001 ^a	16.47 (14.58)	<.001 ^a ; .034 ^b	

^a Statistically significant difference between the current intervention group and the control group (EMLA).

^b Statistically significant difference between the current intervention group and another intervention group (EMLA + sucrose and EMLA + sucrose + DPNB, respectively).

the control and intervention groups, ranging from 139.27 (9.63) to 163 (13.23) beats per minute and 5.78 (6.4) to 45.37 (12.39) seconds, respectively (Table 4). There was no significance between analgesia groups with regard to oxygen saturation during circumcision or postoperative NIPS scores ($P > .930$).

NIPS scores were analyzed by study group for each stage of circumcision (Table 3, Fig 2). Both DPNB and RB had lower scores than the first intervention group (EMLA + sucrose) and the control EMLA, particularly during the most painful stage: lysis of adhesions between the foreskin and the glans (NIPS score: 4.50–6). Between-group comparisons revealed no significant difference in the NIPS score among the 3 combination analgesics.

However, during the fourth stage of circumcision, all primary and secondary outcome measures, except oxygen saturation, were significantly lower in the EMLA + sucrose + RB group (NIPS score: 2.25 [1.65]) compared with the other 2 intervention groups.

DISCUSSION

Neonatal circumcision remains a common procedure with no consensus on optimal analgesia. We chose to compare EMLA + sucrose to EMLA alone as 1 of the groups because some physicians remain reluctant to perform any additional invasive procedure to assure analgesia. Our data revealed that during newborn circumcision, all interventions provided better

pain relief than EMLA alone. EMLA + sucrose, EMLA + sucrose + DPNB, and EMLA + sucrose + RB were generally equally effective. However, during the most painful stage, that is, lysis of adhesions, EMLA + sucrose + RB provided the best local anesthesia compared with EMLA + sucrose and EMLA + sucrose + DPNB.

Despite the fact that vital signs remained relatively stable, the 10 infants in the control group (EMLA) experienced severe pain (6 at stage III) and higher NIPS scores during all stages of circumcision (3.80–5.90); this is evidenced by the behavioral and physiologic outcomes manifesting as facial grimace, vigorous crying, fisting and trembling, changes in the breathing pattern, and fussiness during each stage of the procedure. The

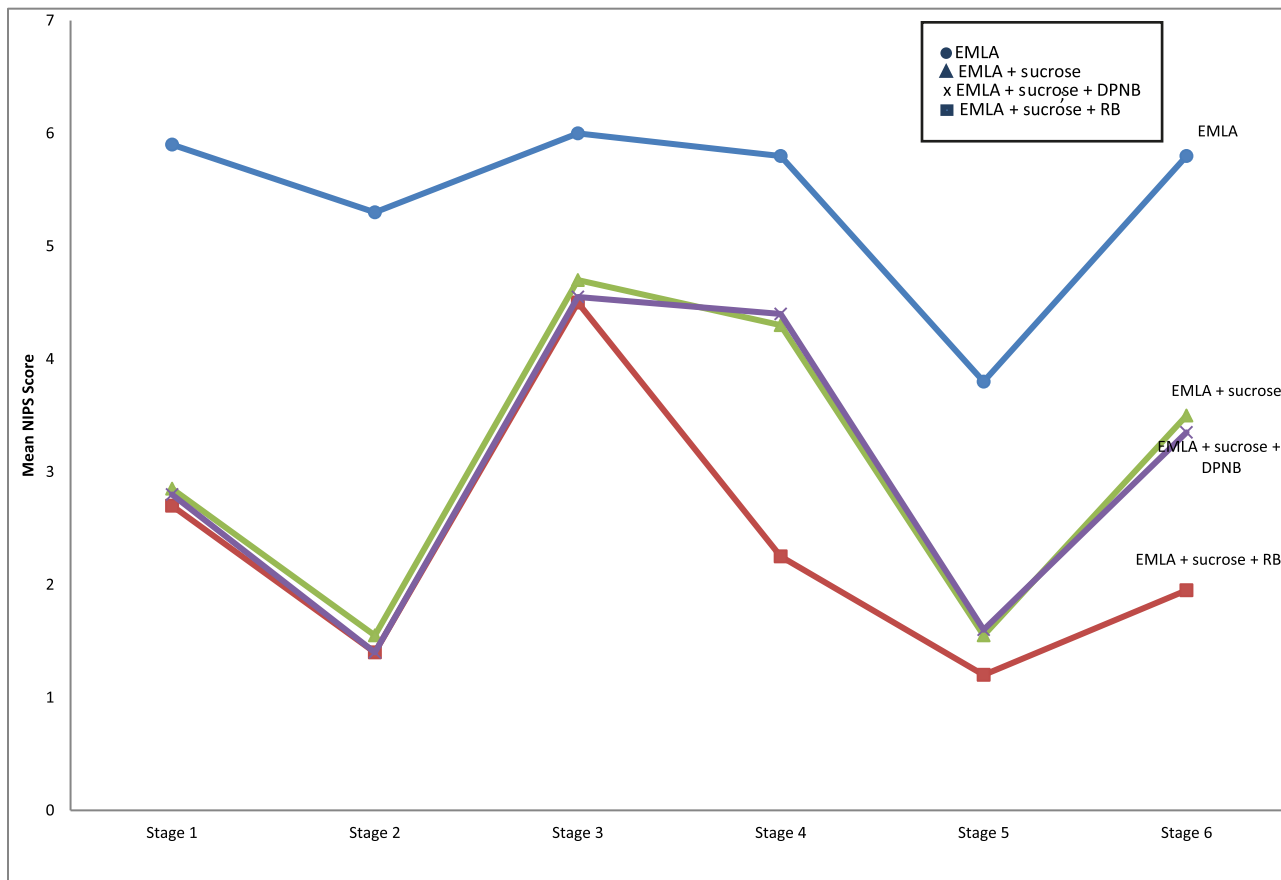


FIGURE 2

NIPS change through the stages of the circumcision. Stages of circumcision include the following: (1) red: stretching and clamping of the foreskin; (2) blue: dorsal incision of the foreskin; (3) green: lysis of adhesions between foreskin and glans; (4) orange: tying the clamp; (5) black: cutting the foreskin; and (6) purple: applying the dressing.

investigators believe these findings to be clinically significant, particularly as the blinded reviewers noted almost “silent circumcisions” in patients later revealed to have been randomly assigned to combination analgesia. This indicates that the procedure was not painful at all: an outcome that health care providers and parents alike would appreciate.

The authors of several studies have evaluated the effect of different analgesia approaches during neonatal circumcision, both invasive and noninvasive.^{10,17–19} A study by Butler-O’Hara et al¹⁵ revealed that DPNB resulted in lower NIPS scores and provided better analgesia than EMLA alone and that EMLA is better than no analgesia at all. Similarly, we demonstrate in our study that DPNB and RB were effective in

reducing the pain of circumcision, as indicated by mean NIPS scores of 3 (1.3) and 2.45 (1.2), respectively, and heart rates lower than the control group EMLA by 16 and 27 beats per minute. Administration of local anesthetic agents through DPNB or RB is considered a relatively simple yet effective pain control measure.²⁰ Understanding the anatomic route of the penile neurovascular bundles allows for proper administration of the block and minimizes the likelihood of complications; nonetheless, this procedure must be performed by trained and experienced practitioners. The authors of studies in which complications associated with DPNB are examined have shown that some newborns experience hematomas,²¹ minor bleeding, and

ecchymosis at the injection site.^{22,23} Few cases of scrotal skin necrosis after an injection of lidocaine and epinephrine have been documented with RB.²³ As elegantly demonstrated by Baskin co-workers,²⁴ the neurovascular bundles run under the pubic arch at 10 and 2 o’clock alongside to the dorsal vein of the penis. Administration of anesthetic agent in the sub-pubic space, while avoiding the dorsal vein entry, will provide safe and effective pain control.

The choice of the circumcision instrument may have an impact on pain, although this may be related to the brevity of the procedure when a certain instrument is used, rather than to a peculiarity of the hardware. Kurtis et al²⁵ compared the Mogen and Gomco clamps in combination

with DPNB in minimizing the pain of circumcision. Their results found that DPNB is effective regardless of the clamp used. For our study, we chose to use the Gomco clamp tied at the fourth stage of the circumcision (NIPS score: 2.25–5.80). Given that this stage follows the most painful one, lysis of adhesions (NIPS score: 4.50–6), and that the average duration of each stage was ~60 (25) seconds, we can safely assume that the infants' distress in the fourth stage can be attributed to the pain experienced in the third. This being said, our results showed that EMLA + sucrose + RB was significantly more effective than EMLA + sucrose + DPNB ($P = 0.002$) in reducing the newborns' pain at that stage, as evidenced by their respective NIPS scores of 2.25 (1.29) vs 4.40 (1.73).

The AAP recommends pain management during painful procedures performed on newborns.^{1,7} This is the current recommended and applied practice in most NICUs. Subsequently, all infants in our study received EMLA. Additionally, Serour et al²⁶ showed that the application of EMLA before DPNB would decrease the pain associated with the administration of the blocks. However, we did not specifically measure this outcome because all study participants received EMLA with or without the nerve blocks. On the basis of our observations, we speculate this to be less the case in most normal nurseries around the world, especially in developing countries, where circumcision has become a "casual" and "routine" procedure and the pain associated with it is expected and accepted.

Per the AAP's recommendations for sucrose as an adjunct analgesia, the authors of a number of studies have concurred that a nipple dipped in sucrose is efficacious for pain relief during neonatal circumcision.^{3,27} Schoen and Fischell²⁸ concluded the following: "in view of the noninvasive, risk-free nature of a sucrose-flavored pacifier, this technique deserves wide-spread evaluation of its effectiveness." In our study, we combined 10 mL of 25% sucrose dripped on the newborn's tongue over the course of the circumcision with EMLA, DPNB, and RB. Our results revealed that although sucrose is more effective than EMLA alone by a statistically significant measure during all stages of circumcision, it marginally falls short during the most painful stage. We note that we did not use a pacifier dipped in sugar, and, hence, this could have eliminated the soothing effect that accompanies the sucking reflex.

Despite our findings and those in the extensive literature about the effectiveness and safety of different analgesic approaches for circumcision and pain management, this procedure continues to be performed without a proper, standardized pain management strategy. The reasons behind this practice are likely multifactorial and may include the following: a lack of familiarity with DPNB and RB techniques and apprehension about some of their potential complications; a lack of awareness among physicians and families about the effectiveness of analgesia during circumcision; an assumption that pain is minimal and transient;

an assumption that newborns do not experience the same degree of pain as other patients; and the presence of subjective views, some culturally rooted, that there is no alternative but to suffer through the pain.

CONCLUSIONS

Newborns randomly assigned to combination anesthesia in the form of EMLA + sucrose + nerve blocks experienced less pain, as indicated by lower NIPS scores and better vital signs over the duration of the procedure compared with newborns who received EMLA alone. In addition, our data reveal that, among the nerve blocks, the most effective method for pain management during circumcision is EMLA + adjunct oral sucrose + RB.

ACKNOWLEDGMENTS

We thank Ms Vicky Tazian, the nurse manager of the normal nursery at the American University of Beirut Medical Center, for her assistance and Drs Labib Ghulmiyyah, Fadi Mirza, and Hani Tamim for their continued support during the course of the study.

ABBREVIATIONS

AAP: American Academy of Pediatrics
DPNB: dorsal penile nerve block
EMLA: eutectic mixture of local anesthetic
NIPS: Neonatal Infant Pain Scale
RB: ring block

Copyright © 2017 by the American Academy of Pediatrics

FINANCIAL DISCLOSURE: Dr Yaser El-Hout was compensated for the circumcision procedures per hospital regulations; the other authors have indicated they have no financial relationships relevant to this article to disclose.

FUNDING: No external funding.

POTENTIAL CONFLICT OF INTEREST: The authors have indicated they have no potential conflicts of interest to disclose.

COMPANION PAPER: A companion to this article can be found online at www.pediatrics.org/cgi/doi/10.1542/peds.2017-2678.

REFERENCES

- American Academy of Pediatrics Task Force on Circumcision. Circumcision policy statement. *Pediatrics*. 1999;103(3):686–693
- Lander J, Brady-Fryer B, Metcalfe JB, Nazarali S, Muttitt S. Comparison of ring block, dorsal penile nerve block, and topical anesthesia for neonatal circumcision: a randomized controlled trial. *JAMA*. 1997;278(24):2157–2162
- Brady-Fryer B, Wiebe N, Lander JA. Pain relief for neonatal circumcision. *Cochrane Database Syst Rev*. 2004;(4):CD004217
- Wellington N, Rieder MJ. Attitudes and practices regarding analgesia for newborn circumcision. *Pediatrics*. 1993;92(4):541–543
- Butler-O'Hara M, LeMoine C, Guillet R. Analgesia for neonatal circumcision: a randomized controlled trial of EMLA cream versus dorsal penile nerve block. *Pediatrics*. 1998;101(4). Available at: www.pediatrics.org/cgi/content/full/101/4/e5
- Howard CR, Howard FM, Fortune K, et al. A randomized, controlled trial of a eutectic mixture of local anesthetic cream (lidocaine and prilocaine) versus penile nerve block for pain relief during circumcision. *Am J Obstet Gynecol*. 1999;181(6):1506–1511
- American Academy of Pediatrics Task Force on Circumcision. Circumcision policy statement. *Pediatrics*. 2012;130(3):585–586
- American Academy of Pediatrics Committee on Fetus and Newborn and Section on Anesthesiology and Pain Medicine. Prevention and management of procedural pain in the neonate: an update. *Pediatrics*. 2016;137(2):e20154271
- Herschel M, Khoshnood B, Ellman C, Maydew N, Mittendorf R. Neonatal circumcision. Randomized trial of a sucrose pacifier for pain control [published correction appears in *Arch Pediatr Adolesc*. 1998;152(5):448]. *Arch Pediatr Adolesc Med*. 1998;152(3):279–284
- Lawrence J, Alcock D, McGrath P, Kay J, MacMurray SB, Dulberg C. The development of a tool to assess neonatal pain. *Neonatal Netw*. 1993;12(6):59–66
- Motta Gde C, Schardosim JM, Cunha ML. Neonatal Infant Pain Scale: cross-cultural adaptation and validation in Brazil. *J Pain Symptom Manage*. 2015;50(3):394–401
- Backus AL. *Validation of the Neonatal Infant Pain Scale* [master's thesis]. Allendale, MI: Grand Valley State University; 1996. Available at: <http://scholarworks.gvsu.edu/theses/280>. Accessed May 11, 2017
- Anand KJS; International Evidence-Based Group for Neonatal Pain. Consensus statement for the prevention and management of pain in the newborn. *Arch Pediatr Adolesc Med*. 2001;155(2):173–180
- Stevens B, Yamada J, Lee GY, Ohlsson A. Sucrose for analgesia in newborn infants undergoing painful procedures [published correction appears in *Cochrane Database Syst Rev*. 2016;(7):CD001069]. *Cochrane Database Syst Rev*. 2013;(1):CD001069
- Kirya C, Werthmann MW Jr. Neonatal circumcision and penile dorsal nerve block—a painless procedure. *J Pediatr*. 1978;92(6):998–1000
- Hardwick-Smith S, Mastrobattista JM, Wallace PA, Ritchey ML. Ring block for neonatal circumcision. *Obstet Gynecol*. 1998;91(6):930–934
- Williamson PS, Williamson ML. Physiologic stress reduction by a local anesthetic during newborn circumcision. *Pediatrics*. 1983;71(1):36–40
- Benini F, Johnston CC, Faucher D, Aranda JV. Topical anesthesia during circumcision in newborn infants. *JAMA*. 1993;270(7):850–853
- Taddio A, Stevens B, Craig K, et al. Efficacy and safety of lidocaine-prilocaine cream for pain during circumcision. *N Engl J Med*. 1997;336(17):1197–1201
- Garry DJ, Swoboda E, Elimian A, Figueroa R. A video study of pain relief during newborn male circumcision. *J Perinatol*. 2006;26(2):106–110
- Soh CR, Ng SB, Lim SL. Dorsal penile nerve block. *Paediatr Anaesth*. 2003;13(4):329–333
- Fontaine P, Dittberner D, Scheltema KE. The safety of dorsal penile nerve block for neonatal circumcision. *J Fam Pract*. 1994;39(3):243–248
- Gul M, Kaynar M, Sekmenli T, Ciftci I, Goktas S. Epinephrine injection associated scrotal skin necrosis. *Case Rep Urol*. 2015;2015:187831
- Akman Y, Liu W, Li YW, Baskin LS. Penile anatomy under the pubic arch: reconstructive implications. *J Urol*. 2001;166(1):225–230
- Kurtis PS, DeSilva HN, Bernstein BA, Malakh L, Schechter NL. A comparison of the Mogen and Gomco clamps in combination with dorsal penile nerve block in minimizing the pain of neonatal circumcision. *Pediatrics*. 1999;103(2). Available at: www.pediatrics.org/cgi/content/full/103/2/e23
- Serour F, Mandelberg A, Zabeeda D, Mori J, Ezra S. Efficacy of EMLA cream prior to dorsal penile nerve block for circumcision in children. *Acta Anaesthesiol Scand*. 1998;42(2):260–263
- Blass EM, Hoffmeyer LB. Sucrose as an analgesic for newborn infants. *Pediatrics*. 1991;87(2):215–218
- Schoen EJ, Fischell AA. Pain in neonatal circumcision. *Clin Pediatr (Phila)*. 1991;30(7):429–432

Combination Analgesia for Neonatal Circumcision: A Randomized Controlled Trial

Rana Sharara-Chami, Zavi Lakissian, Lama Charafeddine, Nadine Milad and Yaser El-Hout

Pediatrics 2017;140;

DOI: 10.1542/peds.2017-1935 originally published online November 17, 2017;

Updated Information & Services

including high resolution figures, can be found at:
<http://pediatrics.aappublications.org/content/140/6/e20171935>

References

This article cites 25 articles, 6 of which you can access for free at:
<http://pediatrics.aappublications.org/content/140/6/e20171935#BIBL>

Subspecialty Collections

This article, along with others on similar topics, appears in the following collection(s):
Fetus/Newborn Infant
http://www.aappublications.org/cgi/collection/fetus:newborn_infant_sub
Circumcision
http://www.aappublications.org/cgi/collection/circumcision_sub
Anesthesiology/Pain Medicine
http://www.aappublications.org/cgi/collection/anesthesiology:pain_medicine_sub

Permissions & Licensing

Information about reproducing this article in parts (figures, tables) or in its entirety can be found online at:
<http://www.aappublications.org/site/misc/Permissions.xhtml>

Reprints

Information about ordering reprints can be found online:
<http://www.aappublications.org/site/misc/reprints.xhtml>

American Academy of Pediatrics

DEDICATED TO THE HEALTH OF ALL CHILDREN™



PEDIATRICS®

OFFICIAL JOURNAL OF THE AMERICAN ACADEMY OF PEDIATRICS

Combination Analgesia for Neonatal Circumcision: A Randomized Controlled Trial

Rana Sharara-Chami, Zavi Lakissian, Lama Charafeddine, Nadine Milad and Yaser El-Hout

Pediatrics 2017;140;

DOI: 10.1542/peds.2017-1935 originally published online November 17, 2017;

The online version of this article, along with updated information and services, is located on the World Wide Web at:

<http://pediatrics.aappublications.org/content/140/6/e20171935>

Pediatrics is the official journal of the American Academy of Pediatrics. A monthly publication, it has been published continuously since 1948. Pediatrics is owned, published, and trademarked by the American Academy of Pediatrics, 141 Northwest Point Boulevard, Elk Grove Village, Illinois, 60007. Copyright © 2017 by the American Academy of Pediatrics. All rights reserved. Print ISSN: 1073-0397.

American Academy of Pediatrics

DEDICATED TO THE HEALTH OF ALL CHILDREN™

