
ERRATA

Tsujii N, Shiraishi I, Kokame K, et al. Severe Hemolysis and Pulmonary Hypertension in a Neonate With Upshaw-Schulman Syndrome. *Pediatrics*. 2016;138(6):e20161565

Errors occurred in the article by Tsujii et al, titled “Severe Hemolysis and Pulmonary Hypertension in a Neonate With Upshaw-Schulman Syndrome” published in the December 2016 issue of *Pediatrics* (2016;138(6):e20161565;doi:10.1542/peds.2016-1565).

On page e1, under author contributions, the text reads “Dr Shraishi contributed to.” This should have read: “Dr Shiraishi contributed to.”

On page e3, in Fig 1, the text “D-dimer ($\mu\text{g/mL}$)” is printed in red. This should have printed in black. A replacement Fig 1 is provided here.

On page e4, in Table 6, on line 6, the text reads: “ $3 \times 10^9/\text{L}$ ”. This should have read: “ $3 \times 10^9/\text{L}$ ”.

On page e5, the underline in Fig 2 is slight shifted. A replacement Fig 2 is provided here.

doi:10.1542/peds.2016-4105

short axis view of TTE

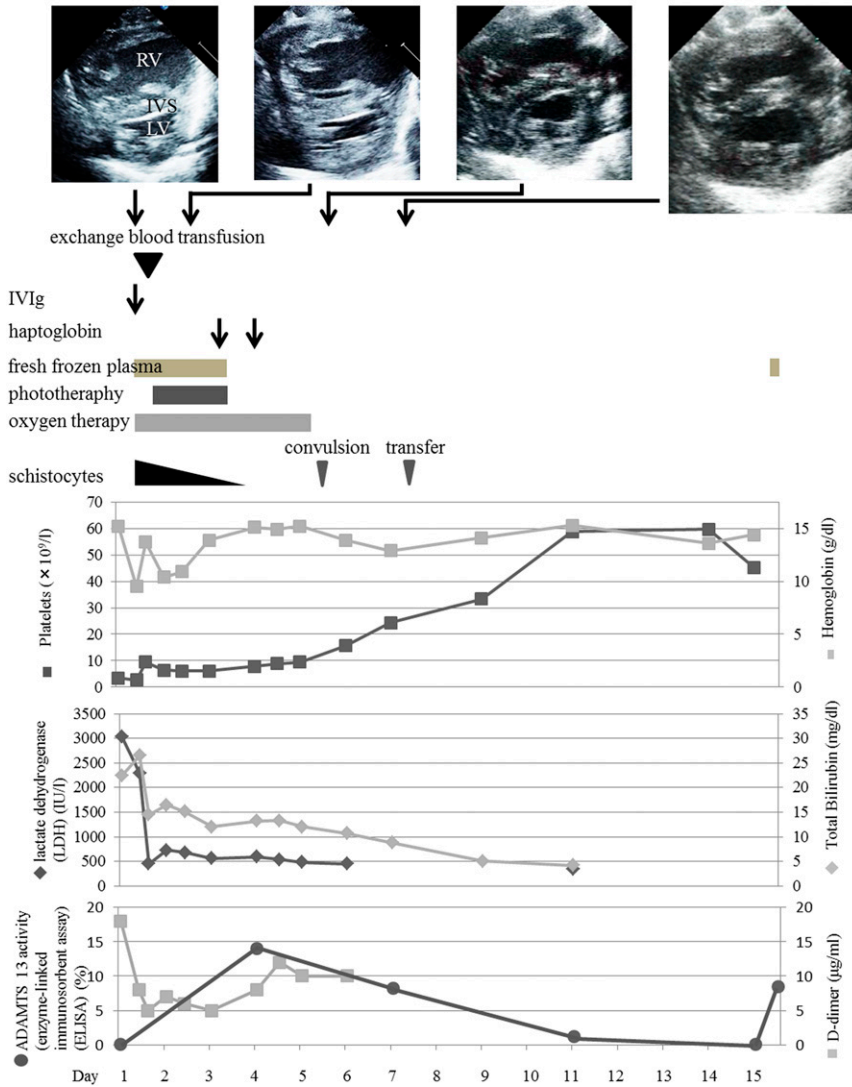


FIGURE 1

Clinical course and echocardiography findings. The upper panel shows TTE results. On days 1 and 3, the intraventricular septum (IVS) bows into the left ventricle (LV). This finding is not seen on days 5 and 7. IViG, intravenous immunoglobulin; RV, right ventricle.

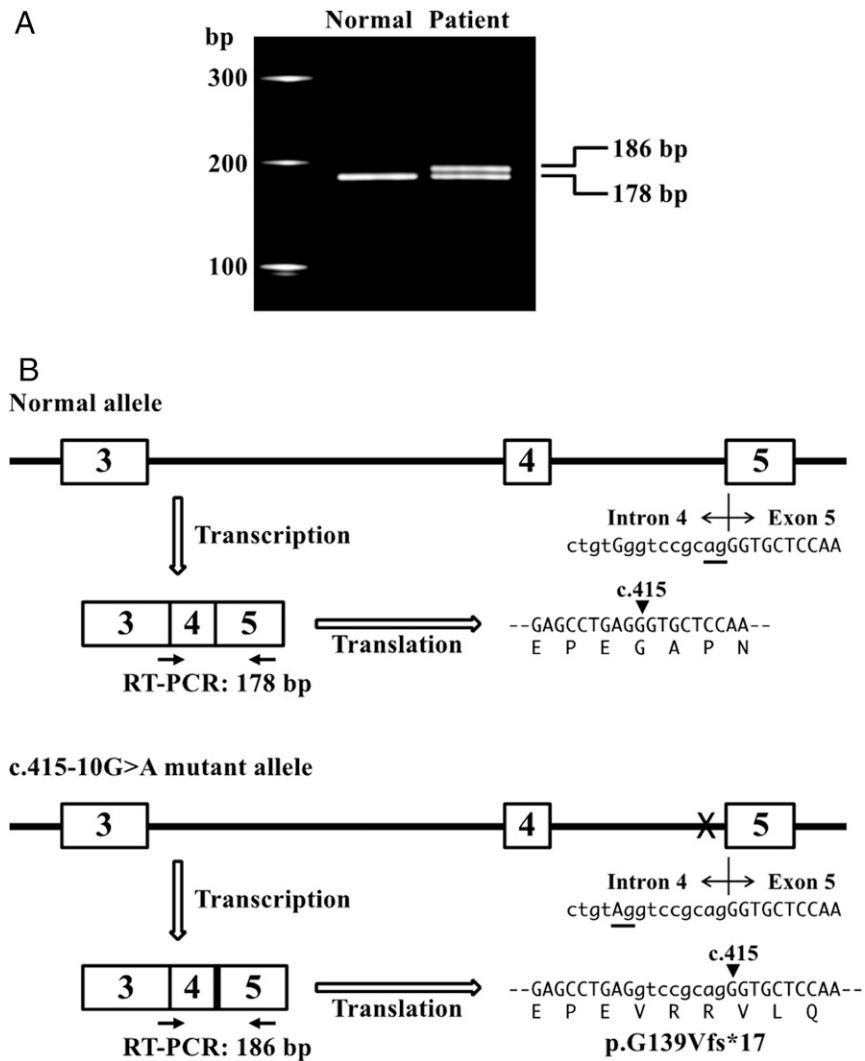


FIGURE 2

The c.415-10G>A mutation results in aberrant splicing. A, RT-PCR. The upper band (186 bp) was detected in patient RNA but not in normal subject RNA. B, the c.415-10G>A mutation resulted in a new splice acceptor site (underlined) and aberrant splicing, which caused the frame shift mutation.

Tsujii N, Shiraishi I, Kokame K, et al. Severe Hemolysis and Pulmonary Hypertension in a Neonate With Upshaw-Schulman Syndrome. *Pediatrics*. 2016;138(6):e20161565

Pediatrics 2017;139;

DOI: 10.1542/peds.2016-4105 originally published online February 28, 2017;

Updated Information & Services	including high resolution figures, can be found at: http://pediatrics.aappublications.org/content/139/3/e20164105
Subspecialty Collections	This article, along with others on similar topics, appears in the following collection(s): Administration/Practice Management http://www.aappublications.org/cgi/collection/administration:practice_management_sub
Permissions & Licensing	Information about reproducing this article in parts (figures, tables) or in its entirety can be found online at: http://www.aappublications.org/site/misc/Permissions.xhtml
Reprints	Information about ordering reprints can be found online: http://www.aappublications.org/site/misc/reprints.xhtml

American Academy of Pediatrics

DEDICATED TO THE HEALTH OF ALL CHILDREN®



PEDIATRICS®

OFFICIAL JOURNAL OF THE AMERICAN ACADEMY OF PEDIATRICS

Tsujii N, Shiraishi I, Kokame K, et al. Severe Hemolysis and Pulmonary Hypertension in a Neonate With Upshaw-Schulman Syndrome. *Pediatrics*. 2016;138(6):e20161565

Pediatrics 2017;139;

DOI: 10.1542/peds.2016-4105 originally published online February 28, 2017;

The online version of this article, along with updated information and services, is located on the World Wide Web at:

<http://pediatrics.aappublications.org/content/139/3/e20164105>

Pediatrics is the official journal of the American Academy of Pediatrics. A monthly publication, it has been published continuously since 1948. Pediatrics is owned, published, and trademarked by the American Academy of Pediatrics, 345 Park Avenue, Itasca, Illinois, 60143. Copyright © 2017 by the American Academy of Pediatrics. All rights reserved. Print ISSN: 1073-0397.

American Academy of Pediatrics

DEDICATED TO THE HEALTH OF ALL CHILDREN®

