

Topical Timolol Maleate Treatment of Infantile Hemangiomas

Katherine Püttgen, MD,^a Anne Lucky, MD,^b Denise Adams, MD,^b Elena Pope, MD,^c Catherine McCuaig, MD,^d Julie Powell, MD,^d Dana Feigenbaum, MD,^e Yulia Savva, PhD,^f Eulalia Baselga, MD,^g Kristen Holland, MD,^h Beth Drolet, MD,^h Dawn Siegel, MD,^h Kimberly D. Morel, MD,ⁱ Maria C. Garzon, MD,ⁱ Erin Mathes, MD,^e Christine Lauren, MD,^j Amy Nopper, MD,^j Kimberly Horii, MD,^j Brandon Newell, MD,^j Wei Song, MD,^k Ilona Frieden, MD,^e on behalf of the Hemangioma Investigator Group

abstract

BACKGROUND: There has been a dramatic increase in the off-label use of ophthalmic timolol maleate, a β -blocker used for infantile hemangioma (IH) treatment as a topical counterpart to oral propranolol. Its safety and efficacy in a pediatric population with IH have not been evaluated in a large cohort. Our goal was to retrospectively assess timolol's effectiveness, discern characteristics associated with response, and document reported adverse events.

METHODS: A multicenter retrospective cohort study of 731 patients treated with topical timolol was completed at 9 centers. Inclusion required an IH suitable for timolol in the treating physician's judgment and access to clinical details including photographs. Logistic regression analysis and descriptive statistics were performed. Primary outcome measures were efficacy assessed by using visual analog scales for color and for size, extent, and volume from review of digital photographs taken as standard of care.

RESULTS: Most IHs were localized (80.1%) and superficial (55.3%). Risk of disfigurement was the most common indication for therapy (74.3%). Duration of therapy ($P < .0001$), initial thinness ($P = .008$), and subtype ($P = .031$) were significant predictors of response. Best response occurred in superficial IHs <1 mm thick. Fifty-three (7.3%) required subsequent therapy with systemic β -blocker. Adverse events were mild, occurring in 25 (3.4%) patients. No cardiovascular side effects were documented.

CONCLUSIONS: Timolol seems to be a well-tolerated, safe treatment option with moderate to good effectiveness, demonstrating best response in thin, superficial IHs regardless of pretreatment size. Timolol can be recommended as an alternative to systemic β -blockers and watchful waiting for many patients.

FREE

^aJohns Hopkins School of Medicine, Baltimore, Maryland; ^bCincinnati Children's Hospital, Cincinnati, Ohio; ^cHospital for Sick Children, Toronto, Ontario, Canada; ^dSainte-Justine Hospital, Montréal, Québec, Canada; ^eUniversity of California, San Francisco, San Francisco, California; ^fJohns Hopkins Bloomberg School of Public Health, Baltimore, Maryland; ^gHospital de la Santa Creu i Sant Pau, Barcelona, Spain; ^hMedical College of Wisconsin, Milwaukee, Wisconsin; ⁱColumbia University, New York, New York; ^jChildren's Mercy Hospital, Kansas City, Missouri; and ^kChildren's Hospital of Fudan University, Shanghai, China

Dr Püttgen conceptualized and designed the study and the data collection instruments, conducted the initial analyses, and drafted the manuscript; Dr Lucky coordinated and participated in data collection and reviewed the manuscript; Dr Adams supervised data collection and reviewed the manuscript; Dr Pope provided feedback on the data collection instruments, coordinated and supervised data collection, and critically reviewed the manuscript; Dr McCuaig provided critical feedback on the data collection instruments, coordinated and supervised data collection, and critically reviewed the manuscript; Dr Powell contributed to data collection and critically reviewed the manuscript; Dr Feigenbaum tested and provided critical feedback on the data collection instruments and coordinated data collection; Dr Savva conducted the complex statistical analyses and reviewed and revised the manuscript; Drs Baselga, Morel, and Mathes coordinated and supervised data collection and critically reviewed the manuscript; Dr Holland

WHAT'S KNOWN ON THIS SUBJECT: β -Blocker therapy has revolutionized the treatment algorithm for infantile hemangiomas, but there is concern about potential overuse of propranolol. Off-label topical application of ophthalmic timolol maleate has been reported in small studies to be a potential alternative for problematic hemangiomas.

WHAT THIS STUDY ADDS: This large cohort shows that topical timolol maleate is a well-tolerated alternative to oral propranolol for selected hemangiomas, most effective for thin, superficial hemangiomas regardless of size. Greater improvement occurs in color than size. Longer treatment results in better response.

To cite: Püttgen K, Lucky A, Adams D, et al. Topical Timolol Maleate Treatment of Infantile Hemangiomas. *Pediatrics*. 2016;138(3):e20160355

The majority of infantile hemangiomas (IHs) proliferate, stabilize, and regress without the need for intervention beyond anticipatory guidance. However, in a significant minority, size or location may necessitate intervention to treat or prevent local disfigurement, functional impairment, or systemic complications. Oral propranolol is now approved by the US Food and Drug Administration for treating IHs that require intervention. Topical β -blockers, most commonly timolol maleate, are also reportedly effective for the treatment of less aggressive IHs, but many questions remain about their effectiveness and possible adverse effects.

The use of topical timolol maleate (TTM) for IH was first reported in 2010.¹ Since then, numerous case reports, case series, and 1 small randomized trial have reported largely encouraging results regarding its efficacy.²⁻⁷ Timolol maleate is a nonselective β -blocker readily available as an ophthalmic preparation as both a solution and gel-forming solution (GFS). It has been used for >3 decades in pediatric patients and is approved by the US Food and Drug Administration for the treatment of elevated intraocular pressure in children aged <6 years.⁸⁻¹⁰ In the 0.5% strength, 1 drop of medication contains 0.25 mg of timolol maleate. The systemic bioavailability of 1 intraocular drop (0.05 mL) of timolol maleate 0.5% solution is variable but may be as high as 80%.¹¹ There is very limited information regarding off-label safety and pharmacokinetic data when used on hemangioma-affected skin.^{12,13} The 8- to 10-fold increased potency of timolol maleate compared with that of propranolol^{14,15} raises concern for potential systemic toxicity from topical therapy.

To address knowledge gaps, particularly in better understanding the efficacy, clinical predictors of response, and tolerability of TTM

in treating IHs, we conducted a multicenter retrospective cohort study at 9 pediatric dermatology and vascular anomalies referral centers.

METHODS

This study was a retrospective multicenter cohort study conducted by the Hemangioma Investigator Group at 9 pediatric dermatology and vascular anomalies centers in the United States, Canada, and Spain from January to November 2014. The research was approved by the Johns Hopkins University Institutional Review Board, the study site of the principal investigator, and by the local institutional review boards at each participating site. Inclusion criteria required that a patient have an IH deemed a candidate for TTM by a physician with expertise in vascular anomalies, along with de-identified demographic information, details of the IH, and treatment course. Minimum treatment duration for study inclusion was 30 days. Exclusion criteria included lack of a baseline photograph and/or lack of at least 1 follow-up visit with clinical data and photograph. Study data were de-identified and collected and managed by using the Research Electronic Data Capture tools hosted at Johns Hopkins University.¹⁶

Demographic information, details on TTM formulation and dosing, IH characteristics, details on treatment course, and adverse events (AEs) were recorded. Vital signs (including heart rate and blood pressure) were obtained at the discretion of the treating physician but were not routinely performed at each follow-up visit. Primary outcome measures were treatment response as assessed by using visual analog scales for color (VAS-C) and visual analog scales for size, extent, and volume (VAS-SEV), with scores ranging from -100 to 100.

Each site investigator reviewed all available digital photographs of the

IHs obtained as standard of care comparing the IH at time of initiation (baseline assessment) versus the IH at time of each follow-up evaluation. Two VAS measurements were recorded for each patient at each time point compared with baseline photographs. The VAS-SEV was designed to encompass overall change in size, extent, and volume of the IH such that -100 corresponded to a doubling in size and 100 to complete resolution. The VAS-C captured change in intensity of IH color in which -100 signified doubling in intensity of color and 100 to complete lack of discoloration compared with the surrounding skin. A change $\geq 10\%$ in VAS-C or VAS-SEV score from baseline was deemed the minimum threshold of meaningful response.

Statistical Analysis

Descriptive statistics were used to detail baseline characteristics of patients and IHs and are presented as percentages and means. The time of follow-up visits among the cohort was not uniform, and follow-up time points were grouped as occurring between 1 and 3 months after initiation of timolol (mean, 2-month follow-up), between 3 and 6 months (mean, 4.5-month follow-up), between 6 and 9 months (mean, 7.5-month follow-up), and >9 months since initiation of TTM. A mixed effects model with autoregressive structure, to allow for unequally spaced time points, was used to test the relationship between the treatment response, measured as VAS-SEV and VAS-C over time. The model was selected by using the likelihood ratio test. The within-subject error term was modeled by using an exponential correlation model. In evaluating the effect of baseline IH parameters on treatment response over time, each independent variable was tested by using univariate and multivariate mixed effects models. Post hoc

comparisons were used to test if there were significant differences between groups of the independent variables at each time interval. AEs were analyzed with univariate logistic regressions to estimate the odds ratios. SEs were adjusted for nonindependence. Fisher's exact test with 2-tailed *P* values were used to analyze categorical data. The significance level was set at 5%. Analysis was performed by using Stata version 12.1 (StataCorp LP, College Station, TX).

RESULTS

There were 731 subjects, with a female predominance (2.65:1 ratio.) The majority ($n = 284$ [41.2%]) were <3 months old at the initiation of treatment. Most ($n = 598$ [86.3%]) were treatment naive before initiation of TTM. The vast majority of IHs ($n = 582$ [80.1%]) were located on the head and neck. Localized IHs were present in 572 (80.1%); 80 (11.2%) were segmental, and 62 (8.7%) were of indeterminate morphology. Most IHs were superficial ($n = 405$ [56.1%])¹⁷ (Table 1). The most common indication for TTM was perceived risk of disfigurement by the treating physician ($n = 544$ [73.3%]), followed by risk of ulceration ($n = 138$ [18.9%]) and risk to vision and/or periocular location ($n = 92$ [12.6%]). Forty-one (5.6%) patients had ulceration present before starting TTM; 4 patients developed ulceration while using TTM (Table 2). Nearly one-half ($n = 362$ [49.5%]) had completed TTM therapy at the time of inclusion in the study. Mean treatment duration at the time of study inclusion was 9.47 months. Most patients received timolol maleate 0.5% GFS ($n = 615$ [85.1%]) with instructions to apply 1 drop twice daily to the IH surface ($n = 591$ [83.5%]). A daily total of ≥ 4 drops of timolol maleate were prescribed in 106 (15.0%) patients of the group.

TABLE 1 Patient and IH Characteristics

Characteristic	Value
Patients, <i>N</i> = 731	
Sex	
Female	530 (72.6)
Male	200 (27.4)
Age at TTM initiation, mo	
0–3	284 (41.2)
3–6	199 (28.8)
6–9	80 (11.6)
9–12	37 (5.4)
>12	90 (13.0)
Previous therapy	
Yes	95 (13.7)
No	598 (86.3)
Mean treatment duration, mo	9.47
IHs	
Location (no. of patients = 727)	
Head and neck	582 (80.1)
Body	145 (19.9)
Morphology (no. of patients = 714)	
Localized	572 (80.1)
Segmental ^a	80 (11.2) [2 PHACE ^b , 1 LUMBAR ^c]
Indeterminate ^d	62 (8.7)
IH subtype (no. of patients = 722)	
Superficial	
<1 mm thick	405 (56.1)
1–3 mm thick	139 (34.8)
>3 mm thick	171 (42.9)
Deep	89 (22.3)
Deep	28 (3.9)
Combined/mixed	
Mainly superficial	289 (40.0)
Equally superficial and deep	96 (33.6)
Mainly deep	85 (29.7)
Mainly deep	105 (36.7)

Unless otherwise indicated, values are given as *n* (%).

^a Segmental IHs are those that encompass a patterned, geographic, and often broad territory of skin involvement and are more likely to be associated with systemic abnormalities and complications.

^b Posterior fossa malformation, hemangioma, arterial anomalies, coarctation of aorta, and eye abnormalities.

^c Lower body hemangioma and other cutaneous defects, urogenital anomalies, ulceration, myelopathy, bony deformities, anorectal malformations, arterial anomalies, and renal anomalies.

^d Indeterminate IHs are those thought to represent a small portion of a defined segmental pattern.

TABLE 2 Adverse Events

AEs	No. of Patients With AEs (<i>n</i> = 25 [3.4%]) ^a
Local irritation from medication (eg, scaling)	12
Developed ulcer	4
Bronchospasm	3
Dermatitis at application site	1
Ocular	
Asymmetric pupil size	1
Possible heterochromia	1
Tan macule in iris	1
Eye infection/drainage	1
Other	
Frequent URTI	1
Maceration	1

URT, upper respiratory tract infection.

^a 26 AEs occurred in 25 patients.

Clinical Response to TTM

Responses to TTM are summarized in Table 3 and Figs 1 and 2. At all

ages and durations of treatment, greater responses were seen in VAS-C than in VAS-SEV. With the mixed effects model, at least a 13.3%

greater degree of improvement in VAS-C compared with VAS-SEV occurred at each time point (Fig 1). The proportion of IHs that achieved a meaningful response to timolol maleate (defined as a $\geq 10\%$ change in VAS from baseline) at each follow-up interval is detailed in Table 3. After 1 to 3 months of TTM therapy, 69.6% of patients experienced $\geq 10\%$ improvement from baseline in VAS-C with a mean improvement score of 31.2; 24.0% had no meaningful change from baseline and 6.4% worsened. Improvement in VAS-SEV occurred in 38.8% of patients, 48.0% had no meaningful change from baseline, and 13.2% worsened during this period. After 6 to 9 months of therapy, VAS-C demonstrated meaningful improvement from baseline in 92.3% of patients, 6.0% had no meaningful change, and 1.7% worsened, compared with VAS-SEV improvement in 76.6%, no change in 18.1%, and worsening in 5.4%. In patients aged <3 months at the start of TTM therapy (ie, during the rapid proliferative phase of IH growth), a similar but less dramatic response was noted. Among the 210 infants aged <3 months at the start of treatment who had follow-up data after a mean of 2 months of treatment, VAS-C improved from baseline in 133 (63.3%), was unchanged in 57 (27.1%), and worsened in 20 (9.5%), compared with VAS-SEV improvement in 71 (33.8%), no change in 96 (45.7%), and worsening in 43 (20.5%).

The mixed effects model also demonstrated a significant linear relationship between both VAS-C and time (95% confidence interval [CI], 3.45–4.28; $P < .0001$) and VAS-SEV and time (95% CI, 3.11–4.46; $P < .0001$), illustrating that longer duration of TTM use significantly improved treatment response. An increase in treatment duration by 1 month improved the VAS-C by 3.9% and VAS-SEV by 3.8%. When

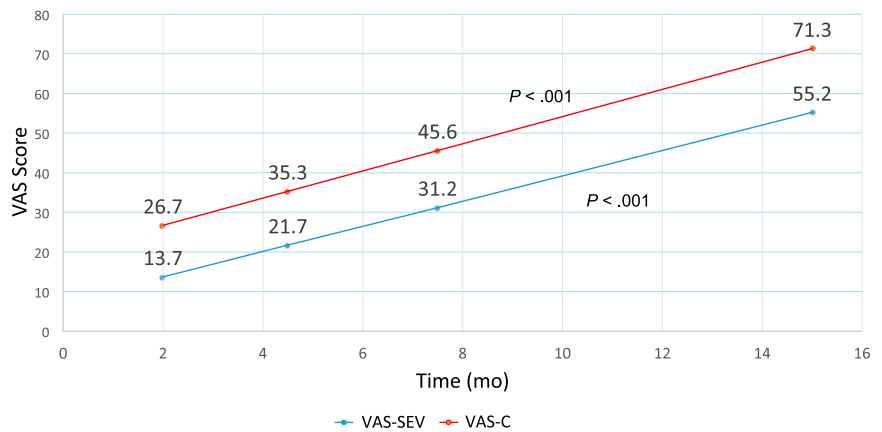


FIGURE 1
VAS scores for size and color over time.

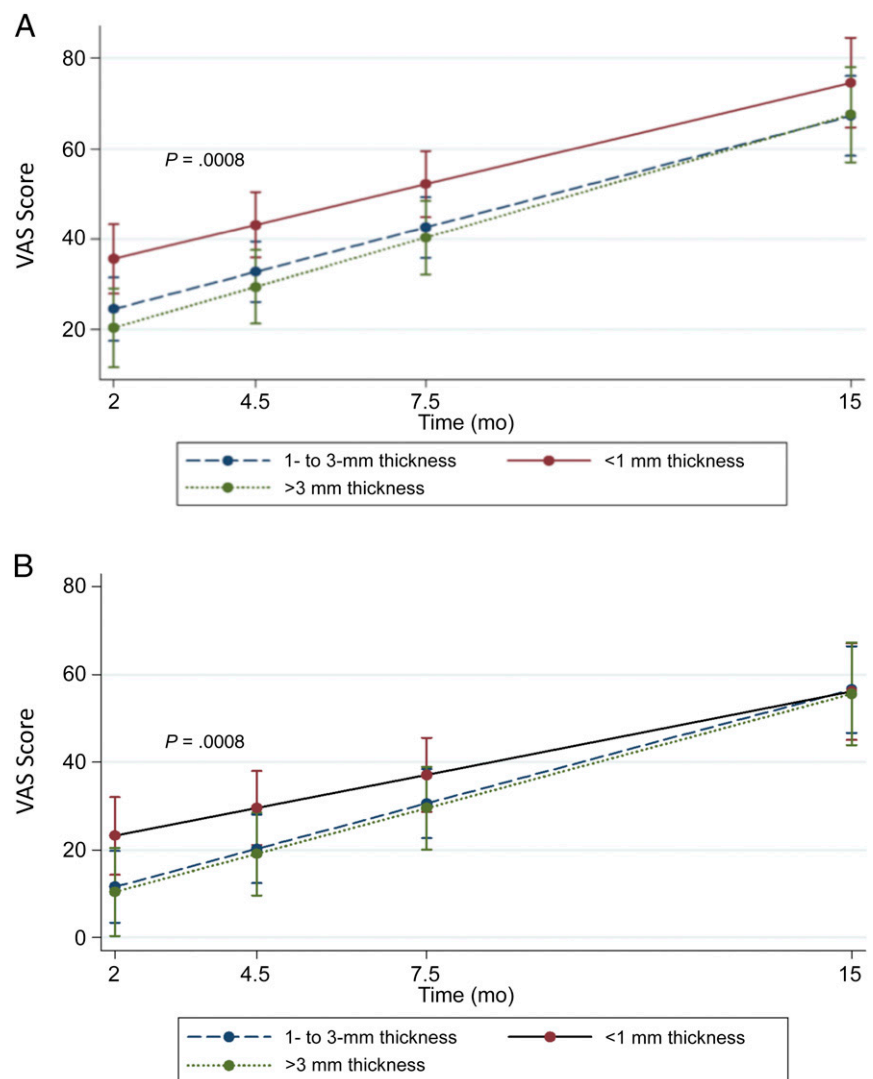


FIGURE 2
(A) Clinical response to timolol maleate in infantile hemangioma color (VAS-C score) over time and (B) clinical response to TTM in infantile hemangioma size, extent, and volume (VAS-SEV score) over time.

TABLE 3 Clinical Response to TTM Relative to Baseline

Time Frame	VAS-C						VAS-SEV											
	Improved			No Change			Worsened			Improved			No Change			Worsened		
	No. of Patients	Mean VAS-C	%	No. of Patients	Mean VAS-C	%	No. of Patients	Mean VAS-C	%	No. of Patients	Mean VAS-SEV	%	No. of Patients	Mean VAS-SEV	%	No. of Patients	Mean VAS-SEV	%
1 to 3 mo (n = 454)	316	31.18	69.6	109	2.95	24.0	29	-23.15	6.4	176	31.93	38.8	218	1.24	48.0	60	-25.13	13.2
3 to 6 mo (n = 459)	412	44.06	89.8	34	3.88	7.4	13	-28.92	2.8	298	48.29	64.9	130	1.34	28.3	31	-23.42	6.8
6 to 9 mo (n = 299)	276	56.36	92.3	18	1.44	6.0	5	-23.6	1.7	229	49.67	76.6	54	0.78	18.1	16	-23	5.4
>9 mo (n = 202)	195	69.72	96.5	4	2	2.0	3	-26.67	1.5	181	61.22	89.6	16	1.25	7.9	5	-34	2.5

≥10% change in VAS from baseline defined as threshold for meaningful clinical response.

evaluating the entire cohort for the extent of response to timolol maleate for VAS-C, the mean VAS-C responses for the group were 25.1, 34.8, 46.4, and 71.5 at months 1 to 3, 3 to 6, 6 to 9, and >9 months of therapy, respectively. Similarly, the mean response for VAS-SEV was 11.7, 21.1, 32.4, and 57 at months 1 to 3, 3 to 6, 6 to 9, and >9 months of therapy.

Univariate and multivariate mixed effects models showed that initial IH thinness was a significant predictor of response to TTM for both VAS-C ($P = .008$) and VAS-SEV ($P = .008$) (Figs 2A and 2B, respectively). After 1 to 3 months of TTM treatment, response was significantly better for VAS-SEV in IHS <1 mm thick compared with IHS 1 to 3 mm thick ($P = .005$) and IHS >3 mm thick ($P = .005$). Although IHS <1 mm thick demonstrated the best response at 1 to 3, 3 to 6, and 6 to 9 months, response according to thickness was no longer significant beyond 9 months of therapy, and thicker IHS (1–3 mm and >3 mm) began to show response rates that were not significantly different from those of the thinnest lesions. Outcomes for both VAS-C and VAS-SEV were significantly affected by IH subtype ($P = .03$ and $P = .04$, respectively), with better responses seen in superficial IHS compared with mixed and deep IHS. VAS-C and VAS-SEV responses were not affected by initial IH size (in square centimeters); localized, segmental, or indeterminate morphology; the presence of ulceration before treatment; location; or pedunculated versus sessile appearance.

Additional therapy with an oral β -blocker (ie, propranolol [$n = 50$] or nadolol [$n = 3$]) was initiated after TTM treatment in 7.3% of the cohort. Age <3 months at the start of TTM ($P < .0001$), deep IHS ($P = .0005$), and mixed IHS ($P = .03$) were strongly associated with an increased need for systemic β -blocker therapy. Surgery, pulsed dye laser, and/or wound care for ulceration was given after TTM

in 46 (6.3%) patients. Reasons cited for use of additional therapy included continued growth (34 patients), persistent volume ($n = 41$), persistent color ($n = 34$), and ulceration ($n = 13$.)

AEs were noted in 25 (3.4%) patients, with local irritation (eg, scaling) accounting for nearly one-half of AEs (Table 2). No cardiovascular AEs were recorded. Three patients experienced bronchospasm. No patient or IH characteristics were found to be associated with increased risk of AEs. The odds of experiencing an AE were 0.036 ($P < .0001$). No AEs were significant enough to require drug discontinuation.

DISCUSSION

This study is the largest to date examining efficacy and AEs with TTM in the treatment of IHs. The response in this retrospective cohort confirms much of the information in previous small studies and provides a more detailed understanding of the effectiveness of this agent in routine clinical practice. All children were prescribed TTM by physicians experienced in IH management; as such, the results detail a cohort preselected to have a greater likelihood of response to topical therapy, most typically younger patients with more superficial IHs. The onset of TTM's effect was more gradual and modest than that typically seen with systemic β -blockers. Nonetheless, these positive responses were likely medication-related rather than due to the IH natural history of slow spontaneous involution, because the largest group of treated infants were young at initiation of treatment (<3 months of age), a time when IH involution would not be expected.^{18,19} Timing of intervention is particularly important for those IHs requiring treatment, a point emphasized in recently published guidelines by a European consensus group.¹⁹ They stressed that frequency of reevaluations should be dictated by the age of the infant, as often as 1 to 2

weeks for the very youngest infants. Because most IHs were localized and superficial, investigators used topical therapy as an initial alternative to systemic therapy or watchful waiting. Seventy percent of patients were <6 months of age at the initiation of therapy, with 41.2% in the early proliferative phase, between 0 and 3 months of age. These factors strongly support the effectiveness of TTM, especially at the first 2 follow-up time points, in halting IH proliferation and inducing involution earlier than would be expected based on natural history (ie, when improvement would not typically occur before 12 months of age).^{18,20,21}

Because most growth observed in IHs is in tumor thickness rather than width, assessment of IH progression or regression has proven difficult with standard methods of measurement. This scenario is especially true for small and uncomplicated IHs. Therefore, investigators have developed several scales to assess IH growth and efficacy of treatment. All available scales are based on a shared concept of visual changes (progression or regression) at the determined end point compared with baseline or time zero and aim to convert subjective improvement or worsening into quantitative measures. Although the VAS is not a validated measure of IH response, it has been used in multiple IH studies^{3,22-26} and can be viewed as corresponding to a percent change from baseline (0 on the VAS.) VAS-SEV was chosen over lesion size measurement or other metrics because, as shown in other studies, size per se is not an accurate measurement of IH response to therapy.²⁷ Based on the VAS-C and VAS-SEV responses in this cohort, the anticipated decrease in color in patients with localized, superficial, relatively thin IHs treated with TTM after 2 months was ~25% improved from baseline. A similar degree of improvement in size, extent, and volume would be anticipated in

~30% of similar IH types after 6 and 9 months (Fig 1). Although this degree of improvement is modest compared with the dramatic responses often seen with propranolol,^{27,28} it nonetheless represents an amount of improvement sufficient to constitute a treatment success in many patients, particularly in young infants when IHs are in the rapid proliferative phase. Our results clearly show a greater effectiveness in the diminution of color over size, extent, and volume, although with duration of therapy beyond 9 months, 2 overlapping phenomena likely occur: TTM slowly improves thicker IHs with prolonged use and improvement from natural involution begins to occur.

Although our study provides convincing data regarding the effectiveness and overall safety of timolol for IH therapy, the strength of its conclusions is limited by its retrospective design, lack of regular follow-up intervals, pharmacokinetic data, and standardized AE surveillance, including rigorous monitoring for heart rate and blood pressure. Our study lacks a control group, but extensive data are available in the literature that characterize the timing of IH growth and involution. Eighty percent of final IH size is reached in the early proliferative phase (3.2 ± 1.7 months of age).¹⁷ Involution is generally anticipated to begin after 1 year of age and is typically completed by 3.5 to 4 years of age.¹⁸ Our results showing improvements in color and size at a much younger age diverge from this known natural history, strongly supporting the efficacy of timolol in preselected patients.

The present study was performed without funding support for regular office visits, and follow-up intervals for each patient were determined by the treating physician. Although a large prospective study would have been preferable, it is unlikely to occur in the near future for use of an inexpensive medication readily

available in generic form, which is already being used widely for this condition. In the absence of such data, our results offer important information for practicing clinicians to offer guidance regarding appropriate patient selection and expected response to TTM therapy. As with all studies on IHs, it suffers from the lack of a validated measure of treatment response.

No patients were discontinued due to AEs. No pretreatment characteristics of patients or their IHs were associated with AEs. The risks of ulceration, existing ulceration, or threat to vision were indications for treatment in nearly one-third of this cohort. Given the greater absorption of timolol maleate across nasolacrimal mucosa,^{15,29} there is a legitimate concern for potential greater absorption and bioavailability in IHs located on mucosal, ulcerated, or in occluded sites. Timolol maleate is metabolized by cytochrome P450 2D6, and poor metabolizers have been shown to have higher peak plasma concentrations and a longer elimination half-life with intraocular administration of timolol maleate.^{30,31} These findings suggest that children with low cytochrome P450 2D6 activity may be at greater risk for cardiovascular effects and may also represent some of the best responders because of greater sensitivity to the therapeutic effects of the drug. Although we found no evidence of systemic toxicity in the setting of ulcerated IHs in this study, the number of such patients in our report was low. Therefore, it cannot be concluded that TTM use in the setting of ulceration is uniformly safe. In the absence of further pharmacokinetic or controlled clinical trials, we favor caution in using TTM on ulcerated IHs, in mucosal sites, in the diaper area, in very young infants (ie, those <4 weeks corrected gestational age), or in those with other serious medical comorbidities, including ongoing or recent history of apnea and bradycardia who may have more potential for AEs.

We favor generally limiting therapy to 1 drop at each application no more

than 2 to 3 times a day, regardless of IH size, instructing caregivers to massage the medication into the IH. In larger IHs, rotational therapy (varying the site of TTM application within the IH) might be considered, but as size increases beyond that which would reasonably be covered by 1 drop, systemic therapy should be increasingly considered. Most of the investigators favor use of GFS because its more viscous texture allows increased ease of application at the desired site and possible lower systemic absorption relative to the solution; it must be noted, however, that the pharmacokinetic properties of the TTM GFS and solution on hemangioma-affected skin remain unknown. The 3 patients who experienced bronchospasm are too small a group to comment with any statistical validity on predictive factors for bronchospasm. All were >3 months of age; had small, localized IHs on the face; and were instructed to apply 1 drop twice daily of timolol 0.5% GFS ($n = 2$) or solution ($n = 1$) and were not receiving systemic β -blockers at the time of timolol therapy.

As experience with the use of β -blockers for IH treatment progresses and the options for systemic or local drug delivery expand, the management of children requiring therapy becomes more nuanced and individualized. TTM is a useful treatment option for many infants who might benefit from therapy but for whom oral β -blockers are not deemed appropriate. This retrospective study of >700 patients provides pragmatic data for patient selection, identifying which IHs can be managed with topical therapy and which are more likely to require systemic therapy. Superficial, relatively thin IHs, regardless of pretreatment surface area or body site, are likely to respond reasonably well to several months of treatment with modest, but definite, improvements in color and size. Thicker, superficial, mixed, and deep IHs may respond³² but are less likely to do so. There is a

window of opportunity for IHs during a critical period of early rapid growth to intervene and prevent potential permanent disfigurement (eg, atrophy, scarring, textural changes) and, particularly on the face, distortion of anatomic structures such as the nose and lips.

CONCLUSIONS

Primary care physicians and specialists caring for infants with IHs must be mindful of the nonlinear IH growth trajectory^{20,33} to determine whether watchful waiting, TTM, or systemic therapy is indicated. Young infants with IHs, particularly infants aged <3 months, have a high risk of accelerated hemangioma growth that can potentially result in permanent and disfiguring scarring.^{19,33} In preselected patients with smaller and relatively superficial IHs, TTM seems to be a safe and effective therapy to help control IH growth and accelerate involution. Parents should be advised to contact their physician if rapid growth occurs despite topical treatment because transition to systemic therapy may be more appropriate in some cases. TTM can be recommended as an initial, and often sole, treatment modality for many relatively superficial IHs without aggressive growth or threat of functional impairment.

ACKNOWLEDGMENTS

The authors acknowledge Margaret Dowd, BBA, for her significant contribution to data entry efforts.

ABBREVIATIONS

AE: adverse event
CI: confidence interval, GFS, gel-forming solution
IH: infantile hemangioma
TTM: topical timolol maleate
VAS: visual analog scale
VAS-C: visual analog scale for color
VAS-SEV: visual analog scale for size, extent, volume

provided critical feedback on the data collection instruments, coordinated and supervised data collection, and critically reviewed the manuscript; Drs Drolet, Siegel, Nopper, Horii, and Newell coordinated data collection and critically reviewed the manuscript; Dr Garzon critically reviewed and revised the manuscript; Drs Lauren and Song coordinated data collection and reviewed the manuscript; Dr Frieden conceptualized and designed the study, provided critical feedback on the data collection instruments, and critically reviewed and revised the manuscript; and all authors approved the final manuscript as submitted and agree to be accountable for all aspects of the work.

DOI: 10.1542/peds.2016-0355

Accepted for publication Jun 20, 2016

Address correspondence to Katherine Püttgen, MD, Johns Hopkins University School of Medicine, Department of Dermatology, 200 N. Wolfe St, Unit 2107, Baltimore, MD 21287. E-mail: kateputtgen@jhmi.edu

PEDIATRICS (ISSN Numbers: Print, 0031-4005; Online, 1098-4275).

Copyright © 2016 by the American Academy of Pediatrics

FINANCIAL DISCLOSURE: Drs Baselga, Frieden, McCuaig, Püttgen, and Pope have served as consultants to Pierre Fabre; the other authors have indicated they have no financial relationships relevant to this article to disclose.

FUNDING: No external funding.

POTENTIAL CONFLICT OF INTEREST: Drs. Baselga, Frieden, McCuaig, Püttgen, and Pope have served as consultants to Pierre Fabre; the other authors have indicated they have no potential conflicts of interest to disclose.

REFERENCES

1. Guo S, Ni N. Topical treatment for capillary hemangioma of the eyelid using beta-blocker solution. *Arch Ophthalmol*. 2010;128(2):255–256
2. Ni N, Langer P, Wagner R, Guo S. Topical timolol for periocular hemangioma: report of further study. *Arch Ophthalmol*. 2011;129(3):377–379
3. Pope E, Chakkittakandiyil A. Topical timolol gel for infantile hemangiomas: a pilot study. *Arch Dermatol*. 2010;146(5):564–565
4. Chakkittakandiyil A, Phillips R, Frieden IJ, et al. Timolol maleate 0.5% or 0.1% gel-forming solution for infantile hemangiomas: a retrospective, multicenter, cohort study. *Pediatr Dermatol*. 2012;29(1):28–31
5. Moehrle M, Léauté-Labrèze C, Schmidt V, Röcken M, Poets C-F, Goelz R. Topical timolol for small hemangiomas of infancy. *Pediatr Dermatol*. 2013;30(2):245–249
6. Chambers CB, Katowitz WR, Katowitz JA, Binenbaum G. A controlled study of topical 0.25% timolol maleate gel for the treatment of cutaneous infantile capillary hemangiomas. *Ophthalm Plast Reconstr Surg*. 2012;28(2):103–106
7. Chan H, McKay C, Adams S, Wargon O. RCT of timolol maleate gel for superficial infantile hemangiomas in 5- to 24-week-olds. *Pediatrics*. 2013;131(6). Available at: www.pediatrics.org/cgi/content/full/131/6/e1739
8. McMahon CD, Hetherington J Jr, Hoskins HD Jr, Shaffer RN. Timolol and pediatric glaucomas. *Ophthalmology*. 1981;88(3):249–252
9. Plager DA, Whitson JT, Netland PA, et al; BETOPTIC S Pediatric Study Group. Betaxolol hydrochloride ophthalmic suspension 0.25% and timolol gel-forming solution 0.25% and 0.5% in pediatric glaucoma: a randomized clinical trial. *J AAPOS*. 2009;13(4):384–390
10. Chang L, Ong EL, Bunce C, Brookes J, Papadopoulos M, Khaw PT. A review of the medical treatment of pediatric glaucomas at Moorfields Eye Hospital. *J Glaucoma*. 2013;22(8):601–607
11. Korte JM, Kaila T, Saari KM. Systemic bioavailability and cardiopulmonary effects of 0.5% timolol eyedrops. *Graefes Arch Clin Exp Ophthalmol*. 2002;240(6):430–435
12. Zhang Q, Chantasart D, Li SK. Evaluation of β -blocker gel and effect of dosing volume for topical delivery. *J Pharm Sci*. 2015;104(5):1721–1731
13. Chantasart D, Hao J, Li SK. Evaluation of skin permeation of β -blockers for topical drug delivery. *Pharm Res*. 2013;30(3):866–877
14. Singh BN, Williams FM, Whitlock RM, Collett J, Chew C. Plasma timolol levels and systolic time intervals. *Clin Pharmacol Ther*. 1980;28(2):159–166
15. McMahon P, Oza V, Frieden IJ. Topical timolol for infantile hemangiomas: putting a note of caution in “cautiously optimistic”. *Pediatr Dermatol*. 2012;29(1):127–130
16. Harris PA, Taylor R, Thielke R, Payne J, Gonzalez N, Conde JG. Research electronic data capture (REDCap)—a metadata-driven methodology and workflow process for providing translational research informatics support. *J Biomed Inform*. 2009;42(2):377–381
17. Chang LC, Haggstrom AN, Drolet BA, et al; Hemangioma Investigator Group. Growth characteristics of infantile hemangiomas: implications for management. *Pediatrics*. 2008;122(2):360–367
18. Couto RA, Maclellan RA, Zurakowski D, Greene AK. Infantile hemangioma: clinical assessment of the involuting phase and implications for management. *Plast Reconstr Surg*. 2012;130(3):619–624
19. Hoeger PH, Harper JI, Baselga E, et al. Treatment of infantile haemangiomas: recommendations of a European expert group. *Eur J Pediatr*. 2015;174(7):855–865
20. Luu M, Frieden IJ. Haemangioma: clinical course, complications and management. *Br J Dermatol*. 2013;169(1):20–30
21. Bauland CG, Lüning TH, Smit JM, Zeebregts CJ, Spauwen PH. Untreated hemangiomas: growth pattern and residual lesions. *Plast Reconstr Surg*. 2011;127(4):1643–1648

22. Pope E, Chakkittakandiyil A, Lara-Corrales I, Maki E, Weinstein M. Expanding the therapeutic repertoire of infantile haemangiomas: cohort-blinded study of oral nadolol compared with propranolol. *Br J Dermatol*. 2013;168(1):222–224
23. Balma-Mena A, Chakkittakandiyil A, Weinstein M, et al. Propranolol in the management of infantile hemangiomas: clinical response and predictors. *J Cutan Med Surg*. 2012;16(3):169–173
24. Bertrand J, McCuaig C, Dubois J, Hatami A, Ondrejchak S, Powell J. Propranolol versus prednisone in the treatment of infantile hemangiomas: a retrospective comparative study. *Pediatr Dermatol*. 2011;28(6):649–654
25. Malik MA, Menon P, Rao KL, Samujh R. Effect of propranolol vs prednisolone vs propranolol with prednisolone in the management of infantile hemangioma: a randomized controlled study. *J Pediatr Surg*. 2013;48(12):2453–2459
26. Zvulunov A, McCuaig C, Frieden IJ, et al. Oral propranolol therapy for infantile hemangiomas beyond the proliferation phase: a multicenter retrospective study. *Pediatr Dermatol*. 2011;28(2):94–98
27. Léauté-Labrèze C, Hoëger P, Mazereeuw-Hautier J, et al. A randomized, controlled trial of oral propranolol in infantile hemangioma. *N Engl J Med*. 2015;372(8):735–746
28. Léauté-Labrèze C, Dumas de la Roque E, Hubiche T, Boralevi F, Thambo JB, Taïeb A. Propranolol for severe hemangiomas of infancy. *N Engl J Med*. 2008;358(24):2649–2651
29. Shedden A, Laurence J, Tipping R; Timoptic-XE 0.5% Study Group. Efficacy and tolerability of timolol maleate ophthalmic gel-forming solution versus timolol ophthalmic solution in adults with open-angle glaucoma or ocular hypertension: a six-month, double-masked, multicenter study. *Clin Ther*. 2001;23(3):440–450
30. Nieminen T, Lehtimäki T, Mäenpää J, Ropo A, Uusitalo H, Kähönen M. Ophthalmic timolol: plasma concentration and systemic cardiopulmonary effects. *Scand J Clin Lab Invest*. 2007;67(2):237–245
31. Shedden AH, Laurence J, Barrish A, Olah TV. Plasma timolol concentrations of timolol maleate: timolol gel-forming solution (TIMOPTIC-XE) once daily versus timolol maleate ophthalmic solution twice daily. *Doc Ophthalmol*. 2001;103(1):73–79
32. Sorrell J, Chamlin SL. Topical timolol 0.5% gel-forming solution for small deep facial infantile hemangiomas. *Pediatr Dermatol*. 2013;30(5):592–594
33. Tollefson MM, Frieden IJ. Early growth of infantile hemangiomas: what parents' photographs tell us. *Pediatrics*. 2012;130(2). Available at: www.pediatrics.org/cgi/content/full/130/2/e314

Topical Timolol Maleate Treatment of Infantile Hemangiomas

Katherine Püttgen, Anne Lucky, Denise Adams, Elena Pope, Catherine McCuaig, Julie Powell, Dana Feigenbaum, Yulia Savva, Eulalia Baselga, Kristen Holland, Beth Drolet, Dawn Siegel, Kimberly D. Morel, Maria C. Garzon, Erin Mathes, Christine Lauren, Amy Nopper, Kimberly Horii, Brandon Newell, Wei Song, Ilona Frieden and on behalf of the Hemangioma Investigator Group

Pediatrics 2016;138;

DOI: 10.1542/peds.2016-0355 originally published online August 15, 2016;

Updated Information & Services	including high resolution figures, can be found at: http://pediatrics.aappublications.org/content/138/3/e20160355
References	This article cites 28 articles, 3 of which you can access for free at: http://pediatrics.aappublications.org/content/138/3/e20160355#BIBL
Subspecialty Collections	This article, along with others on similar topics, appears in the following collection(s): Dermatology http://www.aappublications.org/cgi/collection/dermatology_sub Pharmacology http://www.aappublications.org/cgi/collection/pharmacology_sub Therapeutics http://www.aappublications.org/cgi/collection/therapeutics_sub
Permissions & Licensing	Information about reproducing this article in parts (figures, tables) or in its entirety can be found online at: http://www.aappublications.org/site/misc/Permissions.xhtml
Reprints	Information about ordering reprints can be found online: http://www.aappublications.org/site/misc/reprints.xhtml

American Academy of Pediatrics

DEDICATED TO THE HEALTH OF ALL CHILDREN®



PEDIATRICS®

OFFICIAL JOURNAL OF THE AMERICAN ACADEMY OF PEDIATRICS

Topical Timolol Maleate Treatment of Infantile Hemangiomas

Katherine Püttgen, Anne Lucky, Denise Adams, Elena Pope, Catherine McCuaig, Julie Powell, Dana Feigenbaum, Yulia Savva, Eulalia Baselga, Kristen Holland, Beth Drolet, Dawn Siegel, Kimberly D. Morel, Maria C. Garzon, Erin Mathes, Christine Lauren, Amy Nopper, Kimberly Horii, Brandon Newell, Wei Song, Ilona Frieden and on behalf of the Hemangioma Investigator Group

Pediatrics 2016;138;

DOI: 10.1542/peds.2016-0355 originally published online August 15, 2016;

The online version of this article, along with updated information and services, is located on the World Wide Web at:

<http://pediatrics.aappublications.org/content/138/3/e20160355>

Pediatrics is the official journal of the American Academy of Pediatrics. A monthly publication, it has been published continuously since 1948. Pediatrics is owned, published, and trademarked by the American Academy of Pediatrics, 345 Park Avenue, Itasca, Illinois, 60143. Copyright © 2016 by the American Academy of Pediatrics. All rights reserved. Print ISSN: 1073-0397.

American Academy of Pediatrics

DEDICATED TO THE HEALTH OF ALL CHILDREN®

