

Hypotension Associated With Intravitreal Bevacizumab Therapy for Retinopathy of Prematurity

Lu-Hsuan Wu, MS,^{a,b} Yea-Huei Kao Yang, BPharm,^{a,c} Chyi-Her Lin, MD,^d Yuh-Jyh Lin, MD,^d Ching-Lan Cheng, PhD^{a,c}

Intravitreal bevacizumab therapy in preterm infants for retinopathy of prematurity (ROP) can be associated with hypotension. We report twin preterm infants who developed hypotension within 1 day after intravitreal bevacizumab therapy for ROP. Before receiving the medication, their clinical statuses were stable and similar. The dose, procedure, and premedication were the same; however, twin B presented with hypotension for 3 days. Although bevacizumab-related hypotension has been described in product information (incidence rate 7%–15%), this is the first case report of intravitreal bevacizumab for ROP inducing hypotension. Physicians should be aware of intravitreal bevacizumab therapy-related hypotension when treating ROP. We suggest conducting a postmarketing active surveillance on the systemic adverse effects of this regimen in preterm infants.

Bevacizumab is an anti-vascular endothelial growth factor (VEGF) monoclonal antibody, approved as an additional medication with other chemotherapy drugs for the treatment of metastatic cancer.¹ It has been used off-label to decrease retinal thickening in age-related macular degeneration and to diminish intraoperative complications in diabetic retinopathy patients.^{2,3} In addition, randomized trials have shown improvement of the retina and reduced zone I disease progression with intravitreal bevacizumab therapy for retinopathy of prematurity (ROP) in preterm infants.⁴

Systemic cardiovascular complications of intravenous bevacizumab have been reported, including hypertension, thromboembolic events, cardiac ischemia, cerebrovascular ischemia, and bleeding.⁵ Although local intravitreal bevacizumab therapy might minimize the systemic side effects, cardiovascular adverse effects such as hypertension

have been observed in some studies.⁶ In theory, bevacizumab will elevate blood pressure by reducing nitric oxide synthase in endothelial cells, decreasing vascular permeability.⁷ Thus, bevacizumab-related hypotension needs more attention because this mechanism is unexpected, although it has been mentioned in product information, presenting an incidence rate of 7% to 15%.⁸ One retrospective study in Japan also reported that 25 colorectal patients with cancer presented a temporary blood pressure drop within 90 minutes of intravenous bevacizumab.⁹ Neither systemic adverse events nor hypotension effects were reported in clinical trials after treatment with bevacizumab for ROP^{4,10,11}; however, the serum level of bevacizumab has been detected after intravitreal injection in preterm infants.¹² To provide more safety information for bevacizumab in preterm infants, we report a case of twin preterm infants treated

abstract

^aSchool of Pharmacy and Institute of Clinical Pharmacy and Pharmaceutical Sciences, College of Medicine; ^bHealth Outcome Research Center; and ^dDepartment of Pediatrics, National Cheng Kung University Hospital, Tainan, Taiwan; and ^cDepartment of Pharmacy, Taipei Tzu Chi Hospital, Buddhist Tzu Chi Medical Foundation, Taipei, Taiwan

Ms Wu cared for the cases, noted the adverse effects relative with bevacizumab, and drafted the initial manuscript; Dr Yang carried out the initial analyses and reviewed and revised the manuscript; Drs C-H Lin and Y-J Lin critically reviewed the manuscript; Dr Cheng coordinated and supervised data collection, and reviewed and revised the manuscript; and all authors approved the final manuscript as submitted.

DOI: 10.1542/peds.2015-2005

Accepted for publication Oct 5, 2015

Address correspondence to Ching-Lan Cheng, PhD, School of Pharmacy and Institute of Clinical Pharmacy and Pharmaceutical Sciences, College of Medicine, National Cheng Kung University, Tainan, Taiwan, 1 University Road, School of Pharmacy and Institute of Clinical Pharmacy and Pharmaceutical Sciences, College of Medicine, National Cheng Kung University, Tainan, 701, Taiwan. E-mail: clcheng@mail.ncku.edu.tw

PEDIATRICS (ISSN Numbers: Print, 0031-4005; Online, 1098-4275).

Copyright © 2016 by the American Academy of Pediatrics

FINANCIAL DISCLOSURE: The authors have indicated they have no financial relationships relevant to this article to disclose.

FUNDING: No external funding.

POTENTIAL CONFLICT OF INTEREST: The authors have indicated they have no potential conflicts of interest to disclose.

To cite: Wu L, Yang YK, Lin C, et al. Hypotension Associated With Intravitreal Bevacizumab Therapy for Retinopathy of Prematurity. *Pediatrics*. 2016; 137(2):e20152005

with intravitreal injection of bevacizumab for ROP, after which 1 infant showed posttreatment hypotension that persisted through the day.

CASE REPORT

Twin B: Hypotension After Therapy With Bevacizumab

Twin (B), a male infant, was born at 26 weeks' gestation with a birth weight of 800 g. Bilateral immature retina was found at 6 weeks after birth. At 9 weeks, the ROP had progressed to stage 3, zone 1. Intravitreal injection of bevacizumab (0.625 mg/0.025 mL) was performed in each eye under intravenous ketamine (0.3 mg) and local atropine (0.25%). At the same time, a local steroid (betamethasone) and an antibiotic (levofloxacin) were administered for inflammation and infection prevention. Up to this time, the patient had been stable and had only received parenteral nutrition for growth and metoclopramide 0.2 mg/kg every 8 hours for gastroesophageal reflux during the previous month. Feeding intolerance, hypotension (42/24 mm Hg), and desaturation (arterial oxygen saturation 80.0%) were noted 22 hours after bevacizumab therapy. On the second day, blood pressure remained low (48/26 mm Hg) and feeding intolerance was not improved. In addition, Twin B suffered from shortness of breath with apnea (arterial oxygen saturation 66.1%) and lethargy and was intubated for mechanical ventilation. Because of the hypotension, he received dopamine, 8 mcg/kg per minute infusion, and prophylactic antibiotics with vancomycin, 10 mg/kg every 6 hours and ceftazidime 50 mg/kg every 8 hours. On the third day after bevacizumab therapy, his blood pressure returned to normal, and his general condition improved (Figs 1

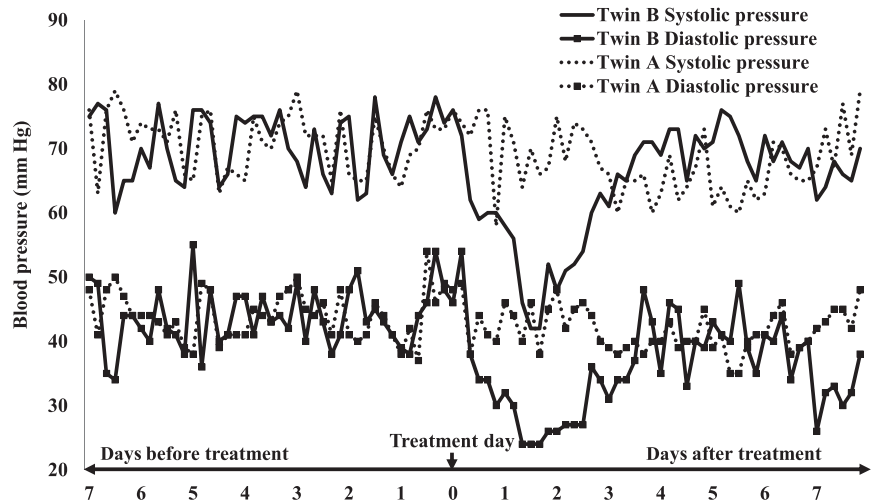


FIGURE 1

Blood pressure of the patients 1 week before and after intravitreal bevacizumab therapy. Twin B was in stable condition before treatment. Hypotension (42/24 mm Hg) was noted within 1 day after bevacizumab therapy. On the second day, blood pressure remained low (48/26 mm Hg).

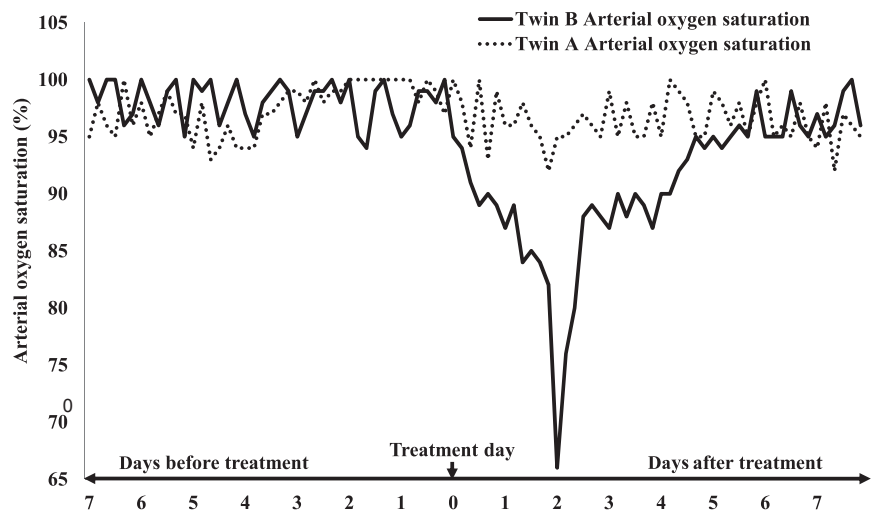


FIGURE 2

Arterial oxygen saturation of the patients 1 week before and after intravitreal bevacizumab therapy. Twin B was in stable condition before treatment. Desaturation (arterial oxygen saturation 80.0%) was noticed within 1 day after bevacizumab therapy. On the second day, arterial oxygen saturation remained low (66.1%).

and 2). On the sixth day, his condition had stabilized, and antibiotics and dopamine were discontinued. He was successfully extubated on the next day, and arterial oxygen saturation was normal. Eighteen weeks after birth, he was discharged from the NICU in stable condition.

Twin A: No Hypotension After Therapy With Bevacizumab

Twin A, a female infant, was similar to her brother: 26 weeks' gestation

with 775 g birth weight. Bilateral immature retina was found 6 weeks after birth (ROP stage 3, zone 1). The treatment regimen was the same as her brother's: intravitreal injections of bevacizumab (0.625 mg/0.025 mL), with intravenous ketamine (0.3 mg), local atropine, betamethasone, and levofloxacin. She received vancomycin 10 mg/kg every 6 hours plus ceftazidime 50 mg/kg every 8 hours for suspected infection in the previous 5 days. Her

TABLE 1 Patient Characteristics

| Patient | Twin B | Twin A |
|---|---------------------|-------------------------|
| Hypotension or desaturation after treatment | Yes | No |
| Gender | Male | Female |
| Gestational age at birth | 26+3 wk | 26+3 wk |
| Body wt at birth | 800 g | 775 g |
| Apgar score at birth | 5–8 | 7–8 |
| PDA with ibuprofen | Yes | Yes |
| PDA with surgical ligation | Yes | Yes |
| Pulmonary hypertension | Yes | Yes |
| ROP stage | Stage III zone I+ | Stage III zone I+ |
| Age at treatment | 34+4 wk | 34+4 wk |
| Body wt at treatment | 1680 g | 1435 g |
| Average wt gain | 16.0 g/kg/day | 12.0 g/kg/day |
| Ventilation status at treatment | NIMV | NIMV |
| Sedation for procedure | Ketamine | Ketamine |
| Intraventricular hemorrhage | Grade I | Grade II |
| Chronic lung disease | Yes | Yes |
| Feeding condition 1 week pretreatment | Milk 8 mL every 4 h | Milk 1 mL every 4 h |
| Parenteral nutrition 1 week pretreatment | Yes | Yes |
| Total fluid intake 1 week pretreatment | 150 mL/kg/d | 150 mL/kg/d |
| Infection 1 month pretreatment | No | Yes |
| Medications 1 week before treatment | Metoclopramide | Vancomycin, ceftazidime |

NIMV, nasal intermittent mandatory ventilation; PDA, patent ductus arteriosus.

blood pressure (72/43 mm Hg) and arterial oxygen saturation (97.3%) were normal after treatment with bevacizumab. The blood pressure (average 70.1/43.7 mm Hg) and arterial oxygen saturation (average 95.6%) were stable during the 2 days after bevacizumab treatment (Figs 1 and 2). Antibiotics were stopped the second day after bevacizumab therapy because infection was no longer noted. Eighteen weeks after birth, she was discharged from the NICU in stable condition.

DISCUSSION

ROP is a serious vasoproliferative disorder that occurs in the retina of preterm infants with incomplete retinal vascularization. ROP can lead to severe visual impairment or blindness.¹³ Exposure to hyperoxia can result in delay of normal retinal vascular development and induce vascular obliteration, and, consequently, VEGF administration before 31 weeks' gestation.¹³ VEGF and other cytokines may contribute to both normal retinal vessel growth and abnormal vascular disruption and subsequent neovascularization.

Increased permeability of these abnormal new vessels can result in retinal edema and hemorrhage. Bevacizumab is an anti-VEGF monoclonal antibody that inhibits the physiologic effects of VEGF to improve visualization of the retina and may facilitate disease regression.⁴

In published reports on the effectiveness of bevacizumab, there are no systemic complications attributable to intravitreal bevacizumab, such as blood pressure fluctuation, cardiopulmonary distress, or infection, in the treatment of ROP.^{10–12} However, the medication can leak through the compromised blood–retina barrier with ROP and be detected in serum 2 days after injection.¹⁴

We report that only 1 preterm twin (twin B, but not twin A) suffered hypotension and desaturation after intravitreal bevacizumab therapy. Before the infants received the treatment, both had adequate weight gain, ~12.0 to 16.0 g/kg/day, under parenteral nutrition and breastfeeding (Table 1). There was no bacterial, viral, or fungal growth from culture of the central venous

catheter for total parenteral nutrition at 1 week before and after the infants received intravitreal bevacizumab. Neither had a hemorrhage event or loss intravascular volume components in the previous month. Vital signs for each were stable for 2 weeks before the regimen (Figs 1 and 2).

Clinical features of hypotension include low blood pressure, change in consciousness, desaturation, tachycardia, skin mottling, cool extremities, and decreased urine output. Factors associated with hypotension in neonates are various, including hemorrhage, loss of intravascular volume components (burns, nephrotic syndrome, diarrhea, vomiting, and diabetes), congenital heart disease, ischemia, dysrhythmias, pneumothorax, sepsis, and drug-induced hypotension.¹⁵ Systemic anesthesia (ketamine) may induce hypotension and apnea. However, although both twins received the same ketamine treatment, only twin B developed hypotension and desaturation the day after intravitreal bevacizumab. The half-life of bevacizumab is 11 to 50 days, whereas the half-life of ketamine is approximately 2 to 3 hours. The hypotension occurred 22 hours after intravitreal treatment and thus is less likely to have resulted from ketamine. The time sequence between the therapy administration and the onset of adverse effects showed a high association between the intravitreal bevacizumab and the hypotension. Although metoclopramide-associated hypotension had been reported within 2 minutes after administration, twin B used metoclopramide 1 month before the incident without hypotension. Thus, intravitreal bevacizumab was considered the probable cause of hypotension in twin B, and this event was idiosyncratic and unexpected.

Off-label use of intravitreal bevacizumab therapy for ROP is increasing, despite the lack of studies on its safety. It is well known that bevacizumab may leak out of the eyes and enter the systemic circulation.^{12,14} The safety of intravitreal bevacizumab for ROP concerns not only the eye but also systemic tissues. The potential for systemic adverse events exists and should not be ignored. Thus, the safety of intravitreal bevacizumab therapy in preterm infants with ROP should be established with further studies.

ABBREVIATIONS

ROP: retinopathy of prematurity
VEGF: vascular endothelial growth factor

REFERENCES

1. Falk AT, Barrière J, François E, Follana P. Bevacizumab: A dose review. *Crit Rev Oncol Hematol*. 2015;94(3):311–322
2. Avery RL, Pieramici DJ, Rabena MD, Castellarin AA, Nasir MA, Giust MJ. Intravitreal bevacizumab (Avastin) for neovascular age-related macular degeneration. *Ophthalmology*. 2006;113(3):363–372 e365
3. Zhang ZH, Liu HY, Hernandez-Da Mota SE, et al. Vitrectomy with or without preoperative intravitreal bevacizumab for proliferative diabetic retinopathy: a meta-analysis of randomized controlled trials. *American journal of ophthalmology*. 2013;156(1):106–115 e102
4. Mintz-Hittner HA, Kennedy KA, Chuang AZ; BEAT-ROP Cooperative Group. Efficacy of intravitreal bevacizumab for stage 3+ retinopathy of prematurity. *N Engl J Med*. 2011;364(7):603–615
5. Scalfani F, Cunningham D. Bevacizumab in elderly patients with metastatic colorectal cancer. *J Geriatr Oncol*. 2014;5(1):78–88
6. Micieli JA, Micieli A, Smith AF. Identifying systemic safety signals following intravitreal bevacizumab: systematic review of the literature and the Canadian Adverse Drug Reaction Database. *Canadian journal of ophthalmology. Journal canadien d'ophtalmologie*. 2010;45(3):231–238
7. Bates DO. Vascular endothelial growth factors and vascular permeability. *Cardiovasc Res*. 2010;87(2):262–271
8. Package insert: bevacizumab. 2004; www.accessdata.fda.gov/drugsatfda_docs/label/2009/125085s01691bl.pdf.
9. Kanai M, Ishiguro H, Mori Y, et al. Temporary blood pressure drop after bevacizumab administration is associated with clinical course of advanced colorectal cancer. *Br J Cancer*. 2011;105(11):1693–1696
10. Sahin A, Sahin M, Cingu AK, et al. Intravitreal bevacizumab monotherapy for retinopathy of prematurity. *Pediatrics international: official journal of the Japan Pediatric Society*. 2013;55(5):599–603
11. Axer-Siegel R, Snir M, Ron Y, Friling R, Sirota L, Weinberger D. Intravitreal bevacizumab as supplemental treatment or monotherapy for severe retinopathy of prematurity. *Retina*. 2011;31(7):1239–1247
12. Wu WC, Lien R, Liao PJ, et al. Serum levels of vascular endothelial growth factor and related factors after intravitreal bevacizumab injection for retinopathy of prematurity. *JAMA Ophthalmol*. 2015;133(4):391–397
13. Pierce EA, Foley ED, Smith LE. Regulation of vascular endothelial growth factor by oxygen in a model of retinopathy of prematurity. *Arch Ophthalmol*. 1996;114(10):1219–1228
14. Kong L, Bhatt AR, Demny AB, et al. Pharmacokinetics of bevacizumab and its effects on serum VEGF and IGF-1 in infants with retinopathy of prematurity. *Invest Ophthalmol Vis Sci*. 2015;56(2):956–961
15. Fanaroff JM, Fanaroff AA. Blood pressure disorders in the neonate: hypotension and hypertension. *Semin Fetal Neonatal Med*. 2006;11(3):174–181

Hypotension Associated With Intravitreal Bevacizumab Therapy for Retinopathy of Prematurity

Lu-Hsuan Wu, Yea-Huei Kao Yang, Chyi-Her Lin, Yuh-Jyh Lin and Ching-Lan Cheng

Pediatrics 2016;137;

DOI: 10.1542/peds.2015-2005 originally published online January 7, 2016;

Updated Information & Services

including high resolution figures, can be found at:
<http://pediatrics.aappublications.org/content/137/2/e20152005>

References

This article cites 10 articles, 1 of which you can access for free at:
<http://pediatrics.aappublications.org/content/137/2/e20152005#BIBL>

Subspecialty Collections

This article, along with others on similar topics, appears in the following collection(s):
Administration/Practice Management
http://www.aappublications.org/cgi/collection/administration:practice_management_sub
Safety
http://www.aappublications.org/cgi/collection/safety_sub
Fetus/Newborn Infant
http://www.aappublications.org/cgi/collection/fetus:newborn_infant_sub
Neonatology
http://www.aappublications.org/cgi/collection/neonatology_sub

Permissions & Licensing

Information about reproducing this article in parts (figures, tables) or in its entirety can be found online at:
<http://www.aappublications.org/site/misc/Permissions.xhtml>

Reprints

Information about ordering reprints can be found online:
<http://www.aappublications.org/site/misc/reprints.xhtml>

American Academy of Pediatrics

DEDICATED TO THE HEALTH OF ALL CHILDREN™



PEDIATRICS®

OFFICIAL JOURNAL OF THE AMERICAN ACADEMY OF PEDIATRICS

Hypotension Associated With Intravitreal Bevacizumab Therapy for Retinopathy of Prematurity

Lu-Hsuan Wu, Yea-Huei Kao Yang, Chyi-Her Lin, Yuh-Jyh Lin and Ching-Lan Cheng

Pediatrics 2016;137;

DOI: 10.1542/peds.2015-2005 originally published online January 7, 2016;

The online version of this article, along with updated information and services, is located on the World Wide Web at:

<http://pediatrics.aappublications.org/content/137/2/e20152005>

Pediatrics is the official journal of the American Academy of Pediatrics. A monthly publication, it has been published continuously since 1948. Pediatrics is owned, published, and trademarked by the American Academy of Pediatrics, 141 Northwest Point Boulevard, Elk Grove Village, Illinois, 60007. Copyright © 2016 by the American Academy of Pediatrics. All rights reserved. Print ISSN: 1073-0397.

American Academy of Pediatrics

DEDICATED TO THE HEALTH OF ALL CHILDREN™

