

Atypical Cutaneous Blastomycosis in a Child With Juvenile Idiopathic Arthritis on Infliximab

Robert J. Smith, BS^a, Markus D. Boos, MD, PhD^{a,b,c}, Jon M. Burnham, MD, MSCE^d, Eileen M. McKay, MD^e, Jason Kim, MD, MSCE^f, Melinda Jen, MD^{a,b,c}

abstract

Blastomyces dermatitidis is a dimorphic fungus endemic to much of North America, particularly the soils of the midwestern and southeastern United States. Human infection typically occurs through inhalation of airborne conidia, which can be followed occasionally by dissemination to the skin, bone, genitourinary system, and central nervous system. A hallmark of the pathogen is that it can cause disease in both immunocompetent and immunosuppressed populations. Blastomycosis is rare in pediatric patients, with cutaneous manifestations occurring even less frequently. Here, we report the case of a 9-year-old boy on iatrogenic immunosuppression with infliximab and methotrexate for juvenile idiopathic arthritis who presented with a nonhealing, indurated plaque of his right ear with significant superficial yellow crusting in the absence of constitutional symptoms. After failing a prolonged course of topical and oral antibiotic therapy, biopsy and tissue culture revealed *Blastomyces dermatitidis* infection. The area cleared after treatment with oral fluconazole and withdrawal of infliximab. To our knowledge, this is the first report of a pediatric patient developing an infection with *B dermatitidis* after initiation of therapy with a tumor necrosis factor- α inhibitor. This case also highlights an unusual morphology of cutaneous blastomycosis in an iatrogenically immunosuppressed child.

Blastomyces dermatitidis is a thermally dimorphic fungus that can cause serious systemic and cutaneous illness in both immunosuppressed and immunocompromised individuals.^{1,2} Cutaneous lesions can develop via primary inoculation with the fungus or dissemination from primary pulmonary disease. Lesion morphology is classically verrucous or ulcerative in nature.³ The differential diagnosis of cutaneous blastomycosis includes tuberculosis, disseminated mycobacterial infections, other deep fungal infections, cutaneous leishmaniasis, halogenodermas, pyoderma gangrenosum, squamous cell carcinoma, and sarcoidosis.⁴ Iatrogenic immunosuppression is a known risk factor the development of fungal

infections.⁵ Although tumor necrosis factor- α (TNF- α) inhibitors carry a US Food and Drug Administration warning of increased risk for fungal infections, the evidence of such risk is thus far limited in pediatric patients.^{6,7} We present the case of a 9-year-old boy on therapy with infliximab and methotrexate for juvenile idiopathic arthritis (JIA) who presented with a nonhealing, indurated plaque of his right earlobe without systemic findings. He was ultimately diagnosed with cutaneous *B dermatitidis*.

CASE PRESENTATION

A 9-year-old boy with a history of enthesitis-related JIA was referred to dermatology for evaluation of

^aPerelman School of Medicine at the University of Pennsylvania, and ^bDepartment of Dermatology, Perelman School of Medicine at the University of Pennsylvania, Philadelphia, Pennsylvania; ^cSection of Dermatology, ^dDivisions of Rheumatology, and ^eInfectious Disease, Department of Pediatrics, and ^fDepartment of Pathology and Laboratory Medicine, and The Children's Hospital of Philadelphia, Philadelphia, Pennsylvania

Mr Smith acquired data for the study, drafted the initial manuscript, and provided critical revisions for intellectual content; Dr Boos conceptualized and designed the study, acquired data, drafted the initial manuscript, and provided critical revisions for intellectual content; Dr Burnham provided critical revisions for intellectual content; Dr McKay provided images and descriptions of pathology slides and provided critical revisions for intellectual content; Dr Kim provided critical revisions for intellectual content; Dr Jen conceptualized and designed the study, acquired data, and provided critical revisions for intellectual content; and all authors approved the final manuscript as submitted.

www.pediatrics.org/cgi/doi/10.1542/peds.2015-1675

DOI: 10.1542/peds.2015-1675

Accepted for publication Aug 3, 2015

Address correspondence to Melinda Jen, MD; 3550 Market St., 2nd Floor, Philadelphia, PA 19104. E-mail: jenm@email.chop.edu

PEDIATRICS (ISSN Numbers: Print, 0031-4005; Online, 1098-4275).

Copyright © 2015 by the American Academy of Pediatrics

FINANCIAL DISCLOSURES: The authors have indicated they have no financial relationships relevant to this article to disclose.

FUNDING: No funding source was secured for this study.

POTENTIAL CONFLICT OF INTEREST: The authors have indicated they have no potential conflicts of interest to disclose.

a nonhealing, inflammatory plaque of his right ear. The lesion was first noted by the patient's mother 6 months before a small red nodule on the right earlobe. Over the subsequent 5 months, the nodule evolved into an erythematous, indurated, and painful ear lesion that periodically expressed serosanguineous fluid. His mother had treated with topical mupirocin and topical triple antibiotic ointment without improvement. His past medical history was notable for trisomy 21 and JIA. His chronic arthritis had been treated with infliximab 8 mg/kg monthly and methotrexate 5 mg weekly for 9 months before presentation. He denied foreign travel but had visited his father in rural Missouri the month before the development of his earlobe lesion. On physical examination, the patient was well appearing. His skin examination was notable for a red, indurated right earlobe with significant superficial yellow crusting and peripheral desquamation that was minimally tender to palpation (Fig 1). He had no palpable cervical lymphadenopathy. The patient was otherwise healthy without pulmonary or constitutional symptoms. At presentation, culture of the earlobe was performed and grew normal skin flora.

Repeat bacterial culture of the crusted area was performed and returned negative. Given the persistent crusting, he was treated for a likely *Staphylococcus aureus* infection with topical mupirocin and separate courses of clindamycin and doxycycline with minimal improvement. After 2 subsequent months of therapy with topical mupirocin and triamcinolone 0.025% ointment without improvement, a biopsy of the lesion was performed. Hematoxylin and eosin stain revealed central granulomatous inflammation with a multinucleated giant cell containing a phagocytosed yeast and a mixed chronic inflammatory infiltrate in the surrounding

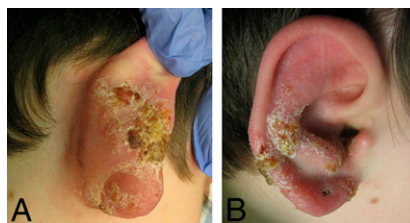

FIGURE 1
A and B, Red, indurated right earlobe with significant superficial yellow crusting and peripheral desquamation at the time of biopsy.

dermis (Fig 2A). Grocott's methenamine silver stain showed scattered fungal yeast forms with some budding, suggestive of a fungal dermatitis (Fig 2B). Acid-fast bacteria and Fite stains were negative for acid-fast bacteria. *B dermatitidis* was identified by DNA probe on fungal culture. After consultation with an infectious disease specialist, extensive laboratory and imaging evaluation for primary pulmonary disease was deferred owing to his overall well appearance since the lesion onset.

The patient was subsequently treated with 12 mg/kg/day of oral fluconazole daily for 6 months. His infliximab was withdrawn for 3 months to allow for improvement of his infection; however, his methotrexate was maintained to guard against exacerbation of his JIA. After 2 months of therapy, the induration and erythema of his right lobe had improved considerably (Fig 3).

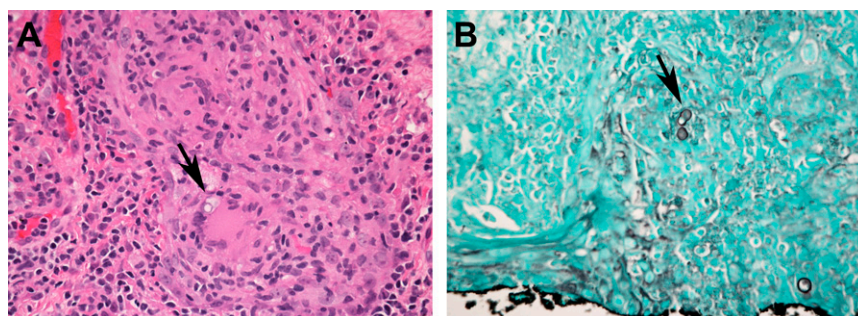


FIGURE 2
A, Central granulomatous inflammation with a multinucleated giant cell containing phagocytosed yeast (arrow) with a mixed chronic inflammatory infiltrate in the surrounding dermis. (Hematoxylin and eosin stain, 40× magnification). B, Large yeast with focal, potential broadly based budding (arrow), characteristic of *B dermatitidis*. (Grocott's methenamine silver stain, 40× magnification).

DISCUSSION

B dermatitidis is a thermally dimorphic fungus endemic to North America, particularly the soils of the Ohio and Mississippi River basins. Human infection typically occurs when soil containing the *Blastomyces* conidia are inhaled; classically, this manifests as primary pulmonary disease with constitutional symptoms of fever, cough, and fatigue but may be asymptomatic.³ When natural alveolar defenses fail to contain the infection, hematogenous dissemination ensues, affecting 25% to 30% of patients.⁸ The most common extrapulmonary sites of disease include the skin, bone, genitourinary, reticuloendothelial, and central nervous systems.^{1,3,8} Morphologically, cutaneous blastomycosis typically presents in either verrucous or ulcerative forms. Verrucous lesions begin as papules that evolve into crusted, warty plaques with an irregular shape, sharp borders, and central clearing. Ulcerative lesions often begin as erythematous papules that then ulcerate in an asymmetric pattern with chronic serosanguineous drainage.^{1,3,9} Diagnosis can be made via biopsy and histologic visualization of multinucleated yeast forms that produce daughter cells from a single bud.³

Cutaneous blastomycosis can develop through both primary and secondary mechanisms. The majority of

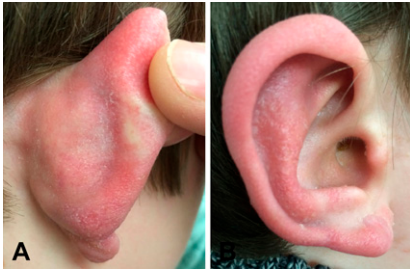

FIGURE 3

A and B, Right ear after 2 months of treatment with systemic fluconazole.

cutaneous blastomycosis occurs by hematogenous spread from a primary pulmonary infection. When associated cutaneous findings appear, pulmonary disease is often subclinical, suggesting that early diagnosis and treatment of cutaneous blastomycosis may help prevent the development of symptomatic systemic illness.¹ Primary cutaneous blastomycosis is a particularly rare entity, typically occurring via infected animal bites or direct occupational inoculation in laboratory settings,^{10,11} Accidental inoculation as a result of direct injury in the context of outdoor activity involving soil can also occur.¹⁰ Four criteria should be met when making a diagnosis of primary inoculation blastomycosis:

- (1) presence of skin lesions, often with focal lymphadenopathy;
- (2) history of inoculation with material known to contain the fungal organism;
- (3) absence of systemic involvement; and
- (4) recovery of organisms from the lesion.¹⁰

Histopathology and lesional morphology cannot distinguish primary inoculation from disseminated cutaneous disease; however, direct inoculation is more likely to result clinically in local lymphangitis.^{10,12}

Pediatric cases of any form of blastomycosis are uncommon, comprising 3% to 11% of all infections.¹³ Up to 50% of pediatric blastomycosis infections may be asymptomatic.^{14,15} A retrospective review of 70 pediatric patients with systemic blastomycosis from

Arkansas showed that only 16% of patients exhibited secondary cutaneous findings.¹⁶ Two subsequent series from the same region examined a total of 20 pediatric patients with blastomycosis infections, 5 of whom presented with secondary cutaneous findings; all patients identified with cutaneous findings also presented with pulmonary disease.^{13,16} A separate 30-year retrospective review from Manitoba, Canada, identified 34 pediatric patients with blastomycosis, of whom 18% presented with cutaneous findings.¹⁷ Finally, a more recent 10-year review from Wisconsin identified 17 pediatric cases of blastomycosis; of these, 6 presented with cutaneous findings, 5 of whom had concurrent pulmonary disease.¹⁸ The majority of these patients were identified as immunocompetent.

Unlike other deep fungal infections, blastomycosis presents in both immunocompetent and immunocompromised individuals.^{1,2} A 20-year review by Lemos showed that in a series of 123 patients diagnosed with blastomycosis, only 31(25%) cases were preceded by immunosuppression (most commonly HIV, prolonged corticosteroid therapy, and chronic renal failure), although an additional 20 patients (16%) presented with diabetes mellitus as a comorbidity.² This study found no association between immunosuppression and the presence of disseminated cutaneous or osseous findings.

TNF- α inhibitors represent a class of antiinflammatory drugs that downregulate the effects of TNF- α , an acute phase cytokine in systemic inflammation.¹⁹ TNF- α inhibitors are used to treat a variety of inflammatory disorders, including JIA, Crohn disease, and severe psoriasis. TNF- α inhibitors, such as infliximab, carry a US Food and Drug Administration black box warning of increased risk for serious fungal

infections.^{6,19} Although TNF- α inhibitors are known to increase the risk of such opportunistic infections in adults, the evidence in pediatric patients is limited.^{20,21} A recent large-scale review of pediatric patients on TNF- α inhibitors for JIA or inflammatory bowel disease found that the occurrence of severe fungal infections was rare and often confounded by the presence of concurrent immunosuppressive therapy in affected patients.⁷ Only 4 of 4625 pediatric patients with JIA on TNF- α inhibitors were noted to develop infection with histoplasmosis, and no blastomycosis infections were reported. Although previously reported in adults, ours is the first case in the literature, to our knowledge, of a pediatric patient developing infection with *B dermatitidis* after initiation of infliximab therapy.^{21,22}

It is uncertain whether our patient presented with primary cutaneous blastomycosis or disseminated cutaneous blastomycosis in the absence of pulmonary constitutional symptoms. Our patient meets at least 3 of the criteria for a diagnosis of primary cutaneous blastomycosis, with skin lesions, an absence of systemic involvement, and evidence of blastomycosis dermatitidis on fungal biopsy.^{10,12} However, he did not endorse trauma to the ear and had no specific history of exposure to soil, animals, or farming equipment. We therefore cannot rule out the more common scenario of a primary pulmonary infection with secondary dissemination.

Our patient was likely exposed to *B dermatitidis* while visiting Missouri, an area endemic to this fungus. Our case is notable in that the morphology of his lesion was not classic for either variant of cutaneous blastomycosis. We speculate that the location of our patient's infection contributed to its atypical appearance. Specifically, the contours of the lobe and helix create a confined

anatomic space that may interfere with the development of classic annular lesions of blastomycosis. Alternatively, the location may have prevented appreciation of the annular configuration of the lesion.

As our case illustrates, the treatment of cutaneous blastomycosis is often delayed in pediatric patients. This delay was likely worsened by the atypical nature of the lesional morphology. Blastomycosis is traditionally treated with amphotericin B, although oral itraconazole is also effective in curing pulmonary and cutaneous blastomycosis infection.^{3,10,15,18} Although the treatment of cutaneous blastomycosis in pediatric patients on iatrogenic immunosuppression is not standardized, our patient experienced rapid improvement after treatment with topical ketoconazole and oral fluconazole and temporary withdrawal of infliximab.

Our case serves as a reminder that in immunosuppressed children with nonhealing, draining lesions and exposure to areas endemic to *B dermatitidis*, a fungal etiology for their condition should be considered. Furthermore, our case illustrates that providers should maintain a high suspicion for the development of fungal infections in pediatric patients started on therapy with TNF- α inhibitors.

ABBREVIATIONS

JIA: juvenile idiopathic arthritis
TNF- α : tumor necrosis factor- α

REFERENCES

1. Mason AR, Cortes GY, Cook J, Maize JC, Thiers BH. Cutaneous blastomycosis: a diagnostic challenge. *Int J Dermatol*. 2008;47(8):824–830
2. Lemos LB, Baliga M, Guo M. Blastomycosis: the great pretender can also be an opportunist. Initial clinical diagnosis and underlying diseases in 123 patients. *Ann Diagn Pathol*. 2002;6(3):194–203
3. Saccente M, Woods GL. Clinical and laboratory update on blastomycosis. *Clin Microbiol Rev*. 2010;23(2):367–381
4. Adams WB. Current and emerging tests for diagnosis of cutaneous blastomycosis. *J Am Acad Dermatol*. 2010;62(3):AB85
5. Choptiany M, Wiebe L, Limerick B, et al. Risk factors for acquisition of endemic blastomycosis. *Can J Infect Dis Med Microbiol*. 2009;20(4):117–121
6. US Food and Drug Association. Safety Information—Remicade (infliximab). Updated January 2015. Available at: <http://www.fda.gov/safety/medwatch/safetyinformation/ucm247032.htm>. Accessed March 9, 2015
7. Toussi SS, Pan N, Walters HM, Walsh TJ. Infections in children and adolescents with juvenile idiopathic arthritis and inflammatory bowel disease treated with tumor necrosis factor- α inhibitors: systematic review of the literature. *Clin Infect Dis*. 2013;57(9):1318–1330
8. Stephens J, Huddleston H, Reeck M. Cutaneous blastomycosis in the absence of active pulmonary disease. *J Am Acad Dermatol*. 2007;56(2, suppl 2):AB130
9. Turner JE, Hodge SJ, Gruber GG. Cutaneous blastomycosis, an unusual presentation. *J Ky Med Assoc*. 1980;78(12):719–721
10. Gray NA, Baddour LM. Cutaneous inoculation blastomycosis. *Clin Infect Dis*. 2002;34(10):E44–E49
11. Ferchichi L, Mekni A, Bellil K, et al. La blastomycose cutanée: trois cas. *Med Mal Infect*. 2006;36(5):285–287
12. Landay ME, Schwarz J. Primary cutaneous blastomycosis. *Arch Dermatol*. 1971;104(4):408–409, passim
13. Schutze GE, Hickerson SL, Fortin EM, et al. Blastomycosis in children. *Clin Infect Dis*. 1996;22(3):496–502
14. Varkey B. Blastomycosis in children. *Semin Respir Infect*. 1997;12(3):235–242
15. Kline L, States U, Kovach R, States U. Cutaneous blastomycosis: a case report and review of the literature. *J Am Acad Dermatol*. 2011;64(2, suppl 2):AB105
16. Steele RW, Abernathy RS. Systemic blastomycosis in children. *Pediatr Infect Dis*. 1983;2(4):304–307
17. Fanella S, Skinner S, Trepman E, Embil JM. Blastomycosis in children and adolescents: a 30-year experience from Manitoba. *Med Mycol*. 2011;49(6):627–632
18. Brick KE, Drolet BA, Lyon VB, Galbraith SS. Cutaneous and disseminated blastomycosis: a pediatric case series. *Pediatr Dermatol*. 2013;30(1):23–28
19. Smith JA, Kauffman CA. Endemic fungal infections in patients receiving tumour necrosis factor- α inhibitor therapy. *Drugs*. 2009;69(11):1403–1415
20. Martin-Mola E, Balsa A. Infectious complications of biologic agents. *Rheum Dis Clin North Am*. 2009;35(1):183–199
21. Ordonez ME, Farraye FA, Di Palma JA. Endemic fungal infections in inflammatory bowel disease associated with anti-TNF antibody therapy. *Inflamm Bowel Dis*. 2013;19(11):2490–2500
22. McCann DA, Smith HL. Infliximab-associated Blastomycosis dermatitidis in treatment of ulcerative colitis. *Colorectal Dis*. 2013;15(2):e102–e103

Atypical Cutaneous Blastomycosis in a Child With Juvenile Idiopathic Arthritis on Infliximab

Robert J. Smith, Markus D. Boos, Jon M. Burnham, Eileen M. McKay, Jason Kim and Melinda Jen

Pediatrics 2015;136:e1386

DOI: 10.1542/peds.2015-1675 originally published online October 19, 2015;

Updated Information & Services	including high resolution figures, can be found at: http://pediatrics.aappublications.org/content/136/5/e1386
References	This article cites 21 articles, 1 of which you can access for free at: http://pediatrics.aappublications.org/content/136/5/e1386#BIBL
Subspecialty Collections	This article, along with others on similar topics, appears in the following collection(s): Dermatology http://www.aappublications.org/cgi/collection/dermatology_sub Infectious Disease http://www.aappublications.org/cgi/collection/infectious_diseases_sub
Permissions & Licensing	Information about reproducing this article in parts (figures, tables) or in its entirety can be found online at: http://www.aappublications.org/site/misc/Permissions.xhtml
Reprints	Information about ordering reprints can be found online: http://www.aappublications.org/site/misc/reprints.xhtml

American Academy of Pediatrics

DEDICATED TO THE HEALTH OF ALL CHILDREN™



PEDIATRICS®

OFFICIAL JOURNAL OF THE AMERICAN ACADEMY OF PEDIATRICS

Atypical Cutaneous Blastomycosis in a Child With Juvenile Idiopathic Arthritis on Infliximab

Robert J. Smith, Markus D. Boos, Jon M. Burnham, Eileen M. McKay, Jason Kim
and Melinda Jen

Pediatrics 2015;136:e1386

DOI: 10.1542/peds.2015-1675 originally published online October 19, 2015;

The online version of this article, along with updated information and services, is
located on the World Wide Web at:

<http://pediatrics.aappublications.org/content/136/5/e1386>

Pediatrics is the official journal of the American Academy of Pediatrics. A monthly publication, it has been published continuously since 1948. Pediatrics is owned, published, and trademarked by the American Academy of Pediatrics, 141 Northwest Point Boulevard, Elk Grove Village, Illinois, 60007. Copyright © 2015 by the American Academy of Pediatrics. All rights reserved. Print ISSN: 1073-0397.

American Academy of Pediatrics

DEDICATED TO THE HEALTH OF ALL CHILDREN™

