

Severe Hyperinsulinemic Hypoglycemia in a Neonate: Response to Sirolimus Therapy

Únőke Méder, MD^a, Géza Bokodi, MD, PhD^a, Lídia Balogh, MD, PhD^a, Anna Körner, MD, PhD^a, Miklós Szabó, MD, PhD^a, Stepanka Pruhova, MD, PhD^b, Attila J. Szabó, MD, PhD^{a,c}

Hyperinsulinemic hypoglycemia (HH) is one of the most common causes of persistent hypoglycemic episodes in neonates. Current pharmacologic treatment of neonatal HH includes diazoxide and octreotide, whereas for diffuse, unresponsive cases a subtotal pancreatectomy may be the last resort, with questionable efficacy. Here we report a case of congenital diffuse neonatal HH, first suspected when severe hypoglycemia presented with extremely high serum insulin levels immediately after birth. Functional imaging and genetic tests later confirmed the diagnosis. Failure to respond to a sequence of different treatments and to avoid extensive surgery with predictable morbidity prompted us to introduce a recently suggested alternative therapy with sirolimus, a mammalian target of rapamycin inhibitor. Glucose intake could be reduced gradually while euglycemia was maintained, and we were able to achieve exclusively enteral feeding within 6 weeks. Sirolimus was found to be effective and well tolerated, with no major adverse side effects attributable to its administration.

PATIENT PRESENTATION

Our patient, a male infant, was born by normal vaginal delivery during the 37th week of gestation after an uneventful pregnancy. Birth weight was 4400 g, and 1- and 5-minute Apgar scores were 10 and 10. Both parents and the baby's 2 older siblings had unremarkable medical histories. A right-sided clavicular fracture was noted on first examination, which did not warrant additional intervention. Two hours after delivery, tremor and irritability were observed, with severe hypoglycemia (0.5 mmol/L, 9 mg/dL). High doses of intravenous glucose (up to 20 mg/kg per minute) and occasional glucagon boluses were needed to normalize the persistently low blood glucose levels. The diagnosis of hyperinsulinemic hypoglycemia (HH) was based on the clinical picture and on the laboratory values (glucose, 0.5 mmol/L;

concomitant serum insulin, 130.7 μ U/mL; growth hormone, 18.3 ng/mL; thyroid-stimulating hormone, 8.2 mU/L; free thyroxine, 20.5 pmol/L; cortisol, 835 nmol/L), and samples were sent for genetic testing.

Diazoxide therapy (with hydrochlorothiazide 1 mg/kg per day) was commenced on day 4 and was gradually increased to a maximum dose of 20 mg/kg per day without any effect. Somatostatin treatment (introduced as intravenous, subsequently modified to subcutaneous) was initiated on week 2 and increased to a maximum dose (35 μ g/kg per day), but only a 20% reduction in total glucose requirements was achieved. On week 4 nifedipine was added to the therapeutic regimen, but it was discontinued after a week because of lack of response (Fig 1).

abstract



^aFirst Department of Pediatrics, Semmelweis University, Budapest, Hungary; ^bDepartment of Pediatrics, 2nd Faculty of Medicine, Charles University in Prague and University Hospital Motol, Prague, Czech Republic; and ^cPediatrics and Nephrology Research Group, Hungarian Academy of Sciences, Budapest, Hungary

Dr Méder was involved in the clinical management and follow-up of the patient, coordinated the multidisciplinary meetings, researched current literature and collected the data, drafted the initial manuscript, and revised it for final submission; Dr Bokodi was involved in the clinical management and follow-up of the patient and assisted with data collection; Dr Körner was involved in developing the treatment plan, took part in the multidisciplinary discussions, and critically reviewed the manuscript; Dr Szabó coordinated and supervised the clinical care of the patient, took part in the multidisciplinary discussions, and revised the manuscript; Dr Pruhova performed the genetic testing and reviewed the manuscript; Dr Szabó led the multidisciplinary discussions, reviewed the manuscript for final submission, and approved the publication strategy; and all authors approved the final manuscript as submitted.

www.pediatrics.org/cgi/doi/10.1542/peds.2014-4200

DOI: 10.1542/peds.2014-4200

Accepted for publication Jun 23, 2015

Address correspondence to Únőke Méder, First Department of Pediatrics, Semmelweis University, Budapest, Bókay u. 53–54, H-1083, Hungary. E-mail: meder.unoke@med.semmelweis-univ.hu

PEDIATRICS (ISSN Numbers: Print, 0031-4005; Online, 1098-4275).

Copyright © 2015 by the American Academy of Pediatrics

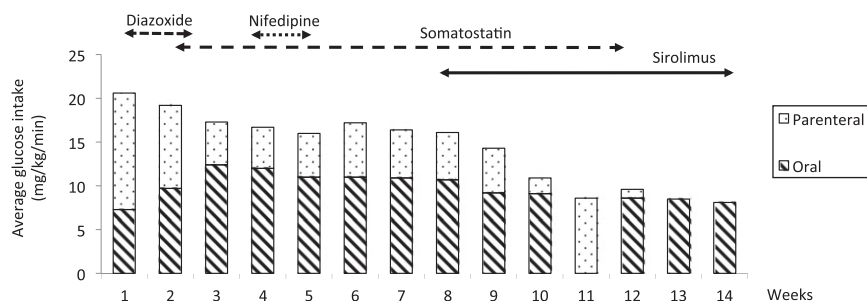


FIGURE 1 Timeline of parenteral and enteral average glucose intake in relation to the changes in therapy.

Functional imaging with ^{18}F 3,4-dihydroxyphenylalanine positron emission tomography scan performed on week 6 confirmed diffuse pancreatic enhancement. Genetic tests subsequently showed a compound heterozygote for the known mutations in the *ABCC8* gene: mutation p.Y512* (c.1536C>A M/n)¹ inherited from the unaffected father and IVS36-13G>A (c.4412-13G>A, p.? M/n)² inherited from the unaffected mother. Multidisciplinary discussions, involving the parents, were organized regarding treatment options, including a subtotal pancreatectomy. A recent report³ of a novel indication of sirolimus, a mammalian target of rapamycin (mTOR) inhibitor in similar cases, was also discussed. After risks and benefits were considered carefully, a consensus decision was made to proceed with this alternative treatment option. Approval was sought from Directorate General of National Institute of Pharmacy, Hungary, and written consent from the parents was also obtained.

Sirolimus (Rapamune; Pfizer, Walton Oaks, Surrey, United Kingdom) was initiated on week 8, built up from a dose of 0.5 mg/m² per day, with gradual increments controlled by serum levels (aiming for 5–15 ng/mL) checked every 3 to 5 days (see Supplemental Information). During the next 6 weeks the patient's glucose requirement was significantly reduced for the first time (to 8 mg/kg per minute), and somatostatin could gradually be discontinued, while the

patient maintained normoglycemia. During this transitional period, an episode of sepsis with bloody stool developed at week 11, with signs of intestinal pneumatosis on the abdominal radiograph. Bell stage II A necrotizing enterocolitis (NEC) was diagnosed, enteral feed was briefly suspended, and the symptoms resolved with conservative treatment.

Regular blood (complete blood cell count, renal and liver function, lipid levels) and urine samples were collected to monitor for known side effects of sirolimus, but apart from mildly elevated liver function tests and triglyceride and cholesterol levels we could not attribute any significant adverse events to the treatment. Clinical neurologic examinations were unremarkable during the period of treatment apart from the initial tremor witnessed immediately after birth. Neurodevelopmental assessment revealed moderate axial hypotonia, which improved with physiotherapy. A brain MRI scan at 5 months was reported as normal. Weight and head circumference were both above the 98 percentile at birth and remained in this range throughout the period of observation. Although oral intake has remained the primary route for feeding, a percutaneous endoscopic gastrostomy tube was inserted at 6 months to aid supplemental feeding at regular intervals.

Follow-up assessment at the age of 1 year confirmed that the treatment had sustained results. The infant, weighing 13.5 kg, currently receives

1.5 mg sirolimus once a day, which maintains a serum sirolimus level of 9.62 ng/mL. Capillary blood sugar is checked at least ≥ 4 times every day, with levels ranging between 3.5 and 7.0 mmol/L, and no hypoglycemic episode (serum glucose <2.6 mmol/L) has been reported since discharge. Controlled fasting levels significantly improved from <1 hour at the time of diagnosis to >6 hours at follow-up (insulin levels were 20 $\mu\text{U}/\text{mL}$ and 5.52 $\mu\text{U}/\text{mL}$ after 4 and 6 hours of fasting, respectively). The liver function tests and serum lipid levels remained mildly elevated (aspartate aminotransferase, 73 U/L; alanine aminotransferase, 65 U/L; cholesterol, 5.9 mmol/L; triglyceride, 3.9 mmol/L) but showed improvement, with the reduction of sirolimus levels, and continue to be closely monitored.

DISCUSSION

HH in neonates, formerly also described as nesidioblastosis or congenital hyperinsulinism, is characterized by unregulated and elevated insulin secretion of the pancreatic islet β cells, resulting in persistent hypoglycemia. This is a rare disease with an incidence of 1 in 50 000 live births, but significant variation has been reported.⁴ Early diagnosis and treatment are crucial to the appropriate management of HH.

Histologic presentation may be focal or diffuse⁵ (and very rarely atypical⁶) based on the spread of affected regions in the pancreas. Differentiation between these subgroups can be made by using ^{18}F 3,4-dihydroxyphenylalanine positron emission tomography scans.⁷ Several congenital mutations have been described that may have a role, and in $\sim 50\%$ of the cases the adenosine triphosphate (ATP) sensitive K^+ channel in pancreatic β cells seems to play a key role in the uncontrolled insulin secretion.⁸ *KCNJ11* and *ABCC8* localized on chromosome 11p15.1 are responsible

for coding the 2 subunits of these K-ATP channels.⁹

The primary goal of treatment is to achieve normoglycemia to prevent long-term neurologic damage.¹⁰ The treatment algorithm most widely accepted recommends the K-ATP agonist diazoxide as first-line therapy and the somatostatin analog octreotide as second-line therapy.¹¹ The calcium channel blocker nifedipine has also been reported as an alternative in unresponsive cases.¹² Focal lesions usually warrant surgical excision, whereas for therapy-resistant diffuse presentations the only treatment option available is subtotal or total pancreatectomy.¹³ Definitive success rates are high for the former, but about one-third of patients remain hyperinsulinemic after subtotal pancreatectomy, many develop exocrine pancreatic insufficiency, and nearly all will develop diabetes by adolescence.¹⁴

A recently published novel treatment option for HH of the newborn has been suggested including the immunosuppressant sirolimus, an mTOR inhibitor.³ No major adverse reactions were observed during the 1-year follow-up period in the 4 cases reported. This finding is reinforced by the latest case report of another

infant.¹⁵ The suggested method of action of sirolimus includes the reduction of β cell proliferation, inhibition of insulin production,¹⁶ and induced peripheral insulin resistance.¹⁷

Our decision to proceed with this treatment option was prompted by the lack of response to standard therapies, with the aim to avoid the major adverse effects of subtotal pancreatectomy. The desired glycemic control was achieved within 6 weeks of initiating sirolimus treatment. A transient episode of NEC was observed after the introduction of sirolimus, which responded well to conservative treatment and subsequent termination of somatostatin therapy. Based on previously published evidence of somatostatin-related NEC,¹⁸ it was considered most likely that this adverse event was attributable to somatostatin rather than sirolimus. Although the side effects of elevated liver function, hypercholesterolemia, and hypertriglyceridemia were observed, they were mild, and improvement was seen with reduction in sirolimus dosage. Significant renal, hematologic, or pulmonary complications associated with sirolimus reported elsewhere¹⁹ were not experienced. Compliance

with dietary and therapeutic recommendations took patience and full engagement with the parents.

CONCLUSIONS

We believe our case report adds to the growing evidence of published cases suggesting that sirolimus could be an effective and safe treatment option in therapy-resistant diffuse HH of the newborn.

ACKNOWLEDGMENTS

Professor Jan Lebl, MD, PhD, of the Department of Pediatrics, 2nd Faculty of Medicine, Charles University in Prague, provided a detailed analysis of the genetic results.

We thank Professor Tivadar Tulassay of the 1st Department of Pediatrics, Semmelweis University Budapest, for his valuable comments and recommendations for this manuscript.

ABBREVIATIONS

ATP: adenosine triphosphate
HH: hyperinsulinemic hypoglycemia
mTOR: mammalian target of rapamycin
NEC: necrotizing enterocolitis

FINANCIAL DISCLOSURE: The authors have indicated they have no financial relationships relevant to this article to disclose.

FUNDING: No external funding was secured for this case report. The molecular genetic analysis was supported by a grant from the Czech Ministry of Health (NT 11402).

POTENTIAL CONFLICT OF INTEREST: The authors have indicated they have no potential conflicts of interest to disclose.

REFERENCES

- Ohkubo K, Nagashima M, Naito Y, et al. Genotypes of the pancreatic beta-cell KATP channel and clinical phenotypes of Japanese patients with persistent hyperinsulinemic hypoglycaemia of infancy. *Clin Endocrinol (Oxf)*. 2005;62(4):458–465
- Henquin JC, Nenquin M, Sempoux C, et al. In vitro insulin secretion by pancreatic tissue from infants with diazoxide-resistant congenital hyperinsulinism deviates from model predictions. *J Clin Invest*. 2011;121(10):3932–3942
- Senniappan S, Alexandrescu S, Tatevian N, et al. Sirolimus therapy in infants with severe hyperinsulinemic hypoglycemia. *N Engl J Med*. 2014;370(12):1131–1137
- Bruining GJ. Recent advances in hyperinsulinism and the pathogenesis of diabetes mellitus. *Curr Opin Pediatr*. 1990;2(4):758–765
- Rahier J, Guiot Y, Sempoux C. Persistent hyperinsulinaemic hypoglycaemia of infancy: a heterogeneous syndrome unrelated to nesidioblastosis. *Arch Dis Child Fetal Neonatal Ed*. 2000;82(2): F108–F112
- Hussain K, Flanagan SE, Smith VV, et al. An ABCC8 gene mutation and mosaic uniparental isodisomy resulting in atypical diffuse congenital

- hyperinsulinism. *Diabetes*. 2008;57(1):259–263
7. Otonkoski T, Nääntö-Salonen K, Seppänen M, et al. Noninvasive diagnosis of focal hyperinsulinism of infancy with [¹⁸F]-DOPA positron emission tomography. *Diabetes*. 2006;55(1):13–18
 8. Flanagan SE, Clauin S, Bellanné-Chantelot C, et al. Update of mutations in the genes encoding the pancreatic beta-cell K(ATP) channel subunits Kir6.2 (KCNJ11) and sulfonylurea receptor 1 (ABCC8) in diabetes mellitus and hyperinsulinism. *Hum Mutat*. 2009;30(2):170–180
 9. Thomas PM, Cote GJ, Wohlk N, et al. Mutations in the sulfonylurea receptor gene in familial persistent hyperinsulinemic hypoglycemia of infancy. *Science*. 1995;268(5209):426–429
 10. Ainsley-Green A, Hussain K, Hall J, et al. Practical management of hyperinsulinism in infancy. *Arch Dis Child Fetal Neonatal Ed*. 2000;82(2):F98–F107
 11. Arnoux JB, de Lonlay P, Ribeiro MJ, et al. Congenital hyperinsulinism. *Early Hum Dev*. 2010;86(5):287–294
 12. Durmaz E, Flanagan SE, Parlak M, Ellard S, Akcurin S, Bircan I. A combination of nifedipine and octreotide treatment in an hyperinsulinemic hypoglycemic infant. *J Clin Res Pediatr Endocrinol*. 2014;6(2):119–121
 13. Arya VB, Mohammed Z, Blankenstein O, De Lonlay P, Hussain K. Hyperinsulinaemic hypoglycaemia. *Horm Metab Res*. 2014;46(3):157–170
 14. Beltrand J, Caquard M, Arnoux JB, et al. Glucose metabolism in 105 children and adolescents after pancreatectomy for congenital hyperinsulinism. *Diabetes Care*. 2012;35(2):198–203
 15. Shah P, Arya VB, Flanagan SE, et al. Sirolimus therapy in a patient with severe hyperinsulinaemic hypoglycaemia due to a compound heterozygous ABCC8 gene mutation. *J Pediatr Endocrinol Metab*. 2015;28(5–6):695–699
 16. Bourcier ME, Sherrod A, DiGuardo M, Vinik AI. Successful control of intractable hypoglycemia using rapamycin in an 86-year-old man with a pancreatic insulin-secreting islet cell tumor and metastases. *J Clin Endocrinol Metab*. 2009;94(9):3157–3162
 17. Kulke MH, Bergsland EK, Yao JC. Glycemic control in patients with insulinoma treated with everolimus. *N Engl J Med*. 2009;360(2):195–197
 18. Laje P, Halaby L, Adzick NS, Stanley CA. Necrotizing enterocolitis in neonates receiving octreotide for the management of congenital hyperinsulinism. *Pediatr Diabetes*. 2010;11(2):142–147
 19. Mao S, Zhang A, Huang S. Sirolimus in severe hyperinsulinemic hypoglycemia. *N Engl J Med*. 2014;370(25):2448–2449

Severe Hyperinsulinemic Hypoglycemia in a Neonate: Response to Sirolimus Therapy

Ünoke Méder, Géza Bokodi, Lúdia Balogh, Anna Körner, Miklós Szabó, Stepanka Pruhova and Attila J. Szabó
Pediatrics 2015;136:e1369

DOI: 10.1542/peds.2014-4200 originally published online October 26, 2015;

Updated Information & Services	including high resolution figures, can be found at: http://pediatrics.aappublications.org/content/136/5/e1369
References	This article cites 19 articles, 6 of which you can access for free at: http://pediatrics.aappublications.org/content/136/5/e1369#BIBL
Subspecialty Collections	This article, along with others on similar topics, appears in the following collection(s): Endocrinology http://www.aappublications.org/cgi/collection/endocrinology_sub Fetus/Newborn Infant http://www.aappublications.org/cgi/collection/fetus:newborn_infant_sub Neonatology http://www.aappublications.org/cgi/collection/neonatology_sub
Permissions & Licensing	Information about reproducing this article in parts (figures, tables) or in its entirety can be found online at: http://www.aappublications.org/site/misc/Permissions.xhtml
Reprints	Information about ordering reprints can be found online: http://www.aappublications.org/site/misc/reprints.xhtml

American Academy of Pediatrics

DEDICATED TO THE HEALTH OF ALL CHILDREN™



PEDIATRICS®

OFFICIAL JOURNAL OF THE AMERICAN ACADEMY OF PEDIATRICS

Severe Hyperinsulinemic Hypoglycemia in a Neonate: Response to Sirolimus Therapy

Ünoke Méder, Géza Bokodi, Lídia Balogh, Anna Körner, Miklós Szabó, Stepanka Pruhova and Attila J. Szabó

Pediatrics 2015;136:e1369

DOI: 10.1542/peds.2014-4200 originally published online October 26, 2015;

The online version of this article, along with updated information and services, is located on the World Wide Web at:

<http://pediatrics.aappublications.org/content/136/5/e1369>

Data Supplement at:

<http://pediatrics.aappublications.org/content/suppl/2015/10/21/peds.2014-4200.DCSupplemental>

Pediatrics is the official journal of the American Academy of Pediatrics. A monthly publication, it has been published continuously since 1948. Pediatrics is owned, published, and trademarked by the American Academy of Pediatrics, 141 Northwest Point Boulevard, Elk Grove Village, Illinois, 60007. Copyright © 2015 by the American Academy of Pediatrics. All rights reserved. Print ISSN: 1073-0397.

American Academy of Pediatrics

DEDICATED TO THE HEALTH OF ALL CHILDREN™

