

Butyrfentanyl Overdose Resulting in Diffuse Alveolar Hemorrhage

Jon B. Cole, MD^a, John F. Dunbar, MD^b, Sarah A. McIntire, MD^c, Warren E. Regelman, MD^d, Tina M. Slusher, MD^e

abstract

Butyrfentanyl is a potent short-acting opioid and a fentanyl analog with uncertain clinical effects. A review of the literature reveals no human case reports of butyrfentanyl overdose. As the use of analog and synthetic drugs continues to increase, clinicians are often faced with tremendous uncertainty when they encounter patients exposed to these synthetic drugs. We describe, to our knowledge, the first case of a butyrfentanyl overdose that resulted in clinically significant hemoptysis, acute lung injury, hypoxic respiratory failure, and diffuse alveolar hemorrhage. Complicating this case was a false-positive urine drug screen for fentanyl. Clinicians who encounter fentanyl exposures should be aware they may in fact be dealing with butyrfentanyl. As little is known of butyrfentanyl and our patient suffered a significant pulmonary hemorrhage, those who encounter butyrfentanyl exposures should monitor for hemorrhagic complications.

^aDepartment of Emergency Medicine, Hennepin Regional Poison Center, ^bDivision of Critical Care Medicine, Department of Pediatrics, and ^cTransitional Residency at Hennepin County Medical Center, Minneapolis, Minnesota; ^dDepartments of Pediatrics and Medicine, and ^eDivision of Pulmonary Medicine, Department of Pediatrics, University of Minnesota Medical School, Minneapolis, Minnesota

Dr Cole conceptualized the manuscript, provided medical toxicology consultation for the patient, and drafted the initial manuscript; Dr Dunbar provided inpatient care for the patient, assisted in obtaining laboratory data and correspondence with the Bureau of Criminal Apprehension, and reviewed and revised the manuscript; Dr McIntire provided pulmonary consultation care for the patient, assisted in obtaining clinical images, and reviewed and revised the manuscript; Dr Regelman provided pulmonary consultation care for the patient including bronchoscopy, and reviewed and revised the manuscript; Dr Slusher provided mentorship for Dr Cole in conceptualizing the manuscript, provided intensive care for the patient, and critically reviewed and revised the manuscript; and all authors approved the final manuscript as submitted.

www.pediatrics.org/cgi/doi/10.1542/peds.2014-2878

DOI: 10.1542/peds.2014-2878

Accepted for publication Dec 2, 2014

Address correspondence to Jon B. Cole, MD, Hennepin Regional Poison Center, 701 Park Ave, Minneapolis, MN 55415. E-mail: jon.cole@hcmcd.org

PEDIATRICS (ISSN Numbers: Print, 0031-4005; Online, 1098-4275).

Copyright © 2015 by the American Academy of Pediatrics

FINANCIAL DISCLOSURE: The authors have indicated they have no financial relationships relevant to this article to disclose.

FUNDING: No external funding.

POTENTIAL CONFLICT OF INTEREST: The authors have indicated they have no potential conflicts of interest to disclose.

Opioid overdoses are a growing problem in the United States, rivaling other major sources of morbidity and mortality, such as motor vehicle collisions.¹ The burden of disease has become great enough that the US Centers for Disease Control and Prevention has declared opioid overdoses to be at epidemic levels.² Complicating this problem further is the rise in abuse of synthetic opioids that are not approved by the Food and Drug Administration, the clinical effects of which are less well understood and perhaps more dangerous than more common opioids, such as heroin and oxycodone.³ For example, acetyl fentanyl has been hypothesized to be exceptionally dangerous because of the narrow range between its effective dose and lethal dose.⁴

Butyrfentanyl is a potent short-acting opioid and an analog of fentanyl; in fact, its chemical structure differs only by 1 methyl group from fentanyl.⁴ There are virtually no human data on butyrfentanyl in humans, particularly in overdose. To our knowledge, we report the first human case of

a butyrfentanyl overdose, which resulted in clinically significant hemoptysis, acute lung injury, and diffuse alveolar hemorrhage.

CASE DESCRIPTION

An 18-year-old male high school student with a past medical history of intravenous heroin abuse was found by his mother unconscious with labored breathing. Drug paraphernalia, including a rolled up dollar bill, was found at the scene. Emergency Medical Services was activated, and on arrival found the patient obtunded with gurgling respirations. His mental status drastically improved with 0.4 mg of intravenous naloxone, and he was transported to a local emergency department (ED). In the ED, his vital signs were as follows: temperature 37.3°C, heart rate 113 beats per minute, blood pressure 105/70 mm Hg, respiratory rate 28 breaths per minute, and pulse oximetry 97% on 15 L/min of oxygen by facemask. He stated he had been in good health recently and that just before becoming unconscious he had snorted what he believed to be

acetyl fentanyl that he had purchased surreptitiously on the Internet. On waking after receiving naloxone, he complained of dyspnea and was noted to be coughing up frank blood in the ED (Fig 1). Physical examination in the ED was notable for an alert patient oriented to person, place, and time with tachypnea, blood in his nares, an increased work of breathing, and coarse rales in all lung fields on auscultation. His initial chest radiograph was notable for bilateral “batwing”-shaped perihilar predominant airspace opacities with diffuse increased interstitial markings (Fig 2). Laboratory values were as follows: white blood cell count 17.6 k/cmm, platelets 217 k/cmm, hemoglobin 15.5 g/dL, sodium 136 mEq/L, potassium 3.6 mEq/L, chloride 108 mEq/L, bicarbonate 25 mEq/L, creatinine 1.06 mg/dL, glucose 142 mg/dL, aspartate aminotransferase 37 IU/L, alanine aminotransferase 22 IU/L, total creatine kinase 318 IU/L, troponin 0.103 µg/L, pro-brain natriuretic peptide 41 pg/mL, activated partial thromboplastin time 27.3 seconds, prothrombin time 15.3 seconds, fibrinogen 309 mg/dL, and lactate 0.8 mmol/L. Urine drug screening was negative for cocaine,



FIGURE 1
The patient's hemoptysis in a suction canister.

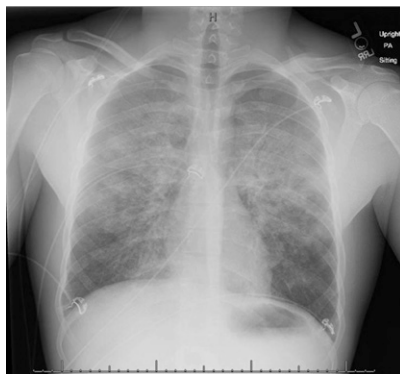

FIGURE 2
PA chest film demonstrating bilateral “batwing”-shaped perihilar opacities with diffuse interstitial markings.

methamphetamine, and other sympathomimetics. Immunoassays for opiates and fentanyl were both positive; however, high-performance liquid chromatography and mass spectrometry revealed no evidence of fentanyl. The substance snorted by the patient was identified by the Bureau of Criminal Apprehension by using high-performance gas chromatography and mass spectrometry as butyrfentanyl.

In the PICU, the patient became progressively more dyspneic, eventually failing noninvasive positive-pressure ventilation and requiring intubation. Bronchoscopy revealed thin red-tinged secretions with subepithelial petechiae and progressive reddening of fluid returns from bronchoalveolar lavage (Fig 3). Cytology of this fluid showed numerous red blood cells and hemosiderin-laden macrophages. Serial hemoglobin measurements revealed a progressive decline from 15.5 g/dL in the ED to 12.3 g/dL the next day. These results are consistent with diffuse alveolar hemorrhage; there was no evidence of airway wall edema, airway epithelial sloughing, or carbon particles. Echocardiography revealed an ejection fraction of 55% to 60% with no wall-motion abnormalities. Sedation was difficult; the patient required drips of fentanyl (100 µg/h), midazolam (5 mg/h), and dexmedetomidine (2.0 µg/kg/h)

simultaneously to maintain adequate sedation. The patient required prolonged ventilation for a drug overdose and could not be extubated until hospital day 4. He was discharged from the hospital on hospital day 7 after treatment of ventilator-associated pneumonia. He suffered no known permanent adverse sequelae.

DISCUSSION

To our knowledge, this is the first well-documented case of butyrfentanyl overdose. Our patient experienced pulmonary edema and acute lung injury (ALI), as well as diffuse alveolar hemorrhage. Although pulmonary edema and ALI are well described in opioid overdose,⁵ diffuse alveolar hemorrhage is far less common.⁶ The exact mechanisms for opioid-related pulmonary edema are not agreed on; however, the proposed mechanisms may provide insight and plausibility into why our patient suffered hemoptysis and diffuse alveolar hemorrhage.

One theory on opioid-related ALI is that the opioid antagonist naloxone is responsible. In this model, the administration of naloxone and subsequent rapid precipitation of opioid withdrawal causes a massive increase in blood catecholamines. This rise in catecholamines creates a tremendous afterload increase, with resulting cardiac strain leading to fluid accumulation in the alveoli; thus, in effect this theory suggests opioid-related ALI is in fact “cardiogenic” pulmonary edema. This theory is supported by numerous anecdotal human cases, as well as animal evidence in which opioid-naïve canines intoxicated on fentanyl had significant increases in catecholamine concentrations after naloxone infusion.^{7,8} This theory is also supported by a series of opioid-naïve patients given opioids while undergoing surgery who developed opioid-related ALI after the administration of naloxone.⁹

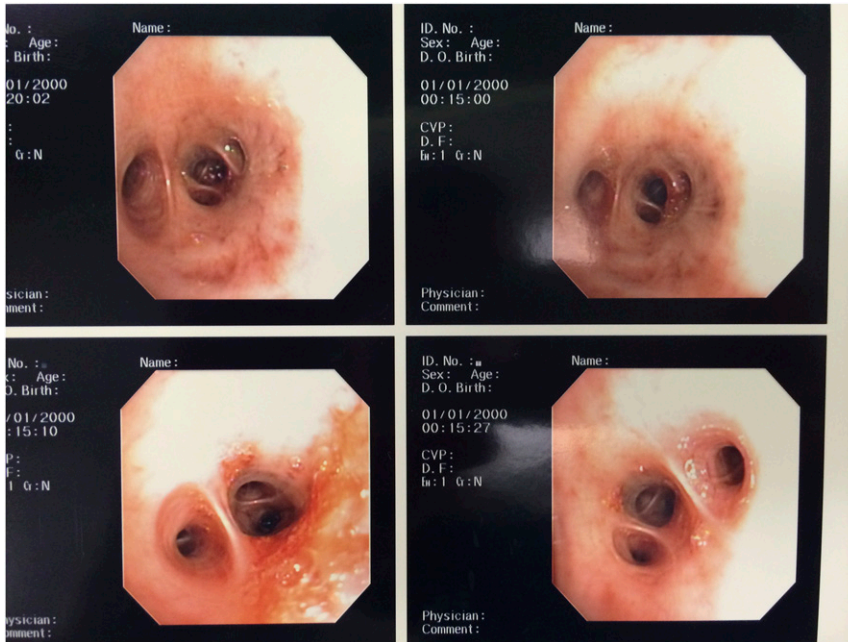


FIGURE 3 Bronchoscopy images revealing bloody secretions and subepithelial petechiae.

A second theory purports that negative-pressure barotrauma is to blame for opioid-related ALI. In this theory, a closed glottis made lax from opioid intoxication is inhaled against; this negative intrathoracic pressure creates a pressure gradient that draws fluid into the alveolar space. Sound reasoning supports this theory. Opioid-related ALI is described to occur in the absence of naloxone. In fact, it was first described in the 19th century, long before naloxone had been synthesized.¹⁰ This mechanism has even been described to cause pulmonary hemorrhage, which may explain our patient's findings.¹¹ One can imagine the additional load of catecholamines precipitated by the administration of naloxone contributing further to pulmonary hemorrhage.

Little is known of butyrfentanyl; published literature involves primarily rodent experiments. Animal evidence suggests butyrfentanyl is 7 times more potent than morphine but only 0.13 the potency of fentanyl.⁴ Despite the dramatic difference in potency compared with fentanyl, the cross-reactivity on immunoassay between the 2 is high. Compared with

other fentanyl analogs, butyrfentanyl is extremely likely to cross-react on a fentanyl immunoassay; cross-reactivity with fentanyl on immunoassay was 77% in 1 study and was higher than all other fentanyl analogs in another, reacting at nearly the same rate as fentanyl.^{12,13} This was consistent with the false-positive fentanyl immunoassay in our patient, which is an important finding that clinicians should note for presumed future fentanyl exposures.

Additionally, it is of note that mice poisoned with butyrfentanyl had significant bleeding in the small intestines on autopsy.⁴ No proposed mechanism, however, was provided by the authors of this study. The clinical significance of this in humans is of course uncertain, but given that our patient suffered significant hemorrhage, those who also encounter butyrfentanyl exposures should monitor for hemorrhagic complications.

CONCLUSIONS

We present a case of butyrfentanyl overdose in a teenage boy resulting in hemoptysis and diffuse alveolar

hemorrhage. In this case, the clinical urine drug screen was false-positive for fentanyl; clinicians should be aware this might actually represent a butyrfentanyl exposure. This case also highlights that although drug users may attempt to purchase 1 chemical on the Internet, the reliability of the substance received is highly dubious. As there are virtually no human data on butyrfentanyl overdose, clinicians encountering this synthetic opioid should monitor for diffuse alveolar hemorrhage.

ACKNOWLEDGMENTS

We acknowledge the Hennepin Regional Poison Center and Hennepin County Medical Center Departments of Emergency Medicine and Pediatrics for their assistance in the care of this patient.

REFERENCES

1. Kuehn BM. Poisonings top crashes for injury-related deaths. *JAMA*. 2012;307(3):242
2. Centers for Disease Control and Prevention (CDC). Vital signs: overdoses of prescription opioid pain relievers—United States, 1999–2008. *MMWR Morb Mortal Wkly Rep*. 2011;60(43):1487–1492
3. Centers for Disease Control and Prevention (CDC). Acetyl fentanyl overdose fatalities—Rhode Island, March–May 2013. *MMWR Morb Mortal Wkly Rep*. 2013;62(34):703–704
4. Higashikawa Y, Suzuki S. Studies on 1-(2-phenethyl)-4-(N-propionylanilino) piperidine (fentanyl) and its related compounds. VI. Structure-analgesic activity relationship for fentanyl, methyl-substituted fentanyls and other analogues. *Forensic Toxicol*. 1998;26(1):1–5
5. Duberstein JL, Kaufman DM. A clinical study of an epidemic of heroin intoxication and heroin-induced pulmonary edema. *Am J Med*. 1971;51(6):704–714
6. Porter R, O'Reilly H. Pulmonary hemorrhage: a rare complication of opioid overdose. *Pediatr Emerg Care*. 2011;27(8):742–744
7. Mills CA, Flacke JW, Miller JD, Davis LJ, Bloor BC, Flacke WE. Cardiovascular effects of fentanyl reversal by naloxone

- at varying arterial carbon dioxide tensions in dogs. *Anesth Analg*. 1988; 67(8):730–736
8. Mills CA, Flacke JW, Flacke WE, Bloor BC, Liu MD. Narcotic reversal in hypercapnic dogs: comparison of naloxone and nalbuphine. *Can J Anaesth*. 1990;37(2):238–244
9. Prough DS, Roy R, Bumgarner J, Shannon G. Acute pulmonary edema in healthy teenagers following conservative doses of intravenous naloxone. *Anesthesiology*. 1984;60(5): 485–486
10. Osler W. Oedema of the left lung-Morphia poisoning. *Montreal Gen Hosp Rep*. 1880; 1:291–293
11. Schwartz DR, Maroo A, Malhotra A, Kesselman H. Negative pressure pulmonary hemorrhage. *Chest*. 1999; 115(4):1194–1197
12. Alburges ME, Hanson GR, Gibb JW, Sakashita CO, Rollins DE. Fentanyl receptor assay. II. Utilization of a radioreceptor assay for the analysis of fentanyl analogs in urine. *J Anal Toxicol*. 1992;16(1):36–41
13. Ruangyuttikarn W, Law MY, Rollins DE, Moody DE. Detection of fentanyl and its analogs by enzyme-linked immunosorbent assay. *J Anal Toxicol*. 1990;14(3):160–164

Butyrfentanyl Overdose Resulting in Diffuse Alveolar Hemorrhage
Jon B. Cole, John F. Dunbar, Sarah A. McIntire, Warren E. Regelman and Tina M. Slusher

Pediatrics 2015;135:e740

DOI: 10.1542/peds.2014-2878 originally published online February 23, 2015;

Updated Information & Services	including high resolution figures, can be found at: http://pediatrics.aappublications.org/content/135/3/e740
References	This article cites 12 articles, 0 of which you can access for free at: http://pediatrics.aappublications.org/content/135/3/e740#BIBL
Subspecialty Collections	This article, along with others on similar topics, appears in the following collection(s): Pharmacology http://www.aappublications.org/cgi/collection/pharmacology_sub Toxicology http://www.aappublications.org/cgi/collection/toxicology_sub Substance Use http://www.aappublications.org/cgi/collection/substance_abuse_sub
Permissions & Licensing	Information about reproducing this article in parts (figures, tables) or in its entirety can be found online at: http://www.aappublications.org/site/misc/Permissions.xhtml
Reprints	Information about ordering reprints can be found online: http://www.aappublications.org/site/misc/reprints.xhtml

American Academy of Pediatrics

DEDICATED TO THE HEALTH OF ALL CHILDREN™



PEDIATRICS®

OFFICIAL JOURNAL OF THE AMERICAN ACADEMY OF PEDIATRICS

Butyrfentanyl Overdose Resulting in Diffuse Alveolar Hemorrhage
Jon B. Cole, John F. Dunbar, Sarah A. McIntire, Warren E. Regelman and Tina M. Slusher

Pediatrics 2015;135:e740

DOI: 10.1542/peds.2014-2878 originally published online February 23, 2015;

The online version of this article, along with updated information and services, is located on the World Wide Web at:

<http://pediatrics.aappublications.org/content/135/3/e740>

Pediatrics is the official journal of the American Academy of Pediatrics. A monthly publication, it has been published continuously since 1948. Pediatrics is owned, published, and trademarked by the American Academy of Pediatrics, 141 Northwest Point Boulevard, Elk Grove Village, Illinois, 60007. Copyright © 2015 by the American Academy of Pediatrics. All rights reserved. Print ISSN: 1073-0397.

American Academy of Pediatrics

DEDICATED TO THE HEALTH OF ALL CHILDREN™

