

# Intrapulmonary Recombinant Factor VIIa for Diffuse Alveolar Hemorrhage in Children

Jeong A. Park, MD, PhD, Byoung-Ju Kim, MD, PhD

## abstract

Diffuse alveolar hemorrhage (DAH) is a life-threatening pulmonary complication in patients with hematologic malignancies or autoimmune disorders, and it has a high mortality rate. The current treatment options of corticosteroids, transfusions, and immunosuppressants have been limited and largely unsuccessful, and they can be accompanied by multiple complications. Intrapulmonary administration of recombinant activated factor VII (rFVIIa) has been reported in adults, but there are scarce data on its use in children. The present article reviews our institutional experience with intrapulmonary rFVIIa for the treatment of DAH in children. The study included 6 pediatric patients with acute, bronchoscopically confirmed DAH treated between 2011 and 2013. The median age was 11 years, and patient diagnoses were as follows: acute myeloid leukemia (2 patients), myelodysplastic syndrome (1 patient), hemophagocytic lymphohistiocytosis (1 patient), T-cell lymphoblastic lymphoma (1 patient), and idiopathic pulmonary hemosiderosis (1 patient). These patients were treated with intrapulmonary rFVIIa concurrent with methylprednisolone, fresh-frozen plasma, and maintenance of the platelet count  $>50\,000/\text{mm}^3$ . Complete and sustained hemostasis after rFVIIa treatment and an absence of adverse events were observed in all patients. The  $\text{PaO}_2/\text{fraction of inspired oxygen ratio}$  increased significantly, and rapid clinical improvements were observed. Two patients who received hematopoietic stem cell transplantation died of subsequent respiratory syncytial virus and *Acinetobacter baumannii* infections, but the other 4 patients exhibited rapid improvement, were successfully weaned from ventilators, and experienced long-term survival. Our findings indicate that intrapulmonary administration of rFVIIa is an effective and safe treatment option for children with DAH; however, further clinical studies are needed.

Department of Pediatrics, Haeundae-Paik Hospital, Inje University College of Medicine, Busan, Republic of Korea

Dr Park conceptualized and designed the study, drafted the initial manuscript, reviewed and revised the manuscript, and submitted the final manuscript; and Dr Kim reviewed the manuscript. Both authors approved the final manuscript as submitted.

[www.pediatrics.org/cgi/doi/10.1542/peds.2014-1782](http://www.pediatrics.org/cgi/doi/10.1542/peds.2014-1782)

DOI: 10.1542/peds.2014-1782

Accepted for publication Oct 7, 2014

Address correspondence to Jeong A. Park, MD, PhD, Department of Pediatrics, Haeundae-Paik Hospital, Inje University College of Medicine, 875, Haeundae-ro, Haeundae-gu, Busan, Republic of Korea 612030. E-mail: [jeonga95@gmail.com](mailto:jeonga95@gmail.com)

PEDIATRICS (ISSN Numbers: Print, 0031-4005; Online, 1098-4275).

Copyright © 2015 by the American Academy of Pediatrics

**FINANCIAL DISCLOSURE:** The authors have indicated they have no financial relationships relevant to this article to disclose.

**FUNDING:** No external funding.

**POTENTIAL CONFLICT OF INTEREST:** The authors have indicated they have no potential conflicts of interest to disclose.

## INTRODUCTION

Diffuse alveolar hemorrhage (DAH) is characterized by widespread bleeding into the alveoli due to injury to the alveolar capillary endothelium and alveolar inflammation.<sup>1-3</sup> Extensive pulmonary inflammation leads to abundant intra-alveolar expression of tissue factor, resulting in marked increases in molecular markers of thrombin generation in bronchoalveolar lavage fluid.

For pulmonary hemorrhage, treatment has relied on different nonspecific treatment modalities without evidence of efficacy. Recently, some reports have recommended the intrapulmonary use of recombinant activated factor VII (rFVIIa).<sup>4</sup> Our data on the use of this agent in children, however, are scarce.<sup>5</sup> We report here our institutional experience with intrapulmonary rFVIIa for the treatment of DAH in children.

## CASE REPORT

This study included 6 pediatric patients diagnosed with DAH and treated at Haeundae Paik Hospital between 2011 and 2013. The detailed characteristics of the patients are presented in Table 1. Two patients (unique patient numbers [UPNs] 1 and 6) had previously received hematopoietic stem cell transplantation (HSCT). DAH developed on day 31 and day 30 after HSCT, respectively. UPN1 had received total body irradiation (900 cGy), fludarabine (75 mg/m<sup>2</sup>), and cyclophosphamide (120 mg/kg) as a conditioning regimen. UPN6 had received a conditioning regimen consisting of busulfan (8.8 mg/kg), fludarabine (150 mg/m<sup>2</sup>), cyclophosphamide (100 mg/kg), and rabbit antithymocyte globulin (7.5 mg/kg). UPN1 experienced grade IV hemorrhagic cystitis and thrombotic microangiopathy (TMA), and UPN6 developed grade III hepatic sinusoidal obstruction syndrome (SOS) and cytomegalovirus antigenemia. UPN2 developed acute respiratory distress and a massive pulmonary hemorrhage on day 5 of induction chemotherapy, and he was believed to have cytarabine syndrome (fever, myalgia, bone pain, nonspecific rash, conjunctivitis, and occasionally pericarditis and acute respiratory distress syndrome) while undergoing treatment with cytarabine.<sup>6,7</sup> UPN3 had been admitted for chickenpox infection during continuation chemotherapy and developed 6-mercaptopurine-associated hepatic SOS and chickenpox pneumonia

despite intravenous acyclovir treatment. Eleven days after admission, he had difficulty in breathing, coughing, and hemoptysis. The patient was intubated, and fresh blood spurting from the endotracheal tube. UPN4 was admitted to the ICU for hemoptysis and acute respiratory failure at the time of diagnosis. He had marked thrombocytopenia and severe disseminated intravascular coagulation (DIC); chest radiographs showed diffuse alveolar infiltrates, indicating pulmonary hemorrhage. UPN5 was admitted to the ICU for acute respiratory distress and hemoptysis. Her hemoglobin level decreased to 3.3 g/dL, and chest radiograph showed bilateral alveolar infiltrates indicating pulmonary hemorrhage. She was intubated and placed on a mechanical ventilator; bronchoscopy revealed ongoing, active bleeding bilaterally from the bronchial trees.

All patients were treated with rFVIIa (NovoSeven, NovoNordisk, Bagsvaerd, Denmark) administered by bronchoscopy (Table 2). The dose of rFVIIa was ~5.0 μg/kg, dissolved in 25 to 50 mL of normal saline by bronchoalveolar lavage with 5 to 10 mL in each of the 5 main bronchi.<sup>8</sup> The treatment efficacy of rFVIIa was graded as an excellent, good, or poor response. An excellent response was defined as complete and sustained hemostasis after a single treatment with rFVIIa; a good response was defined when repeated intrapulmonary administrations were required to obtain hemostasis; and a poor response was defined as the

lack of any effect on bleeding.<sup>8</sup> For UPN6, the rFVIIa immediately spewed from the endotracheal tube with a massive amount of blood as soon as it was administered, and the bronchoscope was removed. The second dose was administered 30 minutes later, and immediate hemostasis was observed. All patients exhibited immediate cessation of pulmonary bleeding, and complications associated with rFVIIa were not observed in any of the patients. All patients received concurrent corticosteroids; 4 received high-dose methylprednisolone (15–30 mg/kg per day for 3 days), and the other 2 patients (UPN3 and UPN4) received a lower dose of methylprednisolone (2 mg/kg per day for 5 days). Supportive treatment was continued, including platelet transfusions, to maintain platelet counts >50 000/mm<sup>3</sup> and infusions of fresh-frozen plasma and cryoprecipitates.

For all patients, the Pao<sub>2</sub>/fraction of inspired oxygen ratios significantly increased on subsequent days ( $P = .03$ ) (Fig 1), and 5 patients were successfully weaned from ventilators within a few days (median: 2 days; range: 1–7 days). However, 3 of the 6 patients developed significant infections. UPN1 developed respiratory syncytial virus pneumonia and died of respiratory failure with diffuse lung fibrosis after 54 days of DAH (day 85 of umbilical cord blood transplantation). UPN2 developed carbapenem-resistant *Pseudomonas aeruginosa* sepsis, and UPN6 developed carbapenem-resistant *Acinetobacter baumannii* infection. UPN2 was successfully treated with colistin and tigecycline, but UPN6 died of septic shock after 21 days of DAH. The remaining 3 patients experienced no significant complications. UPN3 and UPN4 successfully finished chemotherapy and were doing well at 28 and 20 months, respectively. UPN5 was diagnosed with idiopathic pulmonary hemosiderosis according to lung

**TABLE 1** Patient Characteristics

UPN	Gender	Age	Diagnosis	History Before DAH
1	Female	11 y	MDS	UCBT, HC, and TMA
2	Male	15 y	AML	Day 5 of induction chemotherapy, DIC, cytarabine syndrome
3	Male	6 y	T-LL	Maintenance chemotherapy, chickenpox infection, hepatic SOS
4	Male	14 y	AML	DIC
5	Female	11 y	IPH	History of recurrent pneumonia and iron-deficiency anemia
6	Female	10 mo	HLH	uPBSCT, CMV infection, hepatic SOS

AML, acute myeloid leukemia; CMV, cytomegalovirus; HC, hemorrhagic cystitis; HLH, hemophagocytic lymphohistiocytosis; IPH, idiopathic pulmonary hemosiderosis; MDS, myelodysplastic syndrome; T-LL, T-cell lymphoblastic lymphoma; UCBT, umbilical cord blood transplantation; uPBSCT, unrelated peripheral blood stem cell transplantation.

**TABLE 2** Treatment Outcomes of Intrapulmonary rFVIIa Treatment

UPN	No. of Administrations	Dose, $\mu\text{g}/\text{kg}$	rFVIIa Effects	Complications	Time to Weaning, d	Rebleeding After rFVIIa Treatment	FEV <sub>1</sub> /FVC Ratio (Times After DAH)	Survival <sup>a</sup>
1	1	60	Excellent	No	7	No	NA	Death due to RSV pneumonia (+54 d)
2	1	45	Excellent	No	2	No	88% (3 mo)	Survived but died with relapsed leukemia (16 mo)
3	1	43	Excellent	No	5	No	85% (4 mo)	Survived (28 mo)
4	1	52	Excellent	No	2	No	97% (4 mo)	Survived (20 mo)
5	1	57	Excellent	No	1	No	86% (3 mo)	Survived (27 mo)
6	2	63	Good	No	No	No	NA	Death due to septic shock (+21 d)

FEV<sub>1</sub>, forced expiratory volume in 1 second; FVC, forced vital capacity; NA, not available; RSV, respiratory syncytial virus.

<sup>a</sup> Survival to hospital discharge (the date of death or last follow-up after DAH).

biopsy results after recovery. She did not experience DAH again on maintenance therapy with methotrexate over 27 months. UPN2 died of relapsed leukemia after 16 months of DAH.

## DISCUSSION

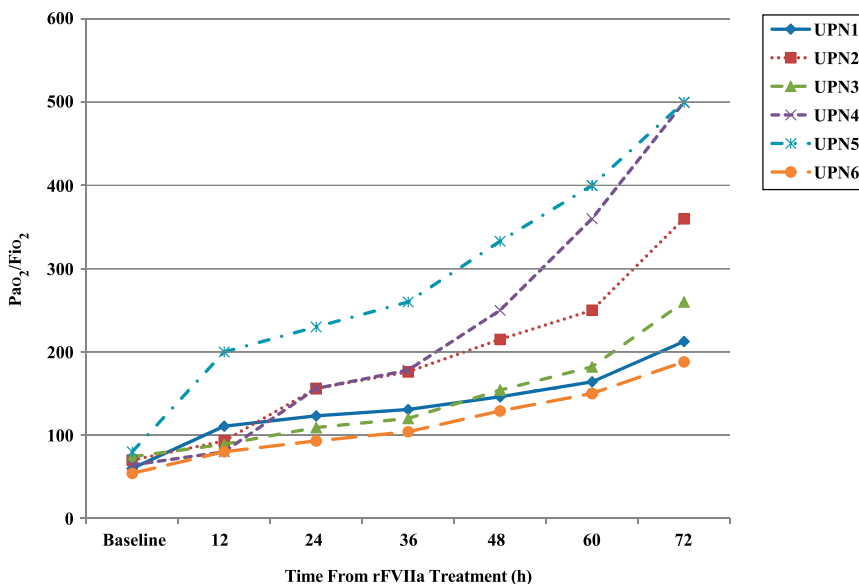
DAH can develop after HSCT, chemotherapy, sepsis, and DIC, as well as in patients with autoimmune disorders; mortality rates exceed 75% in patients with acute macroscopic hemorrhage.<sup>1,9</sup> It has been recommended that treatment of DAH be based on the underlying cause of hemorrhage, with corticosteroids as a mainstay of treatment in most cases, aimed at reducing possible acute inflammatory responses to hemorrhage induced by

lung alveolar epithelial swelling, thrombotic microangiopathy, and inflammatory cells and cytokines.<sup>10–13</sup>

DAH after HSCT is a grave complication that significantly increases treatment-related mortality. Although initially described after autologous transplantation, recent reports have suggested an increasing frequency of this complication after allogeneic transplantation (up to 20%).<sup>2</sup> The cause of DAH after HSCT is not fully understood; vascular damage and inflammation from chemotherapy and total body irradiation used in the conditioning regimen, immunologic causes such as allogeneic stem cell sources, and graft-versus-host disease, thrombocytopenia, renal

insufficiency, and pulmonary infection have been implicated.<sup>2,14</sup> The recommended treatment regimen for DAH in HSCT recipients includes the early use of high-dose corticosteroids, platelet transfusions, and mechanical ventilator support for acute respiratory failure. Treatment with high-dose corticosteroids is typically initiated with intravenous methylprednisolone, 500 mg to 2 g/day for the first 3 to 5 days, followed by a gradual tapering over the next 2 to 4 weeks.<sup>9,15,16</sup> However, despite the widespread use of high-dose corticosteroids for DAH, the overall mortality has remained high.<sup>14</sup> The increased risk of opportunistic infections from fungal or atypical organisms remains a serious and possibly fatal complication of high-dose corticosteroid use, especially in immune-compromised hosts after HSCT.

Previous reports on the use of rFVIIa for active bleeding have focused on intravenous administration; however, satisfactory hemostasis has been achieved by multiple doses of rFVIIa, although these effects were transient in some cases.<sup>13,14,16,17</sup> For the use of rFVIIa for pulmonary hemorrhage, there is a gap between the alveolar compartment, where the effective drug-related receptors are located, and the vascular compartment. Intravenously administered rFVIIa might not reach the receptors in the alveoli sufficiently because they do not pass the alveolar-capillary membrane barriers. This effect requires higher doses of rFVIIa



**FIGURE 1** The changes in PaO<sub>2</sub>/fraction of inspired oxygen F<sub>i</sub>O<sub>2</sub> ratio after rFVIIa treatment.

(90–270  $\mu\text{g}/\text{kg}$ )<sup>13,16,18</sup> and is associated with a higher risk of adverse systemic effects.<sup>4,19,20</sup>

Thromboembolic complications are associated with higher doses of rFVIIa,<sup>21,22</sup> and there has been serious concern regarding the use of rFVIIa in children at increased risk for thromboembolic events, including those with DIC, hepatic SOS, and TMA.<sup>18,23,24</sup>

Recently, adult studies have reported the successful use of intrapulmonary rFVIIa for DAH. Even in severe macroscopic pulmonary bleeding, patients have been shown to respond rapidly. These effects are due to combined rFVIIa and its receptor tissue factor in the alveoli causing balanced and durable hemostases with improvement in oxygen transport capacity.<sup>25</sup> These effects also explain the lack of systemic adverse effects with locally administered rFVIIa.<sup>4</sup>

However, other than treatment of the underlying disease, such as with plasmapheresis, corticosteroids, and antibiotics, there has been no proposed intervention that can ensure pulmonary hemostasis in DAH in children. Our patients were treated with intrapulmonary rFVIIa, along with aggressive platelet, fresh-frozen plasma and corticosteroid treatment. They demonstrated rapid resolution of bleeding after 1 or 2 doses of rFVIIa and did not experience further bleeding episodes without additional doses of rFVIIa. Most were at high risk for thromboembolic events (DIC, hepatic SOS, and TMA), but none developed any thromboembolic complications.

Conversely, 2 patients who had received HSCT succumbed to infectious complications, which were implicated by pulmonary fibrosis as a reaction to DAH, compromised immune status after transplantation, and concomitant use of high-dose corticosteroids. Although inflammation is believed to play a role in the pathogenesis of DAH, the

use of high-dose corticosteroids can lead to overwhelming infections, such as in our cases.

Although this study was limited by the small number of patients, it shows that intrapulmonary rFVIIa can be successfully used in pediatric patients with DAH without significant thromboembolic complications. We propose that intrapulmonary rFVIIa be considered early in the treatment of DAH in children at high risk, in addition to treating the underlying disease. Additional clinical data including larger numbers of pediatric patients are needed, and considering the adverse effects of high-dose corticosteroids, the issue of optimization of corticosteroids requires serious thought and the emergence of some type of consensus.

#### REFERENCES

1. Huringa AJ, Leyva FJ, Giral SA, et al. Outcome of bone marrow transplantation patients requiring mechanical ventilation. *Crit Care Med*. 2000;28(4):1014–1017
2. Lewis ID, DeFor T, Weisdorf DJ. Increasing incidence of diffuse alveolar hemorrhage following allogeneic bone marrow transplantation: cryptic etiology and uncertain therapy. *Bone Marrow Transplant*. 2000;26(5):539–543
3. Agustí C, Ramirez J, Picado C, et al. Diffuse alveolar hemorrhage in allogeneic bone marrow transplantation. A postmortem study. *Am J Respir Crit Care Med*. 1995;151(4):1006–1010
4. Heslet L, Nielsen JD, Nepper-Christensen S. Local pulmonary administration of factor VIIa (rFVIIa) in diffuse alveolar hemorrhage (DAH)—a review of a new treatment paradigm. *Biologics*. 2012;6:37–46
5. Colin AA, Shafeian M, Andreansky M. Bronchoscopic instillation of activated recombinant factor VII to treat diffuse alveolar hemorrhage in a child. *Pediatr Pulmonol*. 2010;45(4):411
6. Castleberry RP, Crist WM, Holbrook T, Malluh A, Gaddy D. The cytosine arabinoside (Ara-C) syndrome. *Med Pediatr Oncol*. 1981;9(3):257–264
7. Andersson BS, Luna MA, Yee C, Hui KK, Keating MJ, McCredie KB. Fatal pulmonary failure complicating high-dose cytosine arabinoside therapy in acute leukemia. *Cancer*. 1990;65(5):1079–1084
8. Heslet L, Nielsen JD, Levi M, Sengeløv H, Johansson PI. Successful pulmonary administration of activated recombinant factor VII in diffuse alveolar hemorrhage. *Crit Care*. 2006;10(6):R177
9. Raptis A, Mavroudis D, Suffredini A, et al. High-dose corticosteroid therapy for diffuse alveolar hemorrhage in allogeneic bone marrow stem cell transplant recipients. *Bone Marrow Transplant*. 1999;24(8):879–883
10. Heggen J, West C, Olson E, et al. Diffuse alveolar hemorrhage in pediatric hematopoietic cell transplant patients. *Pediatrics*. 2002;109(5):965–971
11. Newsome BR, Morales JE. Diffuse alveolar hemorrhage. *South Med J*. 2011; 104(4):269–274
12. Susarla SC, Fan LL. Diffuse alveolar hemorrhage syndromes in children. *Curr Opin Pediatr*. 2007;19(3):314–320
13. Hicks K, Peng D, Gajewski JL. Treatment of diffuse alveolar hemorrhage after allogeneic bone marrow transplant with recombinant factor VIIa. *Bone Marrow Transplant*. 2002;30(12):975–978
14. Majhail NS, Parks K, DeFor TE, Weisdorf DJ. Diffuse alveolar hemorrhage and infection-associated alveolar hemorrhage following hematopoietic stem cell transplantation: related and high-risk clinical syndromes. *Biol Blood Marrow Transplant*. 2006;12(10):1038–1046
15. Afessa B, Tefferi A, Litzow MR, Krowka MJ, Wylam ME, Peters SG. Diffuse alveolar hemorrhage in hematopoietic stem cell transplant recipients. *Am J Respir Crit Care Med*. 2002;166(5):641–645
16. Pastores SM, Papadopoulos E, Voigt L, Halpern NA. Diffuse alveolar hemorrhage after allogeneic hematopoietic stem-cell transplantation: treatment with recombinant factor VIIa. *Chest*. 2003; 124(6):2400–2403
17. Toor AA, Slungaard A, Hedner U, Weisdorf DJ, Key NS. Acquired factor VII deficiency in hematopoietic stem cell transplant recipients. *Bone Marrow Transplant*. 2002;29(5):403–408
18. Alten JA, Benner K, Green K, Toole B, Tofil NM, Winkler MK. Pediatric off-label use of

- recombinant factor VIIa. *Pediatrics*. 2009; 123(3):1066–1072
19. Levi M, Levy JH, Andersen HF, Truloff D. Safety of recombinant activated factor VII in randomized clinical trials. *N Engl J Med*. 2010;363(19):1791–1800
  20. Stanworth SJ, Birchall J, Doree CJ, Hyde C. Recombinant factor VIIa for the prevention and treatment of bleeding in patients without haemophilia. *Cochrane Database Syst Rev*. 2007;(2):CD005011
  21. Yilmaz D, Karapinar B, Balkan C, Akisü M, Kavakli K. Single-center experience: use of recombinant factor VIIa for acute life-threatening bleeding in children without congenital hemorrhagic disorder. *Pediatr Hematol Oncol*. 2008;25(4):301–311
  22. Levy JH, Fingerhut A, Brott T, Langbakke IH, Erhardtson E, Porte RJ. Recombinant factor VIIa in patients with coagulopathy secondary to anticoagulant therapy, cirrhosis, or severe traumatic injury: review of safety profile. *Transfusion*. 2006;46(6):919–933
  23. Hedner U. Mechanism of action of recombinant activated factor VII: an update. *Semin Hematol*. 2006;43(1 suppl 1): S105–S107
  24. Pihusch M, Lohse P, Reitberger J, et al. Impact of thrombophilic gene mutations and graft-versus-host disease on thromboembolic complications after allogeneic hematopoietic stem-cell transplantation. *Transplantation*. 2004; 78(6):911–918
  25. Mariani G, Testa MG, Di Paolantonio T, Molskov Bech R, Hedner U. Use of recombinant, activated factor VII in the treatment of congenital factor VII deficiencies. *Vox Sang*. 1999;77(3): 131–136

# Intrapulmonary Recombinant Factor VIIa for Diffuse Alveolar Hemorrhage in Children

Jeong A. Park and Byoung-Ju Kim

*Pediatrics* 2015;135:e216

DOI: 10.1542/peds.2014-1782 originally published online December 29, 2014;

<b>Updated Information &amp; Services</b>	including high resolution figures, can be found at: <a href="http://pediatrics.aappublications.org/content/135/1/e216">http://pediatrics.aappublications.org/content/135/1/e216</a>
<b>References</b>	This article cites 25 articles, 2 of which you can access for free at: <a href="http://pediatrics.aappublications.org/content/135/1/e216#BIBL">http://pediatrics.aappublications.org/content/135/1/e216#BIBL</a>
<b>Subspecialty Collections</b>	This article, along with others on similar topics, appears in the following collection(s): <b>Critical Care</b> <a href="http://www.aappublications.org/cgi/collection/critical_care_sub">http://www.aappublications.org/cgi/collection/critical_care_sub</a> <b>Hematology/Oncology</b> <a href="http://www.aappublications.org/cgi/collection/hematology:oncology_sub">http://www.aappublications.org/cgi/collection/hematology:oncology_sub</a> <b>Blood Disorders</b> <a href="http://www.aappublications.org/cgi/collection/blood_disorders_sub">http://www.aappublications.org/cgi/collection/blood_disorders_sub</a>
<b>Permissions &amp; Licensing</b>	Information about reproducing this article in parts (figures, tables) or in its entirety can be found online at: <a href="http://www.aappublications.org/site/misc/Permissions.xhtml">http://www.aappublications.org/site/misc/Permissions.xhtml</a>
<b>Reprints</b>	Information about ordering reprints can be found online: <a href="http://www.aappublications.org/site/misc/reprints.xhtml">http://www.aappublications.org/site/misc/reprints.xhtml</a>

American Academy of Pediatrics

DEDICATED TO THE HEALTH OF ALL CHILDREN™





# PEDIATRICS®

OFFICIAL JOURNAL OF THE AMERICAN ACADEMY OF PEDIATRICS

## **Intrapulmonary Recombinant Factor VIIa for Diffuse Alveolar Hemorrhage in Children**

Jeong A. Park and Byoung-Ju Kim

*Pediatrics* 2015;135:e216

DOI: 10.1542/peds.2014-1782 originally published online December 29, 2014;

The online version of this article, along with updated information and services, is located on the World Wide Web at:

<http://pediatrics.aappublications.org/content/135/1/e216>

Pediatrics is the official journal of the American Academy of Pediatrics. A monthly publication, it has been published continuously since 1948. Pediatrics is owned, published, and trademarked by the American Academy of Pediatrics, 141 Northwest Point Boulevard, Elk Grove Village, Illinois, 60007. Copyright © 2015 by the American Academy of Pediatrics. All rights reserved. Print ISSN: 1073-0397.

American Academy of Pediatrics

DEDICATED TO THE HEALTH OF ALL CHILDREN™

