

Atrial Fibrillation Induced by Commotio Cordis Secondary to a Blunt Chest Trauma in a Teenage Boy

Kyle Ota, MPH^a, Andras Bratincsak, MD, PhD^{a,b}

Low-energy blunt chest trauma can cause commotio cordis and ventricular fibrillation (VF) in otherwise healthy young individuals. If the chest wall impact occurs during a narrow vulnerable window of ventricular repolarization, the generated premature ventricular impulse can lead to VF and sudden death. Atrial fibrillation (AF) in association with a blunt chest trauma has not yet been reported in a child or adolescent. Our case describes a healthy 16-year-old boy who suffered blunt chest trauma during football practice. He was found to have AF, which resolved in 3 days without any therapy. He did not have any identifiable structural or electrical cardiac abnormality and had no previous history of arrhythmia. We hypothesize that AF, similar to commotio cordis-induced VF, may occur as a result of a blunt chest trauma in healthy young individuals. Animal studies evaluating arrhythmias related to chest wall impact may elucidate the timing and mechanism of AF induced by commotio cordis.

Commotio cordis, defined as a blunt chest trauma resulting in sudden cardiac arrest, is a well-described and documented entity in youth.¹ It is the second leading cause of death in young athletes² and occurs typically in males with an average age of 15 years.³ The stipulated mechanism of commotio cordis has been defined with the use of animal models: a relatively innocent chest wall impact triggers immediate ventricular fibrillation (VF).⁴ The timing and the location of the impact are critical in the generation of VF. When the impact is directly over the heart and it occurs within a 20-millisecond window during the upslope of T wave in ventricular repolarization, the rapid increase in the left ventricular intracavitary pressure triggers stretch-activated ion channels generating focal ventricular depolarization that propagates to VF.^{5,6} Our case report describes a young male adolescent who suffered blunt chest

trauma and who developed not VF but atrial fibrillation (AF). This unique case is the first documented description of a child with AF due to suspected commotio cordis.

PATIENT PRESENTATION

A healthy and active 16-year-old football player was hit in the chest by another player's helmet during a football game. The chest wall impact was at the left lower edge of the boy's sternum. He did not faint or experience dizziness in conjunction with the injury. He reported to the emergency department in 25 minutes because of chest pain and palpitation. No internal injuries, obvious trauma, or neurologic complaints were noted. His past medical history was unremarkable, and his previous medical examinations suggested no structural heart problem or arrhythmia. There was no family history of cardiac disease, cardiomyopathy, or known arrhythmia

abstract

^aJohn A. Burns School of Medicine, University of Hawai'i, Honolulu, Hawaii; and ^bKapi'olani Medical Specialists, Hawai'i Pacific Health, Honolulu, Hawaii

Mr Ota reviewed the case and drafted the manuscript; and Dr Bratincsak conceptualized the case report and reviewed the manuscript; and both authors approved the final manuscript as submitted.

www.pediatrics.org/cgi/doi/10.1542/peds.2014-1972

DOI: 10.1542/peds.2014-1972

Accepted for publication Sep 24, 2014

Address correspondence to Andras Bratincsak, MD, PhD, Kapi'olani Medical Specialists, Hawai'i Pacific Health, 1319 Punahou St, Suite 1160, Honolulu, HI 96826. E-mail: ibrati@me.com

PEDIATRICS (ISSN Numbers: Print, 0031-4005; Online, 1098-4275).

Copyright © 2015 by the American Academy of Pediatrics

FINANCIAL DISCLOSURE: The authors have indicated they have no financial relationships relevant to this article to disclose.

FUNDING: No external funding.

POTENTIAL CONFLICT OF INTEREST: The authors have indicated they have no potential conflicts of interest to disclose.

or pacemaker placement. There was no toxicology screen performed, but the patient denied the use of alcohol, illicit drugs, tobacco, or over-the-counter medications.

The cardiovascular examination revealed irregular rhythm, normal first and second heart sounds, no murmur, and no third or fourth heart sound. A chest radiograph was unremarkable with normal cardiac silhouette. An electrocardiogram (ECG) was obtained and identified AF (Fig 1 A and B) with irregular ventricular response at an average rate of 70 to 80 beats per minutes. The patient was admitted to the hospital for observation and was scheduled for transesophageal echocardiogram and cardioversion. He remained in stable hemodynamic condition. He did not receive electrical or medical cardioversion because his rhythm spontaneously converted to normal sinus rhythm

72 hours after the initial encounter. His follow-up ECG confirmed normal sinus rhythm (Fig 1 C and D). The ECG showed no evidence of atrial or ventricular hypertrophy, preexcitation, or repolarization abnormality. An echocardiogram confirmed the absence of structural heart defect. The patient was discharged from the hospital without any antiarrhythmic medication. A follow-up 1 year after his initial encounter confirmed normal sinus rhythm. He was advised to use protective gear for football and to avoid direct chest wall impact.

DISCUSSION

To our knowledge, AF has not yet been reported in association with chest wall impact in youth. The absence of structural heart defect in this teenage boy, the lack of electrical abnormalities on his follow-up ECG, and the fact that the arrhythmia

resolved spontaneously within 72 hours suggest that the high-speed chest trauma was the cause of the AF.

The association of commotio cordis and VF in young athletes is well documented.¹⁻³ We propose that mechanical forces similar to those that induce VF may trigger AF in an otherwise healthy individual.

Mechanical forces applied to cardiac tissue are known to affect its electrical properties. The activation of mechano-sensitive ion channels can generate premature ventricular depolarization.⁵ If the timing of the premature depolarization occurs during a vulnerable period of ventricular repolarization, it may trigger VF.^{7,8} Similarly, an increase in atrial pressure and atrial wall stretch can activate mechano-sensitive ion channels and induce AF.^{9,10}

In commotio cordis, the timing and the location of the chest wall impact

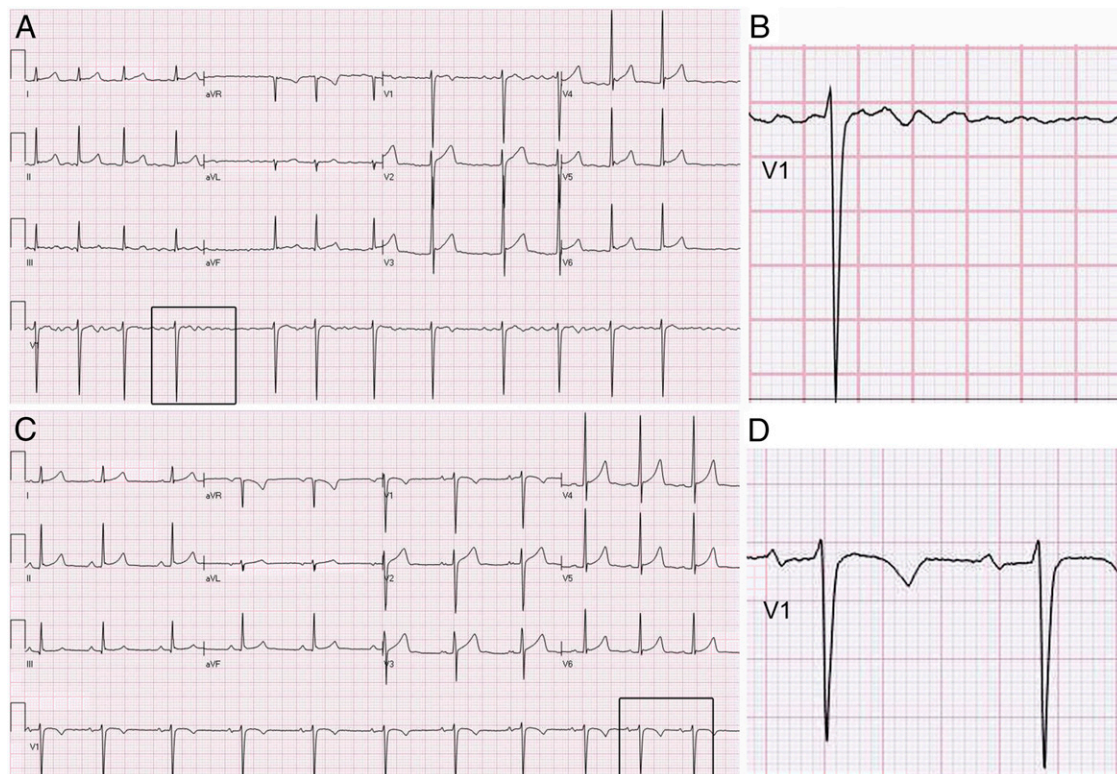


FIGURE 1

ECG of a 16-year-old boy with AF induced by commotio cordis secondary to a blunt chest trauma. A, ECG reveals AF with irregular ventricular rhythm; B, enlarged insert from lead V1; C, follow-up ECG 3 days after presentation showing spontaneous resolution to normal sinus rhythm; D, enlarged insert from lead V1.

determine the development of VF. The relatively low-energy impact has to occur during a critical 20-millisecond window of the cardiac repolarization and the impact has to be directly over the cardiac silhouette to induce VF.^{11,12} It is plausible that if a low-energy chest wall impact occurs during the vulnerable window of atrial repolarization, the impact-induced elevated atrial pressure will trigger a premature atrial depolarization and the initiation of AF. As a result of the impact, the atrial tissue may exhibit a dispersion of refractoriness inducing a so-called heterogeneity of atrial repolarization, which can perpetuate and sustain AF. Although AF was not studied or induced in animal models of low-energy chest wall impact, and AF was not documented in young athletes related to chest trauma, there is a case report in an adult that proposes the association of a fall injury with AF.¹³ It is possible that due to the relatively benign nature of chest trauma-induced AF (no syncope, no dizziness, no hemodynamic compromise) the occurrence of "atrial commotio cordis" is underreported. Moreover, it is plausible that "lone AF" reported in otherwise healthy athletes could be triggered by a previous blunt chest trauma; therefore, a careful history should be taken when evaluating young athletes with a history of palpitation or evidence of AF.

We hypothesize that similar to developing VF in commotio cordis, a blunt mechanical trauma to the heart may trigger AF in an otherwise healthy individual. Because AF may lead to rapid ventricular rate and even VF in certain underlying conditions such as Wolff-Parkinson-White syndrome,¹⁴ the recognition of AF due to commotio cordis may have implications for potentially life-threatening arrhythmias in young athletes.

REFERENCES

1. Maron BJ, Poliac LC, Kaplan JA, Mueller FO. Blunt impact to the chest leading to sudden death from cardiac arrest during sports activities. *N Engl J Med.* 1995;333(6):337–342
2. Maron BJ. Sudden death in young athletes. *N Engl J Med.* 2003;349(11):1064–1075
3. Maron BJ, Estes NA III. Commotio cordis. *N Engl J Med.* 2010;362(10):917–927
4. Link MS, Wang PJ, Pandian NG, et al. An experimental model of sudden death due to low-energy chest-wall impact (commotio cordis). *N Engl J Med.* 1998; 338(25):1805–1811
5. Bode F, Franz MR, Wilke I, Bonnemeier H, Schunkert H, Wiegand UK. Ventricular fibrillation induced by stretch pulse: implications for sudden death due to commotio cordis. *J Cardiovasc Electrophysiol.* 2006;17(9):1011–1017
6. Link MS, Estes NA III. Athletes and arrhythmias. *J Cardiovasc Electrophysiol.* 2010;21(10):1184–1189
7. Link MS. Commotio cordis: ventricular fibrillation triggered by chest impact-induced abnormalities in repolarization. *Circ Arrhythm Electrophysiol.* 2012;5(2): 425–432
8. Madias C, Maron BJ, Weinstock J, Estes NA III, Link MS. Commotio cordis—sudden cardiac death with chest wall impact. *J Cardiovasc Electrophysiol.* 2007;18(1):115–122
9. Ninio DM, Saint DA. The role of stretch-activated channels in atrial fibrillation and the impact of intracellular acidosis. *Prog Biophys Mol Biol.* 2008;97(2-3): 401–416
10. Franz MR, Bode F. Mechano-electrical feedback underlying arrhythmias: the atrial fibrillation case. *Prog Biophys Mol Biol.* 2003;82(1–3):163–174
11. Link MS, Maron BJ, Wang PJ, VanderBrink BA, Zhu W, Estes NA III. Upper and lower limits of vulnerability to sudden arrhythmic death with chest-wall impact (commotio cordis). *J Am Coll Cardiol.* 2003;41(1):99–104
12. Link MS, Maron BJ, VanderBrink BA, et al. Impact directly over the cardiac silhouette is necessary to produce ventricular fibrillation in an experimental model of commotio cordis. *J Am Coll Cardiol.* 2001;37(2):649–654
13. Ghose RR. Commotio cordis and atrial fibrillation. *N Z Med J.* 1998;111(1075): 394
14. Meijler FL, van der Tweel I, Herbschleb JN, Hauer RN, Robles de Medina EO. Role of atrial fibrillation and atrioventricular conduction (including Wolff-Parkinson-White syndrome) in sudden death. *J Am Coll Cardiol.* 1985;5(6 suppl):17B–22B

Atrial Fibrillation Induced by Comotio Cordis Secondary to a Blunt Chest Trauma in a Teenage Boy

Kyle Ota and Andras Bratincsak

Pediatrics 2015;135:e199

DOI: 10.1542/peds.2014-1972 originally published online December 8, 2014;

Updated Information & Services	including high resolution figures, can be found at: http://pediatrics.aappublications.org/content/135/1/e199
References	This article cites 14 articles, 1 of which you can access for free at: http://pediatrics.aappublications.org/content/135/1/e199#BIBL
Subspecialty Collections	This article, along with others on similar topics, appears in the following collection(s): Cardiology http://www.aappublications.org/cgi/collection/cardiology_sub Cardiovascular Disorders http://www.aappublications.org/cgi/collection/cardiovascular_disorders_sub
Permissions & Licensing	Information about reproducing this article in parts (figures, tables) or in its entirety can be found online at: http://www.aappublications.org/site/misc/Permissions.xhtml
Reprints	Information about ordering reprints can be found online: http://www.aappublications.org/site/misc/reprints.xhtml

American Academy of Pediatrics

DEDICATED TO THE HEALTH OF ALL CHILDREN™



PEDIATRICS®

OFFICIAL JOURNAL OF THE AMERICAN ACADEMY OF PEDIATRICS

Atrial Fibrillation Induced by Commotio Cordis Secondary to a Blunt Chest Trauma in a Teenage Boy

Kyle Ota and Andras Bratincsak

Pediatrics 2015;135:e199

DOI: 10.1542/peds.2014-1972 originally published online December 8, 2014;

The online version of this article, along with updated information and services, is located on the World Wide Web at:

<http://pediatrics.aappublications.org/content/135/1/e199>

Pediatrics is the official journal of the American Academy of Pediatrics. A monthly publication, it has been published continuously since 1948. Pediatrics is owned, published, and trademarked by the American Academy of Pediatrics, 141 Northwest Point Boulevard, Elk Grove Village, Illinois, 60007. Copyright © 2015 by the American Academy of Pediatrics. All rights reserved. Print ISSN: 1073-0397.

American Academy of Pediatrics

DEDICATED TO THE HEALTH OF ALL CHILDREN™

