



CLINICAL REPORT

Prevention and Management of Positional Skull Deformities in Infants

abstract

FREE

Positional skull deformities may be present at birth or may develop during the first few months of life. Since the early 1990s, US pediatricians have seen an increase in the number of children with cranial asymmetry, particularly unilateral flattening of the occiput, likely attributable to parents following the American Academy of Pediatrics “Back to Sleep” positioning recommendations aimed at decreasing the risk of sudden infant death syndrome. Positional skull deformities are generally benign, reversible head-shape anomalies that do not require surgical intervention, as opposed to craniosynostosis, which can result in neurologic damage and progressive craniofacial distortion. Although associated with some risk of positional skull deformity, healthy young infants should be placed down for sleep on their backs. The practice of putting infants to sleep on their backs has been associated with a drastic decrease in the incidence of sudden infant death syndrome. Pediatricians need to be able to properly differentiate infants with benign skull deformities from those with craniosynostosis, educate parents on methods of proactively decreasing the likelihood of the development of occipital flattening, initiate appropriate management, and make referrals when necessary. This report provides guidance for the prevention, diagnosis, and management of positional skull deformity in an otherwise normal infant without evidence of associated anomalies, syndromes, or spinal disease. *Pediatrics* 2011;128:1236–1241

INTRODUCTION

Flattening of the occiput and asymmetrical skull molding may be caused by mechanical factors that act on the head in utero or during early infancy. This common condition has been referred to by many names such as benign positional molding, posterior plagiocephaly, occipital plagiocephaly, plagiocephaly without synostosis, and deformational plagiocephaly. Ancient civilizations recognized the malleability of the rapidly growing newborn skull and intentionally deformed skulls by selective positioning and using external constraints to achieve cultural distinction. The term “plagiocephaly” is a Greek derivative that means “oblique head.” Most skull deformities present at birth are the result of in utero or intrapartum molding.¹ Associated conditions involve uterine constraint, especially in cases of multiple-birth infants, and forces exerted on the skull during complex delivery associated with forceps or vacuum-assisted delivery.^{2–4} Infants born prematurely also have a greater incidence of skull deformity attribut-

James Laughlin, MD, Thomas G. Luerksen, MD, Mark S. Dias, MD, and THE COMMITTEE ON PRACTICE AND AMBULATORY MEDICINE, SECTION ON NEUROLOGICAL SURGERY

KEY WORDS

infant, positional skull deformity, cranial asymmetry, sleep positioning, SIDS, Back to Sleep, tummy time

This document is copyrighted and is property of the American Academy of Pediatrics and its Board of Directors. All authors have filed conflict of interest statements with the American Academy of Pediatrics. Any conflicts have been resolved through a process approved by the Board of Directors. The American Academy of Pediatrics has neither solicited nor accepted any commercial involvement in the development of the content of this publication.

The guidance in this report does not indicate an exclusive course of treatment or serve as a standard of medical care. Variations, taking into account individual circumstances, may be appropriate.

www.pediatrics.org/cgi/doi/10.1542/peds.2011-2220

doi:10.1542/peds.2011-2220

All clinical reports from the American Academy of Pediatrics automatically expire 5 years after publication unless reaffirmed, revised, or retired at or before that time.

PEDIATRICS (ISSN Numbers: Print, 0031-4005; Online, 1098-4275).

Copyright © 2011 by the American Academy of Pediatrics

able to molding after birth.⁵ Most of these deformities improve spontaneously during the first few months of life if the infant does not rest his or her head predominantly on the flattened area of the skull. If the infant continues to rest his or her head on the flattened side of the occiput, an initially occipital plagiocephalic deformity may be perpetuated or worsened by gravitational forces⁶⁻⁸ and will be referred to in the remainder of this report as positional skull deformity as it relates to otherwise normal infants. Plagiocephaly is less commonly caused by unilateral lambdoidal or unilateral coronal craniosynostosis, which is a progressive and potentially devastating condition that requires early detection and surgical management. The clinical differentiation of benign positional skull deformity from craniosynostosis is well documented in the literature.⁹⁻¹¹ A long narrow head, known as dolichocephaly, can be positional from breech presentation, familial, or caused by sagittal craniosynostosis. Occipital flattening and atypical shape also may be caused by craniosynostosis, particularly bilateral lambdoid craniosynostosis. However, the incidence of isolated lambdoid craniosynostosis is quite rare, estimated to be approximately 3 in 100 000 births (0.003%).¹²

If the positional skull deformity develops postnatally, an initially typical, rounded skull shape may become flattened occipitally as a result of static supine positioning. Associated torticollis or “wryneck” may occur as a consequence of hemorrhage (within the sternocleidomastoid muscle) and/or subsequent scarring within the sternocleidomastoid muscle or muscle shortening caused by persistent, unidirectional positioning and limited neck motion resulting in plagiocephaly.¹³

The incidence of positional skull deformity has been estimated to be as low

as 1 in 300 live births to as high as 48% of typical healthy infants younger than 1 year, depending on the sensitivity of the criteria used to make the diagnosis.¹⁴ Since the American Academy of Pediatrics Task Force on Infant Positioning and Sudden Infant Death Syndrome (SIDS) in 1992 recommended that healthy infants be positioned supine for sleeping, the incidence of SIDS has decreased from 1.2 per 1000 live births in 1992 to 0.56 per 1000 live births in 2001.^{3,6,15} Coincident with this decrease in SIDS has been a drastic increase in positional skull deformity, estimated at approximately 13% in healthy singleton infants,^{14,15} which makes this a relatively common issue to be faced by the pediatrician caring for infants and their families.

Mild positional skull deformity may persist in some children into adolescence. Minor craniofacial asymmetry can be detected in a significant number of adults; however, there are few current cases of positional skull deformity serious enough to be acknowledged by patients.¹²

Families are often concerned that positional skull deformity may cause developmental delays. Although there have been no rigorous prospective studies to address this concern, there is currently no evidence to suggest that positional skull deformity causes developmental delays.^{8,16-18} There has been some early motor skill developmental delay of all infants placed supine related to upper body strength and rolling over, which resolves over time.¹⁹ Long-term follow-up studies have primarily been retrospective and questionnaire in nature and have not noted delays in cognitive or neurologic function.^{18,20-22} As might be suspected, conditions that cause delayed or abnormal development may predispose to positional skull deformity (eg, infants with hypotonia or hypertonia).^{23,24}

Concerns have been raised over vision

development²⁵ and mandibular asymmetry,²⁶ but a causal link to positional skull deformity has not been established.¹⁶ Likewise, there has been no credible medical evidence to support concerns brought up in lay literature associating positional skull deformity to otitis media, temporomandibular joint (TMJ) syndrome, scoliosis, or hip dislocation.

PREVENTION

The pediatrician or other primary care clinician should educate parents as well as other health care professionals, such as those in newborn care units, on methods for decreasing the risk of development of positional skull deformity and its treatment. A certain amount of prone positioning, or “tummy time,” while the infant is awake and being observed is recommended to help prevent the development of flattening of the occiput and to facilitate development of the upper shoulder girdle strength necessary for timely attainment of certain motor milestones.²⁷ Beginning at birth, most positional skull deformity also can be prevented by nightly alternating the supine head position (ie, left and right occiputs) during sleep and periodically changing the orientation of the infant to outside activity, such as is likely to occur at the door of the room. Avoidance of prolonged placement indoors in car safety seats and swings should be discouraged. Documentation of these educational discussions and notation of infants’ positive physical findings longitudinally are important.

DIAGNOSIS

Positional skull deformity risk factors (multiple births, large for gestational age, oligohydramnios, breech or transverse position, etc) should be noted at birth, and positional skull deformity should be screened for at each health supervision visit up to 1 year of age to

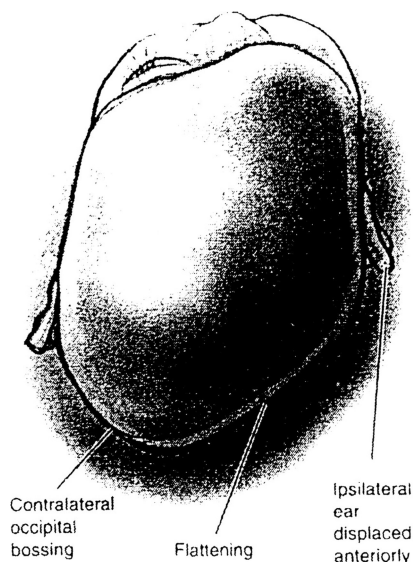


FIGURE 1
Positional molding. Adapted with permission from Lin KY, Ogle RC, Jane JA, eds. *Craniofacial Surgery: Science and Surgical Technique*. Philadelphia, PA: WB Saunders Company; 2002.

detect deformities that occur after birth as delineated in *Bright Futures*. Transient molding (caput, cephalhematoma) may be present at birth and obscure the true head shape. The diagnosis of positional skull deformity in infancy is made primarily on the basis of history and is confirmed by the physical examination. It is important for the pediatrician or other examiner to look down at the top of the head, view the position of the ears, and note the position of the cheekbones (maxilla). By doing this, the typical plagiocephalic positional skull deformity, which forms a parallelogram, will be observed. In addition to the usually unilateral flattening of the occipital area, there may be ipsilateral frontal (forehead) and parietal bossing, cheekbone prominence, and anterior ear displacement ipsilateral to the flattened occiput (Fig 1).

In contrast to deformational plagiocephaly, true craniosynostosis (either unilateral coronal or, much less commonly, lambdoid) most commonly yields a trapezoidal head shape in which there is flattening of both the occipital and frontal regions on the af-

ected side. Uncommonly, lambdoid craniosynostosis can produce a parallelogram head shape, although the affected ear is displaced posteriorly and inferiorly in contrast to deformational plagiocephaly, with which it is displaced anteriorly. There is also tilting of the posterior skull base with prominence of the mastoid. Facial deformities are minimal if present at all. Normal and abnormal physical findings should be documented.

Examination of the face also may lead to detection of abnormalities such as head tilt and contralateral facial flattening. An assessment of neck movements also should be made to confirm or rule out the presence of torticollis. Infants with torticollis have some limitation of active rotation of their heads away from the flattened side of the occiput. The rotating-chair or stool test is a procedure that assists in the diagnosis of torticollis associated with positional skull deformity. The examiner sits on a rotating chair or stool and holds the infant facing the parent: the parent attempts to keep the infant interested in maintaining eye contact while the examiner rotates with the infant on the chair or stool and observes the infant's head movements. The difference between movement toward and away from the flattened side is helpful in making the diagnosis of torticollis associated with positional skull deformity.

SKULL RADIOGRAPHS AND CRANIAL COMPUTED TOMOGRAPHY SCANS

Because the diagnosis of positional skull deformity is made on the basis of history, findings on physical examination, and resolution over time with positional intervention, imaging studies are unnecessary in most situations. In addition, if obtained, their interpretations may be misleading to clinicians, particularly in the case of computed tomography (CT) scans. For the infant

born with a normal head shape that progressively changes during the first weeks postnatally, no studies should be performed. Imaging studies should be reserved for infants born with deformities or those that do not improve over the first several weeks with repositioning. To minimize the risk of radiation exposure and the possible need for sedation, it is recommended that imaging studies be ordered by the specialist, because most craniofacial surgeons reserve radiographic imaging or CT scans for those patients who are suspected of having craniosynostosis and/or require surgical intervention.¹⁶ Radiographs and other imaging studies are also rarely indicated for infants with torticollis unless it is progressive or associated with other clinical findings.

MANAGEMENT

Management of positional skull deformity involves preventive counseling for parents, mechanical adjustments, and exercises. Parental compliance with the management plan is pivotal in lessening the likelihood and severity of positional skull deformity. Skull-molding helmets are an option for patients with severe deformity or skull shape that is refractory to therapeutic physical adjustments and position changes.²⁸ Surgery is rarely necessary but may be indicated in severe refractory cases of positional skull deformity.²⁹ However, infants with craniosynostosis typically require surgical correction and skull reconstruction. Early surgical intervention results in less invasive procedures because an infant's normal brain growth assists in remodeling the skull postoperatively. Minimally invasive surgery is now available to some infants identified with craniosynostosis in the first months of life.

Preventive Counseling

To prevent the deformity, parents should be counseled during the new-

born period (by 2–4 weeks of age) when the skull is maximally deformable. Parents should be instructed to lay the infant down to sleep in the supine position, alternating positions (ie, left and right occiputs). When awake and being observed, the infant should spend time in the prone position for at least 30 to 60 minutes/day. The infant should spend minimal time in car seats (when not a passenger in a vehicle)³⁰ or other seating that maintains supine positioning. Aside from potentially preventing positional skull deformity, routine awake tummy time has been shown to enhance infant motor developmental scores during the first 15 months of life. Once positional skull deformity has developed, these same preventive strategies may be used to minimize progression. In addition, it is important to monitor head shape closely until there is confidence that improvement will continue, usually when the infant is old enough to sit, crawl, and spend less time on his or her back and until any associated torticollis is completely corrected. The prevalence of positional skull deformity generally peaks at 4 months and will begin to show significant improvement by 6 months of age.^{16,31–33}

Mechanical Adjustments and Exercises

Once positional skull deformity is diagnosed, the parent should be made aware of the condition and the mechanical adjustments that can be instituted. In general, most infants improve if the appropriate measures are conducted for a 2- to 3-month period.⁵ These measures include positioning the infant so that the rounded side of the head is placed dependent against the mattress. In addition, the position of the crib in the room may be changed to require the child to look away from the flattened side to see the parents and others in his or her room. The pediatrician should continue to en-

courage supervised tummy time on firm surfaces when the infant is awake and being observed. Torticollis perpetuates the position of the head on the flattened side and can add to a greater facial deformity. Therefore, if torticollis is present, neck-motion exercises should be taught to the parents as part of management. Neck exercises should be performed with each diaper change. There are 3 repetitions per exercise, and it is estimated to take approximately 2 additional minutes per diaper change. One hand is placed on the child's upper chest, and the other hand rotates the child's head gently so that the chin touches the shoulder. This is held for approximately 10 seconds. The head is then rotated toward the opposite side and held for the same count. This will stretch out the sternocleidomastoid muscle. Next, the head is tilted so that the infant's ear touches his or her shoulder. Again, the position is held for a count of 10 and repeated for the opposite side. This second exercise stretches the trapezius muscle. In addition, the parents may be taught the previously mentioned rotating-chair or stool technique as a therapy to enhance neck motion in the infant.

Referral

If there is progression or lack of improvement of the skull deformity after a trial of mechanical adjustments, then referral to a pediatric neurosurgeon with expertise in craniofacial malformations or to a craniofacial surgeon or craniofacial team should be considered by 4 to 6 months of age. The purpose of this referral is to obtain the expertise of the craniofacial specialist to assess the diagnosis and to direct the subsequent management, which may include molding helmets or surgery. In addition, referral to a physical therapist may be considered if torticollis does not improve with neck-stretching exercises within 2 to 3 months.

Skull-Molding Helmets

Ancient civilizations recognized the malleability of the rapidly growing newborn skull and intentionally deformed skulls by selective positioning and using external constraints to achieve a culturally desired skull form. Conversely, skull-molding helmets can be used to correct atypical skull shapes, and similar devices are now proposed for this purpose. There is currently no evidence that molding helmets work any better than positioning for infants with mild or moderate skull deformity. Because more than half of the infants will improve by 6 months of age, repositioning should be attempted as the initial treatment for infants younger than 6 months. In most situations, an improvement in response to repositioning and neck exercise is seen over a 2- to 3-month period if these measures are instituted as soon as the condition is recognized. For severe deformity, the best use of helmets occurs in the age range of 4 to 12 months^{20,34} because of the greater malleability of the young infant skull bone and the normalizing effect of the rapid growth of the brain. There is less modification of the cranial configuration and more compliance problems when used after 12 months of age.¹⁶ The use of helmets and other related devices seems to be beneficial primarily when there has been a lack of response to mechanical adjustments and exercises. Although there is some limited evidence that molding helmets may work faster for children with severe deformities, there were significant methodologic flaws associated with these studies, and there is evidence that long-term outcomes (2–3 years after treatment) may not result in a substantial benefit from helmet use.¹⁶ In particular, a recent study of 161 children treated with po-

sitional changes only showed that 87% had achieved significant improvements, 61% achieved normal skull contours, and only 4% had severe residual deformities by the time of preschool.⁵⁵

Although there have been few published studies, complications of helmet use seem to be low. Cost of helmets can be significant and extremely variable depending on the provider or vendor.

Surgery

Surgical correction for positional skull deformity is currently not recommended except possibly under unusual circumstances in which a child has persistent, severe deformities that have not adequately been corrected despite all other nonoperative measures.

SUMMARY

In most cases, the diagnosis and successful management of positional

skull deformity can be assumed by the pediatrician or other primary health care clinician. This management includes examination for and counseling regarding positional skull deformity in the newborn period and at health supervision visits during infancy, as well as monitoring for improvement or progression. For the mild-to-moderate deformity, positioning and observation is the recommended treatment. Both positional changes and molding helmets are options for the infant with severe deformity. Cranial orthoses should be reserved for severe cases of deformity or for the infant whose deformity does not improve after 6 months of age. Referral to a pediatric neurosurgeon with expertise in craniofacial malformations, a craniofacial surgeon, or a craniofacial team should be considered if there is progression or lack of improvement after a trial of mechanical adjustments or suspicion of craniosynostosis.

REFERENCES

1. de Chalain T, Park S. Torticollis associated with positional plagiocephaly: a growing epidemic. *J Craniofac Surg*. 2005;16(3):411–418
2. American Academy of Pediatrics, Task Force on Infant Sleep Positioning and SIDS. Positioning and SIDS [published correction appears in *Pediatrics*. 1992;90(2 pt 1):264]. *Pediatrics*. 1992;89(6 pt 1):1120–1126
3. American Academy of Pediatrics, Task Force on Infant Sleep Position and Sudden Infant Death Syndrome. Changing concepts of sudden infant death syndrome: implications for infant sleeping environment and sleep position. *Pediatrics*. 2000;105(3 pt 1):650–656
4. de Ribaupierre S, Vernet O, Rilliet B, Cavin B, Kalina D, Leyuraz PF. Posterior positional plagiocephaly treated by cranial remodeling orthosis. *Swiss Med Wkly*. 2007;137(25–26):368–372
5. Rekate H. Occipital plagiocephaly: a critical review of the literature. *J Neurosurg*. 1998;89(1):24–30
6. American Academy of Pediatrics, Task Force on Sudden Infant Death Syndrome. The changing concept of sudden infant death syndrome: diagnostic coding shifts, controversies regarding the sleeping environment, and new variables to consider in reducing risk. *Pediatrics*. 2005;116(5):1245–1255
7. Ellenbogen R, Gruss J, Cunningham M. Update on craniofacial surgery: the differential diagnosis of lambdoid synostosis/posterior plagiocephaly. *Clin Neurosurg*. 2000;47:303–318
8. Fowler E, Becker D, Pilgram T, Noetzel M, Epstein J, Kane A. Neurologic findings in infants with deformational plagiocephaly. *J Child Neurol*. 2008;23(7):742–747
9. Huang MH, Gruss JS, Clarren SK, et al. The differential diagnosis of posterior plagiocephaly: true lambdoid synostosis versus positional molding. *Plast Reconstr Surg*. 1996;98:765–774
10. Huang MHS, Mouradian WE, Cohen SR, Gruss JS. The differential diagnosis of abnormal head shapes: separating craniosynostosis from positional deformities and normal variants. *Cleft Palate Craniofac J*. 1998;35(3):204–211
11. Ellenbogen RG, Gruss JC, Cunningham ML. Update on craniofacial surgery: the differential diagnosis of lambdoid synostosis/posterior plagiocephaly. *Clin Neurosurg*. 2000;47:303–318
12. Argenta L. Clinical classification of positional plagiocephaly. *J Craniofac Surg*. 2004;15(3):368–372
13. Davis B, Moon R, Schas H, Ottolini M. Effects of sleep position on infant motor development. *Pediatrics*. 1998;102(5):1135–1140
14. Littlefield TR, Saba NM, Kelly KM. On the current incidence of deformational plagiocephaly: an estimation based on prospective registration at a single center. *Semin Pediatr Neurol*. 2004;11(4):301–304
15. Peitsch W, Keefer C, LaBrie R, Mulliken J. Incidence of cranial asymmetry in healthy newborns. *Pediatrics*. 2002;110(6). Available at: www.pediatrics.org/cgi/content/full/110/6/e72
16. Robinson S, Proctor M. Diagnosis and management of deformational plagiocephaly. *J Neurosurg Pediatr*. 2009;3(4):284–295
17. Panchal J, Amirshaybani H, Gurwitsch R, et al. Neurodevelopment in children with single-suture craniosynostosis and plagiocephaly without synostosis. *Plast Reconstr Surg*. 2001;108(6):1492–1498
18. Collett B, Breiger D, King D, Cunningham M, Speltz M. Neurodevelopmental implications

LEAD AUTHORS

James Laughlin, MD
Thomas G. Luerssen, MD
Mark S. Dias, MD

COMMITTEE ON PRACTICE AND AMBULATORY MEDICINE, 2009–2010

Lawrence Hammer, MD, Chairperson
Oscar Brown, MD
Edward Curry, MD
James Laughlin, MD
Herschel Lessin, MD
Chadwick Rodgers, MD
Geoffrey Simon, MD

LIAISONS

Xylina Bean, MD – National Medical Association

STAFF

Elizabeth Sobczyk, MSW, MPH

SECTION ON NEUROLOGICAL SURGERY EXECUTIVE COMMITTEE, 2009–2010

Mark S. Dias, MD, Chairperson
Joseph Piatt, MD, Immediate Past Chairperson
Philipp Aldana, MD
John Ragheb, MD
Michael Partington, MD
David Gruber, MD

PAST EXECUTIVE COMMITTEE MEMBER

Thomas G. Luerssen, MD

STAFF

Aleksandra Stolic, MPH

- of “deformational” plagiocephaly. *J Dev Behav Pediatr*. 2005;26(5):379–389
19. Jantz J, Blosser C, Fruechting L. A motor milestone change noted with a change in sleep position. *Arch Pediatr Adolesc Med*. 1997;151(6):565–568
 20. Govaert B, Michels A, Colla C, van der Hulst R. Molding therapy of positional plagiocephaly: subjective outcome and quality of life. *J Craniofac Surg*. 2008;19(1):56–58
 21. Miller R, Clarren S. Long-term developmental outcomes in patients with deformational plagiocephaly. *Pediatrics*. 2000;105(2). Available at: www.pediatrics.org/cgi/content/full/105/2/e26
 22. Steinbok P, Lam D, Singh S, Mortenson P, Singhal A. Long-term outcome of infants with positional occipital plagiocephaly. *Childs Nerv Syst*. 2007;23(11):1275–1283
 23. van Vimmeren L, van der Graaf Y, Boere-Boonekamp M, L’Hoir M, Helders P, Englebert R. Risk factors for deformational plagiocephaly at birth and at 7 weeks of age: a prospective cohort study. *Pediatrics*. 2007;119(2). Available at: www.pediatrics.org/cgi/content/full/119/2/e408
 24. Kordestani R, Patel S, Bard D, Gurwitsch R, Panchal J. Neurodevelopmental delays in children with deformational plagiocephaly. *Plast Reconstr Surg*. 2006;117(1):207–218
 25. Siatkowski R, Fortney A, Nazir S, et al. Visual field defects in deformational posterior plagiocephaly. *J AAPOS*. 2005;9(3):274–278
 26. Lee R, Teichgraeber J, Baumgartner J, et al. Long-term treatment effectiveness of molding helmet therapy in the correction of posterior deformational plagiocephaly: a five-year follow-up. *Cleft Palate Craniofac J*. 2008;45(3):240–245
 27. Clarren S. Plagiocephaly and torticollis: etiology, natural history, and helmet treatment. *J Pediatr*. 1981;98(1):92–95
 28. Hellbusch J, Hellbusch L, Bruneteau R. Active counter-positioning of deformational occipital plagiocephaly. *Nebr Med J*. 1995;80(12):344–349
 29. Jalaluddin M, Moss D, Shaffon D. Occipital plagiocephaly: the treatment of choice [abstr]. *Neurosurgery*. 2001;49(2):545
 30. Bull M, Engle W; American Academy of Pediatrics, Committee on Violence, Injury, and Poison Prevention, Committee on Fetus and Newborn. Safe transportation of preterm and low birth weight infants at hospital discharge. *Pediatrics*. 2009;123(5):1424–1429
 31. Boere-Boonekamp M, van der Linden-Kuiper L. Positional preference: prevalence in infants and follow-up after two years. *Pediatrics*. 2001;107(2):339–343
 32. Hutchison BL, Hutchison LA, Thompson JM, Mitchell EA. Plagiocephaly and brachycephaly in the first two years of life: a prospective cohort study. *Pediatrics*. 2004;114(4):970–980
 33. Pollack IF, Losken HW, Fasick P. Diagnosis and management of posterior plagiocephaly. *Pediatrics*. 1997;99(2):180–185
 34. Graham JM Jr, Gomet M, Halberg A, et al. Management of deformational plagiocephaly: repositioning versus orthotic therapy. *J Pediatr*. 2005;146(2):258–262
 35. Hutchison BL, Stewart AW, Mitchell AE. Deformational plagiocephaly: a follow-up of head shape, parental concern, and neurodevelopment at ages 3 and 4 years. *Arch Dis Child*. 2011;96(1):85–90

Prevention and Management of Positional Skull Deformities in Infants
James Laughlin, Thomas G. Luerssen, Mark S. Dias and the Committee on Practice
and Ambulatory Medicine, Section on Neurological Surgery
Pediatrics 2011;128;1236
DOI: 10.1542/peds.2011-2220 originally published online November 28, 2011;

Updated Information & Services	including high resolution figures, can be found at: http://pediatrics.aappublications.org/content/128/6/1236
References	This article cites 32 articles, 9 of which you can access for free at: http://pediatrics.aappublications.org/content/128/6/1236#BIBL
Subspecialty Collections	This article, along with others on similar topics, appears in the following collection(s): Genetics http://www.aappublications.org/cgi/collection/genetics_sub
Permissions & Licensing	Information about reproducing this article in parts (figures, tables) or in its entirety can be found online at: http://www.aappublications.org/site/misc/Permissions.xhtml
Reprints	Information about ordering reprints can be found online: http://www.aappublications.org/site/misc/reprints.xhtml

American Academy of Pediatrics

DEDICATED TO THE HEALTH OF ALL CHILDREN™



PEDIATRICS®

OFFICIAL JOURNAL OF THE AMERICAN ACADEMY OF PEDIATRICS

Prevention and Management of Positional Skull Deformities in Infants

James Laughlin, Thomas G. Luerssen, Mark S. Dias and the Committee on Practice and Ambulatory Medicine, Section on Neurological Surgery

Pediatrics 2011;128;1236

DOI: 10.1542/peds.2011-2220 originally published online November 28, 2011;

The online version of this article, along with updated information and services, is located on the World Wide Web at:

<http://pediatrics.aappublications.org/content/128/6/1236>

Pediatrics is the official journal of the American Academy of Pediatrics. A monthly publication, it has been published continuously since 1948. Pediatrics is owned, published, and trademarked by the American Academy of Pediatrics, 141 Northwest Point Boulevard, Elk Grove Village, Illinois, 60007. Copyright © 2011 by the American Academy of Pediatrics. All rights reserved. Print ISSN: 1073-0397.

American Academy of Pediatrics

DEDICATED TO THE HEALTH OF ALL CHILDREN™

