

Acute Periorbital Infections: Who Needs Emergent Imaging?

AUTHORS: Tiffany F. Rudloe, MD,^a Marvin B. Harper, MD,^{a,b} Sanjay P. Prabhu, MBBS, MD,^c Reza Rahbar, DMD, MD,^d Deborah VanderVeen, MD,^e and Amir A. Kimia, MD^a

Divisions of ^aEmergency Medicine and ^bInfectious Disease, Department of Medicine, ^cDivision of Neuroradiology, Department of Pediatric Radiology, and Departments of ^dOtolaryngology and Communication Enhancement and ^eOphthalmology, Children's Hospital Boston, Boston, Massachusetts

KEY WORDS

periorbital cellulitis, orbital cellulitis, subperiosteal abscess, computed tomography, orbital infections

ABBREVIATIONS

CT—computed tomography
EOM—extraocular movement
ED—emergency department
WBC—white blood cell
ANC—absolute neutrophil count
URI—upper respiratory tract infection
EMR—electronic medical record
CI—confidence interval
IQR—interquartile range

www.pediatrics.org/cgi/doi/10.1542/peds.2009-1709

doi:10.1542/peds.2009-1709

Accepted for publication Nov 12, 2009

Address correspondence to Tiffany F. Rudloe, MD, Division of Emergency Medicine, Children's Hospital Boston, 300 Longwood Ave, Boston, MA 02115. E-mail: tiffany.rudloe@childrens.harvard.edu

PEDIATRICS (ISSN Numbers: Print, 0031-4005; Online, 1098-4275).

Copyright © 2010 by the American Academy of Pediatrics

FINANCIAL DISCLOSURE: *The authors have indicated they have no financial relationships relevant to this article to disclose.*



WHAT'S KNOWN ON THIS SUBJECT: Orbital infections may be difficult to distinguish from periorbital cellulitis on the basis of clinical examination. CT can be used to delineate orbital anatomy and determine if an abscess is present.



WHAT THIS STUDY ADDS: We present here an algorithm to stratify patients who are at risk for subperiosteal or orbital abscess and need emergent imaging, and to identify a population of patients at low risk.

abstract

FREE

OBJECTIVES: Computed tomography (CT) is used often in the evaluation of orbital infections to identify children who are most likely to benefit from surgical intervention. Our objective was to identify predictors for intraorbital or intracranial abscess among children who present with signs or symptoms of periorbital infection. These predictors could be used to better target patients for emergent CT.

METHODS: This was a retrospective cohort study of all patients admitted to an urban pediatric tertiary care emergency department between 1995 and 2008. We included otherwise healthy patients with suspected acute clinical periorbital or orbital cellulitis without a history of craniofacial surgery, trauma, or external source of infection. Immunocompromised patients and patients with noninfectious causes of periorbital swelling were excluded. Variables analyzed included age, duration of symptoms, highest recorded temperature, previous antibiotic therapy, physical examination findings, laboratory results, and interpretation of imaging. CT scans of the orbit were reread by a neuroradiologist.

RESULTS: Nine hundred eighteen patients were included; 298 underwent a CT scan, and of those, 111 were shown to have an abscess. Although proptosis, pain with external ocular movement, and ophthalmoplegia were associated with presence of an abscess, 56 (50.5%) patients with abscess did not experience these symptoms. Other variables associated with the presence of an abscess in multivariate analysis were a peripheral blood neutrophil count greater than 10 000/ μ L, absence of infectious conjunctivitis, periorbital edema, age greater than 3 years, and previous antibiotic therapy ($P < .05$ for all). Our recursive partitioning model identified all high-risk (44%) patients as well as a low-risk (0.4%–2%) group ($R_{sq} = 0.27$).

CONCLUSIONS: We confirmed that patients with proptosis and/or pain or limitation of extraocular movements are at high risk for intraorbital abscess, yet many do not have these predictors. Other features can identify patients who do not have such obvious predictors but do have significant risk of disease. A recursive partitioning model is presented. *Pediatrics* 2010;125:e719–e726

Orbital cellulitis or abscess can occur as a complication of acute sinusitis in children. This infectious process involves the structures posterior to the anatomic boundary created by the orbital septum.^{1–3} Preseptal cellulitis is also common in childhood, and may result from sinusitis, percutaneous introduction of bacteria, or bacteremia.^{2,4–6} It is important to distinguish between preseptal cellulitis, orbital cellulitis, and orbital abscess. Orbital and subperiosteal abscess place a patient at risk for blindness, intracranial infection, or death.^{1,7,8} External sources of infection, which could lead to periorbital swelling, are less likely to cross the anatomic boundary of the orbital septum and lead to such complications.^{1,9,10}

Evaluation of children with acute periorbital swelling can be difficult. Clinical findings alone may not be specific enough to distinguish preseptal from orbital infections or those with complications.^{11–13} To date, studies have identified proptosis and ophthalmoplegia (limitation of extraocular movements) as indicators of intraorbital inflammation but have not been able to distinguish between orbital cellulitis and abscess.^{13–15} Laboratory findings have not proven helpful in making this determination.¹³

Concern for orbital involvement may prompt the use of computed-tomography (CT) scanning of the orbit.^{9,13,16} CT imaging can detect extension of infection into the orbit, identify an orbital abscess, or reveal sinus disease.^{16–19} Although CT scanning is a useful tool, it exposes the pediatric patient to ionizing radiation and, in some cases, the risks associated with sedation.^{14,16} Protocols in the current literature provide a wide range of indications for CT imaging that include ophthalmoplegia or proptosis but go further to suggest imaging for those in whom visual acuity cannot be assessed, patients with persistence of fe-

ver for >36 hours, and those with no clinical improvement within 24 hours of first antibiotic administration.¹⁶ Others have suggested imaging only for patients with ophthalmoplegia, pain, or proptosis after their condition failed to respond to an initial antibiotic trial, reserving CT scanning for cases in which surgical intervention is being considered.⁵

The aim of our study was to determine clinical predictors of subperiosteal, orbital, or intracranial complication in cases of acute periorbital symptoms caused by infection. Such predictors could be used to stratify patients into groups of those who are most likely or least likely to have complications identified by CT scanning that would benefit from surgical intervention.

METHODS

Study Design

A retrospective cohort review of consecutive patients seen at an urban tertiary care pediatric emergency department (ED) was conducted. The ED serves ~50 000 children per year. ED electronic medical records (EMRs) of patients who presented from October 1995 through August 2008 with periorbital-related complaints were reviewed. The study protocol was approved by the Children's Hospital Boston internal review board committee.

Study Population

All patients with available EMRs during the study period were evaluated for inclusion in this study. Otherwise healthy patients with acute periorbital edema and/or erythema who were thought to have preseptal cellulitis, orbital cellulitis, or intraorbital abscess were included in the study population. Patients were excluded if they had a history of immunodeficiency, previous ocular or craniofacial surgery, or anatomic anomaly (eg, craniosynostosis); had orbital swelling that was thought

not to be related to infection (patient did not receive treatment with antibiotic [eg, allergic reaction or nephrotic syndrome]); had an underlying lesion such as a dacrocystocele; or were identified as having an external source of infection (eg, infected laceration, bug bites) or dentoalveolar abscess. In cases of diagnostic uncertainty, we included patients to whom antibiotic treatment was administered or prescribed. For those patients with more than 1 ED visit for periorbital symptoms, subsequent visits were excluded if they occurred within the first 24 hours after the initial visit or >24 hours after the initial visit with no changes in clinical variables.

Case Identification

Case identification was conducted in 2 phases. First, for the initial screening, we created a computer-assisted screening tool that is similar to keyword search tools but uses regular expressions.²⁰ Regular expression matching provides a more comprehensive and inclusive search than keyword searching because it includes possible misspelled and mistyped variations of the key word(s) of interest. Second, a manual chart review was performed by a single pediatric urgent care medicine attending physician (Dr Rudloe) using the inclusion and exclusion criteria above.

Data Extraction

Data regarding the ED or hospital course and management were then retrieved from EMRs. Data abstracted included age, gender, height of fever, duration of symptoms, previous upper respiratory tract infection (URI)/sinusitis symptoms, previous antibiotic treatment, laboratory tests including complete blood count, absolute neutrophil count (ANC), erythrocyte sedimentation rate, and measurement of C-reactive protein level. Physical examination findings (extraocular move-

ment [EOM], degree of edema, proptosis), CT results, and procedures performed were also recorded. EMRs were screened for return visits within 1 week of the index visit. If a trainee was involved in the patient care, both the trainee and the attending physician's notes were reviewed. Findings were considered present if they were documented either by the resident or attending physician. All cases were reviewed to screen for a second ED visit or hospital admission within 1 week of the index visit.

Definitions

We divided our clinical and laboratory data into binary results that represent either presence or absence of a finding. Quantitative measures of proptosis were rarely recorded. Therefore, proptosis was considered simply as present or absent. If there was no specific finding of proptosis recorded in the chart, it was considered to be absent. Fever was defined as any temperature of $>38^{\circ}\text{C}$ recorded during patient care (oral, rectal, or tympanic). Edema was considered significant if the documentation suggested extension beyond the eyelid. EOMs were categorized as limited, intact, or unable to determine. Pain with EOM was coded as present if specifically recorded. Otherwise, pain with EOM was coded as not present/not addressed. For the purposes of analysis the 3 results of proptosis, limitation of EOM, and pain with EOM were also grouped into a single "clinical findings" category if any one was present. On the basis of the ability to communicate symptoms and primary analysis, age was treated as a binary variable, with the 2 groups being those aged 3 years and older and those younger than 3 years. Duration of symptoms was recorded and then analyzed as greater than or less than 1 day of symptoms. Previous antibiotic treatment was considered present if any oral or intravenous antibiotic had

TABLE 1 Chandler Classification of Orbital Complications of Sinusitis, a Clinical Description

Chandler Class	Stage	Clinical Description and Definition
I	Inflammatory edema	Eyelid edema and erythema Normal extraocular movement Normal visual acuity
II	Orbital cellulitis	Diffuse edema of orbital contents without discrete abscess formation
III	Subperiosteal abscess	Collection of purulent exudate ^a beneath periosteum of lamina papyracea Displacement of globe downward/laterally
IV	Orbital abscess	Purulent collection within orbit ^a Proptosis Chemosis Ophthalmoplegia Decreased vision
V	Cavernous sinus thrombosis	Bilateral eye findings Prostration Meningismus

^a The radiographic correlation of a subperiosteal or orbital abscess seen with CT is a contrast-enhancing mass in the extraconal/intraconal space, possibly with areas of cavitation, because purulence cannot be determined with CT scanning.

been administered for >24 hours before the ED visit.

Outcome Measures

Imaging findings were categorized according to Chandler's clinical classification (modified Huberts classification) for complications of acute sinusitis (Table 1).²¹ This classification system was introduced before the advent of CT but is widely used today.¹⁰

The Chandler classification system is similar to others described based on CT findings.²² Both ED imaging results and imaging results from outside hospitals were included. All CT scans performed within 24 hours of the ED visit were analyzed. All available CT images were reviewed again by a single neuro-radiologist (Dr Prabhu) who classified the readings by using Chandler's criteria. Two-dimensional and coronal planes were reviewed. Discrepancies between original readings and those of the study reviewer were resolved by consensus among investigators. A κ score was calculated to assess agreement.

A CT finding was classified as "significant" if the Chandler score was III or higher (subperiosteal abscess, orbital abscess, or cavernous sinus thrombosis), thus discriminating patients who may need surgical intervention from

those who require antibiotic therapy alone.

CT Classification

Patients who underwent imaging within 24 hours of their initial visit and were diagnosed with an abscess were considered to have had the abscess on their initial visit and classified as having a significant result. Patients who underwent imaging >24 hours from their initial visit and were diagnosed with an abscess were excluded. The authors could not determine if the abscess represented natural progress of disease of an existing abscess from the index visit. Patients who did not undergo imaging were classified as having a negative or "nonsignificant" result.

Statistical Analysis

Data were analyzed by using SPSS for Windows (SPSS Inc, Chicago, IL). Multivariate analyses were used to examine relationships between patients with significant CT findings and those without them. All patients were included in the analysis even if they did not have a CT scan. A recursive partitioning model was created by using JMP software (SAS Institute, Cary, NC) that creates a decision tree based on dichoto-

mous dependent variables. Internal validation was performed by using K-fold validation.

RESULTS

Study Group

There were 670 056 ED visits from October 1995 to August 2008 with electronic ED notes available for review. Fig 1 shows how the 918 patient visits that met study criteria were identified. Table 2 lists the patient demographics and clinical characteristics.

Radiologic Findings

Two hundred ninety-eight patients had an orbital CT performed (32%). There were 295 CT scans obtained with contrast-enhanced images (Table 3). One hundred eleven patients, 12% of patients overall (95% confidence interval [CI]: 10.1–14.4) or 37% (95% CI: 32.0–43.2) of the 298 evaluable CT scans had significant CT findings. There was good agreement between radiology readings when original readings were compared with neuro-radiologist rereads ($K = 0.9$). The maxillary and ethmoid sinuses were the most commonly involved, at 86% and 84%, respectively (Table 3).

Of the 111 patients who had a significant CT finding (abscess), the median age was 7.3 years (interquartile range [IQR]: 3.3–9.7); 20 patients were younger than 3 years of age. The median white blood cell (WBC) count was 15 500/ μL (IQR: 12.6–20 000), and median ANC was 12 210/ μL (IQR: 9900–16 640). Median duration of ocular symptoms was 2 days. Of the 111 patients with abscess shown with CT, 56 (50.5% [95% CI: 40.8–60.0]) of these did not have ophthalmoplegia, proptosis, or pain with extraocular movements.

Subspecialty consult requests were ordered for 240 patients. The most common were otorhinolaryngology (171) and ophthalmology (217). Among

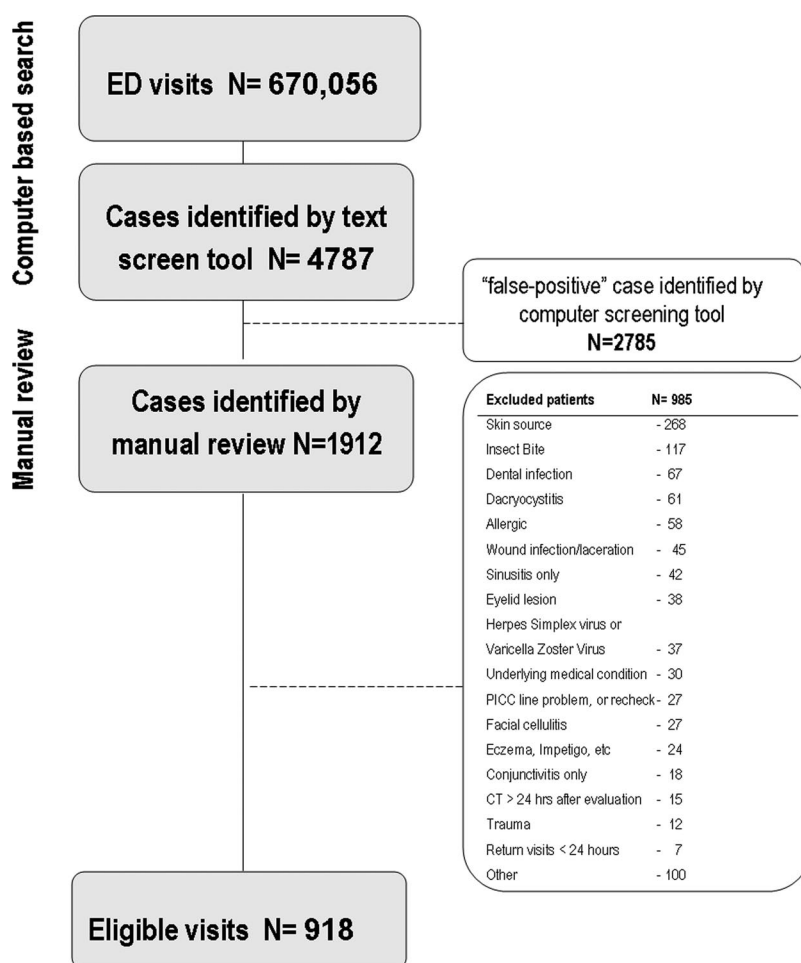


FIGURE 1

Case identification. PICC indicates peripherally inserted central catheter.

these, consults of both services were common (148).

Patient Outcomes

Four hundred sixty-nine patients (51%) were admitted to the hospital. The median hospital length of stay was 2.1 days (IQR: 1.6–3.7). Seventy-two patients underwent a surgical procedure. Sixty-two children had drainage of a subperiosteal or orbital abscess, and 10 had sinus surgery. Forty sinus or abscess specimens were obtained after antibiotic treatment. The organisms recovered are shown in Table 4. Three of 407 blood specimens that were sent for culture grew a pathogen (*Streptococcus pneumoniae*), and 8 grew an unlikely pathogen (5 non-

aureus *Staphylococcus*, 2 group A streptococci, and 1 *Streptococcus milleri*). Seven patients had sequelae of infection 3 months from the initial presentation: 2 patients suffered loss of vision in the affected eye, 3 had persistence of ptosis, and 2 had persistence of pain. None of the 39 remaining patients required surgery after subsequent review of the charts.

Of the 450 patients discharged to home from the initial ED visit, 22 (4.8%) returned to the ED >24 hours but <1 week after the initial visit. One patient had a significant finding on orbit CT scan (subperiosteal abscess) when she returned on day 4 and was excluded per protocol.

TABLE 2 Patient Demographics

	Value	95% CI
ED visits during the study period, <i>n</i>	670	056
Included patients	918	
Age, median (IQR), y	3.8 (1.7–7.4)	
Female, %	46	
Symptoms of URI or sinusitis, %	39	36–43
Pretreated with antibiotics, %	34	32–43
Topical antibiotics, %	6	
Oral antibiotics, %	17	
Parenteral antibiotics, %	11	
Duration of previous antibiotics, median, d	1	
Duration of ocular symptoms, median (IQR), d	1 (1–2)	
Previous conjunctivitis, %	19	16–21
Periorbital edema > eyelid, %	24	21–27
Pain with extraocular movement, %	12	10–13
Limited extraocular movement, %	13	12–17
Proptosis, %	4	3–5
Fever ($\geq 38.0^{\circ}\text{C}$), %	42	35–45
Temperature, median (IQR), $^{\circ}\text{C}$	37.3 (36.5–38.8)	
WBC count obtained, %	71	
WBC, mean (IQR), $\times 1000/\mu\text{L}$	13.8 (9.9–17.7)	
ANC, mean (IQR), $\times 1000/\mu\text{L}$	8.1 (4.2–11.8)	

TABLE 3 Radiologic Findings, Based on Chandler Stage of Orbital Findings

	No. (%) of Patients
Chandler stage	
0	12 (4)
1	124 (42)
2	51 (17)
3	100 (34)
4	6 (2)
5	4 (1)
Bilateral involvement	5
Stage 1	4
Stage 2	1
Sinus involvement	
Maxillary	258 (86)
Ethmoid	252 (84)
Sphenoid	131 (44)
Frontal	89 (30)
None	26 (9)
Unspecified	3 (1)
Multiple	240 (80)

The data should be interpreted with caution, because 75% of our patients were younger than 7 years of age.

Multivariate Analysis

Binary logistic regression was used to assess the association of each variable with positive CT findings. The variables associated with imaging findings are presented in Table 5.

Recursive Partitioning

A recursive partitioning model was developed and is shown in Fig 2. Our recursive partitioning model identified

TABLE 4 Bacterial Pathogens From Sinus Cultures

Organism	No. of Cultures
Viridans streptococci	25
(<i>Streptococcus intermedius</i>)	(17)
Non-aureus <i>Staphylococcus</i>	13
<i>Streptococcus pyogenes</i> (group A Streptococci)	10
<i>Staphylococcus aureus</i> (MRSA)	7 (1)
<i>Streptococcus pneumoniae</i>	5
<i>Corynebacterium</i>	3
<i>Haemophilus influenzae</i>	3
Peptostreptococci	2
<i>Arcanobacterium pyogenes</i>	1
<i>Eikenella corrodens</i>	1
<i>Escherichia coli</i>	1
Group C streptococci	1
<i>Klebsiella pneumoniae</i>	1
<i>Prevotella intermedia</i>	1
<i>Propionibacterium granulosum</i>	1
<i>Pseudomonas</i>	1
<i>Stomatococcus</i>	1
Multiple organisms	23
No growth	10

Organisms in parentheses are a subset of the group listed directly above it. MRSA indicates methicillin-resistant *Staphylococcus aureus*.

all high-risk (44%) patients and a low-risk (0.4%–2%) group ($R_{sq} = 0.27$ [*K*-fold value of 0.24]). The model shows that those patients with the clinical findings of proptosis, ophthalmoplegia, or pain with EOM fall directly into the high-risk category. For pa-

TABLE 5 Multivariate Analysis

Variable	Adjusted Odds Ratio (95% CI)
ANC $\geq 10\,000$ cells per μL	8.6 (4.4–16.9)
Proptosis, limitation, or pain with EOM	6.6 (3.3–13.5)
Absence of conjunctivitis	5.9 (1.5–23.9)
Edema beyond the eyelid	3.6 (1.9–6.7)
Previous antibiotics	3.4 (1.8–6.3)
Age ≥ 3 y	2.3 (1.1–5.0)
Presence of URI or sinusitis (by history)	0.9 (0.5–1.7)
Temperature $\geq 38.0^{\circ}\text{C}$	0.6 (0.3–1.1)

tients with none of these findings, the risk can be further stratified to low, intermediate, and high risk on the basis of the presence of significant edema, an ANC of $>10\,000/\mu\text{L}$, age, and previous antibiotic treatment, as described in Fig 2.

DISCUSSION

In this large study in a pediatric ED setting, we examined the factors that identify candidates for early imaging of the orbit. In the case of patients who presented with periorbital symptoms that may indicate infection, the diagnoses of concern are intraorbital abscess, which may lead to blindness, and intracranial spread of infection or thromboses, which may lead to death.^{9,23,24} Prompt recognition of patients who are at risk for complications, with timely CT imaging and/or specialty surgical consultation, is an early goal for these children. When identified, a discrete abscess collection that is sufficiently large to allow drainage may require surgical drainage.^{9,23} In a carefully monitored setting, many patients with subperiosteal abscess respond well to medical management but must be identified early.²⁵ As a result, we have focused our attention on identifying orbital or subperiosteal abscesses that may require drainage rather than trying to discriminate these infections as being preseptal versus postseptal. Other authors have taken a similar approach and

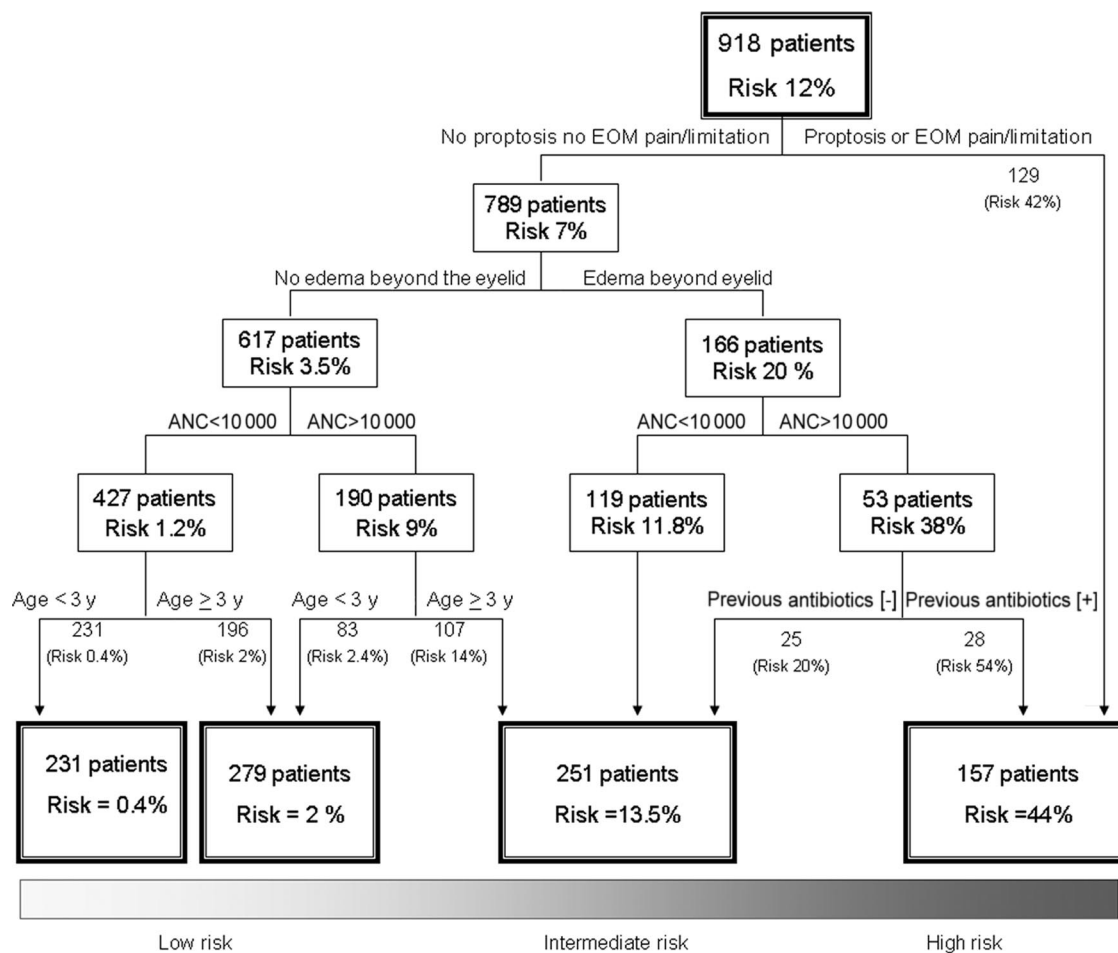


FIGURE 2

Recursive partitioning model stratifying the risk for orbital abscess. A, Patients with proptosis, ophthalmoplegia, or pain with EOM were at high risk. B, Those with edema beyond the eyelid had a risk of 20%, whereas patients with no edema beyond the eyelid had a risk of 3.5%. C, The risk can be further stratified by adding ANC, age, previous antibiotics (shown), and previous conjunctivitis (not shown).

have proposed refining the classification by simply considering those with orbital complications of acute sinusitis and dividing them into 3 main categories (orbital cellulitis, subperiosteal abscess, and orbital abscess) rather than using the more traditional preseptal or postseptal terminology commonly used.²² This strategy leaves preseptal cases in a separate category, because this is not a process that directly affects the orbit.

A previous study of 139 patients who underwent CT scanning (38 had postseptal disease and 101 had preseptal only) showed that proptosis and ophthalmoplegia were found in a significantly higher proportion of patients

with postseptal disease compared with preseptal disease.¹⁴ However, these findings could not discriminate between orbital cellulitis and orbital abscess.¹⁴

We present here 111 patients with Chandler class III or greater, of which almost half had either proptosis or ophthalmoplegia. Our data confirm that clinical findings such as proptosis, ophthalmoplegia, or pain with extraocular movements are causes for concern not only for orbital inflammation but also for abscess. It is important to draw attention to the 56 patients (50.5%) who did not have these classic findings but did have CT disease stage III or higher. Rahbar et al¹⁵

also reported that subperiosteal abscess can present with only swelling and erythema. The proportion of patients with an abscess who lack classic findings is concerning, because the literature suggests that delay in treatment can result in blindness in up to 10% of affected patients.¹⁵ Two of our 111 patients had a course that resulted in blindness. As a result of the poor sensitivity of clinical findings, the clinician needs better tools to identify those at risk. Clinical findings also have poor specificity; 49% of our patients with findings had Chandler class I or II disease.

We also present an algorithm to further stratify the risk for significant

complications among patients who present without these classic symptoms or clinical findings. Our results show that an ANC of $>10\,000$ cells per μL , moderate-to-severe periorbital edema, absence of conjunctivitis as the presenting symptom, age > 3 years, and previous antibiotic use are predictors of an orbital abscess. The suggestion that edema extending beyond the eyelid margins is a strong predictor was previously described by Vu et al²⁶ as part of a severity score. In addition, the Vu et al score suggests high fever ($>39^\circ\text{C}$) as a marker of severity when it comes to predicting an abscess. Our data did not identify fever as a predictor. It is interesting to note that 44% of the patients with an abscess did not have a documented temperature of $>38^\circ\text{C}$ recorded during their illness.

By excluding patients with an evident external source for infection, we identified a high rate with sinus disease on CT scan (94%) and an overall sobering risk of an abscess at 12%. The overall risk may differ depending on the practice setting (tertiary versus primary care). The incidence of surgical procedures in our cohort (63.9%) was similar to that in previous studies (66%).¹⁴ Once the algorithm was applied to our patient population, the total number of

CT scans obtained was unchanged. The effect on number of images obtained in centers that do not have pediatric subspecialty and/or pediatric emergency medicine expertise remains to be seen. However, identifying patients at particularly high risk should provide the opportunity to expedite the care of these patients with a goal of decreasing associated morbidity. One patient excluded from our study was a 2-year-old girl who came back on day 4 with subperiosteal abscess. Had the suggested algorithm been applied to her at her first visit, her risk would have been estimated at 14%. In our model, almost two thirds of the patients can be classified as being at low risk, eliminating the need for emergent imaging. We therefore recommend expedited imaging of those patients who fall into the high-risk category, with strong consideration of imaging for those in the intermediate-risk category.

This study has several limitations. We considered those who did not undergo CT as not having Chandler III or worse disease. As a result, we may have underestimated the percentage of children with significant findings. A subgroup analysis of only those patients who had CT performed was evaluated, and the recursive partitioning yielded similar results (data not shown). It is

also possible that factors related to how patients arrive at a pediatric ED would introduce bias. If so, our screening criteria may perform more poorly in other settings. In addition, there may have been other reasons for obtaining a CT scan that were not evident to us in this retrospective study.

It is also important to note that we have not analyzed the role of MRI in the management of these cases. Others have suggested that MRI be considered for cases in which there is clinical or CT-based suspicion for intracranial complications such as subdural empyema or cavernous sinus thrombosis.^{27,28}

CONCLUSIONS

We present a tool for physicians who are considering emergent CT imaging versus antibiotic therapy and expectant management. In addition to the known high-risk findings of ophthalmoplegia and proptosis, or in the absence of these signs, we have shown that patients who have moderate-to-severe periorbital edema, or an ANC of $>10\,000$ cells per μL , also fall into a high-risk category and their evaluation should be expedited. We also suggest that those at low risk can be easily identified, and that CT imaging is of low yield for these patients.

REFERENCES

1. Lessner A, Stern GA. Preseptal and orbital cellulitis. *Infect Dis Clin North Am*. 1992;6(4): 933–952
2. Givner LB. Periorbital versus orbital cellulitis. *Pediatr Infect Dis J*. 2002;21(12):1157–1158
3. Uzcátegui N, Warman R, Smith A, Howard CW. Clinical practice guidelines for the management of orbital cellulitis. *J Pediatr Ophthalmol Strabismus*. 1998;35(2):73–79; quiz 110–111
4. Smith TF, O'Day D, Wright PF. Clinical implications of preseptal (periorbital) cellulitis in childhood. *Pediatrics*. 1978;62(6):1006–1009
5. Adnan SB. Instructive case: a swollen eye. *J Paediatr Child Health*. 2000;36(2):179–181
6. Wald ER. Periorbital and orbital infections. *Pediatr Rev*. 2004;25(9):312–320
7. Reynolds DJ, Kodsi SR, Rubin SE, Rodgers IR. Intracranial infection associated with preseptal and orbital cellulitis in the pediatric patient. *J AAPOS*. 2003;7(6):413–417
8. Hytönen M, Atula T, Pitkäranta A. Complications of acute sinusitis in children. *Acta Otolaryngol Suppl*. 2000;543:154–157
9. van Dissel JT, de Keizer RJ. Bacterial infections of the orbit. *Orbit*. 1998;17(4):227–235
10. Younis RT, Lazar RH, Bustillo A, Anand VK. Orbital infection as a complication of sinusitis: are diagnostic and treatment trends changing? *Ear Nose Throat J*. 2002;81(11):771–775
11. Starkey CR, Steele RW. Medical management of orbital cellulitis. *Pediatr Infect Dis J*. 2001; 20(10):1002–1005
12. Goldman RD, Dolansky G, Rogovik AL. Predictors for admission of children with periorbital cellulitis presenting to the pediatric emergency department. *Pediatr Emerg Care*. 2008;24(5):279–283
13. Ho CF, Huang YC, Wang CJ, Chiu CH, Lin TY. Clinical analysis of computed tomography-staged orbital cellulitis in children. *J Microbiol Immunol Infect*. 2007;40(6):518–524
14. Sobol SE, Marchand J, Tewfik TL, Manoukian JJ, Schloss MD. Orbital complications of sinusitis in children. *J Otolaryngol*. 2002;31(3): 131–136
15. Rahbar R, Robson CD, Petersen RA, et al. Management of orbital subperiosteal abscess in children. *Arch Otolaryngol Head Neck Surg*. 2001;127(3):281–286
16. Howe L, Jones NS. Guidelines for the manage-

- ment of periorbital cellulitis/abscess. *Clin Otolaryngol Allied Sci.* 2004;29(6):725–728
17. Hirsch M, Lifshitz T. Computerized tomography in the diagnosis and treatment of orbital cellulitis. *Pediatr Radiol.* 1988;18(4):302–305
 18. Eustis HS, Mafee MF, Walton C, Mondonca J. MR imaging and CT of orbital infections and complications in acute rhinosinusitis. *Radiol Clin North Am.* 1998;36(6):1165–1183, xi
 19. Goldberg F, Berne AS, Oski FA. Differentiation of orbital cellulitis from preseptal cellulitis by computed tomography. *Pediatrics.* 1978;62(6):1000–1005
 20. Friedl JEF. *Mastering Regular Expressions.* 3rd ed. Sebastopol, CA: O'Reilly Media Inc; 2006.
 21. Chandler JR, Langenbrunner DJ, Stevens ER. The pathogenesis of orbital complications in acute sinusitis. *Laryngoscope.* 1970; 80(9):1414–1428
 22. Velasco e Cruz AA, Demarco RC, Pereira Valera FC, dos Santos AC, Anselmo-Lima WT, da Silva Marquezini RM. Orbital complications of acute rhinosinusitis: a new classification. *Braz J Otorhinolaryngol.* 2007;73(5): 684–688
 23. Ikeda K, Oshima T, Suzuki H, Kikuchi T, Suzuki M, Kobayashi T. Surgical treatment of subperiosteal abscess of the orbit: Sendai's ten-year experience. *Auris Nasus Larynx.* 2003;30(3):259–262
 24. Brook I, Friedman EM, Rodríguez WJ, Controni G. Complications of sinusitis in children. *Pediatrics.* 1980;66(4):568–572
 25. Garcia GH, Harris GJ. Criteria for nonsurgical management of subperiosteal abscess of the orbit: analysis of outcomes 1988–1998. *Ophthalmology.* 2000;107(8):1454–1456; discussion 1457–1458
 26. Vu BL, Dick PT, Levin AV, Pirie J. Development of a clinical severity score for preseptal cellulitis in children. *Pediatr Emerg Care.* 2003; 19(5):302–307
 27. Kapur R, Sepahdari AR, Mafee MF, et al. MR imaging of orbital inflammatory syndrome, orbital cellulitis, and orbital lymphoid lesions: the role of diffusion-weighted imaging. *AJNR Am J Neuroradiol.* 2009;30(1): 64–70
 28. Sepahdari AR, Aakalu VK, Kapur R, et al. MRI of orbital cellulitis and orbital abscess: the role of diffusion-weighted imaging. *AJR Am J Roentgenol.* 2009;193(3):W244–W250

Acute Periorbital Infections: Who Needs Emergent Imaging?

Tiffany F. Rudloe, Marvin B. Harper, Sanjay P. Prabhu, Reza Rahbar, Deborah VanderVeen and Amir A. Kimia

Pediatrics 2010;125:e719

DOI: 10.1542/peds.2009-1709 originally published online March 1, 2010;

Updated Information & Services

including high resolution figures, can be found at:
<http://pediatrics.aappublications.org/content/125/4/e719>

References

This article cites 27 articles, 5 of which you can access for free at:
<http://pediatrics.aappublications.org/content/125/4/e719#BIBL>

Subspecialty Collections

This article, along with others on similar topics, appears in the following collection(s):
Dermatology
http://www.aappublications.org/cgi/collection/dermatology_sub

Permissions & Licensing

Information about reproducing this article in parts (figures, tables) or in its entirety can be found online at:
<http://www.aappublications.org/site/misc/Permissions.xhtml>

Reprints

Information about ordering reprints can be found online:
<http://www.aappublications.org/site/misc/reprints.xhtml>

American Academy of Pediatrics

DEDICATED TO THE HEALTH OF ALL CHILDREN™



PEDIATRICS®

OFFICIAL JOURNAL OF THE AMERICAN ACADEMY OF PEDIATRICS

Acute Periorbital Infections: Who Needs Emergent Imaging?

Tiffany F. Rudloe, Marvin B. Harper, Sanjay P. Prabhu, Reza Rahbar, Deborah VanderVeen and Amir A. Kimia

Pediatrics 2010;125:e719

DOI: 10.1542/peds.2009-1709 originally published online March 1, 2010;

The online version of this article, along with updated information and services, is located on the World Wide Web at:

<http://pediatrics.aappublications.org/content/125/4/e719>

Pediatrics is the official journal of the American Academy of Pediatrics. A monthly publication, it has been published continuously since 1948. Pediatrics is owned, published, and trademarked by the American Academy of Pediatrics, 141 Northwest Point Boulevard, Elk Grove Village, Illinois, 60007. Copyright © 2010 by the American Academy of Pediatrics. All rights reserved. Print ISSN: 1073-0397.

American Academy of Pediatrics

DEDICATED TO THE HEALTH OF ALL CHILDREN™

