

Visceral Larva Migrans Associated With Earthworm Ingestion: Clinical Evolution in an Adolescent Patient

Antonella Cianferoni, MD^a, Lynda Schneider, MD^a, Peter M. Schantz, VMD, PhD^b, Daniel Brown, MD, PhD^a, LeAnne M. Fox, MD, MPH^{c,d}

Divisions of ^aImmunology and ^cInfectious Diseases, Children's Hospital, Boston, Massachusetts; ^bDivision of Parasitic Diseases, Centers for Disease Control and Prevention, Atlanta, Georgia; ^dCenter for International Health and Development, Boston University, Boston, Massachusetts

The authors have indicated they have no financial relationships relevant to this article to disclose.

ABSTRACT

A 16-year-old girl developed a cough, hypereosinophilia (absolute eosinophil count: 32 000/mm³), hypergammaglobulinemia, and multiple noncavitary pulmonary nodules 1 month after having ingested an earthworm on a dare. Spirometry revealed moderate restriction and reduced gas diffusion. Parabronchial biopsy demonstrated eosinophilic organizing pneumonitis with multiple eosinophilic microabscesses, and *Toxocara* titers were elevated (>1:4096). Ophthalmologic examination ruled out ocular larva migrans. The patient received a 10-day course of albendazole (400 mg orally twice daily) and demonstrated significant clinical improvement with resolution of cough and pulmonary function abnormalities. Her white blood cell count and hypergammaglobulinemia normalized within 20 days, yet eosinophils (absolute eosinophil count: 1780/mm³) and *Toxocara* serologies (>1:4096) remained elevated 3½ months after completing antihelminthic therapy. In this instance, the ingested earthworm served as the paratenic carrier of *Toxocara* larvae from the soil to the patient. This case highlights the clinical evolution of pulmonary visceral larva migrans infection caused by *Toxocara* spp. associated with a discrete ingestion in an adolescent patient. In addition, it provides a rare opportunity to define the incubation period of visceral larva migrans and emphasizes the importance of education regarding sources of *Toxocara* infection.

CASE REPORT

A 16-YEAR-OLD WHITE female with a history of asthma, urticaria, and bipolar disorder presented for evaluation to the allergy program of our hospital in mid-September 2004 with a 2-week history of progressively increasing eosinophilia associated with moderate cough, wheezing, and 5-lb weight loss. Two weeks before presentation, she had experienced nausea, a temperature to 101°F, and swelling around her eyes, cheeks, and lips and near the thenar eminence of the palm. All symptoms spontaneously resolved in 2 to 3 days.

On physical examination diffuse wheezes with moderately diminished air entry were noted on lung auscultation. Otherwise, the patient had a soft, nontender abdomen without organomegaly, no lymphadenopathy, rashes, or ocular symptoms, and a normal mental-status examination. Spirometry revealed moderate restriction (forced vital capacity [FVC]: 2.78 L at 54% of predicted [reference range: 80–100%]; forced expiratory volume in 1 second [FEV₁]: 2.22 L at 58% of predicted [reference range: 80–100%]; FEV₁/FVC: 107% [reference range: 80–100%]; forced expiratory flow rate between 25% and 75% of the forced vital capacity [FEF_{25–75}]:

2.07 L/second at 55% of predicted [reference range: 70–100%]) and reduced gas diffusion (diffusion capacity of 14.63 at 58% of predicted [reference range: 80–100%]). Laboratory evaluation revealed leukocytosis, a white blood cell (WBC) count of 47 800/mm³ with 67% eosinophils (absolute eosinophil count: 32 000/mm³), elevated platelet count (445 000/mm³), and normal hematocrit. Hypergammaglobulinemia, with increased levels of immunoglobulin (Ig)G (1870 mg/L [reference range: 639–1344 mg/L]), IgM (962 mg/L [reference range: 40–240 mg/L]), and IgE (1570 ng/L [reference range: 0–200 ng/L]), was also noted.

Key Words: visceral larva migrans, *Toxocara*, pediatric, eosinophilia, pulmonary

Abbreviations: FVC, forced vital capacity; FEV₁, forced expiratory volume in 1 second; FEF_{25–75}, forced expiratory flow rate between 25% and 75% of the forced vital capacity; WBC, white blood cell; Ig, immunoglobulin; VLM, visceral larva migrans

www.pediatrics.org/cgi/doi/10.1542/peds.2005-1596

doi:10.1542/peds.2005-1596

Accepted for publication Sep 9, 2005

Address correspondence to LeAnne M. Fox, MD, MPH, Division of Infectious Diseases, Children's Hospital, 300 Longwood Ave, Boston, MA 02115. E-mail: leanne.fox@childrens.harvard.edu or lfox@bu.edu

PEDIATRICS (ISSN Numbers: Print, 0031-4005; Online, 1098-4275). Copyright © 2006 by the American Academy of Pediatrics

The erythrocyte sedimentation rate, C-reactive protein, antineutrophil cytoplasmic antibody, IgA hepatic transaminase, serum urea nitrogen, and creatinine levels were within normal limits. An echocardiogram and electrocardiogram were normal.

The patient denied any history of travel. She smokes half a pack of cigarettes per day and had been taking ibuprofen once or twice daily for occasional headaches for 2 weeks before evaluation. She had a cat and guinea pig at home. She denied pica but stated that she had eaten an earthworm on a dare at the beginning of August 2004. This event occurred in a friend's backyard in which a dog and puppy frequently played. She also denied ingestion of any undercooked or raw meat or liver.

Non-contrast-enhanced chest computed tomography images demonstrated small (5-mm), noncavitary bilateral nodular opacities that were predominantly peripheral in location; several were associated with a hazy ground-glass appearance (Fig 1). Small bilateral pleural effusions were noted also. There was no evidence of pulmonary consolidation or hilar, parabranchial, or mediastinal lymphadenopathy. In addition, there was no imaging evidence of hepatic or splenic involvement or abdominal lymph node enlargement. Bronchoalveolar-lavage cultures were negative for viruses and bacteria. A parabranchial biopsy demonstrated an eosinophilic organizing pneumonitis with multiple eosinophilic microabscesses (Fig 2). No vasculitis, granulomas, or parasites were seen on biopsy. Because of concern for a malignant process, specifically acute lymphoblastic leukemia, the patient underwent a bone marrow biopsy that revealed a 70% cellular marrow, normocellular for age, with an increase in eosinophilic forms, estimated to be 50% to 60% (Fig 3).

Additional testing revealed that the patient was puri-

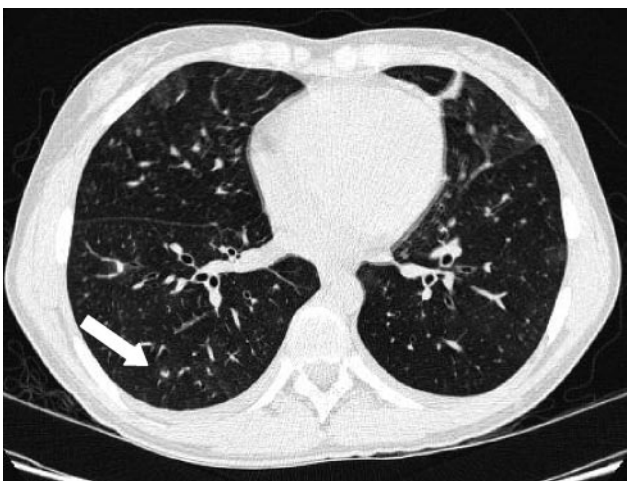

FIGURE 1
Non-contrast-enhanced axial computed tomography image of the lungs at presentation with multifocal noncavitary pulmonary nodules (the arrow indicates 1 nodule).

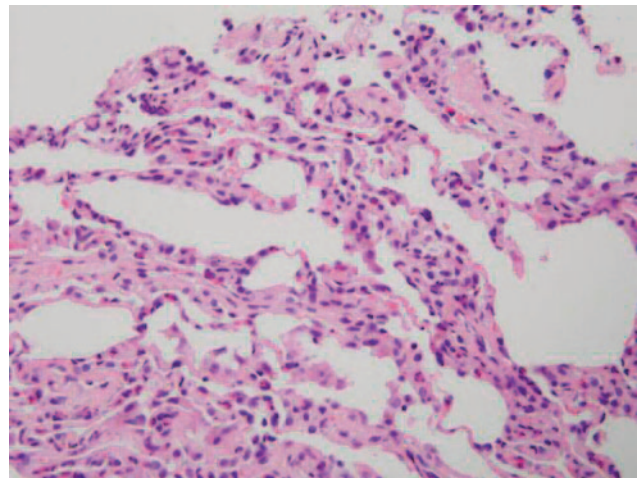


FIGURE 2
Hematoxylin-eosin stain of transbronchial biopsy that demonstrates organizing eosinophilic pneumonitis.

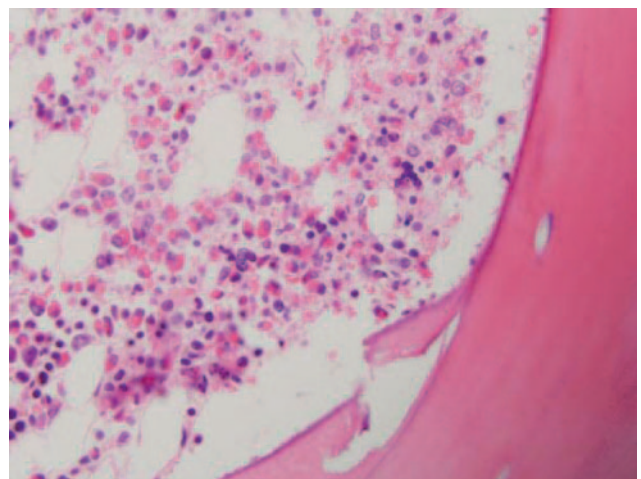


FIGURE 3
Bone marrow biopsy, with 50% to 60% eosinophils.

fied protein derivative-negative and had negative stool ova and parasite examinations. Serological testing for *Trichinella spiralis* and *Strongyloides stercoralis* were negative. *Toxocara* titers returned positive with values of >1:4096 (reference: <1:32). Ophthalmologic examination ruled out ocular larva migrans.

The patient received a 10-day course of albendazole (400 mg orally twice daily) and demonstrated significant clinical improvement with resolution of cough and pulmonary function abnormalities within several days into the course of therapy (FVC: 3.70 L at 102% of predicted [reference range: 80–100%]; FEV₁: 3.25 L at 101% of predicted [reference range: 80–100%]; FEV₁/FVC: 100% [reference range: 80–100%]; FEF_{25–75}: 3.92 L/second at 100% of predicted [reference range: 70–100%]) and normal gas diffusion (diffusion capacity of 22.04 at 88% of predicted [reference range: 80–100%]). Her WBC count and hypergammaglobulinemia normal-

ized within 20 days. Nevertheless, despite marked clinical improvement, eosinophils (WBC count: 9350 with 19% eosinophils; absolute eosinophil count: 1780/mm³) and *Toxocara* serologies (>1:4096) remained elevated 3½ months after completing antihelminthic therapy.

DISCUSSION

To our knowledge, this is the first case report that describes the clinical course of pulmonary visceral larva migrans (VLM) caused by *Toxocara* spp. associated with a discrete ingestion in an adolescent patient. The majority of *Toxocara* infections occur in young children, 1 to 4 years of age, for whom ingestion of contaminated soil is the obvious means of infection.¹ Nevertheless, among helminth infections affecting humans in developed countries, *Toxocara* ranks second only to pinworm infection in frequency.²

In this case, the ingested earthworm served as the paratenic carrier of *Toxocara* larvae from the soil to the patient. Researchers have demonstrated that *Toxocara* larvae are distributed in the tissues of earthworms exposed to infective *Toxocara* eggs and can be transmitted to animal hosts when they are fed earthworms.³ In addition, this known single-point source ingestion, in contrast to multiple instances of soil ingestion that is seen more commonly in young children, provides a rare opportunity to define the incubation period of VLM (~4 weeks between ingestion and symptom onset in this case).

Although infection is most often clinically asymptomatic⁴ and self-resolving, pulmonary involvement can cause cough, wheeze, dyspnea, and infiltrates and may mimic bronchitis, pneumonia, or asthma. Adults with *Toxocara* spp. pulmonary infection have presented with respiratory failure,^{5,6} eosinophilic pleural effusions,^{7,8} pulmonary nodules, and acute and chronic eosinophilic pneumonia.^{9,10} Previous reports in the pediatric literature have demonstrated varied presentations of VLM in children including chronic hypereosinophilia,¹¹ hepatic granulomas and abdominal lymph node enlargement,¹² central nervous system toxocariasis (ie, eosinophilic meningoencephalitis, cerebritis, myelitis),^{13–16} pulmonary involvement including wheezing, coughing, respiratory distress, and pulmonary infiltration,¹⁷ myocarditis,^{18,19} and, more recently, thrombocytosis.²⁰ VLM has been associated also with pyogenic liver abscesses in children.^{14,21} In addition, *Toxocara* infection has caused pericardial tamponade²² and has also been shown to mimic lymphoma.²³

Our patient demonstrated the classic clinical findings seen with pulmonary toxocariasis, including fever, wheezing, coughing, pulmonary nodules, and eosinophilic pneumonia. In young children, fever and hepatomegaly have been shown to be common clinical signs, and abdominal ultrasound examination findings in children with *Toxocara* spp. infection include hepatospleno-

megaly, hepatic granulomas, and abdominal lymph node enlargement.¹² Nevertheless, it has been noted that hepatic nodules in VLM may not be very numerous or well defined, suggesting that such lesions might be overlooked.¹² The hypergammaglobulinemia noted on laboratory evaluation suggests hepatic migration of larvae in this patient, although no clinical or radiologic hepatic abnormalities were seen. In addition, our patient demonstrated thrombocytosis on initial presentation and for 2½ weeks during her illness; a laboratory manifestation of VLM that has been reported only recently.²⁰ Because of the findings of hypereosinophilia in association with multiple pulmonary nodules, our patient underwent bone marrow biopsy to rule out a malignant process. A normocellular marrow with striking eosinophilic predominance was noted, which suggested a reactive process, as seen with a parasitic infection.

Although the definitive diagnosis of toxocariasis requires detecting *Toxocara* larvae in the tissues, larvae are found only rarely on pathologic examination. Alternatively, the detection of specific antibodies for *Toxocara* larval antigens, in the context of marked hypereosinophilia (range: 17–85%; mean: 38%),²⁴ hypergammaglobulinemia, and negative serological results for other parasitic diseases, strongly supports the diagnosis of acute *Toxocara* infection. Specifically, the remarkably high enzyme-linked immunosorbent assay titer (>1:4096) using *Toxocara* spp. excretory/secretory antigen from second-stage (L2) larvae in this patient who had ingested dirt while eating an earthworm, a known paratenic carrier of *Toxocara* larvae, in an area in which dogs and puppies had played and likely defecated, were strongly suggestive of acute infection. Antibody to the excretory-secretory *Toxocara* spp. antigen via the enzyme-linked immunosorbent assay method has a sensitivity of 78% and specificity of 92% at a titer of 1:32 for VLM.²⁵ The quantity of the infecting dose and frequency of reinfection affects the distribution and survival of *Toxocara* spp. larvae and contributes to the marked eosinophilia and hypergammaglobulinemia seen with VLM. Infection with *Toxocara* spp. can produce a profound inflammatory response, not unlike atopy, and perhaps contributed to our patient's initial symptoms of swelling around the eyes, lips, and cheeks. Eosinophilia, leukocytosis,¹ and *Toxocara* serological response¹⁶ may take months to years to resolve even when all clinical symptomatology has normalized. Given the extent of pulmonary findings in our patient associated with strongly elevated *Toxocara* titers, we postulate that this patient ingested a large inoculum of larvae and had a pronounced allergic and inflammatory reaction to the parasite, notwithstanding the history of an isolated ingestion of contaminated soil associated with eating an earthworm.

Previous publications have reported that VLM is a benign and self-limited illness and that treatment of mild

cases is rarely necessary.^{4,5} Nevertheless, severe pulmonary, myocardial, or central nervous system involvement may warrant therapy. Recommended antihelmintics, for adults and children, include albendazole 400 mg twice a day for 5 days or mebendazole 100 to 200 mg twice a day for 5 days, although the optimal duration of therapy is not known.²⁶ Treatment with antihelmintics, particularly in cases of recent *Toxocara* infection, will aid in limiting additional migration of *Toxocara* larvae and may decrease the possibility of even a single larva migrating into the eye and causing ocular damage. There is no consensus concerning the utility of corticosteroids in the treatment of VLM, although steroids have been felt to be beneficial in cases of severe respiratory or myocardial involvement.

This case also highlights the high prevalence of *Toxocara* eggs in the soil environment. Numerous studies have demonstrated *Toxocara* eggs in substantial proportions in environmental soil samples from public parks, playgrounds, and backyards worldwide.^{27–29} Eating earthworms, which ingest soil and are covered in soil, is certainly a risk for infection with *Toxocara*.

Although most pediatric patients with clinically evident VLM present with fever and hepatomegaly, this case, an adolescent patient with hypereosinophilia and nodular pulmonary disease, demonstrates the variations in clinical symptomatology in pediatric patients. Clinical recovery from pulmonary VLM may be rapid despite continued eosinophilia and consistently elevated *Toxocara* titers. Public education about the sources of *Toxocara* infection is a priority.

ACKNOWLEDGMENTS

Dr Fox acknowledges support from the Pediatric Infectious Diseases Society Fellowship Award funded by GlaxoSmithKline.

We thank Marianna Wilson (Division of Parasitic Diseases, Centers for Disease Control and Prevention) for assistance with *Toxocara* testing.

REFERENCES

1. Schantz PM, Glickman LT. Toxocaral visceral larva migrans. *N Engl J Med*. 1978;298:436–439
2. Schantz PM. *Toxocara* larva migrans now. *Am J Trop Med Hyg*. 1989;41:21–34
3. Pahari TK, Sasmal NK. Experimental infection of Japanese quail with *Toxocara canis* larvae through earthworms. *Vet Parasitol*. 1991;39:337–340
4. Bass JL, Mehta KA, Glickman LT. Asymptomatic toxocariasis in children. *Clin Pediatr (Phila)*. 1987;26:441–446
5. Feldman GJ, Worth Parker H. Visceral larva migrans associated with the hypereosinophilic syndrome and the onset of severe asthma. *Ann Intern Med*. 1992;116:838–840
6. Bartelink AK, Kortbeek LM, Huidekoper HJ, Meulenbelt J, van

- Knapen F. Acute respiratory failure due to *Toxocara* infection. *Lancet*. 1993;342:1234
7. Ashwath MK, Robinson DR, Katner HP. A presumptive case of toxocariasis associated with eosinophilic pleural effusion: case report and literature review. *Am J Trop Med Hyg*. 2004;71:764
8. Jeanfaivre T, Cimon B, Tolstuchow N, de Gentile L, Chabasse D, Tuchais E. Pleural effusion and toxocariasis. *Thorax*. 1996; 51:106–107
9. Roig J, Romeu J, Riera C, Texido A, Domingo C, Morera J. Acute eosinophilic pneumonia due to toxocariasis with bronchoalveolar lavage findings. *Chest*. 1992;102:294–296
10. Inoue K, Inoue Y, Arai T, et al. Chronic eosinophilic pneumonia due to visceral larva migrans. *Intern Med*. 2002;41:478–482
11. Guerra A, Navarro C, de Guevara CL. Seroprevalence of toxocariasis in children and a case of VLM. *Eur J Epidemiol*. 1995; 11:701–702
12. Baldisserotto M, Conchin CF, Soares Mda G, Araujo MA, Kramer B. Ultrasound findings in children with toxocariasis: report on 18 cases. *Pediatr Radiol*. 1999;29:316–319
13. Bachli H, Minet JC, Gratzl O. Cerebral toxocariasis: a possible cause of epileptic seizure in children. *Childs Nerv Syst*. 2004;20: 468–472
14. Moreira-Silva SF, Pereira FE. Intestinal nematodes, *Toxocara* infection, and pyogenic liver abscess in children: a possible association. *J Trop Pediatr*. 2000;46:167–172
15. Vidal JE, Sztajnbock J, Seguro AC. Eosinophilic meningoencephalitis due to *Toxocara canis*: case report and review of the literature. *Am J Trop Med Hyg*. 2003;69:341–343
16. Goffette S, Jeanjean AP, Duprez TP, Bigaignon G, Sindic CJ. Eosinophilic pleocytosis and myelitis related to *Toxocara canis* infection. *Eur J Neurol*. 2000;7:703–706
17. Beshear JR, Hendley JO. Severe pulmonary involvement in visceral larva migrans. *Am J Dis Child*. 1973;125:599–600
18. Friedman S, Hervada AR. Severe myocarditis with recovery in a child with visceral larva migrans. *J Pediatr*. 1960;56:91–96
19. Vargo TA, Singer DB, Gillatte PC, Fernbach DJ. Myocarditis due to visceral larva migrans. *J Pediatr*. 1977;90:322–323
20. Kagialis-Girard S, Mialou V, Ffrench M, Dupuis-Girod S, Pages MP, Bertrand Y. Thrombocytosis and toxocariasis: report of two pediatric cases. *Pediatr Blood Cancer*. 2004;44:190–192
21. Pereira FE, Musso C, Castelo SJ. Pathology of pyogenic liver abscess in children. *Pediatr Dev Pathol*. 1999;2:537–543
22. Herry I, Philippe B, Hennequin C, Danel C, Lejeunne C, Meyer G. Acute life-threatening toxocaral tamponade. *Chest*. 1997; 112:1692–1693
23. Bachmeyer C, Lamarque G, Morariu R, Molina T, Bouree P, Delmer A. Visceral larva migrans mimicking lymphoma. *Chest*. 2003;123:1296–1297
24. Dunne K, Gill D. Toxocariasis: diagnosis and dilemmas. *Br J Clin Pract*. 1987;41:681–683
25. Schantz PM. Improvements in the serodiagnosis of helminthic zoonoses. *Vet Parasitol*. 1987;25:95–120
26. Drugs for parasitic infections. *Med Lett Drugs Ther*. 2004;1189: 1–12
27. Chorazy ML, Richardson DJ. A survey of environmental contamination with ascarid ova, Wallingford, Connecticut. *Vector Borne Zoonotic Dis*. 2005;5:33–39
28. Mizgajski H. Eggs of *Toxocara* spp. in the environment and their public health implications. *J Helminthol*. 2001;75:147–151
29. Gillespie SH, Pereira M, Ramsay A. The prevalence of *Toxocara canis* ova in soil samples from parks and gardens in the London area. *Public Health*. 1991;105:335–339

Visceral Larva Migrants Associated With Earthworm Ingestion: Clinical Evolution in an Adolescent Patient

Antonella Cianferoni, Lynda Schneider, Peter M. Schantz, Daniel Brown and LeAnne M. Fox

Pediatrics 2006;117:e336
DOI: 10.1542/peds.2005-1596

Updated Information & Services	including high resolution figures, can be found at: http://pediatrics.aappublications.org/content/117/2/e336
References	This article cites 29 articles, 4 of which you can access for free at: http://pediatrics.aappublications.org/content/117/2/e336#BIBL
Subspecialty Collections	This article, along with others on similar topics, appears in the following collection(s): Infectious Disease http://www.aappublications.org/cgi/collection/infectious_diseases_sub
Permissions & Licensing	Information about reproducing this article in parts (figures, tables) or in its entirety can be found online at: http://www.aappublications.org/site/misc/Permissions.xhtml
Reprints	Information about ordering reprints can be found online: http://www.aappublications.org/site/misc/reprints.xhtml

American Academy of Pediatrics

DEDICATED TO THE HEALTH OF ALL CHILDREN™



PEDIATRICS®

OFFICIAL JOURNAL OF THE AMERICAN ACADEMY OF PEDIATRICS

Visceral Larva Migrans Associated With Earthworm Ingestion: Clinical Evolution in an Adolescent Patient

Antonella Cianferoni, Lynda Schneider, Peter M. Schantz, Daniel Brown and LeAnne M. Fox

Pediatrics 2006;117:e336
DOI: 10.1542/peds.2005-1596

The online version of this article, along with updated information and services, is located on the World Wide Web at:

<http://pediatrics.aappublications.org/content/117/2/e336>

Pediatrics is the official journal of the American Academy of Pediatrics. A monthly publication, it has been published continuously since 1948. Pediatrics is owned, published, and trademarked by the American Academy of Pediatrics, 141 Northwest Point Boulevard, Elk Grove Village, Illinois, 60007. Copyright © 2006 by the American Academy of Pediatrics. All rights reserved. Print ISSN: 1073-0397.

American Academy of Pediatrics

DEDICATED TO THE HEALTH OF ALL CHILDREN™

