

# Linear Scleroderma en coup de sabre With Associated Neurologic Abnormalities

Kristen E. Holland, MD<sup>a</sup>, Burt Steffes, MD, James J. Nocton, MD<sup>b</sup>, Michael J. Schwabe, MD<sup>c</sup>, Richard D. Jacobson, MD, PhD<sup>c</sup>, Beth A. Drolet, MD<sup>a</sup>

<sup>a</sup>Departments of Pediatrics and Dermatology, <sup>b</sup>Department of Pediatrics, Division of Rheumatology, <sup>c</sup>Department of Neurology, Division of Pediatric Neurology, Medical College of Wisconsin, Milwaukee, Wisconsin

The authors have indicated they have no financial relationships relevant to this article to disclose.

## ABSTRACT

Linear scleroderma represents a unique form of localized scleroderma that primarily affects the pediatric population, with 67% of patients diagnosed before 18 years of age. When linear scleroderma occurs on the head, it is referred to as linear scleroderma en coup de sabre, given the resemblance of the skin lesions to the stroke of a sabre. Here we describe 3 pediatric patients with linear scleroderma en coup de sabre who presented with neurologic abnormalities before or concurrent with the diagnosis of their skin disease. Our patients' cases highlight the underrecognized relationship between neurologic complications and linear scleroderma en coup de sabre and illustrate the importance of a thorough skin examination in patients with unexplained neurologic disease.

**S**CLERODERMA IS A rare disease of unknown etiology in which increased collagen deposition occurs and results in dermal thickening. Involvement may be diffuse (systemic sclerosis) or localized to the skin (localized scleroderma). Linear scleroderma represents a unique form of localized scleroderma that primarily affects the pediatric population, with 67% of patients diagnosed before 18 years of age.<sup>1</sup> Linear scleroderma frequently occurs on the limbs but also may develop in the frontoparietal area of the forehead and scalp. When linear scleroderma occurs on the head, it is referred to as linear scleroderma en coup de sabre, given the resemblance of the skin lesions to the stroke of a sabre. Neurologic abnormalities have been described in association with linear scleroderma en coup de sabre. Typically, characteristic skin involvement is recognized before the development of neurologic disease. We describe 3 pediatric patients with linear scleroderma en coup de sabre who presented with neurologic abnormalities before or concurrent with the diagnosis of their skin disease. Their cases illustrate the variability in neurologic manifestations of linear scleroderma en coup de sabre as well as the importance of a careful skin examination in patients with unexplained neurologic disease.

## CASE REPORTS

**CASE 1.** A 5-year-old girl presented with new-onset partial complex seizures and skin lesions. An epileptiform pat-

tern in the left posterotemporal area was detected by electroencephalogram (EEG), and she was started on anticonvulsants. Imaging by computed tomography (CT) and MRI was normal. Enlargement of the skin lesions prompted a referral to dermatology, and examination revealed a linear, indurated plaque with alopecia extending from her left eyebrow into the hair-bearing scalp. Gray-brown atrophic plaques were also present on the midline of her scalp and on her neck extending from her left mandible to the anterior shoulder. A diagnosis of linear scleroderma en coup de sabre was made based on the characteristic skin changes observed. Her anti-single-stranded DNA level was slightly elevated at 159  $\mu$ /ml; her antinuclear antibodies (ANA), rheumatoid factor, complete blood count, anti-extractable nuclear antigens, and anti-double-stranded DNA levels were all within normal limits.

Despite treatment with high-potency topical corticosteroids, there was significant progression of her facial lesions as well as development of a new erythematous,

**Key Words:** pediatric, scleroderma, en coup de sabre, neurologic, children  
**Abbreviations:** EEG, electroencephalogram; CT, computed tomography; ANA, antinuclear antibodies

[www.pediatrics.org/cgi/doi/10.1542/peds.2005-0470](http://www.pediatrics.org/cgi/doi/10.1542/peds.2005-0470)

doi:10.1542/peds.2005-0470

Accepted for publication Jul 22, 2005

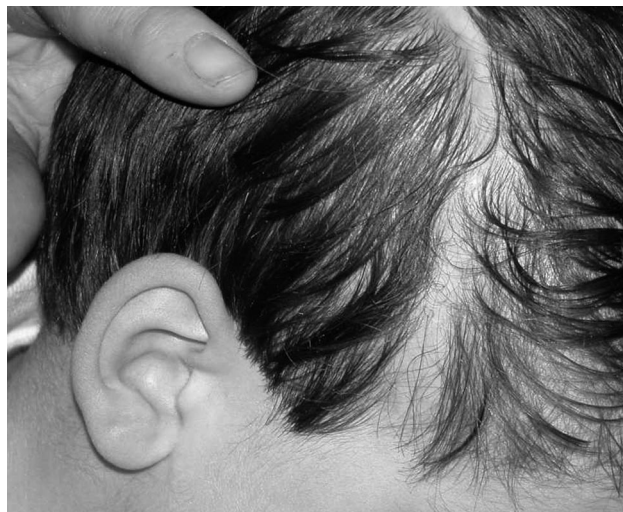Address correspondence to Kristen E. Holland, MD, Department of Dermatology, 9200 W Wisconsin Ave, Milwaukee, WI 53226. E-mail: [kholland@mcw.edu](mailto:kholland@mcw.edu)  
 PEDIATRICS (ISSN 0031 4005). Copyright © 2005 by the American Academy of Pediatrics

indurated plaque over her left malar eminence. The cutaneous disease eventually stabilized, and topical treatment was discontinued after a total of 18 months. Over the next 4 years, serial EEGs showed improvement in wave form, and the patient was tapered off anticonvulsants successfully. At age 14, 5 years after anticonvulsants were stopped, she had another generalized seizure (after 8 seizure-free years). A repeat brain MRI was again normal. She has been restarted on anticonvulsants and has been seizure free for the last year. At the last follow-up visit, all her lesions were soft, but she had persistent hyperpigmentation and linear depressed plaques most notable over the forehead. No facial asymmetry was present.

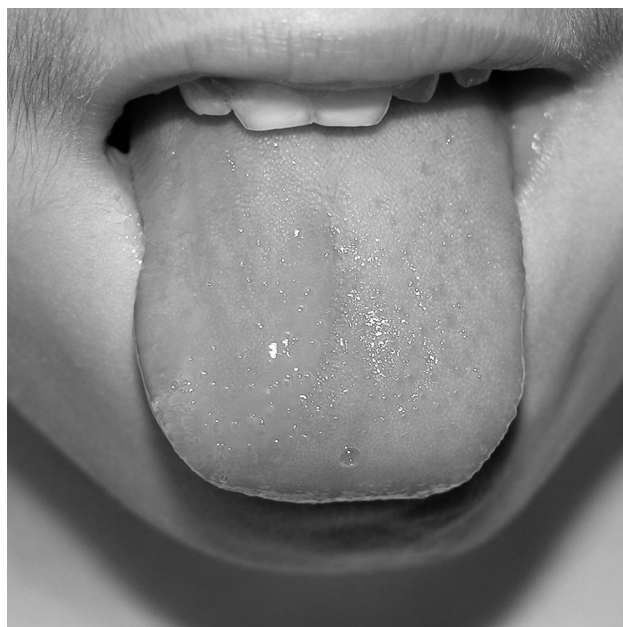
**CASE 2.** A 6-year-old previously healthy boy was first noted to have decreased movement of the right side of his mouth at the age of 5. Several months later, it was noted that the palsy had progressed to include his right cheek. The patient was also experiencing mild headaches 2 to 3 times per week and intermittent abdominal pain with poor weight gain. The patient was evaluated by a neurologist and was found to have palsy of the mandibular branch of the right facial nerve. An MRI was normal, and the etiology of his neurologic changes was unexplained. No cause was found for the abdominal symptoms.

Several months after his neurologic symptoms began, his parents noted a small annular, erythematous area of alopecia on his right parietal scalp. The lesion expanded slowly over the next several months and extended anteriorly toward the forehead and posteriorly toward his occiput. Linear scleroderma was diagnosed; however, his parents were told that his skin changes were not related to his neurologic abnormalities. Treatment with monthly intramuscular triamcinolone acetonide injections was started after a trial of oral steroids was not tolerated.

At the time of presentation to our clinic, the patient's parents reported rapid expansion of the cutaneous lesion. On examination, there was a 12-cm indurated, linear plaque on the right parietal scalp that extended from just behind the ear to the frontal hairline (Fig 1). This lesion was mostly yellow in color, but the advancing edge was violaceous. On the right upper arm the patient also had four 2- to 3-cm, dull pink-brown, atrophic patches. An atrophic, smooth, elliptical patch orientated longitudinally was also noted on the right side of the patient's tongue (Fig 2). A detailed neurologic examination revealed decreased retraction and depression of the right angle of the mouth, which affected his smile. Elevation of the right angle of the mouth was slightly diminished compared with the left with nasolabial fold sparing. Taste was decreased on the right side of his tongue compared with his left. All other cranial nerves were intact. Follow-up MRIs have been normal.



**FIGURE 1**  
Indurated, yellowish, linear plaque on parietal scalp.



**FIGURE 2**  
An atrophic, smooth, elliptical patch present on the tongue.

The patient was treated with intravenous methylprednisolone and subcutaneous methotrexate. The protocol included receiving 3 consecutive days of intravenous methylprednisolone at 30 mg/kg per day followed by monthly infusions of methylprednisolone at 30 mg/kg for 3 months. Weekly subcutaneous methotrexate 7.5 mg was started in combination with the methylprednisolone. The patient's cutaneous and neurologic disease has stabilized on this regimen.

**CASE 3.** A 5½-year-old girl presented with a white patch on the midline of her forehead extending onto the nasal bridge and was diagnosed initially with vitiligo. Two

months later, she had a seizure. An EEG at that time was normal, but a brain MRI showed patchy signal changes in the left frontal lobe and biparietal paraventricular region. Over the next several months, she continued to have uncontrolled partial complex seizures, and additional studies were performed. Video/EEG captured seizures with clinical confusion with staring and looking around arising from the left frontal-temporal areas. A repeat MRI showed prominent T2 signal in the left subcortical and deep white matter, and CT demonstrated calcifications and encephalomalacia of frontal white matter. A positron emission tomography scan showed hypometabolic areas in the left frontal lobe corresponding to the encephalomalacia and calcifications seen on CT. Additional MRI changes with expansion of the T2 signal within the frontal cortex and deep gray matter were concerning for neoplasm. She underwent a left frontal craniotomy with partial resection of the left frontal lobe abnormality. The pathology showed chronic perivascular lymphocytic inflammation with aggregates of dilated vessels and partially organized thrombi. Some vessels showed intimal thickening and hyalinization with occasional intravascular thrombi. Multiple calcifications were present in the areas of the abnormal vessels. There was no evidence of neoplasm. The pathologic changes raised the possibility of a focal, but primary vasculitis. Given the vascular changes, she was referred to rheumatology and dermatology to evaluate for systemic vasculitis. On physical examination, there was a linear V-shaped, slightly depressed, 5.0 × 1.5-cm brown-purple plaque on the midline of her forehead. The overlying skin was shiny with prominent blood vessels. There were no other cutaneous or systemic signs of vasculitis. The clinical diagnosis of linear scleroderma en coup de sabre was made. Laboratory tests including ANA, anticardiolipin antibodies, and anticentromere antibody were normal. In light of her skin changes, the neuropathologic changes were not felt to represent a primary vasculitis but rather secondary changes related to linear scleroderma en coup de sabre. She has done well postoperatively with no recurrence of seizures. Treatment with weekly methotrexate was instituted.

## DISCUSSION

Scleroderma is a connective tissue disorder of unknown etiology that encompasses a wide range of disease from systemic involvement of internal organs to localized cutaneous involvement. When internal organ involvement is present, many experts prefer the term systemic sclerosis, although both terms continue to be used interchangeably. To add to the confusing nosology, the term “morphea” is synonymous with the localized form. Although both systemic and localized forms are characterized by sclerosis of the skin and subcutaneous tissue, localized scleroderma lacks internal organ involvement. Localized scleroderma or morphea may be subdivided

into 5 main types: bullous morphea, plaque morphea, generalized morphea, deep morphea, and linear scleroderma.<sup>2</sup> Unlike most forms of localized scleroderma, which lack extracutaneous manifestations, a subset of linear scleroderma referred to as en coup de sabre has been associated with several neurologic abnormalities.<sup>3-9</sup>

Many of the epidemiologic studies of scleroderma have come from dermatology and rheumatology centers, where referral bias influences estimates of the incidence, prevalence, and severity of this disease. Systemic scleroderma is rare in the pediatric population, and localized scleroderma has been estimated to be at least 10 times more common than systemic disease.<sup>10,11</sup> A population-based retrospective study of Olmsted County in Rochester, Minnesota, over a 33-year period has provided some epidemiologic information regarding localized scleroderma. Of the subtypes of localized scleroderma, the predilection of linear scleroderma for childhood is well recognized.<sup>3,12</sup> In the Minnesota study, 67% of the patients with linear scleroderma were diagnosed before the age of 18. All forms of localized scleroderma have a 3:1 female predominance except for linear scleroderma, in which males and females are affected equally.<sup>1</sup>

Linear scleroderma en coup de sabre is a rare subset of linear scleroderma defined by its characteristic location on the forehead and scalp. Clinically, it is manifested by ivory-colored, sclerotic plaques with violaceous borders distributed in a band-like fashion on the frontoparietal scalp and forehead. Alopecia of the affected scalp is common and often the presenting complaint. Lesions may extend to the nose, cheek, chin, and neck.<sup>13,14</sup> Facial hemiatrophy may develop as a result of hypoplasia of the underlying bone and soft tissues. Progressive hemifacial atrophy (Parry-Romberg syndrome) is a related disorder characterized by progressive hemifacial atrophy without cutaneous sclerosis. Debate continues as to whether Parry-Romberg syndrome is a distinct disease entity or a variant of linear scleroderma, but many would agree that they are closely related forms of craniofacial scleroderma. The diagnosis is a clinical one that relies on the characteristic cutaneous and soft tissue findings because there are currently no diagnostic laboratory tests. ANA with homogeneous and speckled patterns may be positive in 37% to 50% of patients with linear scleroderma, and anti-single-stranded-DNA antibodies may be present.<sup>1,15,16</sup> More specific autoantibodies such as Scl-70, anticentromere, Ro/La, and U1RNP may precede development of systemic disease, and patients with these markers should be followed closely for several years.<sup>15</sup>

Patients with localized scleroderma, by definition, have sclerosis limited to their skin and soft tissue. However, linear scleroderma, mainly the en coup de sabre subtype, often has extracutaneous associations. When linear scleroderma occurs on the extremities, local ab-

normalities such as limb-length discrepancy or joint contractures may occur secondary to sclerosis of the skin. In contrast, the en coup de sabre subtype of linear scleroderma is notorious for multisystem morbidity. Marzano et al<sup>3</sup> reported the presence of ocular, oral, and neurologic abnormalities in almost half of the 17 patients identified with craniofacial involvement (including en coup de sabre, Parry-Romberg, and mixed types). Specific associations with craniofacial scleroderma reported in the literature are listed in Table 1. Development of cutaneous disease typically precedes the onset of extracutaneous manifestations. The time line for the development of systemic findings is typically on the order of months, but reports of delayed onset of neurologic disease several years later exist.<sup>4,17</sup> Systemic signs and symptoms may not parallel cutaneous disease activity.<sup>17</sup>

Neurologic complications are the most common systemic association with linear scleroderma en coup de sabre. Complex partial seizures have been reported most frequently.<sup>5</sup> Abnormalities on MRI and CT studies may be seen in patients with linear scleroderma en coup de sabre even in the absence of neurologic disease.<sup>6,7</sup> Radiologic abnormalities are predominately ipsilateral to the skin disease but may be contralateral.<sup>4,8</sup> Neuroradiologic abnormalities including cerebral atrophy, white-matter lesions, intraparenchymal calcification, meningeocortical alterations, and skull atrophy have all been described in the literature.<sup>4,6,7,9,18</sup> Resolution and recur-

rence of radiologic lesions may correlate clinically with neurologic disease activity.<sup>4,9</sup> Just as imaging may be abnormal in patients without neurologic symptoms, normal imaging can be seen despite the presence of neurologic disease as demonstrated by 2 of our patients as well as the case of a patient with facial and oculomotor nerve palsy and grand mal seizures described by Gambichler et al.<sup>19</sup> The lack of specific and/or sensitive radiologic findings for the associated neurologic disease contributes to the difficulty in counseling these patients regarding prognosis. Certainly the presence of radiologic abnormalities warrants close clinical follow-up.

As in our third patient, brain biopsies have been performed when concerns for neoplasm arise.<sup>4,8</sup> The reported histologic findings are variable; most cases report a perivascular infiltrate or vasculitis. Sclerosis, fibrosis, and gliosis involving brain parenchyma, meninges, and vasculature have also been reported.<sup>8,20</sup> As in our patient and in keeping with the neuroimaging results often described in these patients, scattered calcifications can be seen, often in association with blood vessels.<sup>20</sup>

The pathogenesis of localized scleroderma is not completely understood. Most of the proposed pathogenic mechanisms relate to systemic scleroderma. Similar to systemic sclerosis, endothelial cell damage leading to increased fibroblast activity and ischemia through luminal narrowing with subsequent modification of collagen production has been proposed as the pathogenic mechanism.<sup>15,21,22</sup> The inciting event for such microvascular damage remains unknown. *Borrelia burgdorferi* infection, although implicated in Europe and Japan, has not proven to be a major factor in the United States.<sup>12</sup> Genetic factors also are thought to play a role, with higher incidence of connective tissue disease in family members. An association with preceding trauma has been found, particularly in the pediatric population.<sup>23</sup>

Linear scleroderma is usually a self-limited disease. Regression or softening of skin lesions often occurs, but complete resolution is unusual and reactivation can occur.<sup>21</sup> Spontaneous resolution of extracutaneous changes may occur, but unfortunately pediatric patients are at an increased risk of long-term morbidity because they may have decreased growth of underlying bones and may develop limb and facial asymmetry.<sup>12,16,17</sup> If cosmetic disfigurement develops, psychological disability may be pronounced.<sup>12</sup> Additional orthopedic sequelae such as flexion contractures may occur when the skin overlying joints is involved.<sup>16</sup> Reports of progression to systemic scleroderma in the pediatric population are exceedingly rare.<sup>3,12,21</sup>

Adequate treatment for linear scleroderma remains elusive. The self-limited nature of the disease coupled with mixed results obtained from small, uncontrolled trials with most therapeutic regimens makes decisions regarding treatment difficult. Topical, intralesional, and systemic corticosteroids reduce the inflammation of skin

**TABLE 1** Extracutaneous Changes Associated With Linear Scleroderma en coup de sabre and Parry-Romberg Syndrome

Neurologic	
Seizure disorder, typically complex partial <sup>3,5,8,20,27–29a</sup>	
Hemiparesis/muscle weakness <sup>4,9,17a</sup>	
Trigeminal neuralgia <sup>3a</sup>	
Intracranial aneurysm <sup>30a</sup>	
Rasmussen encephalitis <sup>31a</sup>	
Mental deterioration <sup>28a</sup>	
Subdural hygroma <sup>29a</sup>	
Peripheral facial nerve palsy <sup>19</sup>	
Oculomotor nerve palsy <sup>19</sup>	
Migraine headaches <sup>3</sup>	
Ophthalmologic	
Ptosis <sup>3,8,12,19,32a</sup>	
Exophthalmos <sup>3a</sup>	
Uveitis <sup>3,8a</sup>	
Motility disorder/atrophy of eye muscles <sup>32a</sup>	
Heterochromia of iris <sup>32,33</sup>	
Papillitis <sup>8</sup>	
Retrolbulbar pain <sup>8</sup>	
Enophthalmus <sup>34</sup>	
Displacement of outer canthus from resorption of orbital bone <sup>3</sup>	
Iridocyclitis <sup>7</sup>	
Oral	
Altered dentition <sup>3,14,29,33a</sup>	
Malocclusion <sup>3a</sup>	
Tongue atrophy <sup>3,14,33a</sup>	

<sup>a</sup> Changes reported in pediatric patients.

lesions. In an open-label study, use of topical calcipotriene in 12 patients with localized scleroderma (including linear scleroderma) led to improvement in the cutaneous lesions for all of them.<sup>24</sup> Systemic agents used when more aggressive therapy is warranted include vitamin E, vitamin D<sub>3</sub> (oral calcitriol), aminobenzoate potassium, penicillin, retinoids, diphenylhydantoin, interferon- $\gamma$ , immunosuppressive agents, and UV-A therapy.<sup>8,12,21,25</sup> Immunosuppressive agents that have been used with reported efficacy include hydroxychloroquine, D-penicillamine, methotrexate, cyclosporine, and cyclophosphamide.<sup>8,12,21,25,26</sup> For patients with disfiguring facial atrophy, reconstructive surgery may be beneficial.

In our patients, neurologic manifestations occurred before or concurrent with the diagnosis of linear scleroderma en coup de sabre. Their neurologic symptoms were previously unexplained when they presented to dermatology for evaluation of their skin lesions. These cases illustrate the need for placing craniofacial linear scleroderma on the differential of any patient with neurologic abnormalities such as partial seizures. A thorough examination of the skin should be performed in these patients, with particular attention to the face and scalp. Long and careful follow-up of these patients is prudent based on evidence that neurologic abnormalities may develop at any time during the course of the disease.

## REFERENCES

- Peterson LS, Nelson AM, Su WPD, Mason T, O'Fallon WM, Gabriel SE. Epidemiology of morphea (localized scleroderma) in Olmsted County 1960–1993. *J Rheumatol.* 1997;24:73–80
- Peterson LS, Nelson AM, Su WPD. Classification of morphea (localized scleroderma). *Mayo Clin Proc.* 1995;70:1068–1076
- Marzano AV, Menni S, Parodi A, et al. Localized scleroderma in adults and children: clinical and laboratory investigations of 239 cases. *Eur J Dermatol.* 2003;13:171–176
- Stone J, Franks AJ, Guthrie JA, Johnson MH. Scleroderma “en coup de sabre”: pathological evidence of intracerebral inflammation. *J Neurol Neurosurg Psychiatry.* 2001;70:382–385
- Flores-Alvarado DE, Esquivel-Valerio JA, Garza-Elizondo M, Espinoza LR. Linear scleroderma en coup de sabre and brain calcification: is there a pathologic relationship? *J Rheumatol.* 2003;30:193–195
- Liu P, Uziel Y, Chuang S, Silverman E, Krafchik B, Laxer R. Localized scleroderma: imaging features. *Pediatr Radiol.* 1994;24:207–209
- Appenzeller S, Montenegro MA, Dertkigil S, et al. Neuroimaging findings in scleroderma en coup de sabre. *Neurology.* 2004;62:1585–1589
- Obermoser G, Pfaulser BE, Linder DM, Sepp NT. Scleroderma en coup de sabre with central nervous system and ophthalmologic involvement: treatment of ocular symptoms with interferon gamma. *J Am Acad Dermatol.* 2003;49:543–546
- Unterberger I, Trinkla E, Engelhardt K, et al. Linear scleroderma “en coup de sabre” coexisting with plaque-morphea: neuro-radiological manifestation and response to steroids. *J Neurol Neurosurg Psychiatry.* 2003;74:661–664
- Murray KJ, Laxer RM. Scleroderma in children and adolescents. *Rheum Dis Clin North Am.* 2002;28:603–624
- Black CM. Scleroderma in children. *Adv Exp Med Biol.* 1999;455:35–48
- Hawk A, English JC 3rd. Localized and systemic scleroderma. *Semin Cutan Med Surg.* 2001;20:27–37
- Soma Y, Fujimoto M. Frontoparietal scleroderma (en coup de sabre) following Blaschko's lines. *J Am Acad Dermatol.* 1998;38:366–368
- Itin PH, Schiller P. Double-lined frontoparietal scleroderma en coup de sabre. *Dermatology.* 1999;199:185–186
- Blaszczyk M, Janniger CK, Jablonska S. Childhood scleroderma and its peculiarities. *Cutis.* 1996;58:141–152
- Tuffanelli DL. Localized scleroderma. *Semin Cutan Med Surg.* 1998;17:27–33
- Menni S, Marzano AV, Passoni EP. Neurologic abnormalities in two patients with facial hemiatrophy and sclerosis coexisting with morphea. *Pediatr Dermatol.* 1997;14:113–116
- Heron E, Hernigou A, Chatellier G, Fornes P, Emmerich J, Fiessinger J. Intracerebral calcification in systemic sclerosis. *Stroke.* 1999;30:2183–2185
- Gambichler T, Kreuter A, Hoffmann K, Bechara FG, Altmeyer P, Jansen T. Bilateral linear scleroderma “en coup de sabre” associated with facial atrophy and neurologic complications. *BMC Dermatol.* 2001;1:9
- Chung MH, Sum J, Morrell MJ, Horoupian DS. Intracerebral involvement in scleroderma “en coup de sabre”: report of a case with neurologic findings. *Ann Neurol.* 1995;37:679–681
- Eubanks LE, McBurney EI, Galen W, Reed R. Linear scleroderma in children. *Int J Dermatol.* 1996;35:330–336
- Rocken M, Ghoreschi K. Morphea and lichen sclerosus. In: Bologna JL, Jorizzo JL, Rapini RP, eds. *Dermatology.* 1st ed. St. Louis, MO: Mosby; 1997:1503–1517
- Vancheeswaran R, Black CM, David J et al. Childhood-onset scleroderma: is it different from adult-onset disease? *Arthritis Rheum.* 1996;39:1041–1049
- Cunningham BB, Landells ID, Langman C, Sailer DE, Paller AS. Topical calcipotriene for morphea/linear scleroderma. *J Am Acad Dermatol.* 1998;39:211–215
- Elst EF, van-Suijlekom-Smit LW, Oranje AP. Treatment of linear scleroderma with oral 1,25-dihydroxyvitamin D<sub>3</sub> (calcitriol) in seven children. *Pediatr Dermatol.* 1999;16:53–58
- Uziel Y, Feldman BM, Krafchik BR, Yeung RS, Laxer RM. Methotrexate and corticosteroid therapy for pediatric localized scleroderma. *J Pediatr.* 2000;136:91–95
- Yano T, Sawaishi Y, Toyono M, Takaku I, Takada G. Progressive facial hemiatrophy after epileptic seizures. *Pediatr Neurol.* 2000;23:164–166
- Grosso S, Fioravanti A, Biasi G, et al. Linear scleroderma associated with progressive brain atrophy. *Brain Dev.* 2003;25:57–61
- Sandhu K, Handa S. Subdural hygroma in a patient with Parry-Romberg syndrome. *Pediatr Dermatol.* 2004;21:48–50
- Schievink WI, Mellinger JF, Atkinson JL. Progressive intracranial aneurismal disease in a child with progressive hemifacial atrophy (Parry-Romberg disease): case report. *Neurosurgery.* 1996;38:1237–1241
- Shah JR, Juhasz C, Kupsy WJ, et al. Rasmussen encephalitis associated with Parry-Romberg syndrome. *Neurology.* 2003;61:395–397
- Suttorp-Schulten MS, Koornneef L. Linear scleroderma associated with ptosis and motility disorders. *Br J Ophthalmol.* 1990;74:694–695
- Rai R, Handa S, Gupta S, Kumar B. Bilateral en coup de sabre: a rare entity. *Pediatr Dermatol.* 2000;17:222–224
- Ramboer K, Demaerel PH, Baert AL, Casteels I, Dralands G. Linear scleroderma with orbital involvement: follow up and magnetic resonance imaging [letter]. *Br J Ophthalmol.* 1997;81:90–91

## Linear Scleroderma en coup de sabre With Associated Neurologic Abnormalities

Kristen E. Holland, Burt Steffes, James J. Nocton, Michael J. Schwabe, Richard D. Jacobson and Beth A. Drolet

*Pediatrics* 2006;117:e132

DOI: 10.1542/peds.2005-0470 originally published online December 1, 2005;

<b>Updated Information &amp; Services</b>	including high resolution figures, can be found at: <a href="http://pediatrics.aappublications.org/content/117/1/e132">http://pediatrics.aappublications.org/content/117/1/e132</a>
<b>References</b>	This article cites 33 articles, 8 of which you can access for free at: <a href="http://pediatrics.aappublications.org/content/117/1/e132#BIBL">http://pediatrics.aappublications.org/content/117/1/e132#BIBL</a>
<b>Subspecialty Collections</b>	This article, along with others on similar topics, appears in the following collection(s): <b>Neurology</b> <a href="http://www.aappublications.org/cgi/collection/neurology_sub">http://www.aappublications.org/cgi/collection/neurology_sub</a> <b>Neurologic Disorders</b> <a href="http://www.aappublications.org/cgi/collection/neurologic_disorders_sub">http://www.aappublications.org/cgi/collection/neurologic_disorders_sub</a> <b>Allergy/Immunology</b> <a href="http://www.aappublications.org/cgi/collection/allergy:immunology_sub">http://www.aappublications.org/cgi/collection/allergy:immunology_sub</a> <b>Immunologic Disorders</b> <a href="http://www.aappublications.org/cgi/collection/immunologic_disorders_sub">http://www.aappublications.org/cgi/collection/immunologic_disorders_sub</a>
<b>Permissions &amp; Licensing</b>	Information about reproducing this article in parts (figures, tables) or in its entirety can be found online at: <a href="http://www.aappublications.org/site/misc/Permissions.xhtml">http://www.aappublications.org/site/misc/Permissions.xhtml</a>
<b>Reprints</b>	Information about ordering reprints can be found online: <a href="http://www.aappublications.org/site/misc/reprints.xhtml">http://www.aappublications.org/site/misc/reprints.xhtml</a>

# American Academy of Pediatrics

DEDICATED TO THE HEALTH OF ALL CHILDREN®



# PEDIATRICS®

OFFICIAL JOURNAL OF THE AMERICAN ACADEMY OF PEDIATRICS

## **Linear Scleroderma en coup de sabre With Associated Neurologic Abnormalities**

Kristen E. Holland, Burt Steffes, James J. Nocton, Michael J. Schwabe, Richard D. Jacobson and Beth A. Drolet

*Pediatrics* 2006;117:e132

DOI: 10.1542/peds.2005-0470 originally published online December 1, 2005;

The online version of this article, along with updated information and services, is located on the World Wide Web at:

<http://pediatrics.aappublications.org/content/117/1/e132>

Pediatrics is the official journal of the American Academy of Pediatrics. A monthly publication, it has been published continuously since 1948. Pediatrics is owned, published, and trademarked by the American Academy of Pediatrics, 345 Park Avenue, Itasca, Illinois, 60143. Copyright © 2006 by the American Academy of Pediatrics. All rights reserved. Print ISSN: 1073-0397.

American Academy of Pediatrics

DEDICATED TO THE HEALTH OF ALL CHILDREN®

