

# Respiratory Failure and Hypercoagulability in a Toddler With Lemierre's Syndrome

Tal Schmid, MD\*; Hagit Miskin, MD‡; Yechiel Schlesinger, MDS; Zvi Argaman, MD\*; and David Kleid, MD\*

**ABSTRACT.** A 3.5-year-old healthy boy with 4 days of fever was referred to the emergency department for respiratory distress. The physical examination was remarkable for stupor, tachycardia, tachypnea, and dyspnea. Initial blood tests showed pancytopenia. He rapidly developed torticollis. Computerized tomography of the neck revealed a thrombus in the internal jugular vein. A presumptive diagnosis of Lemierre's syndrome was made and he was started on antibiotics and anticoagulation. He subsequently developed adult respiratory distress syndrome and required high frequency oscillatory ventilation for 9 days. Blood cultures were positive for *Fusobacterium necrophorum*. Screening for hypercoagulability revealed 2 known risk factors: a mutation in the prothrombin gene and elevated lipoprotein a. *Pediatrics* 2005;115:e620–e622. URL: [www.pediatrics.org/cgi/doi/10.1542/peds.2004-2505](http://www.pediatrics.org/cgi/doi/10.1542/peds.2004-2505); *Lemierre's syndrome, respiratory insufficiency, thrombophilia, toddlers, torticollis.*

ABBREVIATIONS. LS, Lemierre's syndrome; ED, emergency department; bpm, beats per minute; CSF, cerebrospinal fluid; WBC, white blood cell; CT, computed tomography;  $\text{FiO}_2$ , fraction of inspired oxygen.

In 1936, Lemierre described a syndrome that consisted of septicemia with an anaerobic agent (later defined as *Fusobacterium necrophorum*), thrombophlebitis of cervical veins, and distal metastatic abscesses, developed several days after an infection of the pharynx and tonsils.<sup>1</sup> Since then, several dozen case reports have been published.<sup>2–8</sup> Most reported cases are in adolescents and young adults. Only a few patients under the age of 10 years have been reported.<sup>2</sup>

We report a 3.5-year-old boy who presented with fever and torticollis and received a diagnosis of Lemierre's syndrome (LS). Screening for thrombophilia revealed two risk factors for hypercoagulability.

## CASE PRESENTATION

A 3.5-year-old healthy boy with fever up to 39°C for 4 days presented to our emergency department (ED) with fever, respiratory distress, and mental status changes. He was examined twice by pediatricians in his local clinic and received a diagnosis of

having a viral infection. On the evening before admission, he refused to move his neck. On the morning of admission, the child was in respiratory distress and was referred to our ED by his pediatrician.

On arrival in the ED, he was stuporous, rectal temperature was 39.3°C, heart rate was 145 beats per minute (bpm), blood pressure was 88/39 mm Hg, respiratory rate was 60 bpm, and oxygen saturation was 100% on 10 L/minute of oxygen delivered via a mask with reservoir. On physical examination, he had intercostal retractions and was grunting. He had mild neck rigidity, pharynx and tonsils were without erythema or exudate, a 3/6 systolic ejection murmur was heard at the left sternal border, there was good air entry bilaterally, and he had strong peripheral pulses. His liver span was 14 cm, there was a palpable spleen tip, and he had a purulent discharge from his right ear.

The child was volume resuscitated with 40 mL/kg of normal saline and treated with 100 mg/kg of Ceftriaxone after blood, urine, and cerebrospinal fluid (CSF) cultures were obtained. Blood tests revealed pancytopenia, white blood cell (WBC) count of 2300/ $\mu\text{L}$ , hemoglobin of 9.4 g/dL, and platelet count of 94 000/ $\mu\text{L}$ . Erythrocyte sedimentation rate was 110 mm in the first hour. CSF tests showed mild pleocytosis with 16 WBC/ $\mu\text{L}$ , no red blood cells, glucose of 86 mg%, and protein of <10 mg%. No bacteria were seen on Gram stain. Urine examination by dipstick was negative.

Chest radiograph revealed mild cardiac enlargement. Echocardiography demonstrated normal cardiac anatomy with a shortening fraction of 36%. He rapidly developed torticollis, and computerized tomography (CT) to rule out a parapharyngeal abscess was performed. The CT demonstrated a 12-mm thrombus in the right internal jugular vein with an adjoining inflammatory mass (Fig 1). No abscess was noted.

A presumptive diagnosis of LS was made, and intravenous Clindamycin was added to his antibiotic regimen. Anticoagulant therapy with low molecular weight heparin (1 mg/kg twice a day) was started to prevent clot progression. He remained hemodynamically stable, but his respiratory status deteriorated and he was transferred to the PICU 24 hours after hospital admission. On admission to the PICU his vital signs were as follows: temperature 38.7°C, respiratory rate 70 bpm, oxygen saturation 100% while using a nasal canula with 1 L/minute of oxygen, heart rate 130 bpm, and blood pressure 87/53 mm Hg. Chest radiograph showed pulmonary edema and a right pleural effusion. Serum albumin was 2.7 g%, and he was treated with 5% albumin and furosemide without any improvement in his respiratory status. Seventy milliliters of pleural fluid was drained and contained 120 000 red blood cells per  $\mu\text{L}$ , 16 800 WBC per  $\mu\text{L}$ , glucose of 113 mg%, protein of 2.8 g%, pH of 7.6, and lactate dehydrogenase of 660 IU/L.

His respiratory status continued to deteriorate. A trial of face mask bilevel positive airway pressure was unsuccessful, and he was endotracheally intubated and mechanically ventilated. Chest radiograph showed bilateral diffuse infiltrates compatible with adult respiratory distress syndrome. His arterial oxygen pressure/fraction of inspired oxygen ( $\text{FiO}_2$ ) ratio was 100. He remained hypoxemic despite mechanical ventilation at a rate of 35 bpm, inspiratory time of 1 second, peak inspiratory pressure of 36 cm  $\text{H}_2\text{O}$ ,  $\text{FiO}_2$  of 100%, and positive end expiratory pressure of 12 cm  $\text{H}_2\text{O}$ . He was switched to high-frequency oscillatory ventilation with initial mean airway pressure of 26 cm  $\text{H}_2\text{O}$ , amplitude of 45 cm  $\text{H}_2\text{O}$ , frequency of 5 Hz, and  $\text{FiO}_2$  of 70%. The arterial oxygen pressure/ $\text{FiO}_2$  ratio improved from 100 to 242. His blood pressure was stable, but urine output decreased, and dopamine and furo-

From the \*Pediatric Intensive Care Unit, †Pediatric Hematology Unit, and §Pediatric Infectious Diseases Unit, Shaare Zedek Medical Center, Jerusalem, Israel.

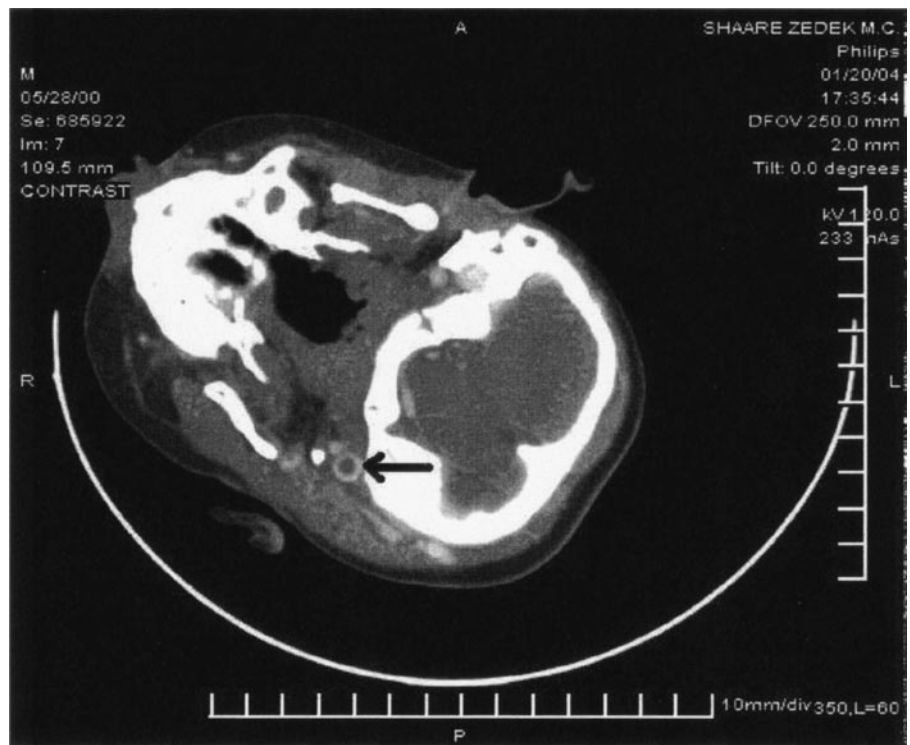
Accepted for publication Nov 29, 2004.

doi:10.1542/peds.2004-2505

No conflict of interest declared.

Reprint requests to (D.K.) Pediatric Intensive Care Unit, Shaare Zedek Medical Center, Jerusalem, Israel. E-mail: [kleid@szmc.org.il](mailto:kleid@szmc.org.il)  
PEDIATRICS (ISSN 0031 4005). Copyright © 2005 by the American Academy of Pediatrics.

**Fig 1.** CT scan of the head and neck showing a thrombus in the internal jugular vein (black arrow) and adjacent swelling of the soft tissues.



semide were started. Repeat echocardiogram was done and revealed a mildly dilated left ventricle with a shortening fraction of 27% and mild mitral and tricuspid regurgitation and a small patent ductus arteriosus.

CT scan of the neck and chest 48 hours after admission showed partial resolution of the cervical thrombus and radiologic findings consistent with adult respiratory distress syndrome. No pulmonary emboli were seen.

On his third PICU day, he showed improvement in all parameters, and the pancytopenia resolved. After 9 days of high-frequency oscillatory ventilation, he was switched back to conventional ventilation and extubated 2 days later. All medications except the antibiotics and anticoagulation were discontinued 12 days after admission. Antibiotic therapy consisted of intravenous ceftriaxone and clindamycin for 5 days, intravenous penicillin and clindamycin for an additional 7 days, and oral metronidazole for an additional 3 weeks.

The patient gradually recovered but experienced severe weakness, walked with a wide-based gait, and had alternating exotropia. He was treated with methadone and lorazepam for presumed withdrawal, and all symptoms resolved. He was discharged from the hospital after 21 days.

*F necrophorum* was isolated from 2 sets of blood cultures that were taken on admission. CSF culture was sterile. Culture from the ear discharge was positive for *Streptococcus pneumoniae* and *Haemophilus influenzae*. Serologic studies showed an elevated antistreptolysin O titer of 347 IU/mL and immunoglobulin M titers for Epstein-Barr virus and cytomegalovirus were negative.

Workup for an underlying hypercoagulability state revealed 2 known risk factors for hypercoagulability. He is a carrier of the A20210G mutation in the prothrombin gene, and he had an elevated lipoprotein apolipoprotein level of 37.7 mg/dL measured 4 months after hospital discharge. He is also a carrier of the thermolabile polymorphism (C677T) in the methyltetrahydrofolate reductase gene, but homocysteine level was normal. Activated protein c resistance ratio; factor V Leiden; protein c; protein s; antithrombin; antiphospholipid antibodies; lupus anticoagulant; and coagulation factors VIII, IX, XI, and XII were normal.

On a follow-up visit 2 months after discharge, he had a normal physical and neurologic examination. A Doppler examination of the cervical vessels 3 months after admission did not show any evidence of a thrombus in the cervical vessels.

## DISCUSSION

LS consists of postanginal bacteremia (usually with *F necrophorum*) and suppurative thrombophlebitis of the cervical veins with distal metastases.<sup>1-6</sup> LS usually occurs in adolescents and young adults and may have a fulminant course even with proper antibiotic therapy.<sup>2-5</sup> Many clinicians are not familiar enough with this syndrome and its wide range of clinical presentations.<sup>6</sup>

Some patients with *F necrophorum* bacteremia may complain of only a sore throat and have mild pharyngitis and fully recover with oral antibiotic therapy.<sup>4</sup> Others may present with a peritonsillar abscess or may be critically ill.<sup>4-8</sup> Our patient's condition deteriorated quickly, although his condition was diagnosed rapidly and he was started on appropriate antibiotic therapy.

Since the wide use of antibiotics for pharyngitis and tonsillitis, LS has become rare and was even considered a "forgotten disease."<sup>3,4</sup> Recently, an increased incidence of LS was reported in Wisconsin.<sup>4</sup>

To the best of our knowledge, this is the youngest patient reported with LS.<sup>4,6</sup> Aside from his age, there were several other unique aspects in his presentation. He presented with torticollis and stupor without a history of sore throat and had a normal-appearing pharynx. The clinical picture of septic shock and the blood film that revealed pancytopenia were consistent with overwhelming sepsis. Most reported patients with LS presented with a normal WBC count or leukocytosis and not with leukopenia.<sup>2,3,6,7</sup>

The tendency to develop thrombosis in vessels adjacent to a site of infection is well known. The high rate of clot formation in LS might be attributed to endothelial damage caused by the *Fusobacterium* or to

platelet aggregation factors that this bacterium produces.<sup>4,7-9</sup> It is not clear whether thrombus formation in LS is attributable to a transient hyperthrombotic state or is a manifestation of an underlying thrombophilia triggered by the acute infection.

The prevalence of thrombophilias in patients who develop a thrombus in association with a local infection is unknown. Of 7 pediatric patients with otitis media and sinus vein thrombosis, 5 had inherited thrombophilia.<sup>10</sup> There are no prospective studies on the prevalence of thrombophilia in LS patients. Our patient has at least 2 risk factors for hypercoagulability, the mutation in the prothrombin gene, and the elevated levels of lipoprotein apolipoprotein.<sup>10</sup> The combination of host factors combined with the specific infection with *F necrophorum* may increase the risk for LS in certain people.

The role of anticoagulation in LS is still controversial.<sup>2,4,7,9</sup> Some authors recommend anticoagulation therapy during the acute phase of LS to prevent clot progression and to decrease the risk for septic pulmonary emboli.<sup>2,4</sup> Others are concerned of the risk for hemorrhage and extension of the infection.<sup>9</sup> Most reported patients were started on anticoagulation and maintained on it for several weeks, even when there were signs of clot resolution.<sup>2-4</sup>

### CONCLUSIONS

LS should be considered in toddlers, and it should be included in the differential diagnosis of acute torticollis in a febrile child. LS is not a common disease, but in recent years, there is evidence that it

may be increasing in frequency.<sup>2,4,5</sup> LS may have a prolonged course and even a fatal outcome.<sup>1-6</sup> Patients may deteriorate quickly even with rapid diagnosis and proper therapy and therefore should be monitored closely. Studies should be conducted to evaluate the prevalence of hereditary thrombophilias in patients with LS, the need for and length of anticoagulation, and the relative risk of these patients for thrombus progression and for developing a thrombus in the future.

### REFERENCES

1. Lemierre A. On certain septicemias due to anaerobic organisms. *Lancet*. 1936;1:701-703
2. Venglaric J. Lemierre's syndrome. *Pediatr Infect Dis*. 2003;22:921-923
3. Screamon NJ, Ravenel JG, Lehner PJ, et al. Lemierre syndrome: forgotten but not extinct—report of four cases. *Radiology*. 1999;213:369-374
4. Ramirez S, Hild TG, Rudolph CN, et al. Increased diagnosis of Lemierre syndrome and other *Fusobacterium necrophorum* infections at a children's hospital. *Pediatrics*. 2003;112(5). Available at: [www.pediatrics.org/cgi/content/full/112/5/e380](http://www.pediatrics.org/cgi/content/full/112/5/e380)
5. Briggs S, Pappachan J, Argent J, et al. Lemierre syndrome in the pediatric intensive care unit, clinical course and the use of high-frequency oscillatory ventilation. *Pediatr Crit Care Med*. 2003;4:107-110
6. Alvarez A, Schreiber JR. Lemierre's syndrome in adolescent children—anaerobic sepsis with internal jugular vein thrombophlebitis following pharyngitis. *Pediatrics*. 1995;96:354-359
7. Hoehn S, Dominguez TE. Lemierre's syndrome: an unusual cause of sepsis and abdominal pain. *Crit Care Med*. 2002;30:1644-1647
8. Jaremko JL, Kirton A, Brenner JL. A 12-year-old girl with pharyngitis, meningitis and sinovenous thrombosis. *CMAJ*. 2003;169:811-812
9. Hagelskajer KL, Prag J. Human necrobacillosis, with emphasis on Lemierre's syndrome. *Clin Infect Dis*. 2000;31:524-532
10. Oestreicher-Kedem Y, Raveh E, Kornreich L, Tamary H. Prothrombotic factors in children with otitis media and sinus thrombosis. *Laryngoscope*. 2004;114:90-95

## Respiratory Failure and Hypercoagulability in a Toddler With Lemierre's Syndrome

Tal Schmid, Hagit Miskin, Yecheil Schlesinger, Zvi Argaman and David Kleid  
*Pediatrics* 2005;115:e620

DOI: 10.1542/peds.2004-2505 originally published online April 15, 2005;

### Updated Information & Services

including high resolution figures, can be found at:  
<http://pediatrics.aappublications.org/content/115/5/e620>

### References

This article cites 9 articles, 2 of which you can access for free at:  
<http://pediatrics.aappublications.org/content/115/5/e620#BIBL>

### Subspecialty Collections

This article, along with others on similar topics, appears in the following collection(s):  
**Hematology/Oncology**  
[http://www.aappublications.org/cgi/collection/hematology:oncology\\_sub](http://www.aappublications.org/cgi/collection/hematology:oncology_sub)  
**Respiratory Tract**  
[http://www.aappublications.org/cgi/collection/respiratory\\_tract\\_sub](http://www.aappublications.org/cgi/collection/respiratory_tract_sub)

### Permissions & Licensing

Information about reproducing this article in parts (figures, tables) or in its entirety can be found online at:  
<http://www.aappublications.org/site/misc/Permissions.xhtml>

### Reprints

Information about ordering reprints can be found online:  
<http://www.aappublications.org/site/misc/reprints.xhtml>

American Academy of Pediatrics

DEDICATED TO THE HEALTH OF ALL CHILDREN™



# PEDIATRICS®

OFFICIAL JOURNAL OF THE AMERICAN ACADEMY OF PEDIATRICS

## **Respiratory Failure and Hypercoagulability in a Toddler With Lemierre's Syndrome**

Tal Schmid, Hagit Miskin, Yechiel Schlesinger, Zvi Argaman and David Kleid  
*Pediatrics* 2005;115:e620

DOI: 10.1542/peds.2004-2505 originally published online April 15, 2005;

The online version of this article, along with updated information and services, is located on the World Wide Web at:

<http://pediatrics.aappublications.org/content/115/5/e620>

Pediatrics is the official journal of the American Academy of Pediatrics. A monthly publication, it has been published continuously since 1948. Pediatrics is owned, published, and trademarked by the American Academy of Pediatrics, 141 Northwest Point Boulevard, Elk Grove Village, Illinois, 60007. Copyright © 2005 by the American Academy of Pediatrics. All rights reserved. Print ISSN: 1073-0397.

American Academy of Pediatrics

DEDICATED TO THE HEALTH OF ALL CHILDREN™

