

Group A Streptococcal Subdural Empyema as a Complication of Varicella

Rolando Ulloa-Gutierrez, MD; Simon Dobson, MD, FRCPC; and John Forbes, MBChB, FRCPC

ABSTRACT. Group A β -hemolytic streptococcus and *Staphylococcus aureus* are the 2 most common pathogens implicated in secondary invasive bacterial disease after varicella. We describe a 3-month-old male infant from British Columbia, Canada, who presented on day 5 of varicella skin rash with fever, seizures, lethargy, and evidence of intracranial hypertension. A prominent subdural empyema was documented, and *Streptococcus pyogenes* was recovered from the subdural fluid. Central nervous system bacterial complications should be part of the differential diagnosis for infants and children with chickenpox who present with fever, lethargy, focal seizures, or similar neurologic findings. This case illustrates the importance of universal varicella vaccination to prevent associated bacterial complications of chickenpox. *Pediatrics* 2005;115:e112–e114. URL: www.pediatrics.org/cgi/doi/10.1542/peds.2004-1336; *Streptococcus pyogenes*, *invasive disease*, *meningitis*, *subdural empyema*, *varicella*, *varicella vaccine*, *bacterial complications*.

ABBREVIATIONS. GAS, group A streptococcus; CNS, central nervous system; AOM, acute otitis media; BCCH, British Columbia's Children's Hospital; VZV, varicella zoster virus; CSF, cerebrospinal fluid.

The clinical course of varicella in childhood is usually benign and self-limited. However, secondary bacterial complications can occur in skin, soft tissues, and other sites, caused predominantly by group A streptococcus (GAS) and *Staphylococcus aureus*.¹ For varicella-associated, invasive, suppurative complications, the former is associated with increased morbidity and mortality rates among both immunocompetent and immunosuppressed children, and episodes can occur even without an obvious skin source of infection. Among children, GAS infections of the central nervous system (CNS) and peripheral nervous system after chickenpox are extremely rare.^{2–4} We describe an infant who developed a GAS subdural empyema during varicella, which is, to our knowledge, an association not described previously.

From the Pediatric Infectious Diseases Division, Department of Pediatrics, British Columbia's Children's Hospital, and the University of British Columbia, Vancouver, British Columbia, Canada.

Accepted for publication Aug 4, 2004.

doi:10.1542/peds.2004-1336

No conflict of interest declared.

Address correspondence to Rolando Ulloa-Gutierrez, MD, Pediatric Infectious Diseases Division, British Columbia's Children's Hospital, 4480 Oak St, Room K4-166, Vancouver, British Columbia, Canada V6H3V4. E-mail: rgut@cw.bc.ca

PEDIATRICS (ISSN 0031 4005). Copyright © 2005 by the American Academy of Pediatrics.

CASE REPORT

A 3-month-old boy was admitted to a community hospital, on day 5 of a varicella skin rash, with fever and focal seizures. On day 1 of the rash, the patient developed decreased appetite and vomited twice; the following day, he began to exhibit a fever of 39°C. On day 4, he was examined at a primary care clinic, a diagnosis of acute otitis media (AOM) was made, and treatment with orally administered trimethoprim-sulfamethoxazole was initiated (the patient received a total of 2 doses). On day 5, the patient was described by his parents as being irritable and lethargic, and that night he developed right-sided focal seizures of the face, arm and leg, with subsequent ocular deviation. The seizures persisted, became generalized, and led to status epilepticus, which necessitated repeat doses of intravenously administered diazepam and phenytoin after admission to the local hospital. The body temperature was 37.8°C, a diffuse varicella skin rash with no evidence of secondary bacterial infection was described, and no AOM was observed. The patient underwent head computed tomography, which showed bilateral subdural fluid collections with left-sided predominance, with a compressed ventricular system and mild midline deviation. A clinical diagnosis of varicella encephalitis and subdural effusions was made, blood cultures were obtained, 1 dose of acyclovir was administered intravenously, and the patient was transferred to British Columbia's Children's Hospital (BCCH).

The family history was remarkable only for paternal psoriasis. The pregnancy was normal, the patient was born at term, the birth weight was 3760 g, and the neonatal medical history was unremarkable except for the child not being breastfed and having intermittent eczema since the first month of life, which was treated with topically administered hydrocortisone occasionally but not during the week preceding admission. The patient had received 1 dose of diphtheria-tetanus-acellular pertussis-*Haemophilus influenzae* type b-inactivated polio virus vaccine and 1 dose of hepatitis B vaccine at 2 months of age. His 5-year-old sibling, who had not been immunized against varicella, had developed uncomplicated varicella 2 weeks earlier and his mother had experienced chickenpox as an adolescent.

At the time of admission to BCCH, the patient's heart rate was 128 beats per minute, the respiratory rate was 28 breaths per minute, the temperature was 37.8°C, and the head circumference was 43.3 cm (95th percentile). In the examination, the patient was in stable hemodynamic condition, had a diffuse varicella rash (with most lesions crusted but no evidence of secondary bacterial infection), had diaper dermatitis, and exhibited no evidence of AOM. He was irritable during handling, was hyperreflexic, had a bulging fontanelle, and was still under the sedative effects of anticonvulsants. Blood cultures were repeated, intravenous acyclovir (60 mg/kg per day) and phenytoin therapy was continued, and treatment with cefotaxime (300 mg/kg per day) and vancomycin (60 mg/kg per day) was initiated for a presumed CNS infection while additional investigation results were awaited. An eye fundus examination performed by the ophthalmologist revealed bilateral papilledema with right-sided predominance, dilated veins, no spontaneous venous pulsation, and no evidence of retinitis or hemorrhage. The patient was examined initially by the neurosurgeons, who suggested repeat brain imaging in 2 days but saw no need for transfontanelar aspiration or surgical drainage at the time of admission.

Investigations revealed normal serum electrolyte, urea nitrogen, and creatinine levels and coagulation times. The hemoglobin concentration was 10.1 g/dL, the platelet count was 325 000 platelets per mm³, and the leukocyte count was 9010 leukocytes per mm³. A lumbar puncture was not performed because the patient

had lumbar varicella skin lesions and evidence of intracranial hypertension. An electroencephalogram showed epileptic activity and was consistent with an infectious or postinfectious process. Contrast-enhanced magnetic resonance imaging of the head performed on day 2 after admission showed bilateral subdural effusions with left-sided predominance and a mass effect, pial enhancement along the surface of the left cerebral hemisphere, and the presence of protein or debris, all consistent with a subdural empyema (Fig 1). Results of a chest radiograph were normal. An infectious disease consultation prompted a repeat neurosurgical evaluation. Consequently, a transfontanelar tap was performed 72 hours after admission, which yielded 55 mL of purulent subdural fluid with 275 000 leukocytes per mm³ (100% neutrophils), 400 erythrocytes per mm³, a protein concentration of >3 g/dL, and a glucose concentration of <19 mg/dL. Staining showed Gram-positive cocci in chains. Bacterial antigen testing could not be performed because the subdural fluid sample clotted. *Streptococcus pyogenes* was recovered 20 hours later from the subdural fluid and was susceptible to penicillin, erythromycin, clindamycin, cefotaxime, and vancomycin. Acyclovir treatment was discontinued and antibiotic treatment was changed to intravenously administered penicillin G (250 000 U/kg per day). Repeat blood cultures obtained at the time of admission to BCCH, as well as those from the community hospital, were sterile. Additional typing of the *S pyogenes* isolate, which was performed at the National Centre for Streptococcus (Edmonton, Alberta, Canada), revealed that the isolate corresponded to a M-nontypeable, T28, R28, AOF28, SOF-positive strain. Repeat subdural taps performed 3 and 5 days after the first analysis showed 34 400 and 40 000 leukocytes per mm³, respectively, with Gram-positive cocci still being visible in both samples but cultures being sterile. Serologic testing for varicella zoster virus (VZV) revealed immunoglobulin G negativity and immunoglobulin M positivity. Serum immunoglobulin values were within normal ranges.

The patient exhibited clinical improvement but at the end of week 2 at BCCH he developed right-sided hemiparesis and new focal seizures. Repeat head computed tomographic scans revealed loculation and increased size of the left subdural collection. A

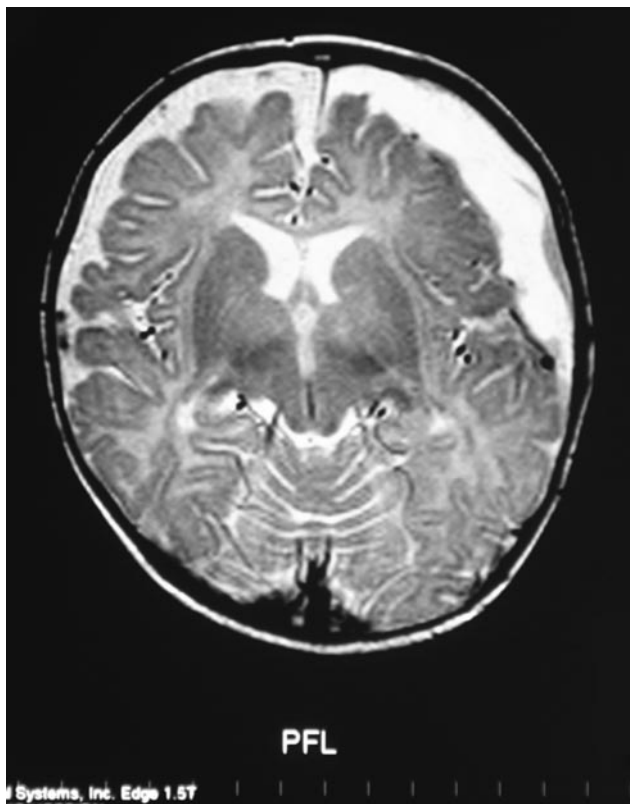


Fig 1. Contrast-enhanced head magnetic resonance imaging scan, showing evidence of bilateral subdural collections with left-sided predominance and mild midline deviation. No brain or epidural abscesses were found.

craniotomy was performed, and inflamed meninges of 3- to 4-mm thickness were found after opening of the dura. A subdural empyema was drained, and an external ventricular drain was inserted into the subdural cavity. Cerebrospinal fluid (CSF) smears and cultures yielded negative results, the external ventricular drain was removed after 3 days, and repeat computed tomographic scans showed progressive resolution of the subdural collections. The patient received, through intravenous administration, a total of 10 days of cefotaxime, 7 days of vancomycin, and 4 weeks of penicillin G after the first sterile subdural fluid culture. He exhibited normal findings in an audiologic evaluation and was discharged from the hospital with right hemiparesis. In follow-up assessments, mild fine-motor developmental delay has been noted and the hemiparesis has resolved. The patient receives oral clobazam treatment and has remained free of seizures.

DISCUSSION

Although uncommon, neurologic complications of varicella include postinfectious cerebellar ataxia, meningoencephalitis, Reye syndrome, myelitis, optic neuritis, stroke, Guillain-Barré syndrome, seventh cranial nerve palsy, and Ramsay-Hunt syndrome. Suppurative bacterial infections of the nervous system are extremely rare. Bacterial meningitis and subgaleal and brain abscesses have been observed after varicella among older children,⁵⁻⁷ but only 3 pediatric case reports of VZV-associated GAS meningitis were published previously.⁸⁻¹⁰ We found 2 additional cases in a series of invasive GAS disease cases among children with varicella reported by Vugia et al.¹¹ In that report, the authors mentioned 2 children who died at home on day 6 and 4 of varicella and for whom GAS was recovered from postmortem CSF and brain cultures. We reviewed the English-language literature for the postantibiotic era and found no previous case reports of infants with GAS subdural empyema as a complication of varicella.

Despite being one of the most common bacterial pathogens in childhood, GAS is a rare cause of bacterial meningitis and associated intracranial suppurative complications among previously healthy infants and children.¹² Among older children and adults, most episodes of GAS meningitis occur as a result of direct spread from a contiguous site of infection (eg, AOM, otomastoiditis, or sinusitis). Two recent reviews of the literature^{2,3} that addressed confirmed cases of GAS meningitis among children and adults in the past 3 decades found only 2 children with brain abscesses, 2 children with subdural hygromas (1 of whom required surgical drainage and shunt insertion),¹³ and none with a subdural empyema. Subsequent cases of pediatric GAS meningitis with a subdural hygroma¹⁴ and an empyema¹⁵ have been reported. However, none of these children experienced varicella before the episode of GAS meningitis.

For this infant, a CSF sample could not be obtained through lumbar puncture; a sample could be obtained only through a subdural tap. Therefore, we could not confirm strictly the origin of the subdural empyema. However, it is more logical to conclude that the empyema developed as a complication of GAS meningitis. Less commonly, the former can be hematogenous in origin, including cases among children with preexisting subdural effusions or hematomas that become secondarily infected. We could not

prove these factors for our patient, however. Although blood cultures were sterile, bacteremia might have acted as a primary route for CNS seeding. Interestingly, in 2 of the 3 previously reported cases of VZV-associated GAS meningitis, blood culture results were also negative (refs 9 and 10; R. Kitz, personal communication, 2004). For the 2 cases reported by Vugia et al,¹¹ no premortem or postmortem blood culture results were available. Papilloedema is an uncommon finding among children with acute uncomplicated meningitis¹² and, when it is detected, other causes should also be considered, including venous sinus thrombosis, subdural or epidural empyema, and brain abscess. We found no evidence of a brain abscess, an epidural empyema, or venous sinus thrombosis for our patient.

The portal of entry remains undetermined for one fourth of invasive GAS disease episodes.¹⁶ For this infant, however, the skin with varicella lesions was most likely the portal of entry for GAS. Atopic dermatitis and previous topical corticosteroid treatment might have contributed to skin colonization with GAS. The household members had experienced no recent GAS respiratory or skin diseases. The presumed diagnosis of AOM could not be proven for this infant, and he had experienced no previous head trauma, scalp injuries, CSF leaks, or neurosurgical procedures, all of which are considered risk factors for GAS meningitis.^{2,3} In addition, he had undergone no previous treatment with nonsteroidal antiinflammatory drugs. Although VZV-associated transient alterations in immune function might have occurred, this possibility was not demonstrated.

Contraindications to lumbar puncture for this infant might have contributed to a delay in diagnosis. Although controversial, repeat subdural taps and broad-spectrum antibiotic treatment represent one of the therapeutic approaches for infants with subdural empyemas who are not candidates for surgical drainage.¹⁷ Infants or children with varicella skin lesions for whom a lumbar puncture or transfontanelar tap is contraindicated or cannot be performed may be at risk for a delayed diagnosis of CNS suppurative complications. If not contraindicated, CSF analysis is desirable for patients who present with characteristics similar to those of this infant, to rule out bacterial complications.

Infants represent a vulnerable risk group for acquiring chickenpox and developing invasive GAS complications, particularly during the first 2 weeks of the disease.^{18,19} The risk is increased if household contacts are not immune to VZV, and varicella tends to be more severe in secondary family cases.²⁰ The age of occurrence of chickenpox for this infant might have coincided with a decrease in the levels of transplacentally acquired VZV-specific immunoglobulin G antibodies. Finally, as recently shown by Patel et al,²¹ the proportion of hospitalizations for treatment of invasive GAS infections associated with varicella decreases significantly with vaccination.

CONCLUSIONS

Varicella is a significant risk factor for invasive GAS disease among children. Although primary

postinfectious cerebellar ataxia and viral encephalitis are the 2 most common neurologic complications of varicella, secondary GAS infections of the CNS should be considered for infants and children with chickenpox who present with fever, signs of meningeal irritation, and neurologic findings such as focal seizures, lethargy, or CNS status deterioration. Brain imaging studies may be useful in the search for focal suppurative complications, as noted for this infant. Varicella immunization of the sibling might have prevented this bacterial complication in this case.

REFERENCES

- Aebi C, Ahmed A, Ramilo O. Bacterial complications of primary varicella in children. *Clin Infect Dis*. 1996;23:698-705
- Baraldés MA, Domingo P, Mauri A, et al. Group A streptococcal meningitis in the antibiotic era. *Eur J Clin Microbiol Infect Dis*. 1999;18:572-578
- Shetty AK, Frankel LR, Maldonado Y, Falco DA, Lewis DB. Group A streptococcal meningitis: report of a case and review of literature since 1976. *Pediatr Emerg Care*. 2001;17:430-434
- Quach C, Tapiero B, Noya F. Group A streptococcus spinal epidural abscess during varicella. *Pediatrics*. 2002;109(1). Available at: www.pediatrics.org/cgi/content/full/109/1/e14
- Singer J. Postvaricella suppurative meningitis: case reports and review of the literature. *Am J Dis Child*. 1979;133:934-935
- Mazzulli T, Kellner J, Humphreys RP, Ford-Jones EL. Cerebellar abscess mimicking acute varicella-associated cerebellar ataxia. *Pediatr Infect Dis J*. 1991;10:413-414
- Wiley JF II, Sugarman JM, Bell LM. Subgaleal abscess: an unusual presentation. *Ann Emerg Med*. 1989;18:785-787
- Gradon JD, Chapnick EK, Lutwick LI, Tepperberg J, Kahn M. Group A streptococcal meningitis complicating varicella. *Pediatr Infect Dis J*. 1991;10:786-787
- Walsh M, Chodock R, Quinn C, Peglow S. Group A β -hemolytic streptococcal meningitis associated with uncomplicated varicella. *Am J Emerg Med*. 1994;12:602-603
- Brandt CM, Kitz R, Luticken R, Brade V. *Streptococcus pyogenes* meningitis complicating varicella in a 3-month-old child. *Scand J Infect Dis*. 2003;35:876-878
- Vugia DJ, Peterson CL, Meyers HB, et al. Invasive group A streptococcal infections in children with varicella in southern California. *Pediatr Infect Dis J*. 1996;15:146-150
- Feigin RD, Pearlman E. Bacterial meningitis beyond the neonatal period. In: Feigin RD, Cherry JD, Demmler GJ, Kaplan SL, eds. *Textbook of Pediatric Infectious Diseases*. 5th ed. Philadelphia, PA: WB Saunders; 2004:443-474
- Burech DL, Koranyi KI, Haynes RE. Serious group A streptococcal diseases in children. *J Pediatr*. 1976;88:972-974
- Steppberger K, Adams I, Deutscher J, Müller H, Kiess W. Meningitis in a girl with recurrent otitis media caused by *Streptococcus pyogenes*: otitis media has to be treated appropriately. *Infection*. 2001;29:286-288
- Melzer M, Joashi U, Murdoch I, Grandsen W. Group A streptococcal meningitis with an infected BCG scar. *J R Soc Med*. 2000;93:641
- American Academy of Pediatrics, Committee on Infectious Diseases. Severe invasive group A streptococcal infections: a subject review. *Pediatrics*. 1998;101:136-140
- Cochrane DD, Dobson SR, Steinbok P. Intracranial suppuration: epidural abscess, subdural empyema, and brain abscess. In: McLone DG, ed. *Pediatric Neurosurgery: Surgery of the Developing Nervous System*. 4th ed. Philadelphia, PA: WB Saunders; 2001:973-989
- Laupland KB, Davies HD, Low DE, et al. Invasive group A streptococcal disease in children and association with varicella-zoster virus infection. *Pediatrics*. 2000;105(5). Available at: www.pediatrics.org/cgi/content/full/105/5/e60
- Law B, MacDonald N, Halperin S, et al. The Immunization Monitoring Program Active (IMPACT) prospective five year study of Canadian children hospitalized for chickenpox or an associated complication. *Pediatr Infect Dis J*. 2000;19:1053-1059
- Ross AH. Modification of chicken pox in family contacts by administration of gamma globulin. *N Engl J Med*. 1962;267:369-376
- Patel RA, Binns HJ, Shulman ST. Reduction in pediatric hospitalizations for varicella-related invasive group A streptococcal infections in the varicella vaccine era. *J Pediatr*. 2004;144:68-74

Group A Streptococcal Subdural Empyema as a Complication of Varicella

Rolando Ulloa-Gutierrez, Simon Dobson and John Forbes

Pediatrics 2005;115;e112

DOI: 10.1542/peds.2004-1336

Updated Information & Services

including high resolution figures, can be found at:
<http://pediatrics.aappublications.org/content/115/1/e112>

References

This article cites 17 articles, 1 of which you can access for free at:
<http://pediatrics.aappublications.org/content/115/1/e112#BIBL>

Subspecialty Collections

This article, along with others on similar topics, appears in the following collection(s):
Infectious Disease
http://www.aappublications.org/cgi/collection/infectious_diseases_sub
Vaccine/Immunization
http://www.aappublications.org/cgi/collection/vaccine:immunization_sub

Permissions & Licensing

Information about reproducing this article in parts (figures, tables) or in its entirety can be found online at:
<http://www.aappublications.org/site/misc/Permissions.xhtml>

Reprints

Information about ordering reprints can be found online:
<http://www.aappublications.org/site/misc/reprints.xhtml>

American Academy of Pediatrics

DEDICATED TO THE HEALTH OF ALL CHILDREN®



PEDIATRICS®

OFFICIAL JOURNAL OF THE AMERICAN ACADEMY OF PEDIATRICS

Group A Streptococcal Subdural Empyema as a Complication of Varicella

Rolando Ulloa-Gutierrez, Simon Dobson and John Forbes

Pediatrics 2005;115:e112

DOI: 10.1542/peds.2004-1336

The online version of this article, along with updated information and services, is located on the World Wide Web at:

<http://pediatrics.aappublications.org/content/115/1/e112>

Pediatrics is the official journal of the American Academy of Pediatrics. A monthly publication, it has been published continuously since 1948. Pediatrics is owned, published, and trademarked by the American Academy of Pediatrics, 345 Park Avenue, Itasca, Illinois, 60143. Copyright © 2005 by the American Academy of Pediatrics. All rights reserved. Print ISSN: 1073-0397.

American Academy of Pediatrics

DEDICATED TO THE HEALTH OF ALL CHILDREN®

