

Prevalence of Scalp Scaling in Prepubertal Children

Judith V. Williams, MD*; Lawrence F. Eichenfield, MD‡; Bonnie L. Burke, MSS§; Myra Barnes-Eley, MPH§; and Sheila F. Friedlander, MD‡

ABSTRACT. *Objective.* To determine the prevalence and most common etiologies of scalp scaling in infants and prepubertal children and the specificity of head and neck lymphadenopathy for the diagnosis of tinea capitis associated with scalp scaling.

Design/Methods. A cross-sectional study of 300 children, 200 from an urban general pediatric practice and 100 from 2 urban pediatric dermatology practices, was conducted. Half of the subjects were <2 years old, and half were 2 to 10 years old. Demographic data, medical history, and clinical data noting the presence of scalp scaling and other scalp signs and symptoms, as well as adenopathy of the head and neck, were collected.

Results. Scalp scaling was seen in 66 (22%) children. There was an insignificantly higher prevalence of scalp scaling in those <2 years old compared with the 2- to 10-year-old group. In those <2 years old with scalp scaling, the most common diagnoses were seborrheic dermatitis (thick, adherent, greasy scale predominantly in the frontal and/or vertex areas of the scalp) and atopic dermatitis/eczema. Among those 2 to 10 years old with scalp scaling, the most common diagnoses were nonspecific (fine, white) scaling, seborrheic dermatitis, and atopic dermatitis/eczema. Nine (3%) patients were culture-positive for a dermatophyte, all of whom were black, and grew *Trichophyton tonsurans*. More than half (52.7%) of all patients had head and neck adenopathy. The presence of posterior nodes was significantly associated with atopic dermatitis/eczema and marginally associated with a positive dermatophyte culture. The presence of scalp scaling plus posterior adenopathy was significantly associated with seborrheic dermatitis and a positive dermatophyte culture in the entire study population and with atopic dermatitis in the pediatric dermatology clinics.

Conclusions. Scalp scaling was common in children 0 to 10 years old. Infantile-type seborrheic dermatitis was noted in both age groups: it was 3 times as likely in children <2 years old (18%) than in those 2 to 10 years old (6%). Contrary to traditional teaching, seborrheic dermatitis can be found in preadolescent children. Atopic dermatitis/eczema was associated with scalp scaling in both

age groups. Head and neck adenopathy was very common and nonspecific for any 1 diagnosis. Posterior adenopathy with concurrent scalp scaling was significantly associated with seborrheic dermatitis, a positive dermatophyte culture, and atopic dermatitis. In this nonselected pediatric population, scalp scaling with adenopathy was not associated exclusively with tinea capitis. *Pediatrics* 2005;115:e1–e6. URL: www.pediatrics.org/cgi/doi/10.1542/peds.2004-1616; scalp scaling, seborrheic dermatitis, atopic dermatitis, tinea capitis.

Scalp scaling is a common finding in infants and children that may be associated with a variety of disorders. Seborrheic dermatitis usually occurs between the first 2 to 6 weeks of life, but it occasionally presents as late as 5 months and often recurs during or after puberty. Traditional teaching in both pediatrics and dermatology has been that seborrheic dermatitis rarely occurs in the period between infancy and puberty.

It has been reported that approximately half of all children with atopic dermatitis may manifest scaling of the scalp, as found in studies of infants 0 to 6 months old¹ and in children from birth to 12 years.² Despite this, most texts do not list scalp scaling as a manifestation of atopic dermatitis, and many physicians are unaware of this finding.

Scalp scaling is noted frequently in tinea capitis as well as psoriasis. Occasionally scalp scaling can be seen in patients with scabies,^{3,4} dermatomyositis,⁵ and Langerhans cell histiocytosis.⁶ Less common etiologies for scalp scaling include pityriasis rubra pilaris,⁷ pemphigus foliaceus,⁸ and leukemia cutis.⁹

A recent study of children 7 months to 11 years old, 98% of whom were black and had at least 1 sign or symptom related to the scalp, found the presence of scalp scaling plus head and neck adenopathy to be 97% predictive of tinea capitis, whereas alopecia plus adenopathy was found to be 100% predictive.¹⁰

Few studies have documented the prevalence and etiologies of scalp scaling in children. Allen and Honig¹¹ evaluated scalp-scaling disorders in children in 1983, noting clinical signs and response to various treatments. No subsequent large-scale studies of childhood scalp scaling have been done. This study sought to identify the prevalence of scalp scaling and its associated symptoms, signs, and etiologies in both the infantile and early school-age population. We also sought to determine if the presence of head and/or neck lymphadenopathy in those patients with scalp scaling was specific for the diagnosis of tinea capitis.

From the *Departments of Pediatrics and Dermatology, Division of Dermatology, Children's Specialty Group, Children's Hospital of The King's Daughters, Eastern Virginia Medical School, Norfolk, Virginia; ‡Pediatric and Adolescent Dermatology, Children's Hospital and Health Center and the University of California, San Diego, California; and §Clinical Outcomes Research and Epidemiology Department, Children's Hospital of The King's Daughters, Norfolk, Virginia.

Accepted for publication Sep 13, 2004.

doi:10.1542/peds.2004-1616

No conflict of interest declared.

Address correspondence to Judith V. Williams, MD, Division of Dermatology, Children's Specialty Group, Children's Hospital of The King's Daughters, 601 Children's Lane, Norfolk, VA 23507. E-mail: williajv@chkd.org
PEDIATRICS (ISSN 0031 4005). Copyright © 2005 by the American Academy of Pediatrics.

METHODS

A cross-sectional study of 300 children <11 years old was approved by the Children's Hospital (San Diego, CA) Institutional Review Board. Informed consent was obtained from participating parents/guardians, and informed assent was gained from children when they were age appropriate. Two hundred subjects were enrolled from a general pediatric practice at Children's Hospital and Health Center (San Diego, CA), and a total of 100 subjects were enrolled from 2 pediatric dermatology practices, 1 at Children's Hospital and Health Center and the other at Eastern Virginia Medical School (Norfolk, VA). Subjects with a known immunodeficiency, those who had used a topical scalp medication or medicated shampoo within the previous 2 weeks, or those who had taken an oral antifungal or oral corticosteroid within the previous month were excluded. All subjects were evaluated by 1 of 2 investigators.

A history was obtained from the parent/guardian that included demographics such as patient age, gender, and ethnicity; prior and current dermatologic diagnoses (tinea capitis, folliculitis, seborrheic dermatitis, eczema, atopic dermatitis, psoriasis, traction alopecia, alopecia areata, other, undetermined, or none); prior scalp signs and symptoms (scaling, crusting, pustules, alopecia, pruritus, or none); and current scalp symptoms. The presence of a diagnosis for use in the analysis was determined by both historical data provided by the parents and the impression of the provider at the time the patient was seen.

All patients were examined for current scalp signs and the presence or absence of palpable nodes in the head and neck location. Location of adenopathy (posterior, anterior, or both) was noted. Scaling that was thick or greasy, adherent to the scalp, and located predominantly in the frontal and/or vertex areas was defined as infantile-type seborrheic dermatitis (Fig 1). Nonspecific scalp scaling was defined as localized or generalized fine, white, nonadherent, nongreasy scale (Fig 2).

All scalps were cultured by using a cotton-tipped swab moistened with tap water and plated on Mycosel agar (BBL Mycosel, Becton, Dickinson, and Co, Franklin Lakes, NJ). This method has been investigated previously and is both sensitive and specific for the diagnosis of dermatophyte infections of the scalp.¹² Plates were numbered and incubated at room temperature for 2 weeks. All plates were read by 1 blinded investigator, who assessed the presence of dermatophytes by colony morphology.

Statistics

Demographic characteristics between clinic groups were assessed. Where demographic profiles were significantly different, analysis was stratified.

Continuous variables were tested for normality by using the Shapiro-Wilk test. Differences between clinic-group means among normally distributed variables were tested by using analysis of variance. Differences between clinic-group distributions among nonnormally distributed variables were tested by using the Wilcoxon rank sum test.

Categorical variables were tabulated and proportions were

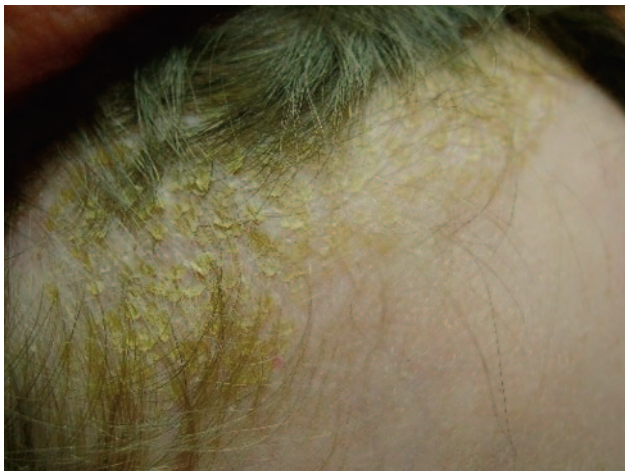

Fig 1. Infantile-type greasy-scalp scale.

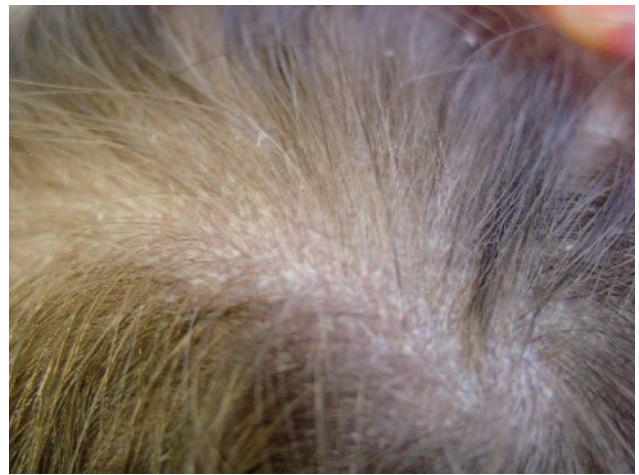

Fig 2. Nonspecific fine, white scale.

compared between age groups, gender groups, and clinic groups by using χ^2 tests or Fisher's exact tests as appropriate. Data were entered into an Access (Microsoft, Redmond, WA) database, and all analysis was conducted by using SAS software, version 8.1 (SAS Institute, Cary, NC).

RESULTS

Table 1 summarizes results comparing demographic profiles between clinic groups. Half (150) of the patients were <2 years old, and half (150) were between 2 and 10 years old. No difference was noted in age, ethnic, or gender distributions between clinics.

Current scalp scaling was found in 66 (22%) of the 300 children in the study (Fig 3). No statistically significant difference was found in the prevalence of scalp scaling between children <2 years old (25.3%) and those 2 to 10 years old (18.7%) nor between males (19.6%) and females (24.3%). Of all subjects presenting to the general pediatric practice, 14% had current scalp scaling, whereas 38% of children in the pediatric dermatology clinics had current scaling of the scalp.

Seborrheic dermatitis, defined as thick or greasy scalp scaling predominantly at the frontal or vertex areas of the scalp, was present in 12% of the overall population and in more than half of those with current scalp scaling and thus was the most common etiology for scalp scaling (Fig 4). Atopic dermatitis/eczema was present in one third of all those with current scalp scaling, and atopic dermatitis, specifically, was present in 42.1% from the pediatric dermatology group. No children with psoriasis were identified during the study.

Seborrheic dermatitis and atopic dermatitis/eczema were the most common diagnoses among children <2 years old with current scalp scaling, compared with an undetermined etiology, seborrheic dermatitis, and atopic dermatitis in the 2- to 10-year-old group. Some patients were noted to have >1 diagnosis.

All 9 patients whose scalps were culture-positive for a dermatophyte were black and grew *Trichophyton tonsurans*. Five of these subjects were 2 to 10 years old, and 4 were <2 years old. Of note, 5 patients who had positive cultures were asymptomatic (no signs

TABLE 1. Demographics by Clinic Type

Characteristic	Dermatology Clinics (n = 100)	Pediatric Clinic (n = 200)	Overall (n = 300)
Age, n (%)			
Under 2 y	50 (50)	100 (50)	150 (50)
2–10 y	50 (50)	100 (50)	150 (50)
Ethnicity, n (%)			
Black	25 (25)	30 (15)	55 (18.4)
White	49 (49.5)	93 (46.5)	142 (47.5)
Asian	5 (5.1)	15 (7.5)	20 (6.7)
Hispanic	15 (15.2)	32 (16)	47 (15.7)
Other/Missing*	5 (5.1)	30 (15)	35 (11.7)
Gender, n (%)			
Male	52 (52)	96 (48)	148 (49.3)
Female	48 (48)	104 (52)	152 (50.7)

No significant difference in demographic profiles between clinics were noted; all $P > .05$.

* One subject's ethnicity was missing.

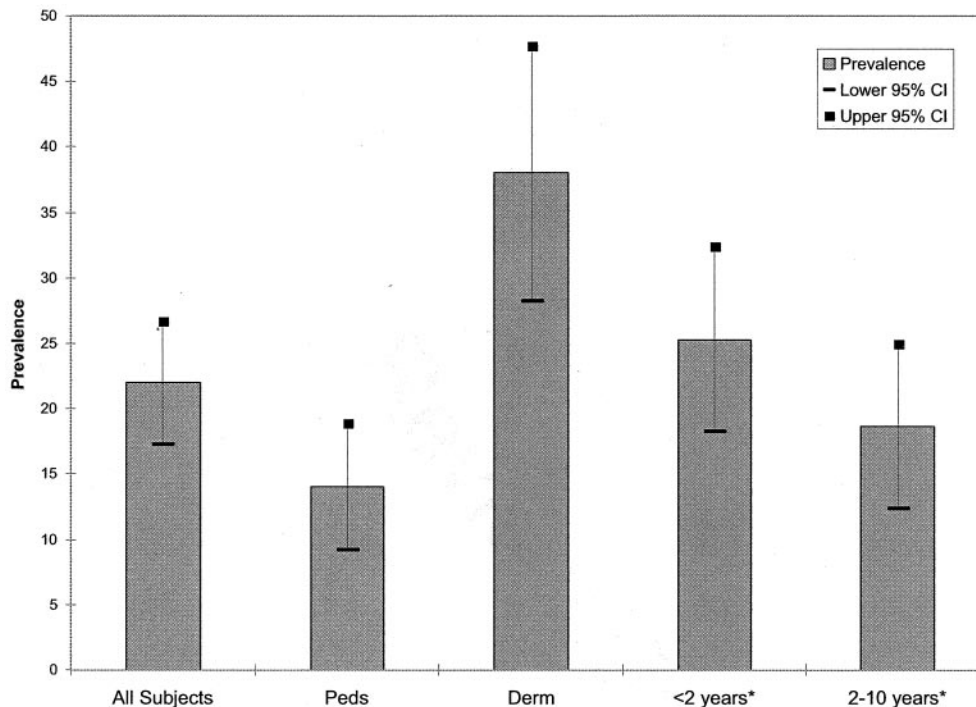


Fig 3. Prevalence of scalp scaling by group.

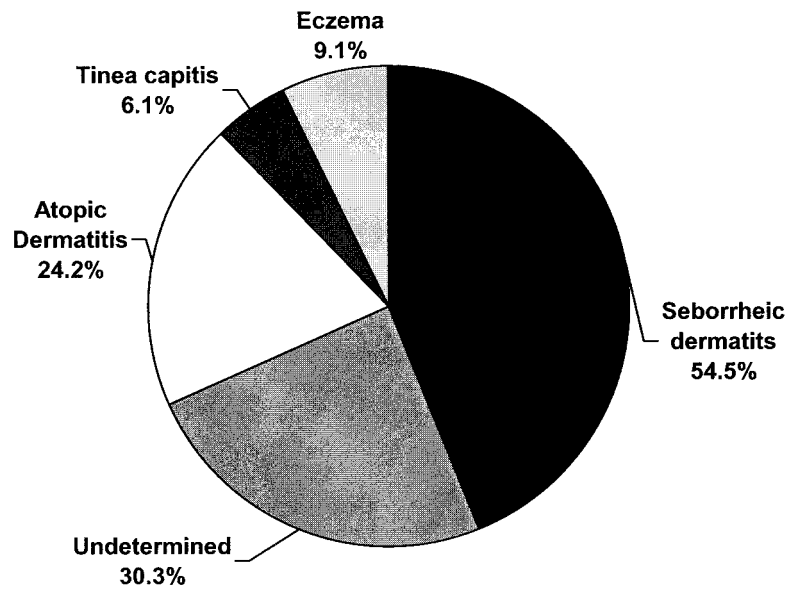
or symptoms related to the scalp). The youngest symptomatic patient was 6 weeks old and had scaling and posterior auricular adenopathy. The presence of current scaling ($P = .014$), pustules ($P < .001$), and alopecia ($P < .001$) were significantly associated with a positive dermatophyte scalp culture.

Of subjects from the pediatric dermatology clinic population, 21% had a current diagnosis of atopic dermatitis; of them, 76.2% (16 of 21) had current scalp scaling, half of which was noted to be infantile-type thick greasy scale, 31.2% (5 of 16) was fine nonspecific scale, and 18.8% (3 of 16) was not described. Some of the parents/guardians of patients in the pediatric clinic population provided a history of eczema in their children but were unclear whether this was specifically atopic dermatitis. Unfortunately, it is common practice for health care practitioners to use the more nonspecific “eczema” term to describe any form of eczematous eruption including atopic dermatitis. The overwhelming majority of pe-

diatric eczemas are atopic dermatitis, and for that reason, the patients with a diagnosis of nonspecific eczema and atopic dermatitis were combined for that population (Fig 4). Such nomenclature problems were not present in the dermatologic clinic patients, because careful attention is paid in those clinics to specifically identify atopic dermatitis versus other forms of eczema whenever possible.

Overall, 52% of 300 patients demonstrated adenopathy of the head and neck, with no significant preference for posterior or anterior location (Fig 5). Nodes in a posterior location were significantly associated with scalp scaling in general ($P = .0054$) and specifically with atopic dermatitis/eczema ($P < .0001$). A positive dermatophyte culture was marginally associated with the presence of posterior nodes ($P = .052$). Of the 66 patients in the study with current scalp scaling, 38 (57.6%) had adenopathy in the head and neck location as well. Posterior head and neck adenopathy with concurrent scalp scaling

Fig 4. Scalp-scaling etiologies (N = 66). The sum of the percentages exceeds 100% because some patients had >1 diagnosis.



*The sum of the percentages exceeds 100% because some patients had more than one diagnosis.

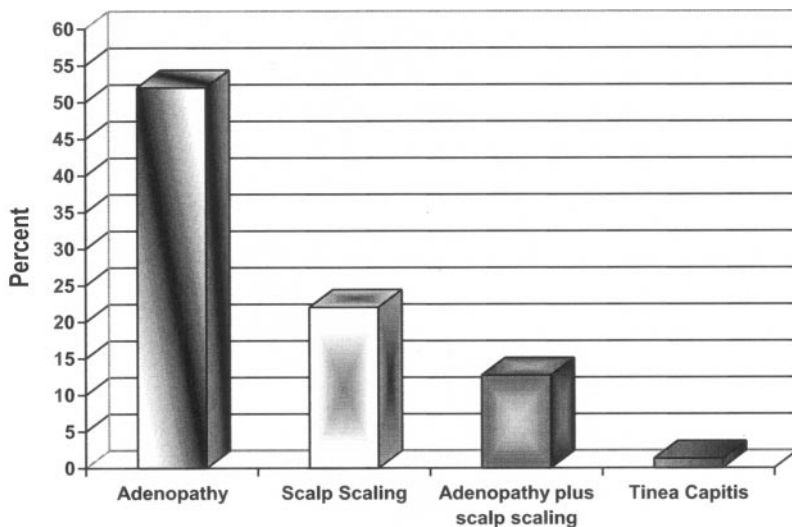


Fig 5. Scalp and neck clinical findings (N = 300).

was significantly associated with seborrheic dermatitis ($P < .001$) and a positive dermatophyte culture ($P = .0012$) for the entire study population and with atopic dermatitis ($p = < .0001$) for the pediatric dermatology group. Of the 38 patients in our study who were found to have scalp scaling plus head and neck adenopathy, only 4 (10.5%) had clinical tinea capitis (Fig 6).

DISCUSSION

This study delineated the prevalence and most common etiologies of scalp scaling in a large cohort of children, ranging in age from newborns to 10-year-olds. Not surprisingly, we found classic infantile seborrheic dermatitis to be a common cause of scalp scaling in infants <2 years old. It is interesting that we found that this “cradle cap” type of greasy scale, which adheres to the scalp and occurs predominantly at the frontal and vertex areas of the scalp, was also common in children 2 to 10 years old, as was the nonspecific fine, nongreasy scale commonly

termed “dandruff,” often found in the postpubertal population. The finding of both infantile- and pubertal-type scaling consistent with the diagnosis of seborrheic dermatitis in this prepubertal population runs contrary to traditional teaching.

Scalp scaling in the setting of atopic dermatitis has been documented by others.^{1,2} We found scalp scaling in association with atopic dermatitis/eczema in children in both age groups in this study, although it was more common in those <2 years old. This likely reflects the overall higher prevalence of atopic dermatitis/eczema in subjects <2 years old (22.7%) compared with 2- to 10-year-olds (7.3%). In our study, diagnostic categories rested on patient history and the diagnoses as listed by the primary provider in the patient chart. The investigators did not attempt to “second-guess” historical data or perform examinations with the purpose of identifying underlying nonscalp disorders. As mentioned previously, primary care physicians frequently combine all eczematous disorders under the term “eczema,”

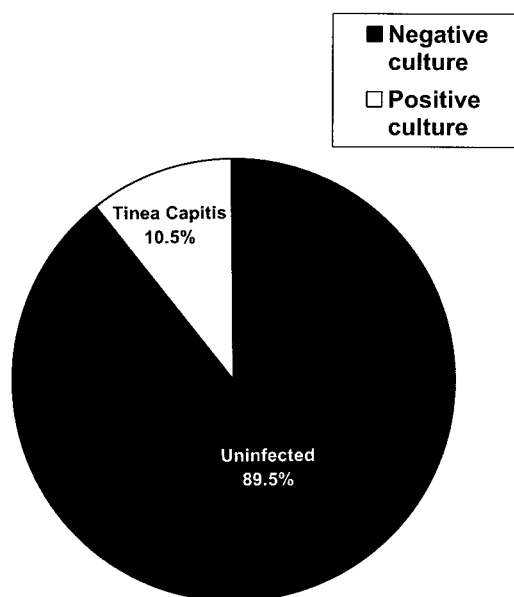


Fig 6. Patients with scalp scaling and lymphadenopathy ($N = 38$).

whereas dermatologists usually make a distinction between atopic dermatitis and other eczematous disorders such as contact dermatitis or nummular dermatitis. For this reason, the group of patients labeled as having “eczema” in the generalist population most likely includes and predominantly represents children with atopic dermatitis.

Scalp scaling was more prevalent in the pediatric dermatology clinic group. This trend may reflect selection bias for skin disorders that are commonly referred to the pediatric dermatologist. An observed 23% of the patients from the pediatric dermatology clinic had a prior or current history of atopic dermatitis, a number well above the estimated overall prevalence (10%) in the general population.

This study did not address other possible etiologies for the nonspecific nongreasy scaling that we considered to be most consistent with postpubertal dandruff. This adult-type of seborrheic dermatitis is believed to be caused, in part, by an immunologic reaction to the presence of the invasive form of the lipophilic yeast *Pityrosporum ovale*.^{13,14} A future study looking at *Pityrosporum* activity on the scalp in both prepubertal and postpubertal populations may be useful in determining if there is supporting evidence for this theory in young children. Even if such nonspecific scaling is unrelated to *Pityrosporum* activity, it is important to recognize how frequently such findings occur.

The prevalence of a positive dermatophyte culture was lower than many of the rates previously reported in studies of inner-city children in the United States.^{15–19} However, prevalence rates vary widely, and lower prevalence rates have been noted in a number of studies.^{20,21} The majority of our subjects were cultured during the spring and early summer months. It is possible that seasonality and/or geographic location with regard to climate may affect dermatophyte prevalence.¹⁸ In addition, the San Diego–based subjects came from both metropolitan

and suburban communities and thus did not represent a true “inner-city” population. Tinea capitis and the asymptomatic carrier state are both more prevalent in the urban black population. Only 18.4% of our study population was black, which could also explain the lower prevalence rate we documented.

A recent study by Hubbard¹⁰ evaluating children with scalp findings in a preselected population of predominantly (91%) black inner-city children found that almost all children with scalp scale and head and neck adenopathy had tinea capitis. We also found a significant association between the presence of scalp scaling with concurrent adenopathy of the head and neck, specifically in a posterior location, and a positive dermatophyte culture. However, we found that the clinical findings of scalp scaling plus adenopathy were not specific for tinea capitis. In fact, the majority of children in our study who had scalp scaling and adenopathy had a negative culture (Fig 6). The scalp scaling in those children most likely represented seborrheic or atopic dermatitis. It may be that the size or quality of lymphadenopathy (eg, “large, firm” rather than “small, shotty”) may be helpful in distinguishing between underlying fungal infection and other causes. Unfortunately, neither our study nor Hubbard’s made such distinctions regarding the quality of lymphadenopathy.

Based on our results, the presence of scalp scaling and adenopathy in both anterior and posterior head and neck locations in a nonselected population of children 0 to 10 years old was a common phenomenon and was not exclusive for tinea capitis. Empiric treatment for tinea capitis in children with scalp scaling and adenopathy alone, without a fungal culture to document the presence of a dermatophyte, may lead to unnecessary treatment. Initiation of therapy pending confirmation by scalp culture would be reasonable in children with suspicious findings, particularly in high-risk groups such as inner-city black children who have scalp scaling or alopecia plus posterior head and neck adenopathy.

CONCLUSIONS

Scalp scaling is a common entity in infants and prepubertal children. Classic seborrheic dermatitis in 2- to 10-year-olds seems to be fairly common despite what current doctrine dictates. Adenopathy of the head and neck is common also in infants and prepubertal children. Head and neck adenopathy in a posterior location is not specific and may be associated with scalp scaling from a variety of causes, particularly atopic dermatitis/eczema. Scalp scaling plus posterior adenopathy of the head and neck may be seen in seborrheic dermatitis, atopic dermatitis, or with a positive dermatophyte culture. In this nonselected pediatric population, scalp scaling with adenopathy was not diagnostic of tinea capitis.

Additional studies are needed to define the causes of nonspecific scalp scaling in children, particularly in the ages between infancy and puberty.

REFERENCES

1. Bonifazi E. Factors influencing the localization of atopic dermatitis. *Acta Derm Venereol*. 1992;176(suppl):24–25

2. Nagaraja, Kanwar AJ, Dhar S, Singh S. Frequency and significance of minor clinical features in various age-related subgroups of atopic dermatitis in children. *Pediatr Dermatol.* 1996;13:10–13
3. Duran C, Tamayo L, de la Luz Orozco M, Ruiz-Maldonado R. Scabies of the scalp mimicking seborrheic dermatitis in immunocompromised patients. *Pediatr Dermatol.* 1993;10:136–138
4. Elmros T, Hornquist R. Infestation of scabies in the scalp area. *Acta Derm Venereol.* 1981;61:360–362
5. Kasteler JS, Callen JP. Scalp involvement in dermatomyositis. Often overlooked or misdiagnosed. *JAMA.* 1994;272:1939–1941
6. Pakula AS, Paller AS. Langerhans cell histiocytosis and dermatophytosis. *J Am Acad Dermatol.* 1993;29(2 pt 2):340–343
7. Shvili D, David M, Mimouni M. Childhood-onset pityriasis rubra pilaris with immunologic abnormalities. *Pediatr Dermatol.* 1987;4:21–23
8. Jones SK, Schwab Hp, Norris DA. Childhood pemphigus foliaceus: case report and review of the literature. *Pediatr Dermatol.* 1986;3:459–463
9. Friedlander SF, West A, Eichenfield LF. Isolated leukemia cutis presenting as "seborrheic dermatitis." *Clin Pediatr (Phila).* 1996;35:531–534
10. Hubbard TW. The predictive value of signs and symptoms in diagnosing childhood tinea capitis. *Arch Pediatr Adolesc Med.* 1999;153:1150–1153
11. Allen HB, Honig PJ. Scalp scaling diseases in children. *Clin Pediatr (Phila).* 1983;22:374–377
12. Friedlander SF, Pickering B, Cunningham BB, Gibbs NF, Eichenfield LF. Use of the cotton swab method in diagnosing tinea capitis. *Pediatrics.* 1999;104:276–279
13. Faergemann J, Bergbrandt IM, Dohse M, Scott A, Westgate G. Seborrheic dermatitis and *Pityrosporum (Malassizia) folliculitis*: characterization of inflammatory cells and mediators in the skin by immunohistochemistry. *Br J Dermatol.* 2001;144:549–556
14. Faergemann J. Pityrosporum yeasts—what's new? *Mycoses.* 1997;40 (suppl 1):29–32
15. Vargo K, Cohen BA. Prevalence of undetected tinea capitis in household members of children with disease. *Pediatrics.* 1993;92:155–157
16. Frieden IJ, Howard R. Tinea capitis: epidemiology, diagnosis, treatment, and control. *J Am Acad Dermatol.* 1994;(3 pt 2):S42–S46
17. Williams JV, Honig PJ, McGinley KJ, Leyden JJ. Semiquantitative study of tinea capitis and the asymptomatic carrier state in inner-city school children. *Pediatrics.* 1995;96:265–267
18. Chen BK, Friedlander SF. Tinea capitis update: a continuing conflict with an old adversary. *Curr Opin Pediatr.* 2001;13:331–335
19. Ghannoum M, Isham N, Hajjeh R, et al. Tinea capitis in Cleveland: survey of elementary school students. *J Am Acad Dermatol.* 2003;48: 189–193
20. Shibaki H, Shibaki A. Analysis of dermatophyte flora at a private clinic in Sapporo during the period 1992 to 2001 [in Japanese]. *Nippon Ishinkin Gakkai Zasshi.* 2003;44:209–216
21. Sharma V, Hall JC, Knapp JF, Sarai S, Galloway D, Babel DE. Scalp colonization by Trichophyton tonsurans in an urban pediatric clinic. Asymptomatic carrier state. *Arch Dermatol.* 1988;124:1511–1513

Prevalence of Scalp Scaling in Prepubertal Children

Judith V. Williams, Lawrence F. Eichenfield, Bonnie L. Burke, Myra Barnes-Eley and
Sheila F. Friedlander

Pediatrics 2005;115;e1

DOI: 10.1542/peds.2004-1616

Updated Information & Services

including high resolution figures, can be found at:
<http://pediatrics.aappublications.org/content/115/1/e1>

References

This article cites 21 articles, 3 of which you can access for free at:
<http://pediatrics.aappublications.org/content/115/1/e1#BIBL>

Subspecialty Collections

This article, along with others on similar topics, appears in the following collection(s):

Dermatology

http://www.aappublications.org/cgi/collection/dermatology_sub

Permissions & Licensing

Information about reproducing this article in parts (figures, tables) or in its entirety can be found online at:

<http://www.aappublications.org/site/misc/Permissions.xhtml>

Reprints

Information about ordering reprints can be found online:

<http://www.aappublications.org/site/misc/reprints.xhtml>

American Academy of Pediatrics

DEDICATED TO THE HEALTH OF ALL CHILDREN®



PEDIATRICS[®]

OFFICIAL JOURNAL OF THE AMERICAN ACADEMY OF PEDIATRICS

Prevalence of Scalp Scaling in Prepubertal Children

Judith V. Williams, Lawrence F. Eichenfield, Bonnie L. Burke, Myra Barnes-Eley and
Sheila F. Friedlander

Pediatrics 2005;115:e1

DOI: 10.1542/peds.2004-1616

The online version of this article, along with updated information and services, is
located on the World Wide Web at:

<http://pediatrics.aappublications.org/content/115/1/e1>

Pediatrics is the official journal of the American Academy of Pediatrics. A monthly publication, it has been published continuously since 1948. Pediatrics is owned, published, and trademarked by the American Academy of Pediatrics, 345 Park Avenue, Itasca, Illinois, 60143. Copyright © 2005 by the American Academy of Pediatrics. All rights reserved. Print ISSN: 1073-0397.

American Academy of Pediatrics

DEDICATED TO THE HEALTH OF ALL CHILDREN[®]

