

# A Novel *CIAS1* Mutation and Plasma/Cerebrospinal Fluid Cytokine Profile in a German Patient With Neonatal-Onset Multisystem Inflammatory Disease Responsive to Methotrexate Therapy

Silvia Stojanov, MD\*; Michael Weiss, MD‡; Peter Lohse, MD§; and Bernd H. Belohradsky, MD\*

**ABSTRACT.** The clinical features, the underlying *CIAS1* mutation, and the results of cytokine analyses are described for a 10-year-old German boy with neonatal-onset multisystem inflammatory disease, whose condition improved with age. Disease onset occurred at 26 months of age with predominantly cutaneous (urticarial rash) and neurologic (headache, chronic meningitis) symptoms including early bilateral optic nerve atrophy, whereas articular manifestations were mild. Sequence analysis of exon 3 of the *CIAS1* gene revealed heterozygosity for a novel missense mutation. A T515C transition led to the replacement of isoleucine by threonine at amino acid position 172 (I172T) in a region of cryopyrin flanking the PYRIN and NACHT domains. This mutation was not present in the parents or in 11 controls and therefore was considered to be a *de novo* mutation. Enzyme-linked immunosorbent assays were performed to determine interleukin-6 and soluble tumor necrosis factor receptor superfamily 1B levels in the patient's serum and cerebrospinal fluid (CSF). Concentrations were highly elevated in the CSF, whereas corresponding serum levels remained low. The strong cytokine activation in the CSF corresponded with the neurologic symptoms. Local activation of intrathecal macrophages may therefore be an important pathogenetic mechanism. CSF cytokine levels decreased to normal under corticosteroid and intrathecal methotrexate therapy. When the boy reached the age of 5.5 years, treatment was stopped, and he has remained relapse-free. *Pediatrics* 2004;114:e124–e127. URL: <http://www.pediatrics.org/cgi/content/full/114/1/e124>; *NOMID, CINCA, chronic infantile neurologic cutaneous and articular syndrome, CIAS1 mutation, cytokines, aseptic meningitis, treatment.*

**ABBREVIATIONS.** NOMID, neonatal-onset multisystem inflammatory disease; CINCA, chronic infantile neurological cutaneous and articular syndrome; CNS, central nervous system; MWS, Muckle-Wells syndrome; FCAS, familial cold autoinflammatory syndrome; IL, interleukin; MTX, methotrexate; CRP, C-reactive protein; ESR, erythrocyte sedimentation rate; Ig, immunoglobulin; CSF, cerebrospinal fluid; PCR, polymerase chain reaction; sTNFRSF1B, soluble tumor necrosis factor receptor superfamily 1B; ELISA, enzyme-linked immunosorbent assay; TNF, tumor necrosis factor.

From the \*Department of Infectious Diseases and Immunology, Children's Hospital, University of Munich, Munich, Germany; †Children's Hospital, City of Cologne, Germany; and ‡Department of Clinical Chemistry–Grosshadern, University of Munich, Munich, Germany.

Received for publication Sep 29, 2003; accepted Feb 2, 2004.

Reprint requests to (S.S.) Department of Infectious Diseases and Immunology, Children's Hospital, University of Munich, Lindwurmstrasse, 4 D-80337 Munich, Germany. E-mail: [silvia.stojanov@med.uni-muenchen.de](mailto:silvia.stojanov@med.uni-muenchen.de) PEDIATRICS (ISSN 0031 4005). Copyright © 2004 by the American Academy of Pediatrics.

Neonatal-onset multisystem inflammatory disease (NOMID),<sup>1</sup> which has also been called chronic infantile neurologic cutaneous and articular (CINCA) syndrome,<sup>2</sup> is defined by the triad of cutaneous rash, central nervous system (CNS) involvement, and arthropathy in association with recurrent bouts of fever of variable duration.<sup>3</sup> Disease onset occurs most often at birth or within the first weeks thereafter, frequently in the form of a persistent and migratory nonpruritic urticaria. CNS manifestations mainly include headaches, chronic aseptic meningitis, and sensory organ involvement such as optic disk changes with consequent visual impairment<sup>4</sup> and progressive perceptual deafness. Articular symptoms vary considerably from mild transient arthralgia to a severe deforming arthropathy. Unrelated patients often resemble each other because of characteristic dysmorphic features such as saddle nose, frontal bossing, and clubbing of fingers. The disease course is usually characterized by progression, and persistent remissions have not been reported yet.

NOMID/CINCA is a rare congenital autoinflammatory disorder (with ~100 reported cases worldwide<sup>5</sup>) that results from missense mutations within exon 3 of the *CIAS1* gene on chromosome 1q44. Alterations of this particular exon have been reported previously also to cause Muckle-Wells syndrome (MWS) and familial cold autoinflammatory syndrome (FCAS),<sup>6</sup> 2 other autoinflammatory diseases associated with fever, arthralgia, and urticaria. Actually, >20 different *CIAS1* mutations have been described to cause the 3 overlapping syndromes, with FCAS representing the mildest and NOMID/CINCA representing the most severe disease expression. Similar to FCAS and MWS, an autosomal dominant inheritance pattern is also assumed for NOMID/CINCA.

The *CIAS1* gene encodes the protein cryopyrin (also called PYPAF1 or NALP3), which is highly expressed in polymorphonuclear cells and chondrocytes.<sup>7,8</sup> It contains a PYRIN domain,<sup>9</sup> involved in the regulation of inflammation and apoptosis.<sup>6</sup> Because cryopyrin activates nuclear factor  $\kappa$ B<sup>10</sup> and also may regulate interleukin-1 (IL-1) processing through PYRIN domain-mediated caspase 1 signaling,<sup>11</sup> *CIAS1* mutations have been proposed to have a profound proinflammatory effect. Accordingly, during (and often between) febrile episodes, laboratory investigations reveal an inflammatory state with elevated acute-phase reactants.

Here we report a de novo *CIAS1* mutation and the resulting cerebral cytokine activation in a patient of German origin, whose clinical picture resembled NOMID/CINCA and whose condition surprisingly improved with age after a long-term methotrexate (MTX) treatment over 2.5 years.

## METHODS

The proband and his healthy, nonconsanguineous parents of German origin were investigated. Written, informed consent was obtained from the patient's parents. The study was conducted according to Helsinki Committee standards.

### Patient

After an uneventful pregnancy, the 10-year-old boy was born at 40 weeks' gestation with a birth weight of 3220 g. Since the age of 26 months, he exhibited a nonpruritic urticarial rash located mainly on his trunk. Three months later, the child showed recurrent fever, arthralgia (knees, ankles, feet), and a sudden, progressive visual impairment. At 32 months of age, he developed the clinical picture of acute meningitis, which was accompanied by high, spiking fever, exanthema, and arthralgia. Physical examination revealed a disproportionate increase of the cranial circumference and a striking delay in the closure of the fontanel. Ventricular enlargement was confirmed by cranial magnetic resonance imaging. Electroencephalography repeatedly showed diffuse slow waves. Neurologic examination demonstrated a normally developed boy without signs of psychomotor or psychomotor retardation. Ophthalmologic evaluation revealed a bilaterally reduced vision, an optic atrophy, which was more pronounced on the left side, and pathologic visually evoked potentials. Laboratory findings showed neutrophilic leukocytosis (up to 85%; maximum: 32,500 per  $\mu\text{L}$ ) with eosinophilia (9%), thrombocytosis (maximum: 575,000 per  $\mu\text{L}$ ), C-reactive protein (CRP) levels up to 23 mg/dL, and an increased erythrocyte sedimentation rate (ESR) (maximum: 124/150 mm/hour, Westergren). Additional pathologic findings were a polyclonal hypergammaglobulinemia with increased immunoglobulin (Ig)G (maximum: 1350 mg/dL), IgM (maximum: 273 mg/dL), and IgD (maximum: 256 IU/mL) levels as well as the presence of anticardiolipin IgG antibodies. The cerebrospinal fluid (CSF) showed an increased cellularity (70 per  $\mu\text{L}$ ) due to predominantly neutrophils (82%) and monocytes (12%) and an elevated protein concentration (55 mg/dL), whereas repeated microbiologic and serologic tests for bacteria and viruses remained negative. The HLA pattern (HLA A2, B7, DR2, DR7), cellular and humoral immunity, complement levels, and antinuclear antibodies were normal.

Despite antibiotic treatment, the symptoms of chronic meningitis as confirmed by repeated CSF examinations did not resolve. After the diagnosis of NOMID/CINCA in early childhood, the patient was treated with high-dose oral glucocorticosteroids (5 mg/kg per day) since the age of 35 months. His clinical condition and especially his vision improved already 1 week after the onset of treatment. After the corticosteroids were reduced to a low-dose regimen (0.2 mg/kg per day) 3 weeks after treatment implementation, however, the boy's clinical condition worsened, and he increasingly showed inflammatory signs in serum and CSF. Therefore, steroids were stopped at the age of 36 months, and oral therapy with MTX was initiated at 37 months of age (10 mg/m<sup>2</sup> per week, raised to 15 mg/m<sup>2</sup> per week within 3 weeks). Because of the deterioration of his left eye vision despite clinical improvement, intrathecal MTX (12 mg) and prednisolone (10 mg) applications once monthly were started at the age of 41 months in addition to the weekly oral MTX therapy. Two days after the sixth intrathecal MTX application, the boy developed a left-sided chronic subdural hematoma, and neurosurgical trepanation had to be performed as an emergency procedure. As a consequence, intrathecal MTX treatment application was stopped when the boy was 46 months old. Oral MTX was continued, and there were no signs of major clinical deterioration. At the age of 4 years, a mild, high-tone sensorineural deafness was diagnosed.

Since the cessation of any immunologic and antiinflammatory therapy at the age of 5.5 years, the boy's clinical condition has improved further. Only intermittently he showed urticarial rash, subfebrile temperatures with exercise-induced fever, and slightly

increased acute-phase reactant levels (CRP: 2.78 mg/dL; ESR: 57/93 mm/hour), but he had no neurologic symptoms, a normal electroencephalogram, and no signs of arthropathy or growth retardation. His visual impairment is slowly progressive, whereas his mild hearing deficit remains stable.

### DNA Extraction

EDTA blood samples were collected from the patient and his parents, and the genomic DNA was isolated from white blood cells by the help of the QIAamp blood minikit (Qiagen, Hilden, Germany).

### Polymerase Chain Reaction Amplification and DNA Sequence Analysis of the *CIAS1* Gene

Exon 3 of the *CIAS1* gene was amplified from high-molecular weight DNA with 2 oligonucleotides located in the adjacent intronic regions ~70 to 80 bases up- and downstream from the respective exon/intron border. The polymerase chain reaction (PCR) products were purified with the QIAquick PCR purification kit (Qiagen) and sequenced with the ABI PRISM Big Dye Terminator v3.1 ready reaction cycle sequencing kit (Applied Biosystems, Foster City, CA) by using 5 different internal primers. Sequences were analyzed on an ABI PRISM 377 DNA sequencer (Applied Biosystems) using the Sequence Analysis 3.4.5 program (Applied Biosystems).

### Measurement of IL-6 and Soluble Tumor Necrosis Factor Receptor Superfamily 1B Levels

During disease exacerbation as well as under steroid and MTX treatment, cytokine measurements were performed in serum and CSF samples from the patient with commercially available enzyme-linked immunosorbent assays (ELISAs). The proinflammatory cytokine IL-6 was measured with a sandwich ELISA kit manufactured by Dianova-Immunotech (Hamburg, Germany; sample volumes: 100  $\mu\text{L}$ ; normal value: <10 pg/mL).<sup>12</sup> To determine serum and CSF concentrations of the soluble tumor necrosis factor receptor superfamily 1B (sTNFRSF1B, p75), an ELISA kit distributed by DPC-Biermann (Bad Nauheim, Germany) was applied. sTNFRSF1B levels increase during inflammation and in autoimmune diseases; however, even in healthy control persons, constitutive concentrations are present in the range of  $\geq 1700$  pg/mL.<sup>13</sup>

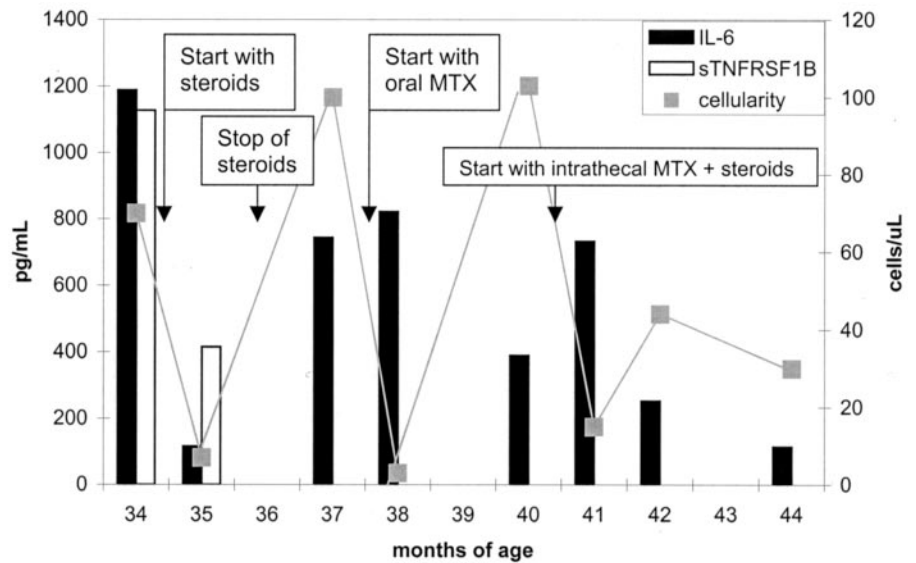
Absorbance was measured in an appropriate photometer (Dynatech Laboratories, Inc, Chantilly, VA), and cytokine concentrations were calculated with an ELISA software program based on standard curves and positive controls.

## RESULTS

We detected a novel T→C transition at cDNA nucleotide position 515 (with respect to the ATG start codon) located in exon 3 of the *CIAS1* gene, which results in the exchange of isoleucine (ATC) by threonine (ACC) at amino acid position 172 (I172T). The boy is a heterozygous carrier of this missense mutation, which was not found in the patient's healthy parents and on 22 control chromosomes and which seems to represent therefore a de novo mutation. It is also the first NOMID/CINCA-associated mutation that is located in the cryopyrin region that flanks the PYRIN and NACHT domain.

Because the boy mainly presented with signs of chronic meningitis including slowly progressive optic nerve atrophy and visual impairment, we also studied his cytokine profile in serum and CSF samples before and after therapy with prednisolone as well as before and during oral and intrathecal MTX treatment over a period of 10 months. Serum sTNFRSF1B levels measured before and after oral steroid therapy were always within the normal range (between 1600 and 2100 pg/mL). Similarly, serum

**Fig 1.** The patient's CSF cellularity as well as IL-6 and sTNFRSF1B levels in the CSF over a period of 10 months. sTNFRSF1B concentrations were only determined until the age of 36 months, whereas the measurement of IL-6 was stopped simultaneously with cessation of intrathecal MTX application after the development of a chronic subdural hematoma at the age of 46 months.



IL-6 measurements revealed normal or only slightly increased concentrations during steroid as well as MTX therapy, ranging from 5 to 27 pg/mL. Thus, proinflammatory IL-6 and antiinflammatory sTNFRSF1B serum levels were not increased, although the patient showed elevated acute-phase reactants, with an ESR of up to 124/150 mm/hour and with maximum CRP levels of 23 mg/dL. Simultaneous measurement of the boy's CSF cytokine concentrations during chronic meningitis, however, revealed markedly elevated levels of IL-6 (1190 pg/mL) and sTNFRSF1B (1130 pg/mL; Fig 1). After initiation of high-dose glucocorticoid therapy, cytokine levels as well as CSF cellularity decreased rapidly (IL-6: 120 pg/mL; sTNFRSF1B: 415 pg/mL; CSF: 7 cells per  $\mu$ L). After reduction of the steroid dosage, IL-6 concentrations increased again to values of  $\sim$ 800 pg/mL, which was accompanied by a CSF pleocytosis of 100 cells per  $\mu$ L. Onset of oral MTX treatment led to clinical improvement and normalization of CSF cellularity (3 cells per  $\mu$ L), whereas IL-6 levels initially remained elevated. During the following 2 MTX treatment months, a CSF pleocytosis (100 cells per  $\mu$ L) again was present, whereas IL-6 concentrations declined to  $\sim$ 400 pg/mL but did not return to normal. Because of the deterioration of his vision with the danger of imminent blindness, intrathecal MTX and prednisolone applications were started at the age of 41 months. Although CSF cellularity nearly normalized to 15 cells per  $\mu$ L, IL-6 levels increased to  $\sim$ 740 pg/mL, which was followed by a slow but continuous decline to 115 pg/mL over the next 3 months in the presence of mild pleocytosis (30–45 cells per  $\mu$ L).

#### DISCUSSION

NOMID/CINCA is the most severe of 3 overlapping syndromes also including FCAS and MWS, which were recognized recently to be the consequence of mutations in exon 3 of the *CIAS1* gene.<sup>7,8</sup> We have identified a novel I172T missense mutation also encoded by *CIAS1* exon 3 in a German patient, who presented with clinical features compatible with

NOMID/CINCA. This mutation is the first amino acid substitution associated with this disorder, which is located next to the PYRIN domain of cryopyrin. Only 1 additional mutation has been reported to be located in the region flanking the PYRIN and NACHT domain (V198M), leading to FCAS instead.<sup>6</sup>

The *CIAS1* gene is highly expressed in leukocytes (especially in monocytes and granulocytes) as well as in chondrocytes. Accordingly, our patient had predominantly neutrophils and monocytes in the peripheral blood as well as in the CSF. Cryopyrin was shown recently to be a potent upstream activator of nuclear factor  $\kappa$ B signaling.<sup>10</sup> Despite this, inflammatory mediators (especially cytokines) have been studied only sporadically in NOMID/CINCA<sup>8,14</sup> and MWS<sup>15</sup> by using serum or plasma samples but not CSF. Cytokine analyses in our proband revealed an intense activation of both proinflammatory IL-6 and antiinflammatory sTNFRSF1B in the CSF. Despite simultaneously increased acute-phase reactants, corresponding cytokine levels in serum remained normal. This result indicates a predominantly local inflammation of the CNS, which is consistent with the clinical phenotype of chronic meningitis in this patient. Because IL-6 plays a central role in acute-phase protein induction, one could speculate that the inflammatory process in the CNS induces a peripheral inflammation via a destroyed blood-brain barrier, with IL-6 not being measurable because of lower peripheral levels and a short half-life. Alternatively, the blood-brain barrier may be intact and peripheral IL-6 is therefore low.

In contrast to our findings, Aksentijevich et al<sup>8</sup> detected increased serum levels of IL-6 and tumor necrosis factor (TNF)  $\beta$ 1 in a patient with the *CIAS1* D303N mutation, who presented with arthropathy as well as CNS inflammation, which was accompanied by an accumulation of cytokines in the peripheral blood. In accordance with the latter finding were the elevated IL-1 $\beta$ , IL-3, IL-5, and IL-6 concentrations measured in monocyte lysates of this patient. Huttenlocher et al,<sup>14</sup> on the other hand, described a patient with severe arthropathy (but without CNS

involvement) who had normal serum levels of IL-1, IL-6, and TNF- $\alpha$ , whereas TNF- $\beta$  levels were elevated.

With regard to the clinical features, our proband suffered from a milder NOMID/CINCA variant, because he showed prominent CNS and eye involvement as well as urticarial exanthema but only mild arthralgia without swelling or development of any joint deformity or bony prominence. Furthermore, the age of the patient at onset of symptoms was 26 months, thus being outside the typical neonatal onset. Besides the lack of arthropathy and the delayed disease onset, this is also the first case of NOMID/CINCA with clinical improvement at later age and especially with unexpected remission of CNS symptoms. Despite 4.5 years of treatment cessation, there was no systemic relapse, and the patient's visual defect showed only a slight progression. Whether this course is because of the earlier intrathecal MTX and prednisolone therapy or a direct consequence of the specific mutation, which is located next to the PYRIN domain, remains to be elucidated. Up to now, only 2 patients in whom treatment with MTX was efficacious in controlling the symptoms have been described.<sup>16</sup> However, none of the patients received MTX intrathecally. Fortunately, the boy has also not shown any clinical signs of amyloidosis despite evidence of slightly but continuously elevated acute-phase proteins.

### CONCLUSIONS

Our findings illustrate the broad spectrum of organ involvement in *CIAS1*-associated diseases (especially in NOMID/CINCA) and the phenotypic variability of the underlying mutations. Our results may also provide a basis for new therapeutic options such as intrathecal MTX application, sTNF-R-Fc fusion proteins such as etanercept (Enbrel), or monoclonal anti-IL-6 antibodies to control local and systemic inflammation.

### ACKNOWLEDGMENTS

We thank the family members for participation in this study and Genoveva Kim and Dieter Kunz for excellent technical assistance.

### REFERENCES

1. Hassink SG, Goldsmith DP. Neonatal onset multisystem inflammatory disease. *Arthritis Rheum.* 1983;26:6368–6373
2. Prieur A-M, Griscelli C, Lampert F, et al. A chronic, infantile, neurological, cutaneous and articular (CINCA) syndrome. A specific entity analysed in 30 patients. *Scand J Rheumatol Suppl.* 1987;66:57–68
3. Prieur A-M. A recently recognised chronic inflammatory disease of early onset characterised by the triad of rash, central nervous system involvement and arthropathy. *Clin Exp Rheumatol.* 2001;19:103–106
4. Dollfus H, Häfner R, Hofmann HM, et al. Chronic infantile neurological cutaneous and articular/Neonatal onset multisystem inflammatory syndrome. Ocular manifestations in a recently recognized chronic inflammatory disease of childhood. *Arch Ophthalmol.* 2000;118:1386–1392
5. Galon J, Aksentijevich I, McDermott MF, O'Shea JJ, Kastner DL. TNFRSF1A mutations and autoinflammatory syndromes. *Curr Opin Immunol.* 2000;12:479–486
6. Hoffman HM, Mueller JL, Broide DH, Wanderer AA, Kolodner RD. Mutation of a new gene encoding a putative pyrin-like protein causes familial cold autoinflammatory syndrome and Muckle-Wells Syndrome. *Nat Genet.* 2001;29:301–305
7. Feldmann J, Prieur A-M, Quartier P, et al. Chronic infantile neurological cutaneous and articular syndrome is caused by mutations in *CIAS1*, a gene highly expressed in polymorphonuclear cells and chondrocytes. *Am J Hum Genet.* 2002;71:198–203
8. Aksentijevich I, Nowak M, Mallah M, et al. De novo *CIAS1* mutations, cytokine activation, and evidence for genetic heterogeneity in patients with neonatal-onset multisystem inflammatory disease (NOMID). *Arthritis Rheum.* 2002;46:3340–3348
9. Masumoto J, Taniguchi S, Sagara J. Pyrin N-terminal homology domain- and caspase recruitment domain-dependent oligomerization of ASC. *Biochem Biophys Res Commun.* 2001;280:652–655
10. Manji GA, Wang L, Geddes BJ, et al. PYPAF1, a PYRIN-containing Apaf1-like protein that assembles with ASC and regulates activation of NF-kappa B. *J Biol Chem.* 2002;277:11570–11575
11. Wang L, Manji GA, Grenier J, et al. PYPAF7: a novel PYRIN-containing Apaf1-like protein that regulates activation of NF-kB and caspase-1-dependent cytokine processing. *J Biol Chem.* 2002;277:29874–29880
12. Küster H, Weiss M, Willeitner AE, et al. Interleukin-1 receptor antagonist and interleukin-6 for early diagnosis of neonatal sepsis 2 days before clinical manifestation. *Lancet.* 1998;352:1271–1277
13. Weiss M, Martignoni M, Petropoulou T, Sölder B, Belohradsky BH. Increased serum levels of soluble tumor necrosis factor receptors (sTNFRs) in children and adolescents with vertically and horizontally transmitted HIV infection. *Infection.* 1996;24:301–308
14. Huttenlocher A, Frieden IJ, Emery H. Neonatal onset multisystem inflammatory disease. *J Rheumatol.* 1995;22:1171–1173
15. Gerbig AW, Dahinden CA, Mullis P, Hunziker T. Circadian elevation of IL-6 levels in Muckle-Wells syndrome: a disorder of the neuro-immune axis? *QJM.* 1998;91:489–492
16. Goldsmith DP, Lasky AS, Prieur A-M. CINCA/NOMID (CN): further clinical observations. *Arthritis Rheum.* 1996;39(suppl):S236

**A Novel *CIAS1* Mutation and Plasma/Cerebrospinal Fluid Cytokine Profile in a German Patient With Neonatal-Onset Multisystem Inflammatory Disease Responsive to Methotrexate Therapy**

Silvia Stojanov, Michael Weiss, Peter Lohse and Bernd H. Belohradsky

*Pediatrics* 2004;114:e124

DOI: 10.1542/peds.114.1.e124

**Updated Information & Services**

including high resolution figures, can be found at:  
<http://pediatrics.aappublications.org/content/114/1/e124>

**References**

This article cites 16 articles, 2 of which you can access for free at:  
<http://pediatrics.aappublications.org/content/114/1/e124#BIBL>

**Subspecialty Collections**

This article, along with others on similar topics, appears in the following collection(s):  
**Genetics**  
[http://www.aappublications.org/cgi/collection/genetics\\_sub](http://www.aappublications.org/cgi/collection/genetics_sub)  
**Rheumatology/Musculoskeletal Disorders**  
[http://www.aappublications.org/cgi/collection/rheumatology:musculoskeletal\\_disorders\\_sub](http://www.aappublications.org/cgi/collection/rheumatology:musculoskeletal_disorders_sub)

**Permissions & Licensing**

Information about reproducing this article in parts (figures, tables) or in its entirety can be found online at:  
<http://www.aappublications.org/site/misc/Permissions.xhtml>

**Reprints**

Information about ordering reprints can be found online:  
<http://www.aappublications.org/site/misc/reprints.xhtml>

American Academy of Pediatrics

DEDICATED TO THE HEALTH OF ALL CHILDREN™



# PEDIATRICS®

OFFICIAL JOURNAL OF THE AMERICAN ACADEMY OF PEDIATRICS

**A Novel *CIAS1* Mutation and Plasma/Cerebrospinal Fluid Cytokine Profile in a German Patient With Neonatal-Onset Multisystem Inflammatory Disease Responsive to Methotrexate Therapy**

Silvia Stojanov, Michael Weiss, Peter Lohse and Bernd H. Belohradsky

*Pediatrics* 2004;114:e124

DOI: 10.1542/peds.114.1.e124

The online version of this article, along with updated information and services, is located on the World Wide Web at:

<http://pediatrics.aappublications.org/content/114/1/e124>

Pediatrics is the official journal of the American Academy of Pediatrics. A monthly publication, it has been published continuously since 1948. Pediatrics is owned, published, and trademarked by the American Academy of Pediatrics, 141 Northwest Point Boulevard, Elk Grove Village, Illinois, 60007. Copyright © 2004 by the American Academy of Pediatrics. All rights reserved. Print ISSN: 1073-0397.

American Academy of Pediatrics

DEDICATED TO THE HEALTH OF ALL CHILDREN™

