

Unilateral Negative-Pressure Pulmonary Edema in an Infant During Bronchoscopy

Shai Hannania, MD*[¶]; Michal Barak, MD^{‡§}; and Yeshayahu Katz, MD, DSc[¶]

ABSTRACT. We report here a case of a 3-week-old infant with a lung disease of unknown origin who underwent diagnostic fiber-optic bronchoscopy. During the procedure, she developed unilateral pulmonary edema. Factors that contributed to this complication are discussed along with means to reduce its occurrence. *Pediatrics* 2004;113:e501–e503. URL: <http://www.pediatrics.org/cgi/content/full/113/5/e501>; infant, pulmonary edema, bronchoscopy.

ABBREVIATION. NPPE, negative-pressure pulmonary edema.

Negative-pressure pulmonary edema (NPPE) may develop whenever subatmospheric pressure is generated at the alveolar level. It usually occurs in young, muscular, adult subjects with an acute airway obstruction of various causes¹ and is unusual in neonates and young infants because of their compliant chest walls. We describe a 3-week-old infant in whom hypoxemia occurred during diagnostic fiber-optic bronchoscopy and who was subsequently diagnosed as having unilateral NPPE. To our knowledge, this is the first case report describing such a complication in a neonate after bronchoscopy.

CASE REPORT

A 3-week-old female infant was scheduled to have an elective diagnostic bronchoscopy. She was born at term via normal vaginal delivery with an Apgar score of 9 at 1 minute and 10 at 5 minutes. Soon after birth, she became slightly cyanotic (saturation: 80–82% on room air), was admitted to the neonatal intensive care unit, and was kept in a humidified oxygen tent (fraction of inspired oxygen: 30%). On this regimen she reached saturations of between 94% and 97%. Over the following days, she gradually developed hypercapnia with acidemia. The main physical finding was of wet inspiratory crackles over the lung bases. Blood cultures and serologic tests for toxoplasmosis, rubella, cytomegalovirus, herpes simplex virus types 1 and 2, and other viruses all proved

negative. Broad-spectrum antibiotics including macrolides did not change her clinical status. Repeated vomiting raised the possibility of gastroesophageal reflux, and cisapride was administered. A plain chest radiograph and computed tomography scan disclosed hyperinflation and bilateral infiltrates. Cardiac echo-Doppler showed no malformation. To rule out congenital alveolar proteinosis, or functional impairment of surfactant, it was decided to perform fiber-optic bronchoscopy.

The infant was anesthetized with gradually increasing concentrations of halothane in oxygen using a fitted pediatric mask and a Jackson-Rees system. She was breathing spontaneously with the assistance of intermittent bag ventilation. Small boluses of propofol were administered whenever she reacted to airway manipulation. A 3.5-mm video-assisted bronchoscope was inserted via a 90° leak-tight swivel connector. Inspection showed normal trachea and left bronchial tree. Bronchoalveolar lavage was performed by wedging the right bronchus and instilling boluses of saline. Five milliliters of saline were instilled and immediately suctioned while withdrawing the bronchoscope upward. The suction port was connected to the wall-mounted high-intensity vacuum system via a standard bottle collection device. The lavage fluid that was collected was mildly hazy. Immediately afterward, the child's oxygen saturation dropped to 73% to 78%. Her respiration became irregular, and active assisted bag ventilation with 100% oxygen was started, but saturation did not improve. Auscultation revealed diminished breath sounds and crepitation over the right lung. Her heart rate ranged between 130 and 150 beats per min. A 3.5-mm (inner diameter) endotracheal tube was inserted, and because the child resisted ventilation, 2 mg of atracurium were given for muscle relaxation. Small positive end-expiratory pressure was applied by partially occluding the Jackson-Rees bag valve. Her blood pressure and heart rate were stable throughout the event, and her temperature was 36°C. Slowly, over 15 to 20 minutes, her blood oxygen saturation rose and stabilized between 94% and 97%. A chest radiograph showed patchy infiltrates in the entire right lung, suggesting unilateral pulmonary edema (Fig 1). The infant was transferred to the neonatal intensive care unit and extubated 6 hours later. A repeated chest radiograph, 8 hours later, was almost normal (Fig 2). She was weaned from the oxygen supplement gradually. The lavage fluid was negative for pneumocystis carinii and alveolar pro-

From the [¶]Department of Anesthesiology and ^{*}Pediatric Pulmonary Unit, HaEmek Medical Center, Afula, Israel; [‡]Department of Anesthesiology, Rambam Medical Center, Haifa, Israel; and [§]Bruce Rappaport Faculty of Medicine, Technion-Israel Institute of Technology, Haifa, Israel.

Received for publication Oct 21, 2003; accepted Jan 9, 2003.

Address correspondence to Yeshayahu Katz, MD, DSc, Department of Anesthesiology, HaEmek Medical Center, 18101 Afula, Israel. E-mail: ykatz18@hotmail.com

PEDIATRICS (ISSN 0031 4005). Copyright © 2004 by the American Academy of Pediatrics.

Fig 1. Chest radiograph showing patchy infiltrates in the right lung.

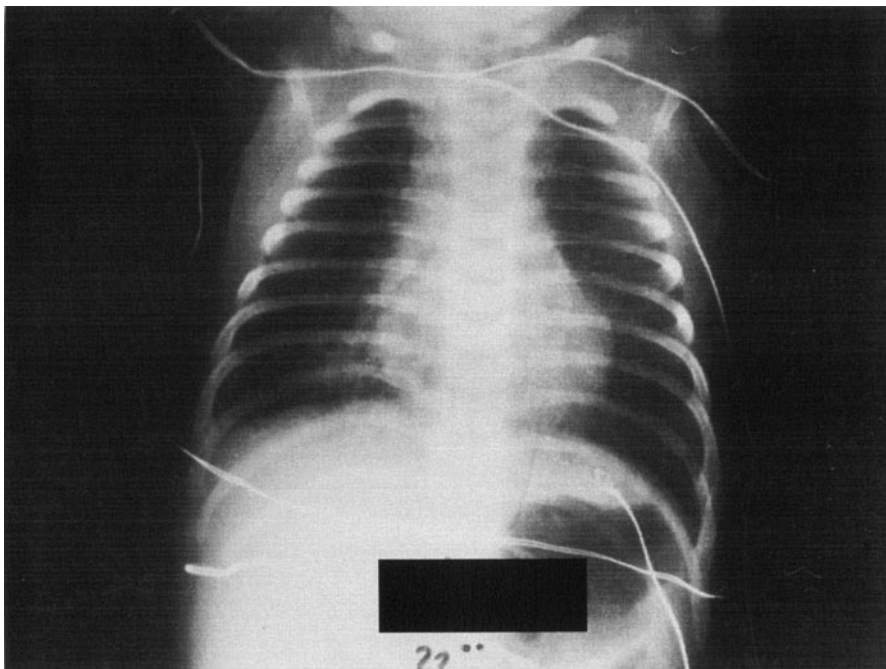
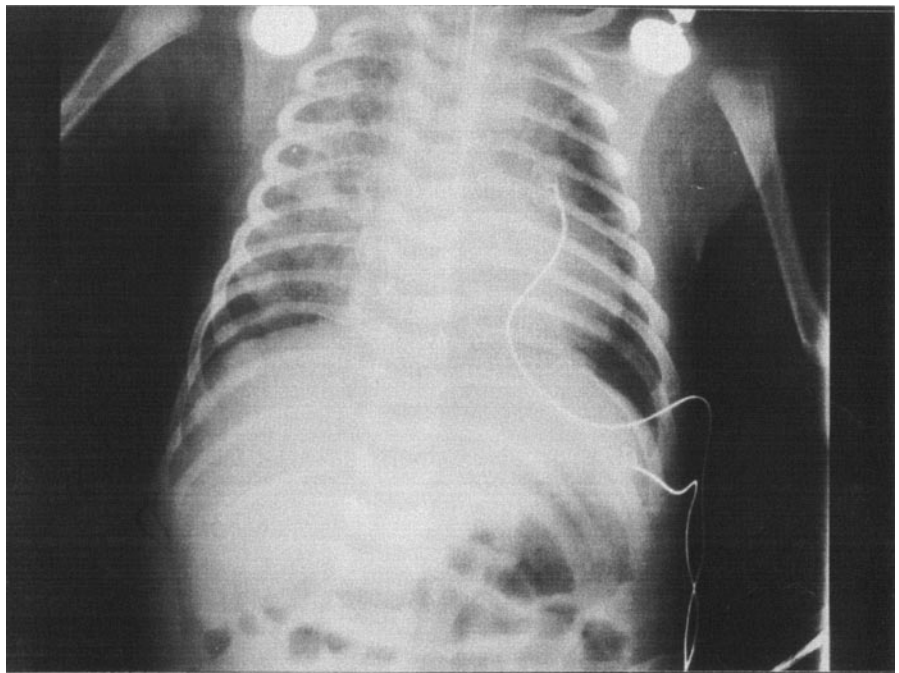


Fig 2. Follow-up chest radiograph showing resolution of the patchy infiltrates in the right lung.

teinosis. Cytologic analysis of the lavage fluid revealed squamous epithelium with few ciliary columnar cells. The infant was discharged from the hospital 10 days later without instructions for special care.

DISCUSSION

Pulmonary edema associated with negative airway pressure was described long ago.^{1,2} The pathophysiology of this disease is the markedly negative intrathoracic pressure caused by forced inspiration against a closed airway, resulting in transudation of fluid from capillaries to the interstitium and alveoli. It usually accrues in healthy adult males with an acute airway obstruction.³ The onset of pulmonary

edema is almost instantaneous, and chest radiographs show characteristic features of congestion. In most cases, the edema resolves within a few hours with or without short-term ventilatory support. The use of diuretics or bronchodilators is debatable, and their contribution to recovery is unclear.⁴ Another physiologic cause for NPPE is the application of external negative pressure in the bronchial/alveolar lumen. Chest wall resistance on the other side opposes that pressure. If the negative pressure is low enough, it may elicit extravasation of fluid into the alveoli.⁵ However, the wide array of clinical situations of NPPE in which the pathophysiology is not always clear necessitates additional investigation.

NPPE is unusual in infants because of their com-

pliant chest walls; the neonate's chest cage is flexible, and its musculature is not fully developed. Therefore, even with airway obstruction, extreme negative intra-alveolar pressure is not generated in the very young pediatric population.⁶ In our case, excessive negative pressure applied for suctioning the lavage fluid facilitated extravasation of transudate fluid into the alveoli and created edema, which could have been prevented by using a negative-pressure release valve within the suction system connected to the bronchoscope or by using a smaller-caliber bronchoscope, which allows venting and precludes generation of excessive negative pressure. The quick development of pulmonary edema, with typical radiographic findings, and rapid resolution of the symptoms are characteristic of NPPE. The 1-sided pathology also supports this diagnosis. Unilateral pulmonary edema is the result of a localized factor. Reexpansion of the lung after thoracocentesis and pneumothorax accounts for the majority of such events.^{7,8} Rare cases include gravitational edema (edema in the dependent lung), occlusion of pulmonary vasculature, and acute bronchial obstruction by a foreign body or tumor.⁹ A relevant differential diagnosis may also be the instillation of a 5-mL bolus of saline to an infant, which results in an immediate decrease in pulmonary compliance, decrease in oxygen saturation, and altered respiratory and cardiovascular dynamics. Furthermore, an abnormal chest radiograph should be expected after lung lavage, especially with preexisting pulmonary pathology. However, lung lavage is a very common procedure during bronchoscopy and had not resulted previously in unilateral pulmonary edema. Thus, it is reasonable to conclude that, in our case, the applica-

tion of suction to the right main bronchus generated negative pressure, causing right-sided pulmonary edema.

Considering that conservative management allowed eventual full recovery of the infant, the diagnostic bronchoscopy could have waited. The urge to have a definitive diagnosis for each and every pathologic sign or symptom drives us to carry out endless tests, some of which are invasive. The price of this trend is the increasing rate of iatrogenic morbidity. It is important to remember the risks that we may introduce when on the track to reaching a diagnosis.

ACKNOWLEDGMENTS

We thank Ms. Frances Nachmani for assistance in editing the manuscript.

REFERENCES

1. Oswalt CE, Gates GA, Holmstrom MG. Pulmonary edema as a complication of acute airway obstruction. *JAMA*. 1977;238:1833-1835
2. Capitanio MA, Kirkpatrick JA. Obstructions of the upper airway in children as reflected on the chest radiograph. *Radiology*. 1973;107:159-161
3. Deepika K, Kanaan CA, Barrocas AM, Fonseca JJ, Bikazi GB. Negative pressure pulmonary edema after acute airway obstruction. *J Clin Anesth*. 1997;9:403-408
4. Halow KD, Ford EG. Pulmonary edema following post-operative laryngospasm: a case report and review of the literature. *Am Surg*. 1993;59:443-447
5. Pang WW, Chang DP, Lin CH, Huang MH. Negative pressure pulmonary oedema induced by direct suctioning of endotracheal tube adapter. *Can J Anaesth*. 1998;45:785-788
6. Lang SA, Duncan PG, Shephard DA, Ha HC. Pulmonary oedema associated with airway obstruction. *Can J Anaesth*. 1990;37:210-218
7. Brander L, Kloeter U, Henzen C, Briner V, Stulz P. Right-sided pulmonary oedema. *Lancet*. 1999;354:1440
8. Taha S, Bartelmaos T, Kassas C, Khatib M, Baraka A. Complicated negative pressure pulmonary oedema in a child with cerebral palsy. *Paediatr Anaesth*. 2002;12:181-186
9. Sullivan M. Unilateral negative pressure pulmonary edema during anesthesia with a laryngeal mask airway. *Can J Anaesth*. 1999;46:1053-1056

Unilateral Negative-Pressure Pulmonary Edema in an Infant During Bronchoscopy

Shai Hannania, Michal Barak and Yeshayahu Katz

Pediatrics 2004;113:e501

DOI: 10.1542/peds.113.5.e501

Updated Information & Services

including high resolution figures, can be found at:
<http://pediatrics.aappublications.org/content/113/5/e501>

References

This article cites 9 articles, 0 of which you can access for free at:
<http://pediatrics.aappublications.org/content/113/5/e501#BIBL>

Subspecialty Collections

This article, along with others on similar topics, appears in the following collection(s):
Fetus/Newborn Infant
http://www.aappublications.org/cgi/collection/fetus:newborn_infant_sub
Pulmonology
http://www.aappublications.org/cgi/collection/pulmonology_sub

Permissions & Licensing

Information about reproducing this article in parts (figures, tables) or in its entirety can be found online at:
<http://www.aappublications.org/site/misc/Permissions.xhtml>

Reprints

Information about ordering reprints can be found online:
<http://www.aappublications.org/site/misc/reprints.xhtml>

American Academy of Pediatrics

DEDICATED TO THE HEALTH OF ALL CHILDREN™



PEDIATRICS®

OFFICIAL JOURNAL OF THE AMERICAN ACADEMY OF PEDIATRICS

Unilateral Negative-Pressure Pulmonary Edema in an Infant During Bronchoscopy

Shai Hannania, Michal Barak and Yeshayahu Katz

Pediatrics 2004;113:e501

DOI: 10.1542/peds.113.5.e501

The online version of this article, along with updated information and services, is
located on the World Wide Web at:

<http://pediatrics.aappublications.org/content/113/5/e501>

Pediatrics is the official journal of the American Academy of Pediatrics. A monthly publication, it has been published continuously since 1948. Pediatrics is owned, published, and trademarked by the American Academy of Pediatrics, 141 Northwest Point Boulevard, Elk Grove Village, Illinois, 60007. Copyright © 2004 by the American Academy of Pediatrics. All rights reserved. Print ISSN: 1073-0397.

American Academy of Pediatrics

DEDICATED TO THE HEALTH OF ALL CHILDREN™

