

# Adolescent Twin Sisters With Severe Acute Respiratory Syndrome (SARS)

N.C. Fong, MMedSc, MRCP; Y.W. Kwan, MRCP, FHKAM; Y.W. Hui, MRCP, FHKAM; L.K. Yuen, MBBS; E.K.C. Yau, MRCP, MRCPCH; C.W. Leung, FRCP, FRCPC; and M.C. Chiu, FRCP, FRCPC

**ABSTRACT.** A novel coronavirus-associated communicable respiratory disease, severe acute respiratory syndrome (SARS), spread worldwide after an outbreak in Guangdong Province of the People's Republic of China in November 2002. Since late February 2003, there has been an epidemic in Hong Kong involving both adult and pediatric patients. The clinical course, intensive care, and outcome of adolescent twin sisters with SARS are described. Adolescents infected with SARS may develop severe illness as adults, and close monitoring for disease progression in terms of both clinical and radiologic deterioration is warranted. *Pediatrics* 2004;113:e146–e149. URL: <http://www.pediatrics.org/cgi/content/full/113/2/e146>; severe acute respiratory syndrome, SARS, intensive care, adolescent.

**ABBREVIATIONS.** SARS, severe acute respiratory syndrome; CXR, chest radiograph; BiPAP, bilevel positive airway pressure; LDH, lactate dehydrogenase; RT-PCR, reverse-transcriptase polymerase chain reaction; SARS-CoV, SARS-associated coronavirus; NPA, nasopharyngeal aspirate; IFA, indirect fluorescent antibody; CT, computed tomography.

## CASE REPORTS

Previously healthy 15-year-old twin sisters were hospitalized on March 14, 2003, because of a 1-day history of fever and other symptoms. Their mother, a health care assistant in a medical ward with the first large-scale outbreak of severe acute respiratory syndrome (SARS) in Hong Kong,<sup>1</sup> was diagnosed as having SARS a few days before the twins' admission. Their clinical course and outcome are described.

### Case 1

The elder twin presented with fever, headache, chills, malaise, myalgia, sore throat, nausea, and unproductive cough the day before admission (day 1 of illness). Her mother had onset of symptoms of SARS on March 8, 2003, and had last contact with the twins on March 12, 2003. Physical examination of the elder twin on day 2 revealed an oral temperature of 40°C and normal chest findings. The laboratory findings are summarized in Table 1. Her chest radiograph (CXR) on day 2 showed focal consolidation of the left lower zone. She was empirically treated with cefotaxime and clarithromycin.

The patient had persistent fever with development of dyspnea and oxygen desaturation necessitating oxygen supplementation through a nasal cannula on day 7 of illness. She was administered intravenous ribavirin (8 mg/kg every 8 hours) and hydrocortisone (2 mg/kg every 6 hours) when clinical deterioration was evident. Despite this treatment, she remained dyspneic with increased fatigability. A CXR repeated on day 8 revealed bilateral

consolidation. Repeat laboratory findings are shown in Table 1. Antibiotic therapy was changed to vancomycin and imipenem. A dose of methylprednisolone (20 mg/kg) was given intravenously. Spontaneous-mode bilevel positive airway pressure (BiPAP) ventilation and increased oxygen flow to 5 L per minute were commenced to keep the oxygen saturation at 94% to 96%.

On day 10, she deteriorated further despite BiPAP support. She was electively intubated and put on pressure-control ventilation with midazolam and atracurium infusion. The partial pressure of oxygen/oxygen concentration ratio was 256 mm Hg. Her preintubation CXR was as shown (Fig 1A). She improved gradually and became afebrile on day 11. On day 12, the highest lactate dehydrogenase (LDH) level and lowest lymphocyte count were registered (Table 1), which coincided with the time of maximal clinical severity. However, it was also possible that the lymphopenia might be related to the lympholytic effect of methylprednisolone. She was extubated on day 13, and oxygen supplementation was discontinued on day 20. Transient blood pressure elevation to 160/90 mm Hg, sinus bradycardia of 40 beats per minute, and mild hypokalemia were observed for a few days after the administration of methylprednisolone without cardiovascular sequelae. Transient water retention occurred and resolved on day 17 after spontaneous diuresis. No adverse event related to ribavirin, except possibly sinus bradycardia, was noted. Vancomycin and imipenem were discontinued after 1 week, and a repeat blood culture was negative. Ribavirin was administered for 2 weeks, and steroid was tapered over 3 weeks. Her albumin level dropped from 37 to 24 g/L over 2 weeks, and her body weight decreased from 52 to 44 kg. Reverse-transcriptase polymerase chain reaction (RT-PCR) for SARS-associated coronavirus (SARS-CoV) was positive in the nasopharyngeal aspirate (NPA) up to day 16.<sup>2</sup> She was discharged on day 23, and the antibody titer to SARS-CoV as measured by indirect fluorescent antibody (IFA) assay increased from <25 to 400 by day 26.<sup>2</sup> Mild decrease in exercise tolerance was still evident on follow-up 3 weeks after discharge. Computed tomography (CT) of the chest performed on day 51 showed ground-glass appearance in both lung fields (Fig 2). However, lung-function tests performed on day 87 were normal.

### Case 2

The younger twin had onset of symptoms similar to those of her twin sister on March 13, 2003. Physical examination on day 2 of illness revealed a fever of 38.6°C and normal chest findings. Her laboratory findings at admission are summarized in Table 1. CXR on day 2 showed focal consolidation of the left lower zone. She was empirically treated with cefotaxime and clarithromycin.

She remained febrile at 39.7°C and developed dyspnea on day 5. Oxygen, intravenous ribavirin, and hydrocortisone were commenced. CXR repeated on day 6 showed bilateral focal consolidation. Repeat laboratory findings are as shown in Table 1. A single dose of methylprednisolone (15 mg/kg) was administered. Fever subsided within 24 hours, but dyspnea worsened. Spontaneous-mode BiPAP ventilation was instituted on day 8, and antibiotic coverage was switched to vancomycin and imipenem. Her CXR on day 11 was as shown in Fig 1B. She improved gradually, and BiPAP and oxygen supplementation was discontinued on days 12 and 16, respectively.

Transient hypertension, sinus bradycardia, fluid retention, and hypokalemia also were observed. The highest LDH level and the lowest lymphocyte count was detected on day 9 (Table 1), again coinciding with maximal disease severity and administration of methylprednisolone. Her albumin level dropped from 41 to 26 g/L over 2 weeks, and her body weight decreased from 68 to 60

From the Department of Paediatrics and Adolescent Medicine, Princess Margaret Hospital, Hong Kong.

Received for publication Jul 16, 2003; accepted Oct 15, 2003.

Address correspondence to N.C. Fong, MMedSc, MRCP, Department of Paediatrics and Adolescent Medicine, Princess Margaret Hospital, Princess Margaret Hospital Rd, Lai Chi Kok, Kowloon, Hong Kong [Special Administrative Region]. E-mail: naichung@hotmail.com

PEDIATRICS (ISSN 0031 4005). Copyright © 2004 by the American Academy of Pediatrics.

**TABLE 1.** Summary of Laboratory Findings for Cases 1 and 2

	Case 1				Case 2			
	On Admission	Clinical Deterioration	Maximal Disease Severity	Convalescence	On Admission	Clinical Deterioration	Maximal Disease Severity	Convalescence
	Day 2*	Day 8	Day 12	Day 26	Day 2	Day 6	Day 9	Day 26
Total white blood cell (4.0–10.0 × 10 <sup>9</sup> /L)	5.1	3.3	8.6	9.4	6.7	2.0	8.6	6.2
Neutrophil (2.0–7.0 × 10 <sup>9</sup> /L)	3.8	2.5	7.8	7.7	5.4	1.2	7.7	4.1
Lymphocyte (1.0–3.0 × 10 <sup>9</sup> /L)	0.9	0.6	0.3	1.2	0.9	0.4	0.4	1.3
C-reactive protein	Normal				Normal			
ALT (1–40 U/L)	11	65	47	28	31	95	60	28
Albumin (36–48 g/L)	37	35	30	37	41	33	30	39
LDH (110–230 U/L)	175	414	431	217	150	360	392	228
CPK (42–245 U/L)	59	59			46	90		
Troponin I		Normal				Normal		
Renal-function tests	Normal	Normal			Normal	Normal		
Clotting profile	Normal	Normal			Normal	Normal		
Blood culture	Negative	Negative	Negative		Negative	Negative	Negative	
NPA × IF†	Negative				Negative			
Antibody titer‡				No rise				No rise
SARS-CoV (IFA)	<25			400	<25			200
Viral culture§		Negative				Negative		
RT-PCR		Negative	Positive			Negative	Negative	

ALT indicates alanine aminotransferase; CPK, creatine phosphokinase.

\* Days since symptom onset.

† Nasopharyngeal aspirate for immunofluorescence (IF) of influenza A and B, adenovirus, respiratory syncytial virus, and parainfluenza virus types 1, 2, and 3 antigens.

‡ Antibody titers to influenza A and B, adenovirus, respiratory syncytial virus, parainfluenza virus types 1, 2, and 3, *Mycoplasma pneumoniae*, *Chlamydia pneumoniae*, and *Legionella pneumophila*.

§ Viral culture of NPA, stool, and urine.

|| RT-PCR for SARS-CoV.

kg. She developed transient emotional lability and incoherent speech the day before discharge, which resolved after counseling by clinical psychologist and her mother. RT-PCR for SARS-CoV was repeatedly negative in the NPA, stool, and urine. She was discharged on day 23, and her antibody titer to SARS-CoV increased from <25 to 200 by day 26. She also had a mild decrease in exercise tolerance 3 weeks after discharge. CT of her chest on day 51 showed similar findings as that of her twin sister, and lung-function tests were normal.

## DISCUSSION

As of June 23, 2003, 8461 cases of SARS with 804 deaths in 29 countries had been reported to the World Health Organization, and in Hong Kong, 1755 cases had been reported since late February 2003.<sup>3</sup> There are 6 case series reported by physicians from Hong Kong and Canada.<sup>1,2,4–7</sup> A novel coronavirus, named SARS-CoV, was found to be the cause of SARS.<sup>2,8–10</sup> Our 2 adolescent patients fulfilled the surveillance case definition for SARS as promulgated by the World Health Organization and Centers for Disease Control and Prevention.<sup>11,12</sup>

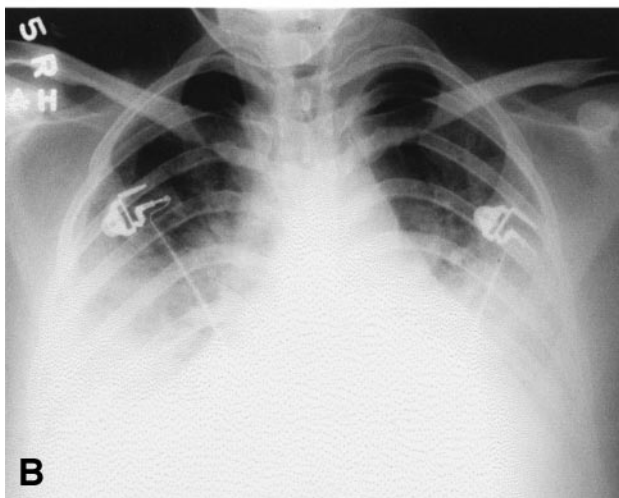
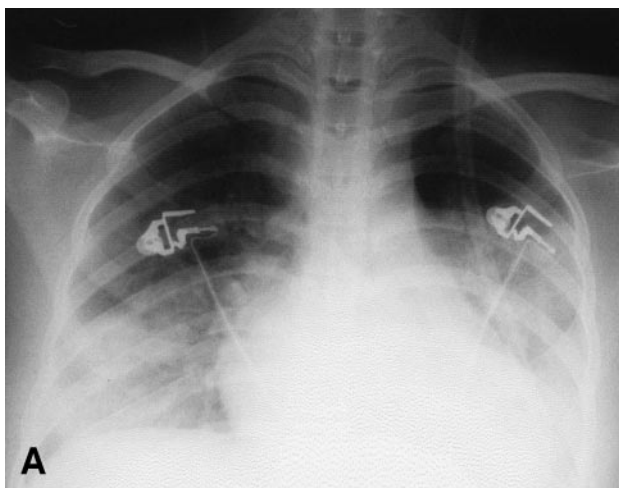
Fever, chills, rigor, myalgia, unproductive cough, headache, and dizziness are common symptoms in adults and some older children with SARS.<sup>1,2,4–7</sup> The clinical presentation of these 2 girls is indistinguishable from that of adults. Lymphopenia and elevated alanine aminotransferase and LDH levels, which were described in both adult and pediatric series, were similarly present.<sup>1,2,4–7</sup>

Our patients deteriorated on day 8 and 6 of illness, respectively, which is similar to the mean time to deterioration of between 6.5 and 8.3 days as reported

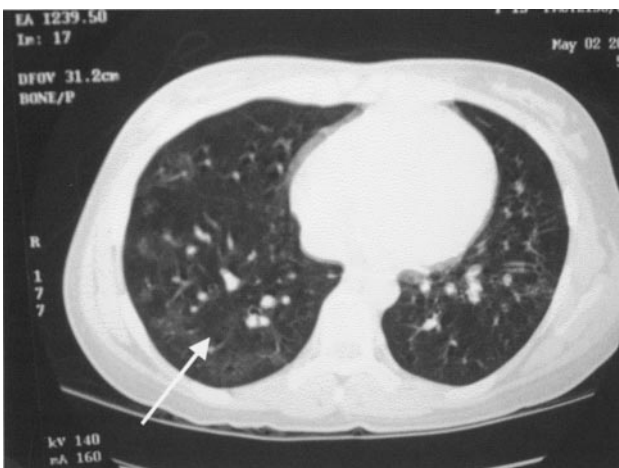in the adult series.<sup>1,2</sup> Most identified adult patients and some pediatric patients had abnormal CXRs with unilateral peripheral air-space consolidation at presentation, which progressed to bilateral involvement during clinical deterioration.<sup>1,6,7</sup> In our patients, focal air-space consolidation of the left lung was noted initially, and it subsequently spread to involve the right side as well.

All microbiologic investigations for respiratory pathogens were negative. NPA for RT-PCR of SARS-CoV was positive in the elder twin only. RT-PCR for urine and stool specimens were all negative for both patients. RT-PCR for SARS-CoV has a high specificity, but the sensitivity was only 50% to 55%.<sup>2</sup> The IFA assay is more sensitive and highly specific. A significant rise in convalescent serum titer is currently the definitive diagnostic tool for SARS, whereas viral culture (although the gold standard) requires a more-sophisticated technique and is often not sensitive enough for confirmation. The need for a reliable, rapid diagnostic test to aid clinical decision cannot be overemphasized. This is the focus of current intense research.

These 2 patients developed hypoxemia and respiratory exhaustion without other major organ involvement as the disease progressed. Although the elder sister eventually required invasive mechanical ventilation, the partial pressure of oxygen/oxygen concentration ratio was 256 mm Hg, which did not fulfill the criteria for diagnosis of acute respiratory distress syndrome (ARDS).<sup>13</sup> She was stabilized after



**Fig 1.** A, CXR (day 11) of case 1 shows bilateral consolidation. B, CXR (day 11) of case 2 shows bilateral consolidation and reduced lung volumes.



**Fig 2.** CT of the chest (day 51) of case 1 shows ground-glass appearance in both lung fields.

receiving ribavirin, steroid, and low-setting ventilatory support, although the recovery might have been spontaneous and unrelated to antiviral and steroid therapy. Children <12 years old were found to have a mild disease course.<sup>6,7</sup> However, these 2 adolescent girls had progressive deterioration, although appar-

ently less severe than some adult cases. Close monitoring of adolescent patients for clinical and radiologic deterioration is warranted.

The high gas flow of BiPAP ventilation is believed to be a potential cause for aerosolization of respiratory secretions that may endanger the health care workers.<sup>1,14,15</sup> High-risk procedures such as intubation and tracheal suction during ventilator therapy also may promote the spread of infective droplets. We had performed these procedures safely in single negative-pressure isolation rooms with our staff protected by personal protection equipment, which included caps, goggles, face shields, N95 masks (particulate respirators), gowns, and gloves. Intubation was performed as an elective procedure with adequate sedation and muscle relaxation. The ventilator circuit was modified with 2 in-line bacterial-viral filters, 1 connected between the endotracheal tube and the Y piece and the other at the expiratory limb before entering the ventilator. The expired gas was directed to a wall-mounted vacuum scavenging system. Suctioning of the endotracheal tube was performed within a closed system. No staff members were infected while taking care of these 2 patients. We feel that the above-mentioned infection-control measures could be recommended for managing SARS patients in the critical care setting.

Similar to adult patients, many children and adolescents with SARS were treated empirically with broad-spectrum antibiotics, ribavirin, and systemic steroids.<sup>1,6,7</sup> When they deteriorated with respiratory compromise, their condition generally improved, although not instantaneously, with methylprednisolone therapy and ventilatory support. However, their improvement might have been spontaneous and unrelated to the administered therapies. The rationale of using ribavirin and steroid was adopted from its initial promising effect in treating adult SARS patients. The choice of ribavirin was made on empirical grounds, because it was the most broad-spectrum antiviral agent available on the market. Sinus bradycardia, hypertension, hyponatremia, hypokalemia, hyperglycemia, and water retention, which are known to be associated with methylprednisolone treatment, were noted.<sup>16,17</sup> Sinus bradycardia, however, can also be related to the use of ribavirin.<sup>18</sup> These adverse effects subsided without sequelae after a few days without intervention. The younger sister had labile mood and incoherent speech when the steroid dosage was being tapered. Whether this was related to the side effect of steroid administration or withdrawal was difficult to ascertain. However, it was more likely to be multifactorial in etiology, including situational reaction to a life-threatening illness, prolonged hospitalization, separation anxiety, and the putative psychotropic effect of the high-dose steroid.

Both patients lost 8 kg during the course of illness, and marked drops in albumin levels were noted also. This is indirect evidence that SARS-CoV can result in an illness that is highly catabolic. The fundamental pathophysiology of this new viral illness requires additional elucidation. Reduced exercise tolerance was noted on follow-up, and CT of chest performed



7 weeks after disease onset still showed ground glass appearance in both lung fields. The clinical significance and long-term evolution of this radiologic finding needs to be determined. Fortunately, the lung-function tests in both patients have been normal.

### CONCLUSIONS

Our adolescent twin sisters had advanced SARS similar to many adult patients. Close monitoring of adolescent patients for clinical and radiologic deterioration is warranted. The efficacy of ribavirin and steroid has not been well studied and requires additional evaluation in randomized, controlled trials. Studies with larger cohorts are necessary for determining the full spectrum of disease manifestations, the natural course of illness, and the prognosis of SARS in various age groups of children.

### REFERENCES

1. Lee N, Hui D, Wu A, et al. A major outbreak of severe acute respiratory syndrome in Hong Kong. *N Engl J Med.* 2003;348:1986–1994
2. Peiris JSM, Lai ST, Poon LLM, et al. Coronavirus as a possible cause of severe acute respiratory syndrome. *Lancet.* 2003;361:1319–1325
3. World Health Organization. Cumulative number of reported probable cases of SARS. Available at: [www.who.int/csr/sars/country/2003.06.23/en/print.html](http://www.who.int/csr/sars/country/2003.06.23/en/print.html). Accessed June 23, 2003
4. Tsang KW, Ho PL, Ooi GC, et al. A cluster of cases of severe acute respiratory syndrome in Hong Kong. *N Engl J Med.* 2003;348:1977–1985
5. Poutanen SM, Low DE, Henry B, et al. Identification of severe respiratory syndrome in Canada. *N Engl J Med.* 2003;348:1995–2005
6. Hon KLE, Leung CW, Cheng WTF, et al. Clinical presentations and outcome of severe acute respiratory syndrome in children [research letters]. *Lancet.* 2003;361:1701–1703
7. Chiu WK, Cheung PCH, Ng KL, et al. Severe acute respiratory syndrome in children: experience in a regional hospital in Hong Kong. *Pediatr Crit Care Med.* 2003;4:279–283
8. Ksiazek TG, Erdman D, Goldsmith C, et al. A novel coronavirus associated with severe acute respiratory syndrome. *N Engl J Med.* 2003;348:1953–1966
9. Drosten C, Gunther S, Preiser W, et al. Identification of a novel coronavirus in patients with severe acute respiratory syndrome. *N Engl J Med.* 2003;348:1967–1976
10. Falsey AR, Walsh EE. Novel coronavirus and severe acute respiratory syndrome [commentary]. *Lancet.* 2003;361:1312–1313
11. Centers for Disease Control and Prevention. Updated interim U.S. case definition for severe acute respiratory syndrome (SARS). Available at: [www.cdc.gov/ncidod/sars/pdf/sars-casedefinition.pdf](http://www.cdc.gov/ncidod/sars/pdf/sars-casedefinition.pdf). Accessed June 23, 2003
12. World Health Organization. Case definitions for surveillance of severe acute respiratory syndrome (SARS). Available at: [www.who.int/csr/sars/casedefinition/en](http://www.who.int/csr/sars/casedefinition/en). Accessed June 23, 2003
13. Bernard GR, Artigas A, Brigham KL, et al. Report of the American-European consensus conference on ARDS: definitions, mechanisms, relevant outcomes and clinical trial coordination. The Consensus Committee. *Intensive Care Med.* 1994;20:225–232
14. Hospital Authority. HA information on management of severe acute respiratory syndrome. Available at: [www.ha.org.hk/hesd/nsapi/?Mival=ha.view\\_content&c\\_id=122711&lang=E](http://www.ha.org.hk/hesd/nsapi/?Mival=ha.view_content&c_id=122711&lang=E). Accessed June 23, 2003
15. Ho W; Hong Kong Hospital Authority Working Group on SARS, Central Committee of Infection Control. Guidelines on management of severe acute respiratory syndrome (SARS) [commentary]. *Lancet.* 2003; 361:1313–1315
16. Pudil R, Hrnčir Z. Severe bradycardia after a methylprednisolone “minipulse” treatment. *Arch Intern Med.* 2001;161:1778–1779
17. Tvede N, Nielsen LP, Andersen V. Bradycardia after high-dose methylprednisolone therapy. *Scand J Rheumatol.* 1986;15:302–304
18. Rebetron and ribavirin [package inserts]. Kenilworth, NJ: Schering Corporation; 2002

**Adolescent Twin Sisters With Severe Acute Respiratory Syndrome (SARS)**  
N.C. Fong, Y.W. Kwan, Y.W. Hui, L.K. Yuen, E.K.C. Yau, C.W. Leung and M.C.  
Chiu  
*Pediatrics* 2004;113:e146  
DOI: 10.1542/peds.113.2.e146

**Updated Information & Services**

including high resolution figures, can be found at:  
<http://pediatrics.aappublications.org/content/113/2/e146>

**References**

This article cites 13 articles, 0 of which you can access for free at:  
<http://pediatrics.aappublications.org/content/113/2/e146#BIBL>

**Subspecialty Collections**

This article, along with others on similar topics, appears in the following collection(s):  
**Adolescent Health/Medicine**  
[http://www.aappublications.org/cgi/collection/adolescent\\_health:medicine\\_sub](http://www.aappublications.org/cgi/collection/adolescent_health:medicine_sub)  
**Infectious Disease**  
[http://www.aappublications.org/cgi/collection/infectious\\_diseases\\_sub](http://www.aappublications.org/cgi/collection/infectious_diseases_sub)

**Permissions & Licensing**

Information about reproducing this article in parts (figures, tables) or in its entirety can be found online at:  
<http://www.aappublications.org/site/misc/Permissions.xhtml>

**Reprints**

Information about ordering reprints can be found online:  
<http://www.aappublications.org/site/misc/reprints.xhtml>

American Academy of Pediatrics

DEDICATED TO THE HEALTH OF ALL CHILDREN™



# PEDIATRICS®

OFFICIAL JOURNAL OF THE AMERICAN ACADEMY OF PEDIATRICS

**Adolescent Twin Sisters With Severe Acute Respiratory Syndrome (SARS)**  
N.C. Fong, Y.W. Kwan, Y.W. Hui, L.K. Yuen, E.K.C. Yau, C.W. Leung and M.C.  
Chiu

*Pediatrics* 2004;113:e146  
DOI: 10.1542/peds.113.2.e146

The online version of this article, along with updated information and services, is  
located on the World Wide Web at:

<http://pediatrics.aappublications.org/content/113/2/e146>

Pediatrics is the official journal of the American Academy of Pediatrics. A monthly publication, it has been published continuously since 1948. Pediatrics is owned, published, and trademarked by the American Academy of Pediatrics, 141 Northwest Point Boulevard, Elk Grove Village, Illinois, 60007. Copyright © 2004 by the American Academy of Pediatrics. All rights reserved. Print ISSN: 1073-0397.

American Academy of Pediatrics

DEDICATED TO THE HEALTH OF ALL CHILDREN™

