

Henoch-Schonlein Purpura Following a Meningococcal Vaccine

Emily M. Lambert, MSV*; Anne Liebling, MD*‡§; Earl Glusac, MD*||¶; and Richard J. Antaya, MD*‡¶¶

ABSTRACT. We report a 17-year-old girl who developed Henoch-Schonlein purpura 10 days after receiving a meningococcal vaccine (Menomune). To our knowledge, this is the first case report of Henoch-Schonlein purpura temporally associated with the tetravalent serogroups A, C, W-135, and Y meningococcal vaccine administered in the United States. *Pediatrics* 2003;112:e491–e494. URL: <http://www.pediatrics.org/cgi/content/full/112/6/e491>; *Henoch-Schonlein purpura, meningococcus, Meningitec, vaccine, leukocytoclastic vasculitis, vasculitis.*

ABBREVIATIONS. HSP, Henoch-Schonlein purpura; LCV, leukocytoclastic vasculitis; IgA, immunoglobulin A.

Henoch-Schonlein purpura (HSP) is a form of systemic leukocytoclastic vasculitis (LCV) characterized by the deposition of immunoglobulin A (IgA)-containing immune complexes in tissue. A meningococcal capsular polysaccharide vaccine has been administered for the past 30 years. The Advisory Committee on Immunization Practices currently recommends that colleges inform incoming students, particularly those who plan to reside in dormitories and face an increased risk of meningococcal disease compared with the general population, about the disease and the availability of a safe and effective vaccine.

CASE REPORT

A healthy 17-year-old girl with no significant medical history presented with 5 days of a nonpruritic eruption that began on her ankles and spread rapidly to her legs and thighs. She denied any new contacts or medications and had started taking Viactiv, a calcium supplement, 1 week before the onset of the rash. She received the Menomune meningococcal polysaccharide vaccine, groups A, C, Y, and W-135 (Aventis Pasteur, Swiftwater, PA), 10 days before the onset of the eruption.

At presentation, a physical examination revealed an otherwise well teenager with multiple purpuric papules, some with darker centers and purpuric halos and others with central ulceration on the bilateral lower extremities, buttocks, volar hands, and left elbow. She denied having abdominal pain, hematuria, fever, cough, or change in bowel movements. In the next couple of weeks, new lesions developed on bilateral elbows and ankles, and the existing lesions progressed to hemorrhagic bullae and then to more prominent purpuric bullae and ulcers (Fig 1). Clobetasol cream twice a day, rest, and lower extremity elevation were prescribed.

From the Departments of †Pediatrics, §Internal Medicine, ||Pathology, and ¶Dermatology, *Yale University School of Medicine, New Haven Connecticut.

Received for publication Oct 14, 2002; accepted Aug 21, 2003.

Address correspondence to Richard J. Antaya, MD, Department of Dermatology, Yale University School of Medicine, P.O. Box 208059, 333 Cedar St, LCI 501 New Haven, CT 06520-8059. E-mail: richard.antaya@yale.edu
PEDIATRICS (ISSN 0031 4005). Copyright © 2003 by the American Academy of Pediatrics.

Initially, she was without rheumatologic complaints, but polyarthritis and bilateral lower extremity edema and pain with difficulty walking at the end of the day developed over the next week. The preexisting treatment regimen was augmented with hydrocolloid dressing (DuoDerm Extra Thin) over the ulcers and mild compression stockings.

The original ankle skin biopsy demonstrated an infiltrate of neutrophils with karyorrhectic debris and fibrin within and around the walls of superficial venules typical of LCV (Fig 2 A). A subsequent lesional skin biopsy taken for immunofluorescence revealed brightly positive granular staining surrounding and within superficial dermal vessel walls with IgA, consistent with HSP (Fig 2 B).

The initial complete blood count, chemistries, liver enzyme tests, and erythrocyte sedimentation rate were normal. Hepatitis C virus antibody and antinuclear antibody were negative. The urinalysis was without blood, protein, or casts. Throat culture was negative for group A β -hemolytic streptococcus. Two weeks after disease presentation, a repeat urinalysis revealed a large amount of blood (performed when the patient was not menstruating). A hospital admission was deemed necessary because of the severity of the skin lesions and the debilitating arthritis.

Although hospitalized, the patient had normal vital signs, mild left upper quadrant abdominal tenderness, and cervical lymphadenopathy. Chest radiograph, complete blood count, electrolytes, erythrocyte sedimentation rate, creatine phosphokinase, and complement levels were normal. Stool guaiac, antinuclear antibody, antineutrophil cytoplasmic antibodies, cryoglobulins, Lyme titers, and rheumatoid factor were negative. A repeat urinalysis was negative for blood, protein, and casts. She was treated with prednisone, 60 mg daily, and nonsteroidal antiinflammatory agents for her severe skin involvement and arthritis. The joint symptoms improved, and the skin lesions stopped progressing. She was discharged from the hospital 2 days after admission.

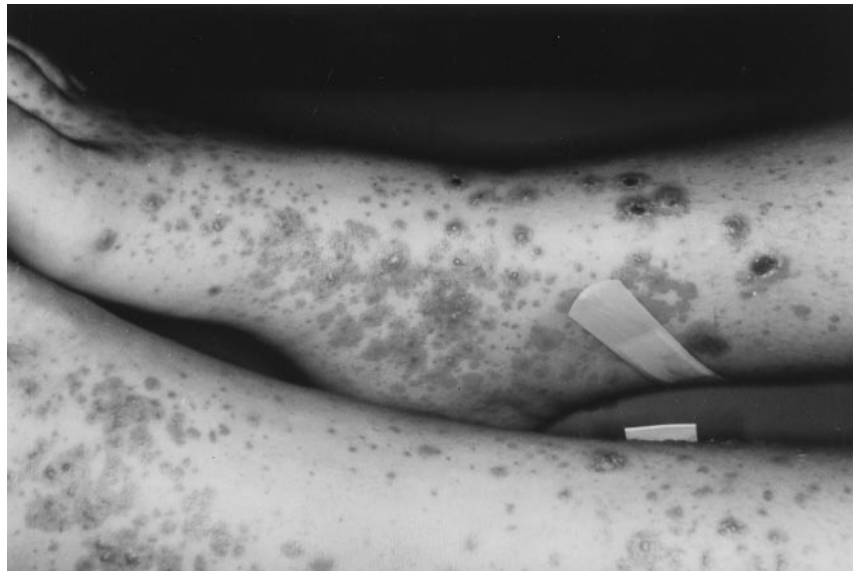Treatment with high-dose prednisone was continued for 2 weeks and then slowly tapered over 6 weeks. Her ulcers healed slowly in the weeks after the hospital admission; a few minor purpuric papules on the ankles and feet persisted but resolved with topical clobetasol.

Three months after the immunization, the patient developed 3+ proteinuria and 3+ hematuria but maintained normal blood pressure. Eight months after vaccination she presented with significant proteinuria (1.320 g/24 hours and 1.1 g/24 hours creatinine). A renal biopsy demonstrated mesangial proliferative glomerulonephritis with IgA deposits compatible with mild HSP renal involvement. Maxepa was begun, and 2 months later a follow-up 24-hour urinalysis revealed creatinine of 0.9 g, blood urea nitrogen of 20 g, and urine protein of 1.030 g. The patient has mild nephropathy thought to be secondary to HSP. It has not worsened over the ensuing several months and is not expected to worsen in the future.

DISCUSSION

HSP is the most common type of vasculitis diagnosed in childhood and is seen less frequently in adults. The main clinical manifestations of HSP include palpable purpura, arthritis, abdominal pain, gastrointestinal bleeding, and nephritis. The symptoms are caused by a LCV caused by IgA deposits in vessel walls. Although the precise etiology of HSP is unknown, IgA is certainly involved. There are increased serum IgA concentrations, increased serum

Fig 1. Multiple purpuric papules, some with darker centers and purpuric halos and others with central ulceration, on the bilateral lower extremities.



polymeric IgA, circulating immune complexes that contain IgA, and IgA rheumatoid factor demonstrable in most cases.¹

The mean age of children affected by HSP is 6 years, and 90% of children afflicted with HSP are <10 years old.² HSP is most common in the fall and winter and frequently follows an upper respiratory infection. It has been inconclusively attributed to pharyngitis caused by *Streptococcus pyogenes*, hepatitis B infection, varicella infection, human immunodeficiency virus, adenovirus, mycoplasma, herpes simplex virus, *Helicobacter pylori*, *Toxocara canis*, human parvovirus B19, and coxsackie virus as well as drugs and environmental factors.^{3,4}

The tetravalent serogroups A, C, Y, and W-135 meningococcus vaccine is administered in the United States. The vaccine contains specific purified bacterial capsular polysaccharides.⁵ Menomune, the meningococcal polysaccharide vaccine, groups A, C, Y, and W-135, involved in this report, is indicated for a select population >2 years old to prevent *Neisseria meningitidis* meningitis. Serogroups B, C, and Y are equally responsible for most sporadic meningococcal disease in the United States today. Although serogroup B was responsible for epidemic meningococcal disease in the 1990s, serogroup C is implicated in most North American meningococcal epidemics and is the most common serogroup to affect young adults.⁶

Standard vaccination of US inhabitants is not recommended, because there is a low disease incidence, vaccine protection is short, and the vaccine is not very effective in children <2 years old, who are most likely to have sporadic disease. The meningococcal vaccine is recommended for use to prevent and control serogroup C meningococcal outbreaks; for people with terminal component complement deficiencies; for people with anatomic or functional asplenia; travelers to countries with hyperendemic meningitis; and individuals with occupational exposure to *N. meningitidis* aerosol. Most germane to this report, the Advisory Committee on Immunization Practices recommends that college students (especially those

planning to reside in dormitories) and their parents be informed about their increased risk for meningococcal disease and the existence of a safe and effective vaccine.⁷

With >6 million meningococcal vaccinations administered, there have been very few reports of serious adverse events. Side effects consist mainly of tenderness and erythema at the injection site,⁸ transient fevers,⁹ headache, malaise, dizziness, and chills seen in a minority of patients.^{10,11} There have not been any previous reports of temporally associated HSP. Unexplained IgA nephropathy has been associated with Menomune vaccinations on rare occasions (Aventis Pasteur Inc, unpublished data, 2003, available at www.micromedex.com). This association is of particular interest to this report, because HSP and IgA nephropathy are associated with identical histologic findings in the kidney.

In the case we report, the patient was 17 years old, did not have a preceding upper respiratory infection, and developed HSP at the beginning of the summer. The temporal relationship of the development of HSP and the Menomune meningococcal polysaccharide vaccine, groups A, C, Y, and W-135, are notable. There was a 2001 report from the United Kingdom of a case of HSP that was temporally associated with the serogroup C meningococcal conjugate vaccine C (Meningitec).¹² There have been several reports of vasculitis following various immunizations. HSP has been associated with the influenza vaccine¹³ and measles vaccine.¹⁴ LCV has been associated with the pneumococcal vaccine,¹⁵ and vasculitis has been reported after hepatitis B and bacillus Calmette-Guérin vaccines^{16,17} Although a relationship between the vaccination and the development of HSP may be coincidental, past reports of temporally associated vaccinations and vasculitis without other identifiable etiologies or historical factors set a precedent for association, albeit with different vaccines and antigens.

Previous observations suggest that there may be an immunopathogenic association between meningococcal diseases and vasculitis. There have been

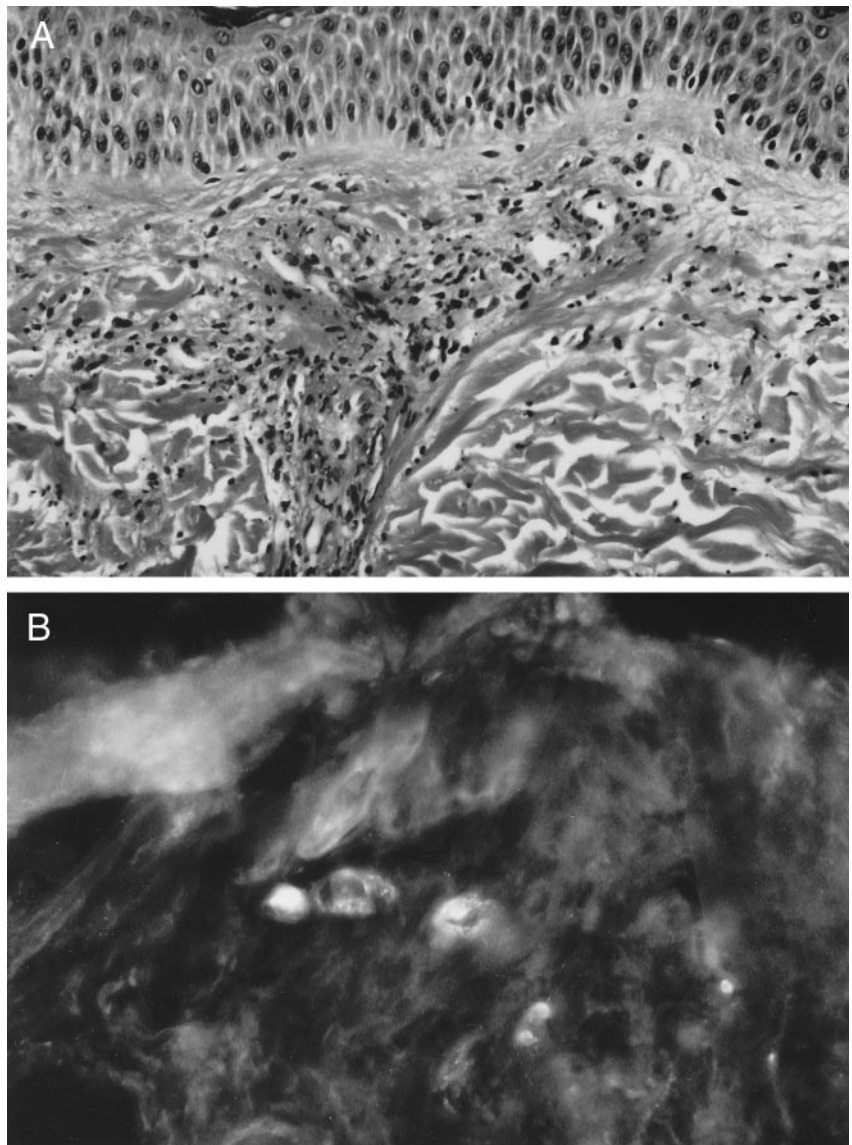


Fig 2. (A) Biopsy of lesional skin of the leg shows superficial perivascular neutrophils with karyorrhectic debris, associated with fibrin in and around venular walls, typical of LCV (hematoxylin/eosin, original magnification $\times 20$). (B) Direct immunofluorescence of lesional skin demonstrates bright granular labeling surrounding and within venular walls with IgA (original magnification $\times 40$)

multiple reports of cutaneous LCV associated with chronic meningococemia. Although chronic meningococemia is associated with intermittent bacteremia and antibiotic administration may impede a positive bacterial culture, nearly all reported skin lesion cultures have been negative for *N. meningitidis*. Attempts to demonstrate antigens and IgA specificity have been similarly futile.¹⁸ These aseptic lesions suggest an immunologic mechanism rather than direct bacterial invasion.¹⁹ Immune complexes have been demonstrated in the lesional skin and synovial fluid of patients with acute meningococcal meningitis who developed cutaneous lesions and arthritis. A decrease in circulating meningococcal antigen titer, followed by a rise in antibody level to the same antigen immediately subsequent to the onset of skin lesions, was also observed in some of these patients.²⁰ Although endotoxins and disseminated intravascular coagulation may be responsible for the vasculitis associated with acute meningococcal meningitis, this evidence of decreasing antigens and increasing antibodies supports the proposed hypothe-

sis of vasculitis resulting from an immunologic response to meningococcal antigen, either naturally or possibly (as in this case) iatrogenically.

The temporal association between the meningococcal vaccine and the development of HSP is notable. We cannot explain the immunopathogenic link between the meningococcal polysaccharide vaccine, groups A, C, Y, and W-135, and vasculitis, but we think that practitioners should be aware of this possible complication and evaluate further cases of post-vaccination vasculitis with causality in mind. However, HSP is extremely rarely associated with the meningococcal vaccine and should not affect vaccine usage.

REFERENCES

1. Saulsbury FT. Henoch-Schonlein purpura. *Curr Opin Rheumatol.* 2001; 13:35-40
2. Meadow SR, Glasgow GF, White RHR, et al. Schonlein nephritis. *Q J Med.* 1972;41:241-258
3. Saulsbury FT. Henoch-Schonlein purpura in children: report of 100 patients and a review of the literature. *Medicine.* 1999;78:395-409

4. Rai A, Nast C, Adler S. Henoch-Schonlein purpura nephritis. *J Am Soc Nephrol*. 1999;10:2637-2644
5. American Medical Association. *Council on Drugs: AMA Drug Evaluation*. 4th ed. American Medical Association: Chicago, IL; 1980
6. Centers for Disease Control and Prevention. Prevention and control of meningococcal disease-recommendations of the Advisory Committee on Immunization Practices (ACIP). *MMWR Recomm Rep*. 2000;49(RR-7): 1-10
7. Centers for Disease Control and Prevention. Meningococcal vaccines. *Morb Mortal Wkly Rep*. 1985;34:255-259
8. Scheifele DW, Bjornson G, Boraston S. Local adverse effects of meningococcal vaccine. *Can Med Assoc J*. 1994;150:14-15
9. Recommendation of the Advisory Committee on Immunization Practices (ACIP). Control and prevention of meningococcal disease and control and prevention of serogroup C meningococcal disease: evaluation and management of suspected outbreaks. *MMWR Recomm Rep*. 1997;46(RR-5):1-10
10. Hankins WA, Gwaltney JM Jr, Hendley JO, Farquhar JD, Samuelson JS. Clinical and serological evaluation of a meningococcal polysaccharide vaccine groups A, C, Y and W-135. *Proc Soc Exp Biol Med*. 1982;169:54-57
11. Ball R, Braun MM, Mootrey GT. Vaccine Adverse Event Reporting System Working Group. Safety data on meningococcal polysaccharide vaccine from the Vaccine Adverse Event Reporting System. *Clin Infect Dis*. 2001;32:1273-1280
12. Courtney PA, Patterson RJ, Lee RJE. Henoch-Schonlein purpura following meningitis C vaccination. *Rheumatology*. 2001;40:345-346
13. Patel U, Bradley JR, Hamilton DV. Henoch-Schonlein purpura after influenza vaccination. *Br Med J Clin Res Ed*. 1988;296:1800
14. Mastroiacovo P. Measles vaccination and Schonlein-Henoch purpura. *Minerva Pediatr*. 1976;28:1591
15. Fox BC, Peterson A. Leukocytoclastic vasculitis after pneumococcal vaccination. *Am J Infect Control*. 1998;26:365-366
16. Le Hello C, Cohen P, Bousser MG, Letellier P, Guillemin L. Suspected hepatitis B vaccination related vasculitis. *J Rheumatol*. 1999;26:191-194
17. Watson DA. Pustular vasculitis complicating BCG vaccination. *Tuber Lung Dis*. 1992;73:126
18. Leibel RL, Fangman JJ, Ostrovsky MC. Chronic meningococemia in childhood. Case report and review of the literature. *Am J Dis Child*. 1974;127:94-98
19. Benoit FL. Chronic meningococemia. Case report and review of the literature. *Am J Med*. 1965;35:103-112
20. Greenwood BM, Whittle HC, Bryceson AD. Allergic complications of meningococcal disease. *Br Med J*. 1973;2:737-740

Henoch-Schonlein Purpura Following a Meningococcal Vaccine
Emily M. Lambert, Anne Liebling, Earl Glusac and Richard J. Antaya
Pediatrics 2003;112:e491

Updated Information & Services

including high resolution figures, can be found at:
<http://pediatrics.aappublications.org/content/112/6/e491>

References

This article cites 19 articles, 2 of which you can access for free at:
<http://pediatrics.aappublications.org/content/112/6/e491#BIBL>

Subspecialty Collections

This article, along with others on similar topics, appears in the following collection(s):
Infectious Disease
http://www.aappublications.org/cgi/collection/infectious_diseases_sub

Permissions & Licensing

Information about reproducing this article in parts (figures, tables) or in its entirety can be found online at:
<http://www.aappublications.org/site/misc/Permissions.xhtml>

Reprints

Information about ordering reprints can be found online:
<http://www.aappublications.org/site/misc/reprints.xhtml>

American Academy of Pediatrics

DEDICATED TO THE HEALTH OF ALL CHILDREN®



PEDIATRICS®

OFFICIAL JOURNAL OF THE AMERICAN ACADEMY OF PEDIATRICS

Henoch-Schonlein Purpura Following a Meningococcal Vaccine
Emily M. Lambert, Anne Liebling, Earl Glusac and Richard J. Antaya
Pediatrics 2003;112:e491

The online version of this article, along with updated information and services, is located on the World Wide Web at:

<http://pediatrics.aappublications.org/content/112/6/e491>

Pediatrics is the official journal of the American Academy of Pediatrics. A monthly publication, it has been published continuously since 1948. Pediatrics is owned, published, and trademarked by the American Academy of Pediatrics, 345 Park Avenue, Itasca, Illinois, 60143. Copyright © 2003 by the American Academy of Pediatrics. All rights reserved. Print ISSN: 1073-0397.

American Academy of Pediatrics

DEDICATED TO THE HEALTH OF ALL CHILDREN®

