

Paranasal Sinus Findings in Children During Respiratory Infection Evaluated With Magnetic Resonance Imaging

Aila Kristo, MD*; Matti Uhari, MD†; Jukka Luotonen, MD*; Petri Koivunen, MD*; Eero Ilkko, MDS; Terhi Tapiainen, MD†; and Olli-Pekka Alho, MD*

ABSTRACT. *Objective.* The spreading of acute respiratory infection into the paranasal sinuses in children is poorly defined. The main objective of this study was to evaluate the frequency and spontaneous resolution of paranasal sinus abnormalities in children with acute respiratory infection using magnetic resonance imaging (MRI).

Methods. We examined 60 children with MRI (mean age: 5.7 years) with symptoms of acute respiratory infection. Twenty-six children with major abnormalities in the first MRI scan had a follow-up MRI taken 2 weeks later.

Results. The children had had symptoms of uncomplicated acute respiratory infection for an average of 6 days before the first examination (mean duration: 6.5; standard deviation: 3.0). Approximately 60% of the children had major abnormalities in their maxillary and ethmoidal sinuses, 35% in the sphenoidal sinuses, and 18% in the frontal sinuses. The most common abnormal finding was mucosal swelling. The mean overall MRI scores correlated significantly with the symptom scores ($r_s = 0.3$). Of the individual symptoms, nasal obstruction, nasal discharge, and fever were significantly related to the MRI scores. Among the 26 children with major abnormalities in the first MRI, the findings subsequently improved significantly (mean [standard deviation] score: 12.7 [5.6] to 5.7 [5.2]), irrespective of the resolution of symptoms.

Conclusions. These observations indicate that acute respiratory infection mostly spreads into the paranasal sinuses of children in the form of mucosal edema and that these abnormalities tend to resolve spontaneously without antimicrobial treatment. *Pediatrics* 2003;111:e586–e589. URL: <http://www.pediatrics.org/cgi/content/full/111/5/e586>; sinusitis, children, acute respiratory infection, MRI.

ABBREVIATIONS. CT, computed tomography; MRI, magnetic resonance imaging; SD, standard deviation.

It is still unclear to what extent uncomplicated upper respiratory tract infections involve the paranasal sinuses in children.¹ In adults, Gwaltney et al² showed extensive radiologic changes in the nasal passages, ostiomeatal area, and sinus cavities during viral colds. It has been assumed that children

have similar changes. This hypothesis receives support from the finding of Glasier et al³ showing that almost all young children who were undergoing computed tomography (CT) examination for reasons other than sinus disease and who had had a respiratory infection in the previous 2 weeks had soft tissue changes in their sinuses. However, these children were infants and the data on infections were based on history. We wanted to evaluate the prevalence of paranasal sinus abnormalities among children with acute respiratory infections of various durations when evaluated with magnetic resonance imaging (MRI) and whether these changes resolve spontaneously.

METHODS

Subjects

The subjects were recruited from child care centers in Oulu, a Finnish city with ~120 000 inhabitants, during September to December 1999. The children participated in a trial to evaluate the effect of xyloitol on the appearance of otitis media during an upper respiratory infection.⁴ The parents were asked to bring the child to the Department of Pediatrics, Oulu University Hospital, within 96 hours after the onset of any symptoms suggestive of respiratory infection. Children aged 4 to 7 years were offered a chance to participate in the present study. MRI was conducted within the next 7 days. The exclusion criteria were acute otitis or tonsillitis; chronic sinusitis or previous sinus surgery; poor cooperation, claustrophobia, and the presence of any implanted ferrous material. The parents were informed about the survey and gave informed consent. The Ethical Committee of the Medical Faculty of the University of Oulu found the study protocol ethically acceptable. Altogether, 60 symptomatic children (27 boys and 33 girls) were enrolled (Fig 1).

Background Data

The background information of the children obtained with a questionnaire are shown in Table 1. The occurrence and duration of acute symptoms were evaluated with modified criteria developed by Jackson et al.⁵ The severity of each symptom was graded on a scale from 0 (not present) to 4 (very severe) and summed up to get the total symptom scores.

MRI Examinations

MRI was performed with an open resistive 0.23 T MRI scanner (Marconi Medical Systems, Cleveland, OH) with a head surface coil including axial and coronal T2-weighted (TR 4300 ms, TE 126 ms) fast-spin echo images with a 4-mm slice thickness.

The gradings of the paranasal sinuses were done as described earlier^{6,7} with some modifications: grade 0, ≤ 2 mm mucosal thickening; grade 1, > 2 mm mucosal thickening, one third volume loss; grade 2, one third to two thirds volume loss; and grade 3, more than two thirds volume loss or air-fluid level. The final grade for each sinus was determined from the more severely affected side, and each grade was summed up to get the total MRI scores (range: 0–24). Grade 0 and undeveloped sinuses were recorded as a normal finding, grade 1 as minor abnormality, and grades 2 to 3 as

From the Departments of *Otorhinolaryngology, †Pediatrics, and ‡Radiology, University of Oulu, Oulu, Finland.

Received for publication Aug 2, 2002; accepted Dec 11, 2002.

Address correspondence to Aila Kristo, MD, Department of Otorhinolaryngology, University of Oulu, PO Box 5000, FIN-90014 Oulu University, Finland. E-mail: aila.kristo@oulu.fi

PEDIATRICS (ISSN 0031 4005). Copyright © 2003 by the American Academy of Pediatrics.

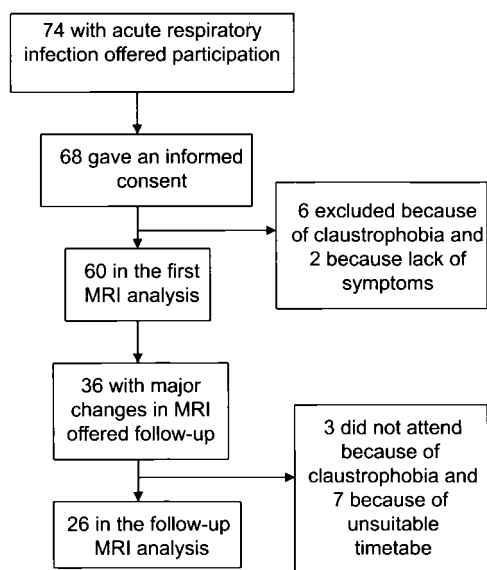


Fig 1. Study profile.

TABLE 1. Characteristics and Recent Medical History of a Series of 60 Children Who Experienced Acute Respiratory Infection

Variable	
Background characteristics	
Mean (SD) age (y)	5.7 (0.8)
Boys	27 (45%)
Allergic history	8 (14%)
Asthma	4 (7%)
Recurrent respiratory infections or otitis media	14 (24%)
Adenoidectomy	8 (30%)
Tonsillectomy	3 (5%)
Medical history for 4 wk before enrollment	
An episode of upper respiratory infection	6 (10%)
An episode of otitis media	3 (5%)
Use of antimicrobials	2 (3%)
Use of antihistamines or nasal corticosteroids	0
Use of nasal decongestants	8 (14%)

major abnormality. One radiologist (E.I.) and 1 otorhinolaryngologist (A.K.) interpreted the MRI scans blinded to the clinical data.

Follow-up Examination

In case of major abnormality in the maxillary sinus on the initial MRI scan, the child was offered the possibility of a follow-up scan 2 weeks later (Fig 1). The symptoms, medications, and acute complications between the 2 scans were recorded.

Statistics

Summary statistics are expressed as means and standard deviations (SDs). Data were analyzed using Wilcoxon ranked-pairs analysis for paired data, the Mann-Whitney *U* test for unpaired data with 2 groups, and the Kruskal-Wallis analysis of variance with more groups. The differences between proportions were tested with a χ^2 test and Fisher exact test. Correlation coefficients were calculated using Spearman rank correlation.

RESULTS

First MRI Examination

The subjects had had symptoms of an uncomplicated acute respiratory infection for an average of 6.5 days (range: 2–12 SD: 3.0), and the mean overall symptom score was 6.5 (SD: 4.0; Table 2). Typical

TABLE 2. Frequency and Severity of Symptoms During Acute Respiratory Infection in a Series of 60 Children

	<i>n</i> (%)	Mean Score* (SD)
Nasal obstruction	50 (83)	1.7 (1.1)
Nasal discharge	49 (82)	1.7 (1.1)
Cough	45 (75)	1.6 (1.2)
Sneezing	29 (48)	0.7 (0.8)
Sore throat	13 (22)	0.4 (0.8)
Headache	8 (13)	0.2 (0.5)
Chilliness	7 (12)	0.1 (0.3)
Fever	5 (8)	0.2 (0.7)

* Graded on a scale from 0 (not present) to 4 (very severe).

examples of a normal MRI scan as well as scans with minor and major abnormal findings are presented in Fig 2. Altogether, 68% of the children had major abnormalities in their paranasal sinuses (Table 3). The opacity of these abnormal findings indicated in most cases the density of mucosal swelling. The

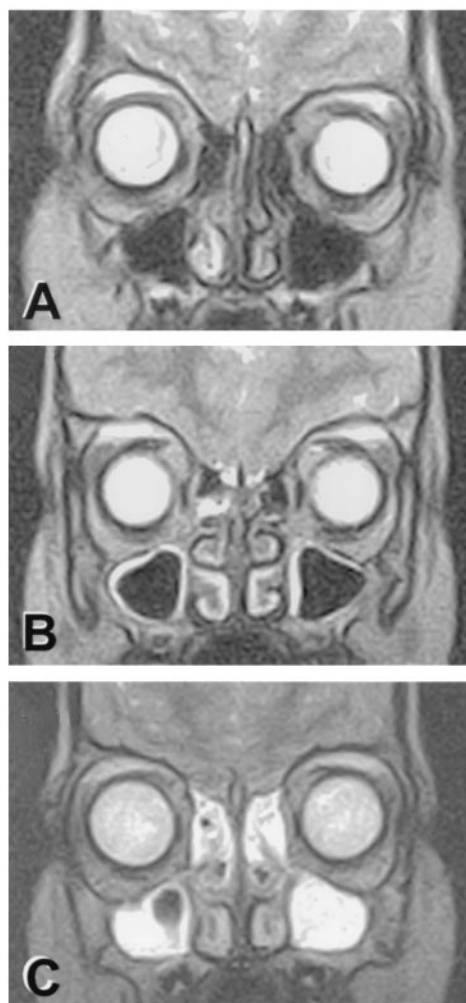


Fig 2. A representative case of normal MRI finding (A), minor abnormality MRI finding (B), and major abnormality MRI finding (C) in a series of 60 children with acute respiratory infection. The increased blood flow in the inferior turbinate on the more congested right side after the nasal cycle is well seen in A as well as the mucosal edema in both maxillary sinuses and right ethmoidal sinus in B and major abnormal changes in ethmoidal and maxillary sinuses in C. The ostial region is not adequately visualized to allow estimation of ostial patency as a result of the sparse slices and that bony structures are not seen on MRI scans.

TABLE 3. Findings With MRI During Acute Respiratory Infection in a Series of 60 Children

	MRI Findings*			
	Normal	Minor Abnormality	Major Abnormality	Mean
	<i>n</i> (%)	<i>n</i> (%)	<i>n</i> (%)	Score (SD)
Maxillary sinuses	15 (25)	9 (15)	36 (60)	1.8 (1.2)
Ethmoidal sinuses	10 (17)	13 (22)	37 (62)	1.9 (1.1)
Frontal sinuses†	16 (27)	6 (10)	11 (18)	1.1 (1.2)
Sphenoidal sinuses‡	31 (55)	6 (10)	20 (35)	1.1 (1.3)
All sinuses	7 (12)	12 (20)	41 (68)	8.5 (6.8)§

* Normal, less than 2-mm mucosal thickening; minor abnormality, less than one third volume loss; major abnormality, more than one third volume loss or an air-fluid level. The final grade has been determined according to the more severely affected side.

† Frontal sinuses were not developed in 24 children and not displayed in the slices in 3 children.

‡ Sphenoidal sinuses were not developed in 3 children.

§ Calculated for all of the sinuses on both side.

mean MRI scores correlated significantly with the symptoms scores ($r_s = 0.3, P = .02$) but not with the duration of symptoms ($r_s = -0.04, P = .73$). Of the individual symptoms, nasal obstruction ($P = .02$), nasal discharge ($P = .04$), and fever ($P = .02$) were significantly related to the MRI scores.

Follow-up MRI

Of the 26 children (12 boys and 14 girls) who attended the follow-up examination, 9 (35%) had fully recovered from the respiratory infection, 9 (35%) continued to have symptoms (mean [SD] symptom score 6.3 [3.9]), and 8 (30%) had developed a new respiratory infection (mean [SD] symptom score 3.5 [1.3]). Two children had received antimicrobial treatment (otitis media, thigh abscess).

Altogether, the MRI findings had improved significantly from the initial scans ($P = .001$; Table 4). Despite the improvement, however, 69% of these 26 most severely affected children still had major abnormalities in the sinuses (Table 4). The MRI scores at the control visit did not correlate significantly with the control visit's symptom score ($r_s = 0.21, P = .29$) or the MRI scores at the initial visit ($r_s = 0.09, P = .66$).

DISCUSSION

We found a high prevalence of paranasal sinus abnormalities on MRI scans in a group of 4- to 7-year-old children with acute respiratory infection. Almost two thirds of the children had opacifications

that constituted at least one third of their maxillary and ethmoidal sinuses. We demonstrate that acute respiratory infection affects not only the nasal passages but also the paranasal sinuses in children. The follow-up MRI scan, taken in the most affected cases in the first scan, showed that the paranasal sinus abnormalities tended to resolve without antimicrobial treatment, but this resolution of MRI changes did not associate with the disappearance of clinical symptoms. Thus, clinicians should not make decisions on treatment based only on the radiologic findings.

The proportion of adenoidectomized children was high in our sample (30%) but represented the typical child population in Finland, where adenoidectomy has been used as the first surgical intervention for recurrent/chronic otitis media. In 2 Finnish studies, it was found that up to 31% of the children have been adenoidectomized before the age of 3 years.^{8,9}

We found a significant correlation between the MRI scores and the severity of nasal obstruction and discharge and fever confirming the results of a study done on adults.¹⁰ None of the other symptoms or the duration of the symptoms predicted the paranasal sinus findings. The sinus abnormalities tended to be more severe in the children with higher symptom scores than those with milder symptoms, similar to the study of the common cold in adults.² In both studies, the differences were small and the symptoms of the patients with and without rhinosinusitis were not clinically distinguishable.

TABLE 4. Findings in MRI During an Acute Respiratory Infection and a Follow-up Visit 2 Weeks Later in a Series of 26 Children With Major Abnormal Findings in the First Scan

Sinus	Acute Visit				Follow-up Visit			
	Normal	Minor Abnormality	Major Abnormality	Mean Score (SD)	Normal	Minor Abnormality	Major Abnormality	Mean Score (SD)
	<i>n</i> (%)	<i>n</i> (%)	<i>n</i> (%)		<i>n</i> (%)	<i>n</i> (%)	<i>n</i> (%)	
Maxillary	—	—	26 (100)	2.7 (0.4)	10 (38)	7 (27)	9 (35)	1.3 (1.3)
Ethmoidal	—	3 (12)	23 (89)	2.5 (0.7)	8 (31)	6 (23)	12 (46)	1.3 (1.1)
Frontal*	3 (21)	4 (29)	7 (50)	1.7 (1.2)	12 (75)	1 (6)	3 (19)	0.6 (1.1)
Sphenoidal†	8 (35)	2 (8)	13 (55)	1.7 (1.4)	15 (60)	4 (16)	6 (24)	0.8 (1.1)
Overall				12.7 (5.6)‡				5.7 (5.2)‡

* Frontal sinuses were not developed in 10 children and not displayed in the slices in the acute visit in 2 children.

† Sphenoidal sinuses were not developed in 1 child and not displayed in the slices in the acute visit in 2 children.

‡ Calculated for all of the sinuses on both sides.

CONCLUSIONS

Our results show that acute respiratory infection is accompanied by mucosal edema in the paranasal sinuses in most children and that these abnormalities tend to resolve spontaneously without antimicrobial treatment irrespective of disappearance of the symptoms.

ACKNOWLEDGMENTS

Financial support for this study was provided by the University Central Hospital of Oulu.

REFERENCES

1. Ioannidis JP, Lau J. Technical report: evidence for the diagnosis and treatment of acute uncomplicated sinusitis in children: a systematic overview. *Pediatrics*. 2001;108(3). Available at: www.pediatrics.org/cgi/content/full/108/3/e57
2. Gwaltney JM Jr, Phillips CD, Miller RD, Riker DK. Computed tomographic study of the common cold. *N Engl J Med*. 1994;330:25–30
3. Glasier CM, Mallory GB Jr, Steele RW. Significance of opacification of the maxillary and ethmoid sinuses in infants. *J Pediatr*. 1989;114:45–50
4. Tapiainen T, Luotonen L, Kontiokari T, Renko M, Uhari M. Xylitol administered only during respiratory infections failed to prevent acute otitis media. *Pediatrics*. 2002;109(2). Available at: www.pediatrics.org/cgi/content/full/109/2/e19
5. Jackson GG, Dowling HF, Spiesman IG, Boang AV. Transmission of the common cold to volunteers under controlled conditions. *Arch Intern Med*. 1958;101:267–278
6. Diamant MJ, Senac MO Jr, Gilsanz V, Baker S, Gillespie T, Larsson S. Prevalence of incidental paranasal sinuses opacification in pediatric patients: a CT study. *J Comput Assist Tomogr*. 1987;11:426–431
7. Lesserson JA, Kieserman SP, Finn DG. The radiographic incidence of chronic sinus disease in the pediatric population. *Laryngoscope*. 1994;104:159–166
8. Niemelä M, Uhari M, Luotonen M, Luotonen J, Manninen M-P, Puhakka H. Changes in day care attendance rates and in the occurrence of adenoidectomies and tympanostomies. *Acta Paediatr*. 1998;87:1003–1004
9. Luotonen M, Uhari M, Aitola L, et al. A nation-wide, population-based survey of otitis media and school achievement. *Int J Pediatr Otorhinolaryngol*. 1998;43:41–51
10. Puhakka T, Makela MJ, Alanen A, et al. Sinusitis in the common cold. *J Allergy Clin Immunol*. 1998;102:403–408

Paranasal Sinus Findings in Children During Respiratory Infection Evaluated With Magnetic Resonance Imaging

Aila Kristo, Matti Uhari, Jukka Luotonen, Petri Koivunen, Eero Ilkko, Terhi Tapiainen and Olli-Pekka Alho

Pediatrics 2003;111;e586

DOI: 10.1542/peds.111.5.e586

Updated Information & Services

including high resolution figures, can be found at:
<http://pediatrics.aappublications.org/content/111/5/e586>

References

This article cites 8 articles, 0 of which you can access for free at:
<http://pediatrics.aappublications.org/content/111/5/e586#BIBL>

Subspecialty Collections

This article, along with others on similar topics, appears in the following collection(s):
Dentistry/Oral Health
http://www.aappublications.org/cgi/collection/dentistry:oral_health_sub

Permissions & Licensing

Information about reproducing this article in parts (figures, tables) or in its entirety can be found online at:
<http://www.aappublications.org/site/misc/Permissions.xhtml>

Reprints

Information about ordering reprints can be found online:
<http://www.aappublications.org/site/misc/reprints.xhtml>

American Academy of Pediatrics

DEDICATED TO THE HEALTH OF ALL CHILDREN™



PEDIATRICS®

OFFICIAL JOURNAL OF THE AMERICAN ACADEMY OF PEDIATRICS

Paranasal Sinus Findings in Children During Respiratory Infection Evaluated With Magnetic Resonance Imaging

Aila Kristo, Matti Uhari, Jukka Luotonen, Petri Koivunen, Eero Ilkko, Terhi
Tapiainen and Olli-Pekka Alho

Pediatrics 2003;111;e586

DOI: 10.1542/peds.111.5.e586

The online version of this article, along with updated information and services, is
located on the World Wide Web at:

<http://pediatrics.aappublications.org/content/111/5/e586>

Pediatrics is the official journal of the American Academy of Pediatrics. A monthly publication, it has been published continuously since 1948. Pediatrics is owned, published, and trademarked by the American Academy of Pediatrics, 141 Northwest Point Boulevard, Elk Grove Village, Illinois, 60007. Copyright © 2003 by the American Academy of Pediatrics. All rights reserved. Print ISSN: 1073-0397.

American Academy of Pediatrics

DEDICATED TO THE HEALTH OF ALL CHILDREN™

