

# Pneumatosis Intestinalis After Pediatric Thoracic Organ Transplantation

Jonathan T. Fleenor, MD\*; Timothy M. Hoffman, MD\*; David M. Bush, MD, PhD\*; Stephen M. Paridon, MD\*; Bernard J. Clark III, MD\*; Thomas L. Spray, MD†; and Nancy D. Bridges, MD\*

**ABSTRACT.** *Objective.* To review and describe pneumatosis intestinalis (PI) in children who have undergone thoracic organ transplantation and evaluate potential risk factors.

*Methods.* We retrospectively reviewed abdominal radiographs obtained from June 1992 through September 2000 in all pediatric (age <21 years) thoracic organ recipients who survived at least 1 week after transplantation. In this group, a case was defined as an episode of radiographically confirmed PI; those without PI were assigned as controls. Variables analyzed included demographic data, gastroenteritis history (stool cultures or symptoms of gastroenteritis), and transplant-related factors (ie, graft type, rejection history, immunosuppression regimen). Significance was defined as  $P < .05$ .

*Results.* Over this 8-year period, PI occurred in 8 (7%) of 116 patients (0.86% annual risk). No child had >1 diagnosed episode of PI. Of these 8 cases, 7 presented with 1 or more abdominal symptoms. Three of these children had rotavirus antigen isolated in their stool, 2 others were noted to have stool positive for *Clostridium difficile* toxin, and in the other 3, no pathogen was identified. All cases were treated with a regimen of intravenous antibiotics and total parenteral nutrition. There were no deaths; however, 1 patient developed an *Aspergillus* pulmonary infection during his course of antibiotic therapy, and another underwent an exploratory laparotomy without bowel resection. Significant risk factors included black race (unadjusted odds ratio: 16), younger age at presentation (age <5 years; unadjusted odds ratio: 9), higher steroid dose (steroid dose >0.5 mg/kg/d; unadjusted odds ratio: 7), and a higher tacrolimus level at presentation (tacrolimus level >1; unadjusted odds ratio: 6). PI did not occur with a steroid dose <0.4 mg/kg/d. Variables not associated with increased risk for developing PI included gender, graft type, total white blood cell count, recent antibiotic use, concurrent use of an antimetabolite, cytomegaloviral infection, past use of extracorporeal membrane oxygenation, and graft rejection history.

*Conclusions.* Significant risk factors for the development of PI in our pediatric thoracic organ transplantation population included black race, younger age, higher daily steroid dosing, and a high tacrolimus level at presentation. In the children diagnosed with PI, there were no related deaths, significant gastrointestinal sequelae, or complications. These findings suggest that in this

population, PI will often have a benign course when treated aggressively, and that steroid dosing should be reduced to <0.5 mg/kg/d whenever possible. *Pediatrics* 2002;109(5). URL: <http://www.pediatrics.org/cgi/content/full/109/5/e78>; *pediatric heart transplantation, pediatric lung transplantation, pediatric heart-lung transplantation, pneumatosis intestinalis, steroids.*

ABBREVIATIONS. PI, pneumatosis intestinalis; CMV, cytomegalovirus; HIV, human immunodeficiency virus; NPO, no enteral feeds; TPN, total parenteral nutrition.

Pneumatosis intestinalis (PI) is a radiologic and pathologic finding defined as the presence of gas within the bowel wall. Although the cause of PI is not fully understood, the most widely accepted theories are based on the bacterial or mechanical causes.<sup>1</sup> Outside the neonatal period, PI is fairly uncommon. It has, however, been associated with a variety of disorders and procedures including solid organ and bone marrow transplantation,<sup>2-8</sup> steroid and other immunosuppressive medications,<sup>1,3,8,9</sup> ischemia, inflammatory bowel disease, intestinal obstruction, and obstructive airway disease. In addition, several concomitant infectious agents have been associated with the development of PI including cytomegalovirus (CMV), *Clostridium difficile*, rotavirus, human immunodeficiency virus (HIV), and other viral infectious agents.<sup>3,4,6,7,9</sup> PI may present in a variety of ways, ranging from an incidental finding that is clinically benign to an acute and life-threatening illness. Recently diagnosed cases of PI in our pediatric thoracic organ transplantation population prompted us to retrospectively review this group of patients and evaluate them for significant clinical outcomes as well as potential risk factors in the development of PI.

## METHODS

The cohort was obtained by locating all patients who underwent thoracic organ transplantation and had abdominal radiographs taken from June 1992 through September 2000. A total of 116 patients underwent transplantation during that period. Of those, 58 had a total of 100 abdominal radiographs taken for various reasons (37 had a single radiograph, 16 had 2 radiographs, 2 had 3 radiographs, 3 had 4 radiographs, 1 had 6 radiographs, and 1 had 7 radiographs). Radiographs that were taken within the same time frame (30 days) were counted as 1 episode.

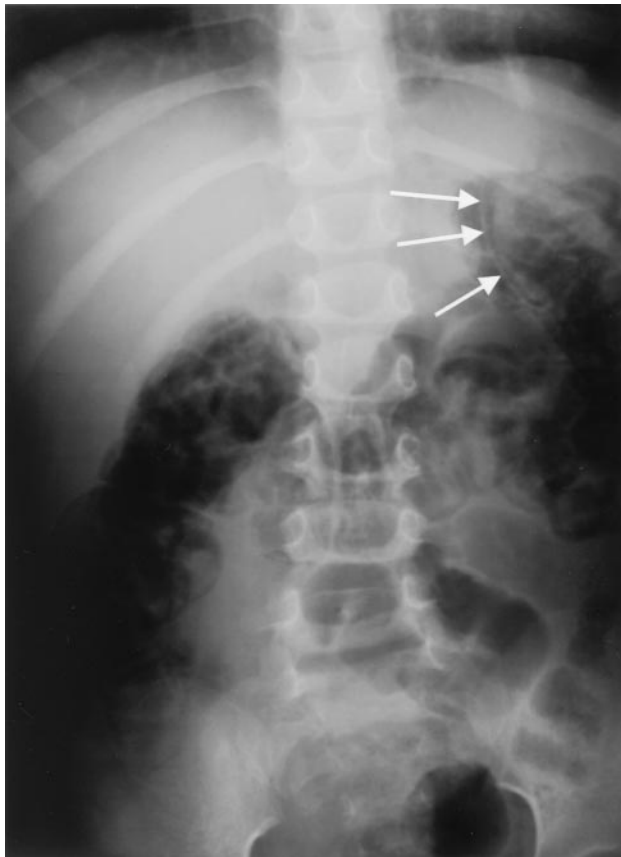The diagnosis of PI was made on abdominal film in 8 children; these were defined as cases (for radiograph examples, see Figs 1 and 2). Of our cases, PI was present on a minimum of 4 and maximum of 9 radiographs (mean: 6.3) taken during their hospital admission. Radiographs were not read in a blinded fashion, but repeat films obtained and read by different attending radiologists confirmed the diagnosis of PI in all cases.

From the Department of Pediatrics, Divisions of \*Cardiology and †Cardiothoracic Surgery, Children's Hospital of Philadelphia, Philadelphia, Pennsylvania.

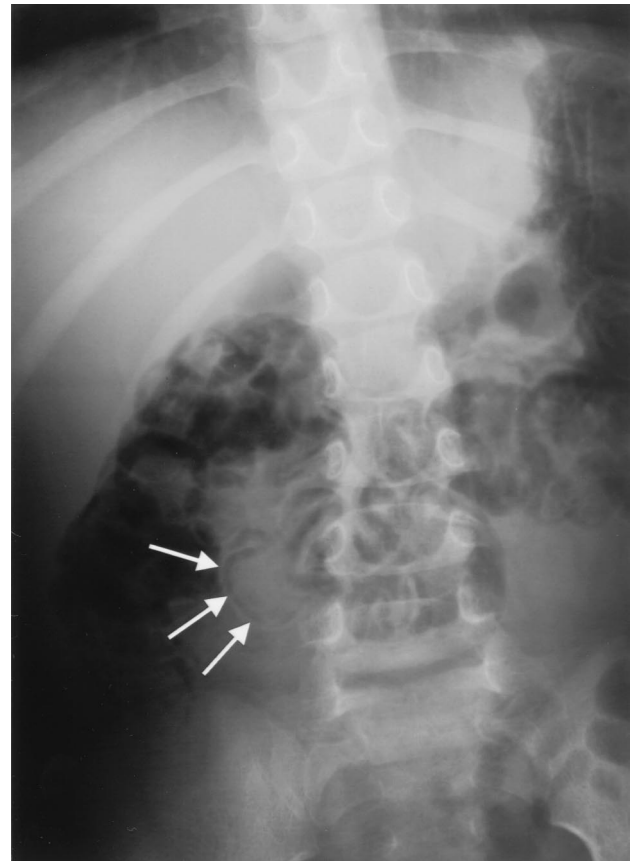
Received for publication Sep 18, 2001; accepted Jan 22, 2002.

Reprints requests to (J.T.F.) Division of Cardiology, Children's Hospital of Philadelphia, 34th St and Civic Center Blvd, Philadelphia, PA 19104. E-mail: jtfleenor@nmcsd.med.navy.mil

PEDIATRICS (ISSN 0031 4005). Copyright © 2002 by the American Academy of Pediatrics.



**Fig 1.** Abdominal radiograph of 4-year-old girl with PI diagnosed 36 months after bilateral lung transplantation. Arrows illustrate linear appearance of PI in the bowel wall.



**Fig 2.** Abdominal radiograph of a 3-year-old girl with PI diagnosed 2 months after orthotopic heart transplantation. Arrows illustrate linear appearance of PI in the bowel wall.

A control population, defined as those patients who had an absence of PI on abdominal film, was then obtained using a random number generator.<sup>10</sup> Data were obtained to assume four controls per case (32 controls). The radiographs and charts of these 40 patients were then reviewed for demographic data, cardiac history before transplant, recent infectious history, and transplant-related factors including graft type, rejection history, and immunosuppression regimen.

Exploratory data analysis was performed to determine normality; selected skewed distributions were changed to categorical variables for additional analysis.  $\chi^2$  analysis was then performed for all dichotomous and categorical variables. Fisher exact test was used when the expected number in any cell was  $<5$ . Odds ratios were used as the measure of association. For continuous variables, a *t*-test of the means was used; skewed distributions were evaluated using the rank-sum test with medians reported. Statistical significance was assessed using a  $P < .05$  (2-tailed). Unconditional logistic regression was then used to assess for confounding or interaction of significant variables from the univariate analysis. Odds ratios were again used as the measure of association. Statistical significance of individual terms was assessed by the Wald test.

## RESULTS

### Patient Characteristics (Table 1)

PI developed in 8 (7%) of 116 patients (0.86% annual risk) between 3 weeks and 36 months (median: 11 months) after thoracic organ transplantation. No child had  $>1$  episode of PI. The PI group included 5 boys and 3 girls, with 5 of the children having undergone heart transplantation, 2 having lung transplantation, and 1 having a heart-lung transplantation. The PI group was significantly younger than the controls (median age 2.8 years vs 6.2 years;  $P = .04$ )

with an age  $<5$  years placing children at significantly increased risk to develop PI (unadjusted odds ratio: 9;  $P < .05$ ). Ethnic background of the cases was black in 6 and white in 2. This was also significantly different from the control group; therefore, black race was associated with a greater risk to develop PI (unadjusted odds ratio: 16;  $P < .01$ ).

### Presenting Symptoms

Abdominal symptoms were present in 7 of the 8 children at the time of diagnosis. These included bloody diarrhea (6 patients), abdominal pain (4 patients), emesis (3 patients), and abdominal distention (1 patient). In the patient without abdominal symptoms, PI was diagnosed incidentally. The child who had undergone previous lung transplantation presented to an outside hospital with symptoms of cough and fever. An initial chest radiograph revealed pneumonia of the right upper lobe, and antibiotics were administered. A follow-up chest radiograph done the next morning confirmed the pneumonia of the right upper lobe, but also showed PI in the transverse colon. This finding was confirmed by additional abdominal imaging. The patient remained symptom-free from an abdominal standpoint throughout her remaining hospitalization.

### Transplant-Related Issues

At the time of diagnosis, all patients who developed PI were on steroids and a calcineurin inhibitor

**TABLE 1.** Patient Characteristics of Cases

Case Number	Age at Time of Diagnosis (Years)	Time Posttransplantation to Presentation of PI (Months)	Graft Type	Sex	Race	Presenting Gastrointestinal Symptoms	Concurrent Infection	Immunosuppression Regimen on Presentation	Outcome/Morbidity
1	3.6	2	Heart	F	Black	Bloody diarrhea, abdominal pain	<i>C difficile</i>	Prednisone Tacrolimus	No sequelae
2*	3.9	0.75	Heart	M	Black	Abdominal pain, distention	<i>C difficile</i>	Prednisone Cyclosporine Azathioprine	No sequelae
3	0.3	11	Heart	M	White	Emesis, bloody diarrhea	Rotavirus	Prednisone Tacrolimus Mycophenolate	No sequelae
4	1.2	9	Lung	M	Black	Bloody diarrhea, abdominal pain	Rotavirus	Prednisone Tacrolimus	No sequelae
5†	9.6	30	Heart/ lung	M	Black	Emesis, bloody diarrhea	None	Prednisone Tacrolimus Mycophenolate	Pulmonary <i>Aspergillus</i>
6	1.9	12	Heart	M	Black	Bloody diarrhea, abdominal pain	Rotavirus	Prednisone Tacrolimus Mycophenolate	No sequelae
7	1.9	4	Heart	F	White	Emesis, bloody diarrhea	None	Prednisone Tacrolimus Mycophenolate	No sequelae
8	4.7	36	Lung	F	Black	None	None	Prednisone Tacrolimus Mycophenolate	No sequelae

\* Exploratory laparotomy was performed.

† Developed pulmonary *Aspergillus* after antibiotic course.

(tacrolimus, 7; cyclosporine, 1), while 6 of 8 were on an antimetabolite (azathioprine, 1; mycophenolate mofetil, 5). Those children who developed PI were on significantly higher steroid doses as compared with controls (0.74 vs 0.27 mg/kg/d;  $P < .01$ ) with a steroid dose of  $>0.5$  mg/kg/d placing patients at significantly increased risk of developing PI (unadjusted odds ratio: 7;  $P = .04$ ). No child developed PI on a steroid dose of  $<0.4$  mg/kg/d. Of note, 2 patients who developed PI had just finished a 3-day steroid burst (10 mg/kg/d) for treatment of possible cardiac rejection.

Those children who developed PI also were noted to have a significantly higher tacrolimus level at presentation (13.0 vs 9.7 ng/mL;  $P = .04$ ), with a level  $>11$  ng/mL placing one at significantly increased risk of developing PI (unadjusted odds ratio: 6;  $P = .04$ ). Evaluation of maintenance tacrolimus levels (tacrolimus level drawn at the most recent outpatient visit before admission for PI) showed no significant differences. Of note, 2 of the 7 patients admitted on tacrolimus were switched to intravenous cyclosporine during their hospitalization secondary to difficulties in maintaining therapeutic drug levels.

There were no significant differences found in regards to graft type, gender, antimetabolite use or antimetabolite dose at presentation, past number of episodes of organ rejection, concurrent organ rejection, or past use of a cardiac mechanical assist device (ie, extracorporeal membrane oxygenation). A summary of clinical characteristics of cases versus controls is shown in Table 2.

#### Concomitant Infections

On analysis of stool in the 8 children diagnosed with PI, 3 had positive enzyme immunoassay anti-

gen tests for rotavirus, 2 were positive for *C difficile* toxin, and in the other 3 cases no infectious organisms could be identified. No patient had positive blood cultures on initial presentation, and there were no cases of recent or ongoing CMV infection.

Of the 32 control patients, only 8 had significant enough gastrointestinal symptoms that prompted the treating physicians to obtain stool samples. This resulted in 2 children being diagnosed with *C difficile*, 1 with rotavirus and 1 with adenovirus.

#### Outcomes

All patients who developed PI were treated with a regimen of intravenous antibiotics, no enteral feeds (NPO), and total parenteral nutrition (TPN) for 10 to 21 days (median: 16 days). The length of hospital stay related to PI issues ranged from 15 to 22 days (median: 18 days). Seven patients had placement of a central line for administration of parenteral antibiotics and TPN, and 1 patient underwent an exploratory laparotomy secondary to concerns for perforation. One child developed sputum positive for *Aspergillus* 4 days after stopping parenteral antibiotics for the PI. Additional evaluation included computed tomography of the chest showing pulmonary nodules and transbronchial biopsy that was also positive for *Aspergillus*. There were no related deaths.

Of note, 1 patient had an acute bradycardic arrest on day 10 of his admission for PI. Cardiac catheterization at that time revealed high filling pressures and diffuse coronary artery vasculopathy. Both of these findings were a change when compared with a catheterization performed just 2 months prior. On biopsy, there was no evidence of cellular rejection. He was treated with steroids and intravenous inotropic medication, but eventually required a second

**TABLE 2.** Clinical Characteristics of Cases Versus Controls

Variable	Cases of PI (n = 8)	Control Patients (n = 32)	P Value
Median age at time of diagnosis (y)	2.8 (range: 3 mo–9.6 y)	6.2 (range: 3 mo–20 y)	.04
Black race	6	5	.04
Prednisone dose at time of diagnosis (mg/kg/d)	0.74 (range: 0.4–9.9)	0.27 (range: 0–1.0)	<.01
Tacrolimus level at presentation (ng/mL)	13.0 (range: 7.7–17.1)	9.5 (range: 6.9–17)	.04
Graft type (heart/lung/heart-lung)	5/2/1	20/10/2	NS
Steady state tacrolimus level (ng/mL)	9.5	9.1	NS
Gender (M/F)	5/3	17/15	NS
Time post-transplant to diagnosis of PI (mo)	10	15	NS
Type of antimetabolite (mycophenolate/azathioprine)	5/1	6/14	NS
Concurrent rejection at time of diagnosis of PI	1	0	NS
Past number of rejection episodes	10	15	NS
Admission WBC	11.5	10.3	NS
Past steady-state WBC	9.9	6.9	NS
Concurrent CMV infection	0	2	NS
History of ECMO use	1	8	NS
Recent antibiotic use	2	12	NS

WBC indicates white blood cell; ECMO, extracorporeal membrane oxygenation; NS, not significant.

heart transplantation for chronic severe (inotrope-dependent) graft dysfunction.

### DISCUSSION

PI has been described in association with transplantation (bone marrow, liver, and kidney), immunosuppression (steroids, HIV), intestinal obstruction, and obstructive airway disease. The incidence of PI in pediatric thoracic organ transplant patients is not known. Although there have been rare case reports of PI developing in these patients after thoracic organ transplantation,<sup>4,7</sup> at least 1 large study of gastrointestinal complications seen in 132 heart and heart-lung transplant patients reported no PI.<sup>11</sup> In a recently reported series of 89 pediatric heart transplant recipients, 4 (4.5%) had documented PI.<sup>12</sup> Our study documents 8 children who developed PI after thoracic organ transplantation.

Significant risk factors for the development of PI in our population included younger age at presentation, black race, and higher maintenance steroid dose. Patients with PI also had significantly higher serum tacrolimus levels at presentation than did controls; however, their maintenance tacrolimus levels were not significantly different from controls, suggesting that the elevated levels at presentation may be the result of rather than a cause of PI (different absorptive pattern of the drug or different hydration status with an alternation in the clearance of the drug). Elevation of serum tacrolimus levels in the setting of gastroenteritis is now well-recognized.<sup>13–16</sup>

Although PI in the newborn period is a well-recognized entity often associated with necrotizing enterocolitis, the propensity for younger children outside of the neonatal period to develop PI is not well-described.<sup>17</sup> The most likely causes for this include differences noted in bowel and associated lymphoid tissue, as well as the tendency for younger

children to have more episodes of infectious gastroenteritis. Our finding that children of black background were at significantly higher risk to develop PI has not been previously reported and is difficult to explain. The use of steroids and its association with development of PI, however, has been well-described.<sup>1,3,8,9</sup> The most commonly accepted mechanism is that steroids cause atrophy of the lymphoid tissue (Peyer's patches) in the gastrointestinal tract, which results in mucosal degradation, allowing dissection of intraluminal air into the intestinal wall. Immunosuppression after cardiac transplantation varies by center with some using steroid-free regimens after a variable time posttransplantation.<sup>18–20</sup> The reported benefits to these steroid-free regimens include a decreased requirement for antihypertensive agents,<sup>21</sup> and decreased incidence of cataract formation and diabetes mellitus.<sup>22</sup> Likewise, these centers report improvement in bone density with fewer compression fractures,<sup>18</sup> as well as improvement in lipid profiles,<sup>23</sup> all without significantly increasing the risk of rejection or mortality. The programs that propose the continued use of steroids as part of their posttransplantation regimen point to prospective data that suggests stopping steroids place patients at increased risk of acute rejection without significant benefits.<sup>24</sup> Because acute episodes of rejection are treated with high-dose steroids, others argue that maintaining a constant low dose of steroids actually exposes patients to an overall lower steroid dose. It should also be noted that centers that use a steroid-free regimen report that 15%<sup>25</sup> to 48%<sup>26</sup> of their patients cannot remain steroid-free for the long-term, and additionally report some cases of coronary vasculopathy and sudden death.<sup>18</sup> No data exist that would imply that a steroid-free regimen is safe in thoracic organ transplantation that involve a

lung graft. Until good long-term prospective pediatric studies on steroid use after cardiac transplantation are performed, it is likely that differing opinions on this topic will remain. Our institution currently uses a triple immunosuppression regimen, which attempts to maintain children on a low-maintenance steroid dose. The data presented in this study show an association of a prednisone dose of >0.5 mg/kg/d with a sevenfold increased risk to develop PI, and no children developed PI on a dose of <0.4 mg/kg/d.

Concomitant infections including rotavirus and *C difficile* were seen in 5 of our 8 cases of PI. Both rotavirus<sup>1,3</sup> and *C difficile*<sup>1,3,7</sup> have been associated with PI. The proposed mechanism for the development of PI with these infectious agents is based on inflammation causing a break in the integrity of the intestinal mucosa, thus allowing intraluminal air to dissect into the bowel wall. Although active CMV infection has been widely described in association with the development of PI, we did not encounter this association in our patients.

Clinically, our cases of PI presented with a variety of symptoms ranging from 1 patient who was asymptomatic from a gastrointestinal standpoint, to the other 7 having various symptoms including abdominal distention, pain, emesis, and bloody diarrhea. All of our patients were treated with NPO status, intravenous antibiotics, and TPN. We had no related deaths, associated bacteremias, central line,

or TPN complications. One child underwent exploratory laparotomy secondary to suspicion of perforation, and one child developed pulmonary *Aspergillus* after finishing his antibiotic course. The diagnosis of PI in the face of no gastrointestinal symptoms has been reported in other transplantation patients. A review of the literature is summarized in Table 3. A total of 62 patients diagnosed with PI after various types of transplantation have been reported. These include 36 bone marrow, 12 kidney, 12 liver, and 2 lung transplantation. Asymptomatic presentation, which occurred in 14 patients (23%), was associated with no deaths or need for surgical intervention. Symptomatic presentation was seen in 48 patients (77%), and resulted in the need for 9 gastrointestinal surgical interventions (19%) and 12 deaths (25%). The majority of these were seen in patients who had received bone marrow transplantation. Although it is difficult to draw conclusions across a spectrum of different graft types, treatments of PI, immunosuppression regimens, and potential causes, a few issues seem to stand out. Asymptomatic patients presenting with PI after transplantation tend to be less ill and usually respond to either no treatment or conservative medical treatment (NPO, TPN, antibiotics) without surgical intervention. Although symptomatic patients often are more ill, more likely to undergo surgical intervention, and have a greater risk for death, they also usually respond to a regimen of bowel rest and intravenous antibiotics.

**TABLE 3.** Summary of PI Cases Reported After Transplantation

Author	Graft Type (Number of Patients)	Total Cases	Presenting		Surgical Intervention		Deaths		Associated Clinical Conditions (Number of Patients)
			Sx	A-Sx	Sx	A-Sx	Sx	A-Sx	
Day <sup>3</sup>	Bone marrow (36)	18	14	4	2	0	7	0	Steroid (12), colitis (10), GVHD (3), deaths (7) Gastric ulcer and CMV pneumonia (1) GVHD, steroids, and pancreatitis (1)
Navari <sup>27</sup>		2	2	0	1	0	2	0	
Yeager <sup>28</sup>		4	4	0	0	0	1	0	GVHD (4), steroid (4), death (1) rotavirus, adenovirus, Candida (1)
Hall <sup>29</sup>		1	1	0	0	0	0	0	GVHD, steroid
Takanashi <sup>30</sup>		1	1	0	1	0	0	0	GVHD, steroid, exploratory laparotomy
Avigan <sup>31</sup>		2	2	0	1	0	0	0	Total colectomy/ileostomy
Lipton <sup>32</sup>		1	1	0	1	0	0	0	GVHD, hemicolectomy/ileostomy
Bates <sup>33</sup>		7	4	3	0	0	1	0	GVHD (6), steroid (3), CMV (4), <i>C difficile</i> (1), death (1)
Ammons <sup>8</sup>	Kidney (12)	3	1	2	0	0	0	0	Asymptomatic (2), no treatment symptomatic (1), IV antibiotics
Van Son <sup>6</sup>		4	3	1	1	0	1	0	CMV (4), duodenal ulcer (1), exploratory laparotomy (1), death (1)
Murphy <sup>34</sup>		3	2	1	0	0	0	0	HSV (1)
Wall <sup>35</sup>		1	1	0	0	0	0	0	Concurrent rejection treatment with steroids
Polinsky <sup>36</sup>		1	1	0	0	0	0	0	Concurrent rejection treatment with steroids
Burress <sup>5</sup>	Liver (12)	6	5	1	0	0	0	0	CMV, <i>Staphylococcus aureus</i> , <i>Escherichia coli</i> (1) Concurrent rejection treatment with steroids Laparotomy, colectomy, ileoproctostomy (2)
Koep <sup>37</sup>		2	2	0	2	0	0	0	
Jassen <sup>38</sup>		1	1	0	0	0	0	0	Recent steroid treatment for rejection, subcutaneous scrotal air
King <sup>39</sup>		2	0	2	0	0	0	0	Asymptomatic/no treatment
Sachse <sup>40</sup>		1	1	0	0	0	0	0	Recent steroid treatment for rejection
Schenk <sup>7</sup>	Lung (2)	1	1	0	0	0	0	0	<i>C difficile</i> (1) CMV (1)
Mannes <sup>4</sup>		1	1	0	0	0	0	0	
Totals		62	48	14	9	0	12	0	

Sx indicates symptomatic; A-Sx, asymptomatic; GVHD, graft-versus-host disease; HSV, herpes simplex virus.

## CONCLUSION

PI was found in 7% of our pediatric thoracic organ transplantation population for an annual risk of 0.86%. Associations by statistical analysis included younger age, black race, a higher prednisone dose, and higher tacrolimus level at the time of diagnosis. We recommend abdominal radiographs in all transplant recipients presenting with abdominal symptoms, and individualization of therapy as determined by presentation. We continue to maintain a 2-week period of bowel rest and intravenous antibiotics for those children in whom PI is accompanied by bloody diarrhea and abdominal complaints. This treatment regimen was associated with a relatively benign disease course without major complications or sequelae.

## REFERENCES

1. Heng Y, Schuffler M, Haggitt R, Rohrmann C. Pneumatosis intestinalis: a review. *Am J Gastroenterol.* 1995;90:1747–1758
2. Andorsky R. Pneumatosis cystoides intestinalis after organ transplantation. *Am J Gastroenterol.* 1990;85:189–194
3. Day D, Ramsay N, Letourneau J. Pneumatosis intestinalis after bone marrow transplantation. *AJR Am J Roentgenol.* 1998;151:85–87
4. Mannes G, De Boer W, Van der Jagt E, et al. Pneumatosis intestinalis and active cytomegaloviral infection after lung transplantation. *Chest.* 1994;105:929–930
5. Burress G, Ben-Ami T, Whittington P. Pneumatosis intestinalis in infants after orthotopic liver transplantation. *J Pediatr Gastroenterol Nutr.* 1996; 23:577–582
6. Van Son W, Van der Jagt E, Van der Woude F, et al. Pneumatosis intestinalis after cadaveric kidney transplantation. *Transplantation.* 1984; 38:506–510
7. Schenk P, Madl C, Kramer L, et al. Pneumatosis intestinalis with *Clostridium difficile* colitis as a cause of acute abdomen after lung transplantation. *Dig Dis Sci.* 1998;43:2455–2458
8. Ammons M, Bauling P, Weil R. Pneumatosis cystoides intestinalis with pneumoperitoneum in renal transplant patients on cyclosporine and prednisone. *Transplant Proc.* 1986;18:1868–1870
9. Kleinman P, Brill P, Winchester P. Pneumatosis intestinalis: its occurrence in the immunologically compromised child. *Am J Dis Child.* 1980; 134:1149–1151
10. Glass G, Hopkins K. *Statistical Methods in Education and Psychology.* 2nd ed. Englewood Cliffs, NJ: Prentice Hall Inc; 1984:528
11. Augustine S, Yeo C, Buchman T, Achuff S, Baumgartner W. Gastrointestinal complications in heart and heart-lung transplant patients. *J Heart Lung Transplant.* 1991;10:547–556
12. Rakhit A, Nurko S, Gauvreau K, Mayer J, Blume E. Gastrointestinal complications after pediatric cardiac transplantation. *Circulation.* 2000; 102(suppl 2):653
13. Eades S, Boineau F, Christensen M. Increased tacrolimus levels in a pediatric renal transplant patient attributed to chronic diarrhea. *Pediatr Transplant.* 2000;4:63–66
14. Fruhwirth M, Fischer H, Simma B, et al. Rotavirus infection as a cause of tacrolimus elevation in solid-organ-transplanted children. *Pediatr Transplant.* 2001;5:88–92
15. Mittal N, Thompson J, Kato T, Tzakis A. Tacrolimus and diarrhea: pathogenesis of altered metabolism. *Pediatr Transplant.* 2001;5:75–79
16. Fruhwirth M, Fischer H, Simma B, Ellemunter H. Elevated tacrolimus trough levels in association with mycophenolate mofetil induced diarrhea: a case report. *Pediatr Transplant.* 2001;5:132–134
17. West K, Rescorla F, Grosfeld J, Vane D. Pneumatosis intestinalis in children beyond the neonatal period. *J Pediatr Surg.* 1989;24:818–822
18. Canter C, Moorhead S, Saffitz J, Huddleston C, Spray T. Steroid withdrawal in the pediatric heart transplant recipient initially treated with triple immunosuppression. *J Heart Lung Transplant.* 1994;13:74–80
19. Chinnock R, Baum M, Larsen R, Bailey L. Rejection management and long-term surveillance of the pediatric heart transplant recipient: the Loma Linda experience. *J Heart Lung Transplant.* 1993;12:S255–S264
20. Leonard H, O'Sullivan J, Dark J. Long-term follow-up of pediatric cardiac transplant recipients on a steroid-free regime: the role of endomyocardial biopsy. *J Heart Lung Transplant.* 2000;19:469–472
21. Olivari MT, Antolick A, Ring WS. Arterial hypertension in heart transplant recipients treated with triple-drug immunosuppressive therapy. *J Heart Transplant.* 1989;8:34–39
22. Olivari MT, Jessen M, Baldwin B, Horn V, Yancy C, Ring S, Rosenblatt R. Triple-drug immunosuppression with steroid discontinuation by six months after heart transplantation. *J Heart Lung Transplant.* 1995;14: 127–135
23. Kubo S, Peters J, Knutson K, Hertz M, Olivari M, Bolman R. Factors influencing the development of hypercholesterolemia after cardiac transplantation. *Am J Cardiol.* 1992;70:520–526
24. Keogh A, Macdonald P, Harvison A, Richens D, Mundy J, Spratt P. Initial steroid-free versus steroid-based maintenance therapy and steroid withdrawal after heart transplantation: two views of the steroid question. *J Heart Lung Transplant.* 1992;11:421–427
25. Miller L, Pennington D, McBride L. Long-term effects of cyclosporine in cardiac transplantation. *Transplant Proc.* 1990;22(suppl 1):15–20
26. Lee K, Pierce J, Hess M, et al. Cardiac transplantation with corticosteroid-free immunosuppression: long-term results. *Ann Thorac Surg.* 1991; 52:211–218
27. Navari R, Sharma P, Deeg H. Pneumatosis cystoides intestinalis following allogeneic marrow transplantation. *Transplant Proc.* 1983;15: 1720–1723
28. Yeager A, Kanof M, Kramer S, et al. Pneumatosis intestinalis in children after allogeneic bone marrow transplantation. *Pediatr Radiol.* 1987;17: 18–22.
29. Hall RR, Anagnostou A, Kanojia M. Pneumatosis intestinalis is associated with graft-versus-host disease of the intestinal tract. *Transplant Proc.* 1984;16:1666–1668
30. Takanashi M, Hihi S, Sawada T, Sawada T, Tsunamoto K, Imashuku S. Pneumatosis cystoides intestinalis with abdominal free air in a 2-year-old girl after allogeneic bone marrow transplantation. *Pediatr Hematol Oncol.* 1998;15:81–84
31. Avigan D, Richardson P, Elias A, et al. Neutropenic enterocolitis as a complication of high dose chemotherapy with stem cell rescue in patients with solid tumors: a case series with a review of the literature. *Cancer.* 1998;83:409–414
32. Lipton J, Patterson B, Mustard R, et al. Pneumatosis intestinalis with free air mimicking intestinal perforation in a bone marrow transplant patient. *Bone Marrow Transplant.* 1994;14:323–326
33. Bates F, Gurney J, Goodman L, Santamaria J, Hansen R, Ash R. Pneumatosis intestinalis in bone marrow transplantation patients: diagnosis on routine chest radiographs. *AJR Am J Roentgenol.* 1989;152:991–994
34. Murphy B, Weinfeld A. Innocuous pneumatosis intestinalis of the right colon in renal transplant recipients. *Dis Colon Rectum.* 1987;30:816–819
35. Wall L, Phil D, Linshaw M, Bailie M. Pneumatosis intestinalis in a pediatric renal transplant patient. *J Pediatr.* 1982;101:745–747
36. Polinsky M, Wolfson B, Gruskin A, et al. Development of pneumatosis cystoides intestinalis following transperitoneal renal transplantation in a child. *Am J Kidney Dis.* 1984;3:414–419
37. Koep L, Peters T, Starzl T. Major complications of hepatic transplantation. *Dis Colon Rectum.* 1979;4:218–220
38. Janssen D, Kalayoglu M, Sollinger H. Pneumatosis cystoides intestinalis following lactose and steroid treatment in a liver transplant patient with an intermittently enlarged scrotum. *Transplant Proc.* 1987;19:2949–2952
39. King S, Shuckett B. Sonographic diagnosis of portal venous gas in two pediatric liver transplant patients with benign pneumatosis intestinalis. *Pediatr Radiol.* 1992;22:577–578
40. Sachse R, Burke G, Jonas M, Milgrom M, Miller J. Benign pneumatosis intestinalis with subcutaneous emphysema in a liver transplant recipient. *Am J Gastroenterol.* 1990;85:876–879

**Pneumatosis Intestinalis After Pediatric Thoracic Organ Transplantation**  
Jonathan T. Fleenor, Timothy M. Hoffman, David M. Bush, Stephen M. Paridon,  
Bernard J. Clark III, Thomas L. Spray and Nancy D. Bridges  
*Pediatrics* 2002;109;e78  
DOI: 10.1542/peds.109.5.e78

**Updated Information & Services**

including high resolution figures, can be found at:  
<http://pediatrics.aappublications.org/content/109/5/e78>

**References**

This article cites 39 articles, 0 of which you can access for free at:  
<http://pediatrics.aappublications.org/content/109/5/e78#BIBL>

**Subspecialty Collections**

This article, along with others on similar topics, appears in the following collection(s):  
**Gastroenterology**  
[http://www.aappublications.org/cgi/collection/gastroenterology\\_sub](http://www.aappublications.org/cgi/collection/gastroenterology_sub)  
**Infectious Disease**  
[http://www.aappublications.org/cgi/collection/infectious\\_diseases\\_sub](http://www.aappublications.org/cgi/collection/infectious_diseases_sub)

**Permissions & Licensing**

Information about reproducing this article in parts (figures, tables) or in its entirety can be found online at:  
<http://www.aappublications.org/site/misc/Permissions.xhtml>

**Reprints**

Information about ordering reprints can be found online:  
<http://www.aappublications.org/site/misc/reprints.xhtml>

American Academy of Pediatrics

DEDICATED TO THE HEALTH OF ALL CHILDREN®



# PEDIATRICS®

OFFICIAL JOURNAL OF THE AMERICAN ACADEMY OF PEDIATRICS

**Pneumatosis Intestinalis After Pediatric Thoracic Organ Transplantation**  
Jonathan T. Fleenor, Timothy M. Hoffman, David M. Bush, Stephen M. Paridon,  
Bernard J. Clark III, Thomas L. Spray and Nancy D. Bridges  
*Pediatrics* 2002;109:e78  
DOI: 10.1542/peds.109.5.e78

The online version of this article, along with updated information and services, is  
located on the World Wide Web at:

<http://pediatrics.aappublications.org/content/109/5/e78>

Pediatrics is the official journal of the American Academy of Pediatrics. A monthly publication, it has been published continuously since 1948. Pediatrics is owned, published, and trademarked by the American Academy of Pediatrics, 345 Park Avenue, Itasca, Illinois, 60143. Copyright © 2002 by the American Academy of Pediatrics. All rights reserved. Print ISSN: 1073-0397.

American Academy of Pediatrics

DEDICATED TO THE HEALTH OF ALL CHILDREN®

