

# Hypoplasia of Medullary Arcuate Nucleus in Unexpected Late Fetal Death (Stillborn Infants): A Pathologic Study

Luigi Maturri, MD, PhD\*; Iolanda Minoli, MD‡; Anna Maria Lavezzi, MD\*; Anna Cappellini, MD§; Simone Ramos, MD, PhD||; and Lino Rossi, MD\*

**ABSTRACT.** *Objectives.* To evaluate the frequency, morphology, and pathogenesis (primary or secondary) of the abnormally developed medullary arcuate nucleus (ARCn) in stillbirths.

*Methods.* We examined 26 stillbirths (24 antepartum, 2 intrapartum) that had a gestational age between 25 and 40 weeks and a normal karyotype. All of the stillborns were described as well-developed, with body length and weight proportional to their gestational age. Each case was submitted to complete autopsy examination, which included a systematic gross and microscopic evaluation of the body, the placental disk, and the umbilical cord and membranes. The brainstem was the particular focus of the histologic examination. The study of the various nuclei (nucleus hypoglossus, dorsal vagus motor nucleus, tractus solitarius nucleus, nucleus ambiguus, trigeminal tractus and nucleus, arcuate nucleus, and ventrolateral reticular formation and its neurons and parabrachial/Kölliker-Fuse complex) was performed on transversal serial sections through the entire pons and medulla oblongata. The histologic analysis was supplemented by volumetric reconstruction and immunohistochemical detection of both apoptosis and proliferating cell nuclear antigen.

*Results.* Histologic examination showed abnormalities of the medulla oblongata ARCn in 9 fetuses (35%). In 8, a marked hypoplasia was evident, characterized by a volume reduction of the nucleus accompanied by neuronal depletion, whereas in 1 fetus the nucleus was completely absent (agenesis). The absence of gliosis, the negativity of the proliferating cell nuclear antigen analysis, and the similarities in apoptotic indices between the hypoplastic and well-developed arcuate are in keeping with a primary developmental defect. This anomaly is frequently associated with hypoplasia of the reticular formation and chronic hypoxia.

*Conclusions.* A high frequency of hypoplasia of the ARCn occurs in fetuses who have died "sine causa," ie, in a similar manner to that observed in sudden infant death syndrome. Chemoreceptors, although not involved in reflexogenic oxygenation in fetal life, become of vital importance intrapartum and postpartum; therefore, whenever impaired in the course of development, chemoreceptors may underlie cardioventilatory abnor-

malities critical to sudden infant death syndrome. *Pediatrics* 2002;109(3). URL: <http://www.pediatrics.org/cgi/content/full/109/3/e43>; *medullary arcuate nucleus, brainstem, fetus, still birth, hypoplasia, agenesis, fetal death, SIDS.*

ABBREVIATIONS. SIDS, sudden infant death syndrome; ARCn, arcuate nucleus; VMS, ventral medullary surface; PCNA, proliferating cell nuclear antigen; PBS, phosphate-buffered saline; TdT, terminal deoxynucleotidyl transferase; dUTP, digoxigenin-conjugated deoxyuridine; GFAP, glial fibrillary acidic protein.

Stillbirth is defined as late fetal death before the complete expulsion or retraction of the fetus from the mother.<sup>1</sup> Advances in maternal and fetal care have produced a significant reduction in perinatal mortality but have not changed the prevalence of stillbirth. With a prevalence of 5 to 12 per 1000 births,<sup>2,3</sup> stillbirths represent approximately half of the cases of perinatal mortality. The risk of unexplained, near-term, intrauterine death is present in any pregnancy, and the cause remains obscure in most instances.<sup>4</sup> Unexpected and unexplained fetal death is far more common than sudden infant death syndrome (SIDS), but the pathologic investigations that have been conducted in it unfortunately are sporadic and incomplete.<sup>5-8</sup> Investigations of the pathology of the autonomic nervous system in fetuses are sadly lacking, despite that abnormalities of these structures are often the main pathologic substrate for unexpected fetal death, as in SIDS.<sup>9-18</sup> Evidence indicates that as many as 30% of SIDS cases might be caused by developmental abnormalities of the brainstem, such as the arcuate nucleus (ARCn) of the ventral medullary surface (VMS).<sup>19</sup>

This study attempts to assess the pathologic findings in 26 stillborn infants with a gestational age of 25 to 40 weeks and, in particular, to detect the frequency and the nature (primary or secondary) of the abnormally developed ARCn. This nucleus is closely suggested in cardiorespiratory activity through a chemoreceptor reflexogenic action. Obviously, this is not a physiologic factor in ventilatory chemoreflexogenesis in utero, but it becomes immediately operative (with vital-lethal implications) in the intrapartum and postpartum periods.

## METHODS

### Subjects

We examined 26 singleton white stillbirths that were sent to our institute from May 1998 to July 2000 (Table 1) and that occurred

From the \*Department of Pathology, University of Milan, Milan, Italy; ‡Center for Infants Nutrition to Prevent Illness in Adult Life, Department of Perinatal Pathology, Macedonio Melloni Maternity Hospital, Milan, Italy; §Department of Pathology, S. Gerardo dei Tintori Hospital, Monza, Milan, Italy; and ||Department of Pathology, University of São Paulo, São Paulo, Brazil.

Received for publication Jun 26, 2001; accepted Nov 1, 2001.

Reprint requests to (L.M.) Department of Pathology, State University, Via della Commenda, 19, 20122 Milan, Italy. E-mail: luigi.maturri@unimi.it  
PEDIATRICS (ISSN 0031 4005). Copyright © 2002 by the American Academy of Pediatrics.

**TABLE 1.** Case Profiles

Number	GA (Weeks)	Sex	Body Weight	ARCn Hypoplasia	Reticular Formation Hypoplasia	Chronic Hypoxia	Placental Umbilical Pathology	Other Pathologic Findings
1	25	M	626	+	+	+	Chorioamnionitis	Aspiration of amniotic fluid
2	25	F	830	-	-	-	Multifocal placental infarcts	-
3	25	F	590	-	-	-	Multifocal placental infarcts	-
4	25	M	1000	-	-	-	-	-
5	26	F	894	-	-	-	Multifocal placental infarcts	-
6	27	F	1200	-	-	-	-	-
7	29	F	820	-	-	+	-	Septicemia
8	29	F	1220	-	-	+	-	Bronchopneumonia
9	29	M	1310	-	-	-	-	-
10	30	F	3190	+	+	+	Chorioamnionitis	-
11	33	F	1540	+	-	+	Multifocal placental infarcts	Aspiration of amniotic fluid
12	34	M	2160	-	-	+	-	Dilated cardiomyopathy
13	34	M	2350	-	-	-	-	Aspiration of amniotic fluid
14	35	M	1470	-	-	-	Multifocal placental infarcts	-
15	35	F	2150	-	-	+	-	Aspiration of amniotic fluid
16	36	M	2200	+	+	+	-	-
17	36	F	1840	+	+	+	Umbilical cord around the neck, chorioamnionitis	-
18	36	F	2650	-	-	-	Multifocal placental infarcts	-
19	36	F	2250	-	-	-	-	-
20	38	M	3530	-	-	-	-	-
21	38	M	1750	+	+	+	-	-
22	38	F	3200	Agenesis	+	+	-	Aspiration of amniotic fluid
23	39	F	3100	+	+	+	-	-
24	39	M	3580	-	-	-	-	-
25	39	M	3230	-	-	+	Multifocal placental infarcts	Aspiration of amniotic fluid
26	40	F	3050	+	+	+	Head band of the umbilical cord	-

GA indicates gestational age.

after 25 complete gestational weeks. Twenty-four of these stillbirths were antepartum and 2 were intrapartum (cases 17 and 26).

For this study, we selected fetuses with only initial decomposition signs, and all had an unknown etiopathogenesis. The range of the interval between fetal death and fetal delivery was 24 to 48 hours. Thus, fetuses with advanced decomposition signs and those who had from maternal, fetal, or genetic causes were excluded from this study.

In the 2 cases of intrapartum stillbirth, the newborns had given a few gasps at birth, followed by repeated respiratory irreversible arrests, despite immediate attempts at resuscitation. The umbilical cord in both cases had an atypical location. In 1 case, it was positioned like a head band (case 26); in the other, it was around the neck of the fetus but without causing constriction (case 17).

Pregnancy in all cases had run a normal course. None of the mothers had any significant pathology, and they had not used drugs, tobacco, or alcohol. In only 1 case was there a history of previous spontaneous abortion (case 5).

A complete autopsy examination was conducted, including a systematic gross and microscopic evaluation of the body, the placental disk, the umbilical cord, and membranes. All organs were fixed in 10% phosphate-buffered formalin, processed, and embedded in paraffin. Five-micrometer sections were stained with hematoxylin-eosin and Heidenhain's trichromic (Azan). The brainstem was a particular focus of the histologic examinations, according to the protocol routinely followed by our institute.<sup>20</sup>

Transversal serial 5- $\mu$ m sections were made through the entire pons and medulla oblongata (approximately 600 sections per case). For each group of 12 sections, 3 were stained using alternately hematoxylin-eosin, Bielschowsky, and Klüver-Barrera stains; 3 were used for immunohistochemical analysis of apoptosis, gliosis, and proliferating cell nuclear antigen (PCNA), respectively; and 6 were kept and stained as deemed necessary. A total of approximately 150 sections of the pons and 150 sections of the medulla oblongata were stained and examined. The pertinent nuclei were outlined, namely the parabrachial/Kölliker-Fuse complex in the pons,<sup>21</sup> the nucleus hypoglossus, the dorsal vagus motor nucleus, the tractus solitarius nucleus, the nucleus ambiguus, the trigeminal tractus and nucleus, the ARCn, and the ventrolateral reticular formation and its cellular neurons in the medulla oblongata. Plates in the atlas of Olszewski and Baxter<sup>22</sup> (from No. 1 to No. 33) were used for reference.

**Volumetric Reconstruction**

The morphometric analysis was performed with an Image-Pro Plus Image Analyzer (Media Cybernetics, Silver Spring, MD) on both sides of the medulla oblongata for each specimen. The parameters evaluated were arcuate neuronal density (number of neurons per unit area [mm<sup>2</sup>]) and ARCn volume (V). All of the neurons were counted in transverse sections, coplanar, with clearly defined edges and with a distinct nucleolus, and examined with the optical microscope at 200 $\times$  magnification. The volume of the ARCn was measured by 3-dimensional reconstruction. A computer program developed by Voxblast (VayTek Inc, Fairfield, IA) was used to digitize and display serial section reconstructions and to obtain volumetric measurements of the selected cell populations. In each tenth section, the outer boundaries of the ARCn were traced. The tracings were digitized by computer and then registered to reestablish their original positions relative to one another. The fourth ventricle and central canal served as landmarks for registration. The brainstem was reconstructed from the cervicomedullary to the pontomedullary junction.

**Data Statistical Analysis**

Statistical calculations were conducted on a personal computer with the SPSS statistical software (SPSS, Inc, Chicago, IL). The morphometric results of the measurements are expressed as mean values and standard deviation. The statistical significance of direct comparisons between well-developed and hypoplastic ARCn was determined using the analysis of variance (F test). The selected threshold level for statistical significance was  $P < .05$ .

**Immunohistochemical Analysis**

*Apoptosis*

The sections of all of the medulla oblongata specimens were deparaffinized and incubated at room temperature with 20  $\mu$ g/mL proteinase K (Sigma, St Louis, MO). After the endogenous peroxidase was inactivated by covering sections with 2% H<sub>2</sub>O<sub>2</sub>, the specimens were rinsed with phosphate-buffered saline (PBS). Each section was then incubated at room temperature with terminal deoxynucleotidyl transferase (TdT) buffer. The enzyme TdT was used to incorporate digoxigenin-conjugated deoxyuridine (dUTP) to the ends of DNA fragments. TdT and dUTP in TdT

buffer were added to cover the sections and then incubated at 37°C for 60 minutes (Apoptag Peroxidase "In Situ Apoptosis Detection" Kit, ONCOR, Gaithersburg, MD). The signal of TdT-mediated dUTP nick end labeling was then detected by an anti-digoxigenin antibody conjugated with peroxidase. A tonsil was used as positive control. Apoptotic nuclei were identified by the presence of dark brown staining. We evaluated the apoptotic index of ARCn as number of TdT-mediated dUTP nick end labeling-positive cells/total number of neurons in this nucleus  $\times$  100.

### Gliosis

For glial fibrillary acidic protein (GFAP) immunostain, sections were deparaffinized and washed in PBS. After blocking endogenous peroxidase with 3% H<sub>2</sub>O<sub>2</sub>, the slides were pretreated in a microwave oven using a citrate solution (pH 6) at 600 W for 3 minutes. The sections were incubated overnight with the primary monoclonal antibody NCL-GFAP-GA5 (anti-GFAP; Novocastra, Newcastle Tyne, UK) at a dilution of 1:300. Immunohistochemical staining was performed with the peroxidase-antiperoxidase method and avidin-biotin complex technique (ABC kit; Vectastain, Vector Laboratories, Inc, Burlingame, CA). Diaminobenzidine (Vector Laboratories) was used as chromogen substrate and counterstained with light hematoxylin. Negative controls of the same tissue were performed using PBS instead of primary antibody.

### PCNA

Sections were deparaffinized and washed in PBS. After blocking endogenous peroxidase with 3% H<sub>2</sub>O<sub>2</sub>, the slides were incubated overnight with primary monoclonal antibody PC10 (anti-PCNA; D.B.A Italia s.r.l., Milan, Italy) at a dilution of 1:200. Immunohistochemical staining was performed with the peroxidase-antiperoxidase method and avidin-biotin complex technique (ABC Kit). Diaminobenzidine was used as chromogen substrate and counterstained with light hematoxylin. A tonsil was used as positive control. The PCNA labeling index was defined as the number of neurons with strong unequivocal nuclear staining (corresponding to cells in S phase) divided by the total number of ARCn neurons, expressed as a percentage.

The statistical relationship between immunohistochemical data in groups with normal and hypoplastic ARCn was evaluated by F-test. The level of significance was  $P < .05$ .

## RESULTS

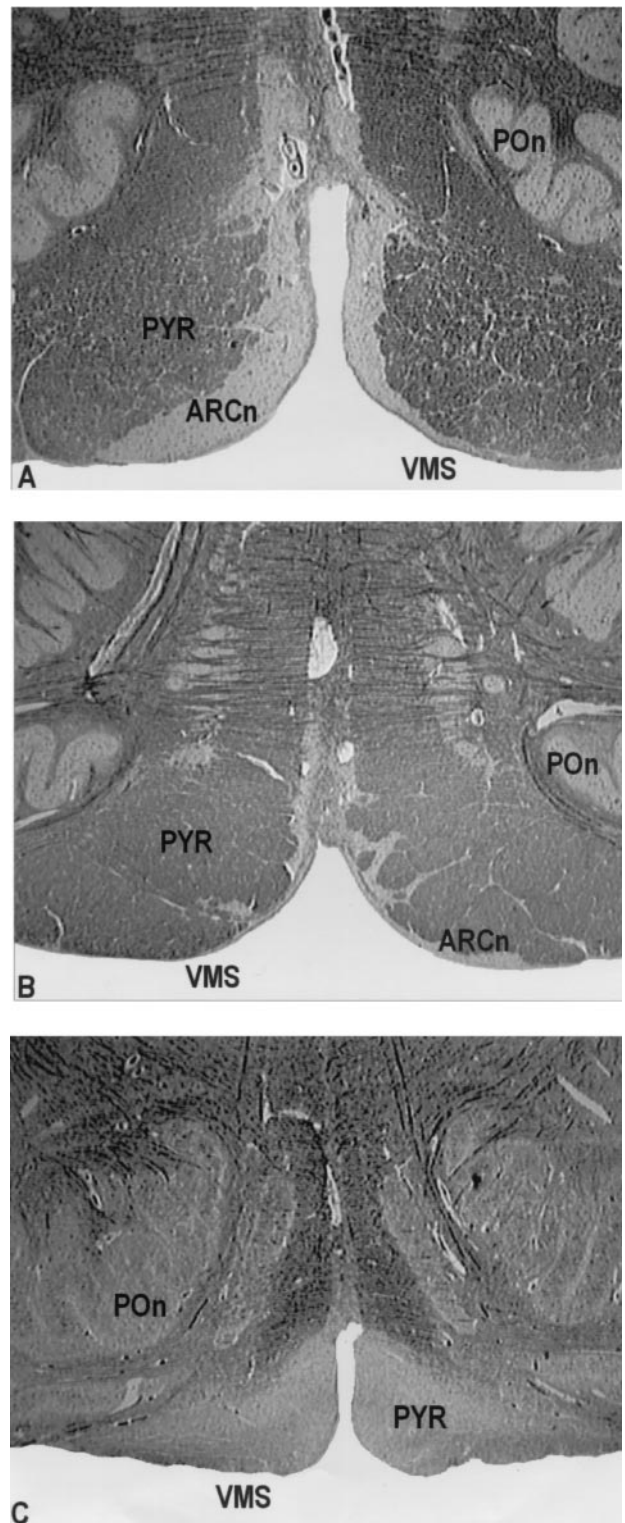
At autopsy, the stillborns were described as well-developed, with body length and weight corresponding to their gestational age (Table 1). No gross fetal anomalies were detected.

With the exception of the brainstem (and specifically of the ARCn, as detailed below), there were no specific gross or histologic findings of the brain, except for acute congestion.

The ARCn was located, on either side of the ventral surface of the medulla, between the caudal pole of the inferior olive and the caudal border of the pons. The ARCn neurons were usually loosely arranged, medium sized, oval, polygonal, or elongated, with eccentric large nuclei and long dendrites. The ARCn formed clusters lying among the ventral external arcuate fibers medial, ventral to the pyramids, and ventral to the inferior olivary complex.

Histologic examination evidenced abnormalities of the ARCn in 9 fetuses (35%). In 8, a marked hypoplasia was evident, characterized by a volume reduction of the nucleus accompanied by neuronal depletion, and in 1 the nucleus was completely absent (agenesis; Table 1 and Fig 1).

Morphometric analysis demonstrated that the volume of the hypoplastic ARCn was on average 1.009 mm<sup>3</sup>  $\pm$  0.35, ie, 5 times less than that of the 17 cases without hypoplasia (5.70 mm<sup>3</sup>  $\pm$  0.6;  $P < .01$ ). This



**Fig 1.** A, Normal development of the ARCn in case 24, a fetus of 39 weeks' gestation. B, Severe hypoplasia of the ARCn in case 11, a fetus of 33 weeks' gestation. C, Agenesis of the ARCn in case 22, a fetus of 38 weeks' gestation (Klüver-Barrera stains, origin magnifications  $\times$ 40). PON, principal inferior olive; PYR, pyramid.

considerable reduction of the size of ARCn was associated with a marked neuronal depletion, as indicated by a neuronal density of  $46 \pm 5$  neurons/mm<sup>2</sup>, as opposed to that of well-developed ARCn ( $213 \pm 20$  neurons/mm<sup>2</sup>) brainstems ( $P < .01$ ; Table 2). In no cases were neuronal morphologic alterations ob-

**TABLE 2.** Morphometric Analysis of the ARCn

	ARCn With Hypoplasia (8 Cases)	ARCn Without Hypoplasia (17 Cases)	<i>P</i>
Mean volume (mm <sup>3</sup> )	1.009 ± 0.35	5.70 ± 0.6	<.01
Mean neuronal density (cell number/mm <sup>2</sup> )	46 ± 5	213 ± 20	<.01

served. The morphometric evaluations did not show significant differences in volume or neuronal density among the right and left ARCn in any case.

The histologic analysis ruled out in all cases the presence of acquired (vascular, metabolic, inflammatory, degenerative) lesions, as well as variations in the glial population of either the ARCn or the other brainstem nuclei. The average apoptotic index of the hypoplastic ARCn was 39.2%, versus 35.5% in the well-developed ARCn (*P* > .05).

Search for PCNA was negative in all instances (PCNA labeling index = 0).

The ARCn hypoplasia/agenesis was associated in 8 cases with an underdeveloped reticular formation, characterized by a marked reduction of the nerve fibers. No abnormalities were detected in the adjacent nucleus ambiguus or in the other nuclei of the medulla oblongata. Furthermore, no alterations were observed in the pontine parabrachial/Kölliker-Fuse complex among the cases with either well-developed or hypoplastic ARCn.

Chronic hypoxic suffering—characterized by a second-degree depletion of the thymus, stress-response adrenal cysts, marked hepatic erythropoiesis, and subpleural hemorrhages (“petechial hemorrhages of Tardieu”)—was present in 14 fetuses. It was found in all 9 cases characterized by a development anomaly of the ARCn, in 1 case of sepsis (case 7), in 1 case of pneumonia (case 8), in 1 case of dilated cardiomyopathy (case 12), and in 2 cases of amniotic fluid aspiration (cases 15 and 24).

Aspiration of amniotic fluid was observed in 6 cases in the entire series, including 2 cases with ARCn hypoplasia and the single case with agenesis. Microscopically, atelectatic alveoli were collapsed. Necrotic cellular debris with scanty eosinophilic hyaline membranes were present in the respiratory bronchioles, alveolar ducts, and scattered proximal alveoli. Other pathologic findings were chorioamnionitis in 3 cases (slight in case 17, severe in cases 1 and 10). Histologic examination of the placenta evidenced vascular abnormalities of mild/moderate degree (villus infarctions, fibrin deposits and abruptions) in 10 cases (Table 1).

## DISCUSSION

The aim of this study was to determine the incidence, nature, and possible physiologic significance of the hypoplasia/agenesis of the ARCn associated with stillbirth.

The ARCn of the ventral surface of the human medulla is implicated in central chemoreception, cardiopulmonary coupling, and blood pressure re-

sponses.<sup>23</sup> Therefore, we and others<sup>14,15,24,25</sup> suggest that ARCn hypoplasia/agenesis may characterize a subset of SIDS cases with a putative defect in brainstem chemoreceptors. A major question is the frequency and nature of this congenital anomaly. In the stillborn autopsies presented here, there was a congenital defect (hypoplasia/agenesis) of the ARCn in 35% of 26 developing fetuses of a gestational age between 25 and 40 weeks, an incidence remarkably similar to that of the 30% observed in our previous article on SIDS victims.<sup>19</sup> It should be noted that in the latter work, we had found the anomaly in question in SIDS but not in control cases.

The morphometric evaluation of the volume and neuronal density conducted here has allowed a more precise definition of this developmental anomaly. In fact, the average volume of the hypoplastic ARCn was 1.009 mm<sup>3</sup> ± 0.35, ie, more than 5 times smaller than that of its normally developed counterpart (5.70 mm<sup>3</sup> ± 0.6; *P* < .01). The neuronal density analysis showed a marked neuronal depletion in the hypoplastic ARCn (mean: 46 ± 5 neurons/mm<sup>2</sup>) when compared with the normal situation (mean: 213 ± 20 neurons/mm<sup>2</sup>).

The primitive and probably genetic nature of this developmental anomaly is suggested by the lack of inflammatory infiltrates, hemorrhages, gliosis, and other reactive changes. The absence of cell proliferation and significant neuronal apoptosis in the ARCn of the examined cases further supports this interpretation. This contrasts with the presence of marked apoptosis that was reported by Waters et al<sup>26</sup> in the brainstem of SIDS victims. Therefore, genetic alterations of the ARCn of the rhombic lip occurring during pregnancy seem the most likely cause, as further supported by the frequent association between hypoplasia of ARCn and hypoplasia of the reticular formation. In fact, 8 of the 9 fetuses with hypoplasia/agenesis of the ARCn also had hypoplasia of the reticular formation, characterized by a reduction of the nervous fiber network.

Evident signs of chronic hypoxia were present in all cases of hypoplasia of ARCn. However irrelevant to fetal life, chemoreceptors become of vital importance in the intrapartum and postpartum periods; therefore, whenever impaired in development, they may underlie cardioventilatory abnormalities critical to SIDS. A relevant question concerns the mechanism by which this congenital anomaly may cause respiratory disturbances immediately after birth, as suggested by the 2 intrapartum cases in our series (cases 17 and 26). In these cases, an anomalous position of the umbilical cord could have enhanced a chemoreceptor dysfunction as an important predisposing or contributing lethal factor.

Kinney et al<sup>15</sup> proposed a triple-risk model for the pathogenesis of SIDS. According to them, sudden death results from the combination of 3 factors: 1) a vulnerable infant, 2) a critical developmental period for homeostatic control, and 3) 1 or more exogenous stressors.

In our observation regarding these developed term fetuses, who died just after birth, respiratory insufficiency was seen immediately, a fact that seems to

indicate that the pathogenetic mechanism of respiratory death involves 2 factors only: 1) vulnerability attributable to the hypoplasia of ARCn, and 2) an exogenous stress represented by birth trauma.

In conclusion, this study documents the high frequency of the hypoplasia of ARCn and emphasizes the need of an accurate postmortem examination to individualize the morphologic substrates of unexpected late fetal death.

#### ACKNOWLEDGMENTS

This study was supported by the Lombardy Region (project 49210-24.3.00: "Program of Research and Intervention for the Reduction of the Risk of Sudden Infant Death and Unexpected Fetal Death") and MURST Cofin 2000 (project MM06153578: "Pathologic Study of Late Fetal Unexplained Death-Stillbirth").

We thank Graziella Alfonsi, Marina Crippa, and Gioacchina Randazzo for technical assistance and Bruna Biondo, ScD, PhD, for the brainstem reconstruction.

#### REFERENCES

1. Kalousek DK, Gilbert-Barnes E. Causes of stillbirth and neonatal death. In: Gilbert-Barnes E, ed. *Potter's Pathology of the Fetus and Infant*. St Louis, MO: Mosby; 1997:128–162
2. Schauer GM, Kalousek DK, Magel LF. Genetic of stillbirth. *Semin Perinatol*. 1992;16:341–351
3. Ahlenius I, Thomassen P. The changing of late fetal death in Sweden between 1984 and 1991. *Acta Obstet Gynecol Scand*. 1999;78:408–414
4. Cotzias CS, Paterson-Brown S, Fisk NK. Prospective risk of unexplained stillbirth in singleton pregnancies at term: population based analysis. *BMJ*. 1999;319:287–288
5. Saller DN, Lesser KB, Harrel U, et al. The clinical utility of the perinatal autopsy. *JAMA*. 1995;273:663–665
6. Ogunyemi D, Jackson U, Buyske S, et al. Clinical and pathological correlates of stillbirths in a single institution. *Acta Obstet Gynecol Scand*. 1998;77:722–728
7. Salafia CH, Vagel CA, Vintzileos AM, et al. Placental pathologic findings in preterm birth. *Am J Obstet Gynecol*. 1991;165:934–938
8. Salafia CH, Pezullo JC, Lopez-Zeno JA, et al. Placental pathologic features of preterm preeclampsia. *Am J Obstet Gynecol*. 1995;173:1097–1105
9. Rossi L, Matturri L. Cardiac neuronal pathology in sudden infant death syndrome. *New Trends Arrhythm*. 1989;1:76–81
10. Rossi L, Matturri L. *Clinicopathologic Approach to Cardiac Arrhythmias*. Mount Kisco, NY: Futura Publishing Co; 1990
11. Rossi L, Matturri L. Anatomohistological features of sudden infant death syndrome. *New Trends Arrhythm*. 1991;2:135–139
12. Rossi L, Matturri L. Anatomohistological features of the heart's conduction system and innervation in SIDS. In: Rognum TO, ed. *Sudden Infant Death Syndrome: New Trends in the Nineties*. Oslo, Norway: Scandinavia University Press; 1995:207–212
13. Kinney HC, Brody BA, Finkelstein DM, et al. Delayed central nervous system myelination in the sudden infant death syndrome. *J Neuropathol Exp Neurol*. 1991;50:29–48
14. Kinney HC, Filiano JJ, Slepser LA, et al. Decreased muscarinic receptor binding in the arcuate nucleus in sudden infant death syndrome. *Science*. 1995;269:446–4450
15. Kinney HC, Filiano JJ, Panigraphy A, et al. Anatomic and neurochemical studies of the ventral medulla in early life. Observation relevant to the sudden infant death syndrome. In: Trough CO, Hillis RH, Kiwull-Schone H, Schlafke ME, eds. *Ventral Brain Stem Mechanisms and Control Respiration and Blood Pressure*. New York, NY: Dekker; 1995:589–609
16. Takashima S, Mito T, Becker LE. Neuronal development in the medullary reticular formation in sudden infant death syndrome and premature infants. *Neuropediatrics*. 1985;16:76–79
17. Obonai T, Takashima S, Becker LE, et al. Relationship of substance P and gliosis in medulla oblongata in neonatal sudden infant death syndrome. *Pediatr Neurol*. 1996;15:89–192
18. Obonai T, Takashima S. In utero brain lesions in SIDS. *Pediatr Neurol*. 1998;19:23–25
19. Matturri L, Biondo B, Mercurio P, Rossi L. Severe hypoplasia of medullary arcuate nucleus: quantitative analysis in sudden infant death syndrome. *Acta Neuropathol*. 2000;99:371–375
20. Rossi L, Matturri L. Cardiac conduction and nervous system in health, disease and sudden death. An anatomoclinical overview. *L'Ospedale Maggiore*. 1995;89:239–257
21. Testut L. *Anatomia umana, V: sistema nervoso centrale—Unione tipografica torinese*. Turin, Italy: 1923:263–283
22. Olszewski J, Baxter D. *Cytoarchitecture of the Human Brain Stem*. Basel, Switzerland: Karger; 1982
23. Millhorn DE, Eldridge FL. Role of ventrolateral medulla in regulation of respiratory and cardiovascular systems. *J Appl Physiol*. 1986;61:1249–1263
24. Filiano JJ, Choi JC, Kinney HC. Candidate cell populations for respiratory chemosensitive fields in the human infant medulla. *J Comp Neurol*. 1990;293:448–465
25. James J, Filiano JJ, Kinney HC. Arcuate nucleus hypoplasia in the sudden infant death syndrome. *J Neuropathol Exp Neurol*. 1992;51:394–403
26. Waters KA, Meehan B, Huang JQ, et al. Neuronal apoptosis in sudden infant death syndrome. *Pediatr Res*. 1999;45:166–172

**Hypoplasia of Medullary Arcuate Nucleus in Unexpected Late Fetal Death  
(Stillborn Infants): A Pathologic Study**

Luigi Maturri, Iolanda Minoli, Anna Maria Lavezzi, Anna Cappellini, Simone Ramos  
and Lino Rossi

*Pediatrics* 2002;109:e43

DOI: 10.1542/peds.109.3.e43

<b>Updated Information &amp; Services</b>	including high resolution figures, can be found at: <a href="http://pediatrics.aappublications.org/content/109/3/e43">http://pediatrics.aappublications.org/content/109/3/e43</a>
<b>References</b>	This article cites 20 articles, 1 of which you can access for free at: <a href="http://pediatrics.aappublications.org/content/109/3/e43#BIBL">http://pediatrics.aappublications.org/content/109/3/e43#BIBL</a>
<b>Subspecialty Collections</b>	This article, along with others on similar topics, appears in the following collection(s): <b>Fetus/Newborn Infant</b> <a href="http://www.aappublications.org/cgi/collection/fetus:newborn_infant_sub">http://www.aappublications.org/cgi/collection/fetus:newborn_infant_sub</a>
<b>Permissions &amp; Licensing</b>	Information about reproducing this article in parts (figures, tables) or in its entirety can be found online at: <a href="http://www.aappublications.org/site/misc/Permissions.xhtml">http://www.aappublications.org/site/misc/Permissions.xhtml</a>
<b>Reprints</b>	Information about ordering reprints can be found online: <a href="http://www.aappublications.org/site/misc/reprints.xhtml">http://www.aappublications.org/site/misc/reprints.xhtml</a>

American Academy of Pediatrics

DEDICATED TO THE HEALTH OF ALL CHILDREN™



# PEDIATRICS®

OFFICIAL JOURNAL OF THE AMERICAN ACADEMY OF PEDIATRICS

## **Hypoplasia of Medullary Arcuate Nucleus in Unexpected Late Fetal Death (Stillborn Infants): A Pathologic Study**

Luigi Maturri, Iolanda Minoli, Anna Maria Lavezzi, Anna Cappellini, Simone Ramos  
and Lino Rossi

*Pediatrics* 2002;109:e43

DOI: 10.1542/peds.109.3.e43

The online version of this article, along with updated information and services, is  
located on the World Wide Web at:

<http://pediatrics.aappublications.org/content/109/3/e43>

Pediatrics is the official journal of the American Academy of Pediatrics. A monthly publication, it has been published continuously since 1948. Pediatrics is owned, published, and trademarked by the American Academy of Pediatrics, 141 Northwest Point Boulevard, Elk Grove Village, Illinois, 60007. Copyright © 2002 by the American Academy of Pediatrics. All rights reserved. Print ISSN: 1073-0397.

American Academy of Pediatrics

DEDICATED TO THE HEALTH OF ALL CHILDREN™

