

# Hepatobiliary Disease in Neonatal Lupus: Prevalence and Clinical Characteristics in Cases Enrolled in a National Registry

Lela A. Lee, MD\*; Ronald J. Sokol, MD†; and Jill P. Buyon, MD§

**ABSTRACT.** *Objective.* To extend the information base on the hepatobiliary manifestations of neonatal lupus erythematosus (NLE) with regard to frequency of occurrence, clinical characteristics, and outcome.

*Methods.* Review of records from the Research Registry for Neonatal Lupus.

*Results.* Nineteen (9%) of 219 patients who had NLE and were enrolled in a national registry had probable or possible NLE hepatobiliary disease. In 16 cases, hepatobiliary disease occurred in addition to cardiac or cutaneous NLE. In 3 cases, hepatobiliary disease occurred as the sole clinical manifestation of NLE. Three clinical variants of hepatobiliary disease were observed: 1) severe liver failure present during gestation or in the neonatal period, often with the phenotype of neonatal iron storage disease; 2) conjugated hyperbilirubinemia with mild or no elevations of aminotransferases, occurring in the first few weeks of life; and 3) mild elevations of aminotransferases occurring at approximately 2 to 3 months of life. The prognosis for the children in the last 2 categories is excellent.

*Conclusions.* Hepatobiliary disease is a relatively common finding in NLE and can be the sole clinical manifestation of NLE. Clinicians should be aware of the broad range of hepatobiliary disease that may occur in children with NLE. *Pediatrics* 2002;109(1). URL: <http://www.pediatrics.org/cgi/content/full/109/1/e11>; neonatal cholestasis, neonatal hepatitis.

ABBREVIATIONS, NLE, neonatal lupus erythematosus; CHB, congenital heart block.

Neonatal lupus erythematosus (NLE) is an uncommon autoimmune disease whose principal clinical characteristics are cardiac disease, notably congenital heart block, and cutaneous lupus lesions.<sup>1,2</sup> The principal serologic characteristics of NLE are anti-Ro/SSA and/or anti-La/SSB maternal autoantibodies, which are transferred across the placenta and can be detected in the affected child for the first few months of life. During the past decade, it has become clear that hepatobili-

ary disease may also occur as a manifestation of NLE. However, although several hundred cases of NLE have been reported, there are only a handful of case reports of NLE hepatobiliary disease.<sup>3-8</sup> Thus, there is little information about the clinical features and prognosis of NLE hepatobiliary disease. The relatively low number of cases reported is surprising in view of the fact that in the series of approximately 40 cases seen by 1 of the authors, 5 had hepatobiliary disease in addition to typical cardiac or cutaneous NLE lesions (L.A.L., personal observation).

A National Research Registry for NLE was established in 1994 to provide a database of potential use for clinicians, researchers, and affected families. The present study was performed using the NLE National Research Registry database to address the following questions: 1) How frequently does hepatobiliary disease occur as a manifestation of NLE? 2) What are the clinical characteristics and outcome of NLE hepatobiliary disease?

## METHODS

### Research Registry for Neonatal Lupus

The Research Registry for NLE was established in September 1994 by the National Institute of Arthritis, Musculoskeletal and Skin Diseases of the National Institutes of Health.<sup>9,10</sup> For the purposes of the registry, NLE is defined as 1) congenital heart block and anti-Ro/SSA or anti-La/SSB in the child or mother; or 2) cutaneous lesions consistent with NLE and documented by biopsy, photographs, or evaluation by a dermatologist and anti-Ro/SSA, anti-La/SSB, or anti-U1RNP in the child or mother (additional details available in Buyon et al<sup>9</sup> and Neiman et al<sup>11</sup>). Charts in the registry include, if applicable and available, medical information about the siblings of the affected child (index case).

Every chart in the registry was reviewed, specifically searching for the following: 1) liver function test results, 2) physical examination documentation of hepatomegaly or jaundice, and 3) additional evaluations performed if hepatobiliary disease was suspected. Cases were not reviewed when documentation for the diagnosis of NLE was inadequate or medical records were not available.

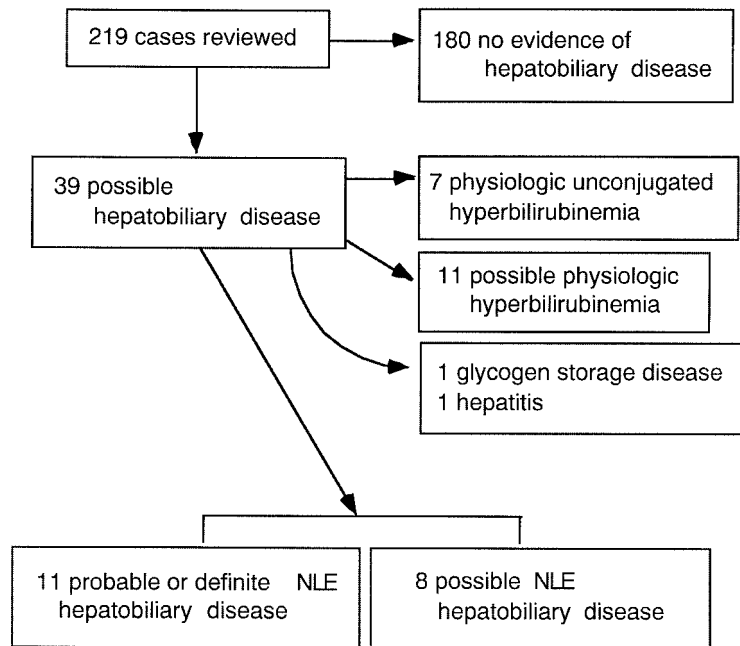
Cases classified as representing NLE hepatobiliary disease were segregated into "probable or definite" and "possible" NLE hepatobiliary disease. Cases were classified as "probable or definite" when the clinical and laboratory findings were consistent with previously reported cases of hepatobiliary disease in NLE. Cases that were classified as "possible" had a clinical course or laboratory findings distinct from that previously reported for NLE hepatobiliary disease.

## RESULTS

### Categorization of Cases

Of 219 charts that were reviewed (Fig 1), 39 patients were identified as potentially having hepatobiliary disease, based on abnormal liver function tests, jaundice or hepatomegaly on physical exami-

From the \*Departments of Dermatology and Medicine, University of Colorado School of Medicine, and Department of Medicine, Denver Health Medical Center, Denver, Colorado; †Section of Pediatric Gastroenterology, Hepatology and Nutrition, Children's Hospital, and Department of Pediatrics, University of Colorado School of Medicine, Denver, Colorado; and §Department of Rheumatology and Medicine, Hospital for Joint Diseases, New York University School of Medicine, New York, New York. Received for publication May 29, 2001; accepted Aug 29, 2001. Reprint requests to (L.A.L.) Denver Health Medical Center, Mail Code 4000 777 Bannock St, Denver, CO 80204. E-mail: lela.lee@uchsc.edu PEDIATRICS (ISSN 0031 4005). Copyright © 2002 by the American Academy of Pediatrics.



**Fig 1.** Categorization of hepatobiliary disease in cases reviewed from the Research Registry for Neonatal Lupus.

nation, or medical record or questionnaire notation of hepatobiliary disease. Of these 39 patients, 27 had elevated bilirubin levels, 1 had jaundice but without the bilirubin level stated, 4 had aminotransferase elevations with normal bilirubin levels, 3 had a history of hepatitis or liver disease noted in the questionnaire, 1 had an ultrasound examination showing hepatomegaly, and 3 had abnormal liver findings on autopsy. There were 180 cases for which there was no clinical evidence noted of hepatobiliary disease. In most of these cases, no specific information was given concerning liver function tests.

Eighteen of the 39 cases were excluded from additional analysis because they represented definite or possible physiologic unconjugated hyperbilirubinemia. In 7 cases, the hyperbilirubinemia was demonstrated to be unconjugated; in 11 additional cases, the bilirubin was not fractionated. In general, these cases were identified within the first few days of life and subsequent comments concerning jaundice or bilirubin levels did not appear in the chart. For the purposes of this study, the 11 cases without bilirubin fractionation are considered to have physiologic unconjugated hyperbilirubinemia, although some of these may have had conjugated hyperbilirubinemia.

Two patients had liver disease unrelated to NLE: in 1 case, the liver biopsy was consistent with glycogen storage disease; in the other, hepatitis was noted after age 1, an age of onset inconsistent with disease activity attributable to NLE.

Of the 19 remaining cases, 11 were considered to represent probable or definite NLE hepatobiliary disease and 8 possible NLE hepatobiliary disease. Most of the cases that were classified as “possible” had moderate elevations of aminotransferases in the absence of an alternative explanation.

#### NLE Hepatobiliary Disease Characteristics

Eleven patients were girls, and 8 were boys. There was no apparent association between hepatobiliary

disease and a specific clinical manifestation of NLE. Seven patients had congenital heart block (CHB), 8 had cutaneous NLE, and 1 had both CHB and cutaneous NLE. In 3 patients, hepatobiliary disease occurred as the sole clinical manifestation of NLE. (These data are shown separately for the “probable or definite” versus the “possible” NLE hepatobiliary disease groups in Table 1.)

For the 3 children who had hepatobiliary disease as their sole manifestation of NLE, the diagnosis of NLE was considered because a sibling was thought to have NLE and the mother had anti-Ro/SSA autoantibodies. In 1 case, the sibling had died at 24 weeks’ gestation of what a parent indicated was a problem with the heart. Although the presence of maternal anti-Ro/SSA autoantibodies was confirmed, medical records neither substantiated nor negated the diagnosis of heart block, and diagnosis of the index case was deemed to be indefinite. The other 2 cases of isolated hepatobiliary disease were siblings. The index case in that family had definite NLE with CHB. The subsequent 2 children were normal. The fourth child—and the first to have hepatobiliary disease—was noted to have liver failure at 2.5 weeks of age and died at 7 weeks of age (for the full case report, see Schoenlebe et al<sup>5</sup>). The fifth child—and the second sibling to have hepatobiliary disease—died at 6 days of age with hepatic failure.

**TABLE 1.** Gender and Clinical Manifestations of NLE in Cases Categorized as Probable or Definite NLE Hepatobiliary Disease and Possible NLE Hepatobiliary Disease

	Probable/Definite	Possible
Total	11	8
Female:male	8:3	3:5
CHB	4	3
Cutaneous NLE	4	4
CHB + cutaneous NLE	0	1
Neither CHB nor cutaneous NLE	3	0

These 19 cases represent a spectrum of hepatobiliary disease, ranging from fulminant liver failure to cholestatic liver disease to mild aminotransferase elevations. Six children had severe liver disease and died, either during gestation or within a few days or weeks after birth. In 4 of the 6 fatal cases, including the 3 with hepatobiliary disease as the sole manifestation of NLE, the liver pathology was consistent with neonatal iron storage disease (also termed "neonatal hemochromatosis"). In 1 case, the histologic findings were severe bile stasis and fibrotic hepatic atrophy, and in the sixth case (classified as "possible" NLE hepatobiliary disease), the histologic findings were massive coagulation necrosis of virtually all hepatocytes.

The 13 nonfatal cases either were noted to have resolution of hepatobiliary disease or had no specific notation about hepatobiliary function on follow-up. In 5 cases, the presentation was cholestasis, with conjugated hyperbilirubinemia but mild or no aminotransferase elevation. These cases generally presented within the first few weeks of life. In 6 cases, aminotransferase elevations, usually moderate (2–3 times the upper limit of normal), were noted without significant elevation of bilirubin and with no other explanation for the aminotransferase abnormality. These cases generally were detected at 2 to 3 months of life. In 1 case, classified as "possible" NLE hepatobiliary disease, liver disease was noted on the questionnaire but not otherwise described. In 1 additional case, also classified as "possible," no laboratory test results were available except for an ultrasound, which noted significant hepatomegaly. In both of these last cases, the child had NLE skin disease without cardiac disease.

In the group of children who died ( $n = 6$ ), 2 were boys and 4 were girls; 4 had CHB and 2 had no other findings of NLE; and 3 were black and 3 were white. In the group of children who lived ( $n = 13$ ), 6 were boys and 7 were girls; 4 had CHB, 8 had skin lesions, and 1 had both CHB and skin lesions; and 10 were white, 2 were Hispanic, and 1 was Asian.

### Subsequent Pregnancies

In the families of the 19 children with probable or possible NLE hepatobiliary disease, there were 5 pregnancies subsequent to that of the index case. Four of these pregnancies resulted in a healthy child with no manifestations of NLE noted. However, a male child, born subsequent to the birth of his female sibling who had neonatal iron storage, developed the same condition. His course was even more advanced in severity than that of his sibling, with an abnormal coagulation profile noted at age 2 days and death at age 6 days.

## DISCUSSION

In our review of the literature, we found 14 cases of NLE hepatobiliary disease.<sup>3–8,12–14</sup> Although the small number of cases reported seems to indicate that hepatobiliary disease is uncommon, our clinical impression was that this is an underestimate of the prevalence of hepatobiliary involvement in NLE. The results of this study confirm that approximately 10%

of cases of NLE have significant hepatobiliary involvement.

Cardiac NLE and cutaneous NLE commonly occur in the absence of other findings of NLE. Indeed, it is remarkable that cardiac and cutaneous NLE coexist so infrequently. Only approximately 10% of cases in the national registry have both cardiac and cutaneous disease. Given the frequency with which NLE manifests as disease of only 1 organ system, it would be surprising if hepatobiliary disease did not occasionally occur in the absence of other findings of NLE. However, to our knowledge, only 2 such cases have been previously reported, 1 of which is also included in this article.<sup>5,7</sup>

This study is subject to several caveats. First, in some cases, the child's NLE was diagnosed retrospectively. Thus, evidence for NLE hepatobiliary disease may not have been sought. Second, hepatobiliary disease may not be commonly recognized as a clinical manifestation of NLE and so may have been underreported. Third, jaundice is a common condition in newborns; thus, healthy-appearing children with jaundice may have been assumed to have physiologic jaundice of the newborn. Fourth, hepatomegaly and liver function test abnormalities may be attributed to congestive heart failure in children with cardiac NLE. Fifth, infants who are not visibly jaundiced typically do not undergo investigation for hepatobiliary disease. Therefore, for most cases in the registry, data are not available concerning liver function tests. The effect of all of the above is to underestimate the frequency of hepatobiliary disease in the NLE population. Thus, the data presented in this report should be viewed as representing the minimal prevalence of hepatobiliary disease in NLE.

It is remarkable that in 4 cases, the clinical and histologic phenotype was that of neonatal iron storage disease, also referred to as "neonatal hemochromatosis." This condition, unrelated to hemochromatosis of adults, is of uncertain cause.<sup>15</sup> It may be a phenotype resulting from any of a number of different causes.<sup>15–17</sup> The observation of a clinical and histologic picture consistent with neonatal iron storage disease in 4 children in this series may indicate that NLE should be sought in "idiopathic" cases of neonatal iron storage disease.

There were no clear-cut prognostic indicators for severe hepatobiliary disease. In comparing the group of 6 children who died with the 13 children who lived, it is not surprising that cutaneous NLE lesions are underrepresented in the children who died, as the skin lesions would not generally have had time to develop. The overrepresentation of black children in the group of children who died raises the possibility that ethnicity may be a risk factor for severe disease. However, the small number of children in the group with severe disease precludes a definite conclusion about ethnicity and prognosis.

## CONCLUSION

Nineteen (9%) of 219 patients who had NLE and were enrolled in a national registry had probable or possible NLE hepatobiliary disease. In 16 patients, hepatobiliary disease occurred in addition to cardiac

or cutaneous NLE. In 3 patients, hepatobiliary disease occurred as the sole clinical manifestation of NLE. Three clinical variants of hepatobiliary disease were apparent in this series: 1) severe liver failure present during gestation or in the neonatal period, often with the phenotype of neonatal iron storage disease; 2) conjugated hyperbilirubinemia with mild or no elevations of aminotransferase, occurring in the first few weeks of life; and 3) mild elevations of aminotransferase occurring at approximately 2 to 3 months of life. The prognosis for the children in the last 2 categories is excellent.

#### ACKNOWLEDGMENTS

This work was supported by National Institutes of Health Grant DK53754 and by National Institute for Arthritis, Musculoskeletal and Skin Diseases Contract No. NO1-AR-4-2220 (Research Registry for Neonatal Lupus).

We acknowledge the able assistance of Peg Katholi at the Research Registry for Neonatal Lupus.

#### REFERENCES

1. Lee LA. Neonatal lupus erythematosus. *J Invest Dermatol.* 1993;100:9S–13S
2. Buyon JP. Neonatal lupus. *Curr Opin Rheumatol.* 1996;8:485–490
3. Laxer RM, Roberts EA, Gross KR, et al. Liver disease in neonatal lupus erythematosus. *J Pediatr.* 1990;116:238–242
4. Lee LA, Reichlin M, Ruyle SZ, Weston WL. Neonatal lupus liver disease. *Lupus.* 1993;2:333–338
5. Schoenlebe J, Buyon JP, Zitelli BJ, Friedman D, Greco MA, Knisely AS. Neonatal hemochromatosis associated with maternal autoantibodies against Ro/SS-A and La/SS-B ribonucleoproteins. *Am J Dis Child.* 1993;147:1072–1075
6. Evans N, Gaskin K. Liver disease in association with neonatal lupus erythematosus. *J Paediatr Child Health.* 1993;29:478–480
7. Selander B, Cedergren S, Domanski H. A case of severe neonatal lupus erythematosus without cardiac or cutaneous involvement. *Acta Paediatr.* 1998;87:105–107
8. Rosh JR, Silverman ED, Groisman G, Dolgin S, LeLeiko NS. Intrahepatic cholestasis in neonatal lupus erythematosus. *J Pediatr Gastroenterol Nutr.* 1993;17:310–312
9. Buyon JP, Hiebert R, Copel J, et al. Autoimmune-associated congenital heart block: demographics, mortality, morbidity and recurrence rates obtained from a national neonatal lupus registry. *J Am Coll Cardiol.* 1998;31:1658–1666
10. Mayes MD, Giannini EH, Pachman LM, Buyon JP, Fleckman P. Connective tissue disease registries. *Arthritis Rheum.* 1997;40:1556–1559
11. Neiman AR, Lee LA, Weston WL, Buyon JP. Cutaneous manifestations of neonatal lupus without heart block: characteristics of mothers and children enrolled in a national registry. *J Pediatr.* 2000;137:674–680
12. Franco HL, Weston WL, Peebles C, Forstot SL, Phanuphak P. Autoantibodies directed against sicca syndrome antigens in the neonatal lupus syndrome. *J Am Acad Dermatol.* 1981;4:67–72
13. Miyagawa S, Kitamura W, Yoshioka J, Sakamoto K. Placental transfer of anticytoplasmic antibodies in annular erythema of newborns. *Arch Dermatol.* 1981;117:569–572
14. Taylor-Albert E, Reichlin M, Toews WH, Overholt ED, Lee LA. Delayed dilated cardiomyopathy as a manifestation of neonatal lupus: case reports, autoantibody analysis, and management. *Pediatrics.* 1997;99:733–735
15. Vohra P, Haller C, Emre S, et al. Neonatal hemochromatosis: the importance of early recognition of liver failure. *J Pediatr.* 2000;136:537–541
16. Sifakos CG, Jonas MM, Perez-Atayde AR. Abnormal bile acid metabolism and neonatal hemochromatosis: a subset with poor prognosis. *J Pediatr Gastroenterol Nutr.* 1997;25:321–326
17. Sigurdsson L, Reyes J, Kocoshis SA, Hansen TW, Rosh J, Knisely AS. Neonatal hemochromatosis: outcomes of pharmacologic and surgical therapies. *J Pediatr Gastroenterol Nutr.* 1998;26:85–89

## Hepatobiliary Disease in Neonatal Lupus: Prevalence and Clinical Characteristics in Cases Enrolled in a National Registry

Lela A. Lee, Ronald J. Sokol and Jill P. Buyon

*Pediatrics* 2002;109:e11

DOI: 10.1542/peds.109.1.e11

### Updated Information & Services

including high resolution figures, can be found at:  
<http://pediatrics.aappublications.org/content/109/1/e11>

### References

This article cites 17 articles, 1 of which you can access for free at:  
<http://pediatrics.aappublications.org/content/109/1/e11#BIBL>

### Subspecialty Collections

This article, along with others on similar topics, appears in the following collection(s):  
**Gastroenterology**  
[http://www.aappublications.org/cgi/collection/gastroenterology\\_sub](http://www.aappublications.org/cgi/collection/gastroenterology_sub)  
**Hepatology**  
[http://www.aappublications.org/cgi/collection/hepatology\\_sub](http://www.aappublications.org/cgi/collection/hepatology_sub)

### Permissions & Licensing

Information about reproducing this article in parts (figures, tables) or in its entirety can be found online at:  
<http://www.aappublications.org/site/misc/Permissions.xhtml>

### Reprints

Information about ordering reprints can be found online:  
<http://www.aappublications.org/site/misc/reprints.xhtml>

# American Academy of Pediatrics

DEDICATED TO THE HEALTH OF ALL CHILDREN®



# PEDIATRICS®

OFFICIAL JOURNAL OF THE AMERICAN ACADEMY OF PEDIATRICS

## **Hepatobiliary Disease in Neonatal Lupus: Prevalence and Clinical Characteristics in Cases Enrolled in a National Registry**

Lela A. Lee, Ronald J. Sokol and Jill P. Buyon

*Pediatrics* 2002;109:e11

DOI: 10.1542/peds.109.1.e11

The online version of this article, along with updated information and services, is located on the World Wide Web at:

<http://pediatrics.aappublications.org/content/109/1/e11>

Pediatrics is the official journal of the American Academy of Pediatrics. A monthly publication, it has been published continuously since 1948. Pediatrics is owned, published, and trademarked by the American Academy of Pediatrics, 345 Park Avenue, Itasca, Illinois, 60143. Copyright © 2002 by the American Academy of Pediatrics. All rights reserved. Print ISSN: 1073-0397.

American Academy of Pediatrics

DEDICATED TO THE HEALTH OF ALL CHILDREN®

