

# Congenital Hypomyelination Neuropathy in a Newborn Infant: Unusual Cause of Diaphragmatic and Vocal Cord Paralyzes

Jin S. Hahn, MD\*; Marion Henry; Louanne Hudgins, MD‡; and Ashima Madan, MD‡

**ABSTRACT.** We report a case of congenital hypomyelination neuropathy presenting at birth. The infant had generalized hypotonia and weakness. There was decreased respiratory effort along with a right phrenic nerve and left vocal cord paralyzes. Tongue fasciculations were present. Deep tendon reflexes were absent in the upper extremities and hypoactive (1+) in the lower extremities. Magnetic resonance imaging of the head revealed no intracranial abnormalities, including normal cerebral myelination. Nerve conduction study showed absence of motor and sensory action potentials in the hands when the nerves in the upper limbs were stimulated. A motor response could be elicited only in the proximal leg muscles. Needle electromyography study was normal in the proximal limb muscles, but showed active denervation in the distal muscles of the arm and leg. These findings were thought to be consistent with a length-dependent sensorimotor peripheral polyneuropathy of axonal type with greater denervation of the distal muscles. A biopsy of the quadriceps muscle showed mild variability in fiber diameter, but no group typing or group atrophy. The muscle fibers showed no intrinsic abnormalities. Biopsy of the sural nerve showed scattered axons with very thin myelin sheaths. There was also a nearly complete loss of large diameter myelinated fibers. No onion bulb formations were noted. These findings were thought to be consistent with congenital hypomyelination neuropathy with a component of axonopathy. DNA analysis for identification of previously characterized mutations in the genes MPZ, PMP22, and EGR2 was negative.

Several attempts at extubation failed and the infant became increasingly ventilator-dependent with increasing episodes of desaturation and hypercapnea. He also developed increasing weakness and decreased movement of all extremities. He underwent surgery at 2 months of age for placement of a gastrostomy tube and a tracheostomy. He was discharged from the hospital on a ventilator at 6 months of age. The infant was 13 months old at the time of submission of this report. Although he appears cognitively normal, he remains profoundly hypotonic and is on a home ventilator. There was no evidence of progressive weakness.

Congenital hypomyelination neuropathy is a rare form of neonatal neuropathy that should be considered in the differential diagnosis of a newborn with profound hypotonia and weakness. It appears to be a heterogeneous disorder with some of the cases being caused by specific

genetic mutations. *Pediatrics* 2001;108(5). URL: <http://www.pediatrics.org/cgi/content/full/108/5/e95>; *congenital peripheral neuropathy, myelin, hypomyelination*.

ABBREVIATIONS. CHN, congenital hypomyelination neuropathy; EMG, electromyogram; HMSN, hereditary motor and sensory neuropathy; DSS, Dejerine-Sotat syndrome; EGR2, early growth response 2 gene; PMP 22, peripheral myelin protein 22 gene; MPZ or MP0, myelin protein zero gene; Cx32/GJB1, connexin32 gene.

When faced with a newborn with severe hypotonia and weakness in the absence of an encephalopathy, pediatricians often consider neuromuscular disorders. Among these neuromuscular disorders, spinal muscular atrophy and congenital muscular dystrophies come to mind because they are the more common cause of neuromuscular disorders in newborns. Congenital neuropathies in general are rare. We report a case of congenital hypomyelination neuropathy (CHN) to bring attention to this rare form of congenital neuropathy that can cause severe hypotonia and weakness in the newborn period. CHN is a rare condition characterized by distal weakness, hypotonia, areflexia, slow nerve conduction, and absence of large myelinated nerve fibers. Patients may present either in the neonatal period with weakness and hypotonia or during infancy with hypotonia and developmental delay. Little is known about the long-term outcome of neonates presenting with CHN, but the neonatal form appears to be more severe, often leading to early mortality.<sup>1</sup> The infantile form appears to be more benign, and thus can result in longer survival.

The neonatal form of CHN is indeed rare. To date only 15 cases have been reported.<sup>1</sup> In some of these cases DNA mutations have been identified in the MPZ gene, PMP22 gene, or EGR2 gene.<sup>1-6</sup> We report a case of CHN presenting at birth with generalized hypotonia and decreased respiratory effort. This form of congenital neuropathy should be considered in severely hypotonic and weak neonates.

## CASE REPORT

This infant was a 2800-g male product of a 40-week gestation. He was born to a 39-year-old gravida 4 para 2312 female of Hispanic origin who had received good prenatal care. The pregnancy was reported to be normal with no history of decreased fetal movements. There was no known exposure to teratogens or medications. The infant has 2 elder brothers, who are reportedly healthy and developmentally normal. Family history was negative for birth defects, genetic diseases, multiple miscarriages, and neurologic or neuromuscular disease. There was no consanguinity. He was delivered by normal spontaneous vaginal delivery and had Apgar scores of 8 at 1 minute and 9 at 5 minutes.

From the Departments of \*Neurology and Neurological Sciences and ‡Pediatrics, Stanford University School of Medicine, Lucile Packard Children's Hospital at Stanford, Stanford, California.

Received for publication Apr 10, 2001; accepted Jun 20, 2001.

Reprint requests to (J.S.H.) Department of Neurology, A343, 300 Pasteur Dr, Stanford, CA 94305-5235. E-mail: [jhahn@stanford.edu](mailto:jhahn@stanford.edu)

PEDIATRICS (ISSN 0031 4005). Copyright © 2001 by the American Academy of Pediatrics.

At approximately 2 hours of age he developed grunting, nasal flaring, and retractions. He later developed an inspiratory stridor and mild oxygen desaturation, necessitating administration of supplemental oxygen by an oxyhood. A sepsis work-up was initiated. A chest radiograph performed at the referring hospital showed an elevation of the right hemidiaphragm. The infant was intubated, placed on the ventilator on low settings, and transferred to Lucile Packard Children's Hospital at Stanford.

The physical examination revealed a nondysmorphic infant with decreased respiratory effort and generalized hypotonia who was intubated and on a ventilator. He was alert and awake. His head was normocephalic. The face appeared normal, but micrognathia and high-arched palate were present. The extremities were normal in length and proportion. His hands were in a "raking" position with flexion of the middle and distal interphalangeal joints. He had proximally placed thumbs and a transverse left palmar crease.

Cranial nerve examination showed normal ocular movements and pupillary responses to light. Tongue fasciculations were present. He was profoundly hypotonic, although he was able to move all extremities spontaneously against gravity. He was noted to have decreased wrist movement, finger extension, and flexion. Sensation appeared intact to tactile stimulation. Deep tendon reflexes were absent in the upper extremities and hypoactive (1+) in the lower extremities. Babinski signs were absent.

Creatine phosphokinase level was 244 IU/L. Serum electrolytes were within normal limits. Serum lactate was mildly elevated at 3.1 mmol/L. Leukocyte lysosomal enzyme screen study, urine organic acids, and serum amino acids were normal. The infant had normal ophthalmologic and audiology examinations. High-resolution chromosome analysis was normal (46, XY).

He was extubated on the second day and weaned to room air. However, he was noted to have occasional desaturation episodes attributable to poor respiratory effort.

A fluoroscopy examination confirmed the presence of right diaphragm paralysis. He underwent a direct laryngoscopy examination that revealed a left-sided vocal cord paralysis and right-sided decreased vocal cord mobility. Magnetic resonance imaging of the head revealed no intracranial abnormalities, including normal cerebral myelination. An electromyogram (EMG)/nerve conduction study showed absence of motor and sensory action po-

tentials in the hands to electrical stimulation of the upper limb. A motor response could be elicited only in the proximal leg muscles. Needle EMG findings showed normal patterns in the proximal limb muscles, but there was evidence of active denervation in the distal muscles of the arm and leg. These findings were thought to be consistent with a length-dependent sensorimotor peripheral polyneuropathy of axonal type with greater denervation of the distal muscles.

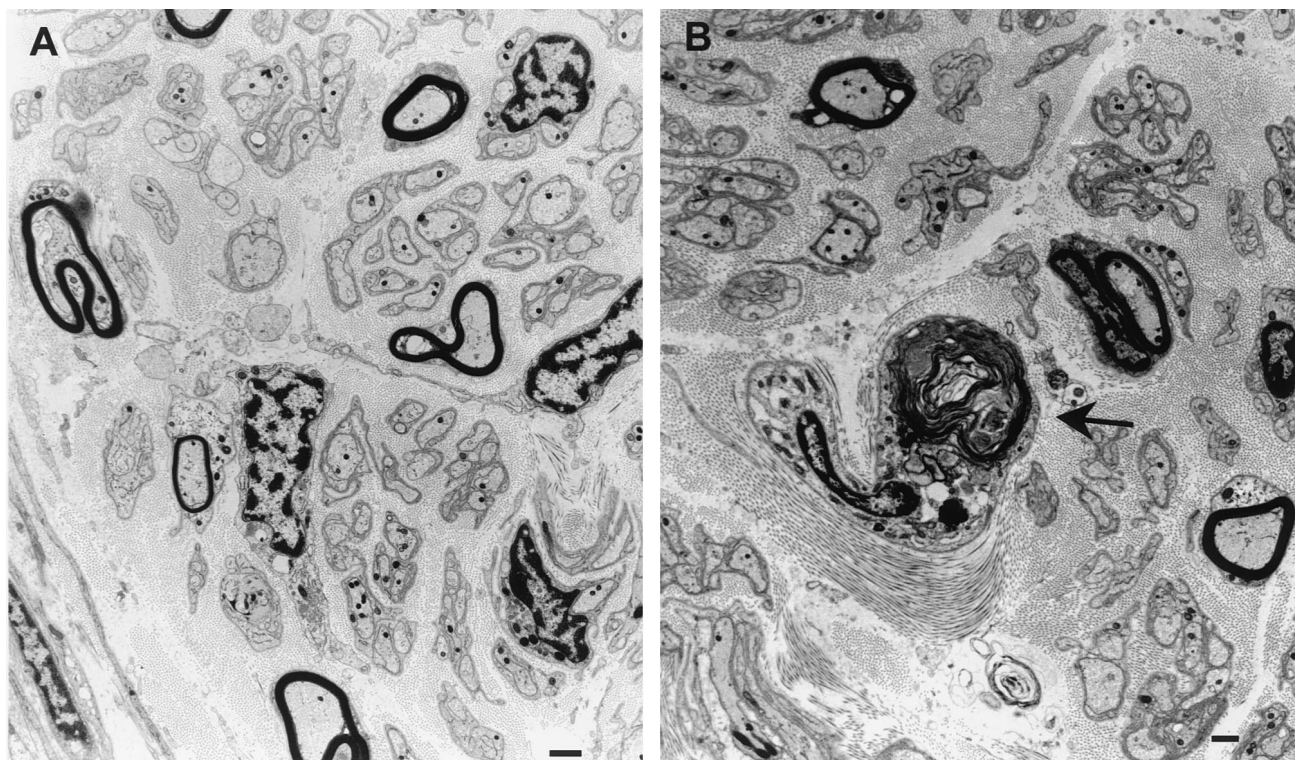
He had some feeding problems initially attributable to poor sucking but was breastfeeding well by 3 weeks of age. He was discharged from the hospital at 3 weeks of age.

He was readmitted to Lucile Packard Children's Hospital at Stanford at 1 month of age because of cyanosis and an apneic episode. The chest radiograph was consistent with atelectasis or pneumonia. A severe apneic episode necessitated intubation, and he was placed on the ventilator.

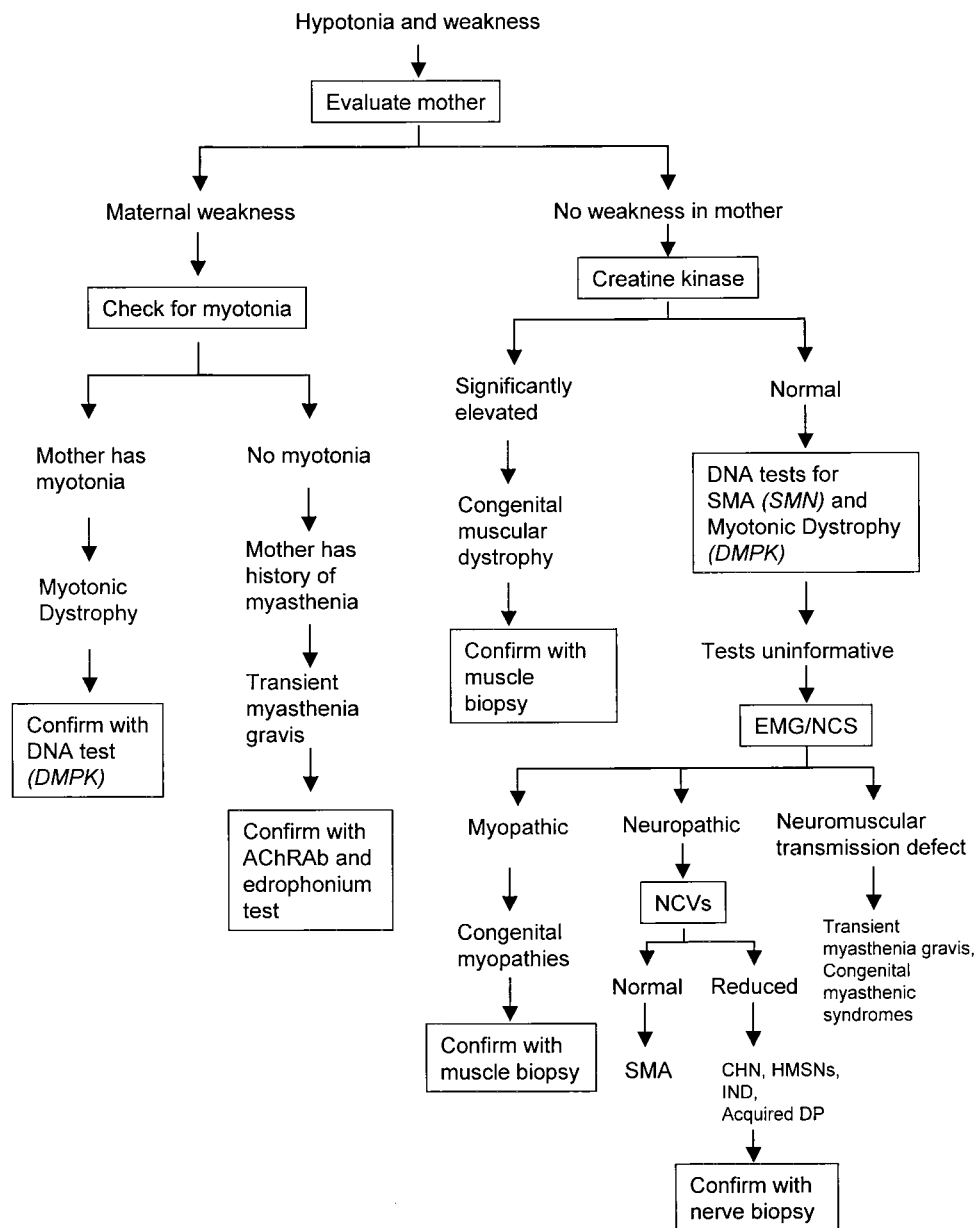
The infant underwent a left quadriceps and left sural nerve biopsy during this admission. The muscle biopsy showed mild variability in fiber diameter but no group typing or group atrophy. The muscle fibers showed no intrinsic abnormalities. Biopsy of the sural nerve showed scattered axons with very thin myelin sheaths (Fig 1A). There was also a nearly complete loss of large diameter myelinated fibers. No onion bulb formations were noted. In addition, there were rare axons undergoing Wallerian degeneration (Fig 1B). These findings were thought to be consistent with congenital hypomyelination neuropathy with a component of axonopathy.

DNA analysis for identification of previously characterized mutations in the genes *MPZ*, *PMP22*, and *EGR2* was negative.

During this hospitalization, several attempts at extubation failed and the infant became increasingly ventilator-dependent with increasing episodes of desaturation and hypercapnea. He also developed increasing weakness and decreased movement of all extremities. He underwent surgery at 2 months of age for placement of a gastrostomy tube and a tracheostomy. He was discharged from the hospital on a ventilator at 6 months of age. The infant is currently 13 months old, and his motor function appears to be stable. He remains ventilator-dependent for respirations.



**Fig 1.** Electron microscopic examination of the sural nerve demonstrates marked reduction in the number of large myelinated fibers and scattered large axons with thin myelin sheaths (A). There are occasional large axons undergoing Wallerian degeneration (arrow, B). No onion bulb formations were seen. Bars represent 1  $\mu$ m.



**Fig 2.** An algorithm for approaching a newborn with hypotonia and weakness attributable to a disorder of the motor unit. The motor unit includes the anterior horn cell, peripheral nerve, neuromuscular junction, and muscle. Central causes of hypotonia and weakness are not considered in this diagram. AChRAb indicates acetylcholine receptor antibody; EMG/NCS, electromyography/nerve conduction studies; NCV, nerve conduction velocity; SMA, spinal muscular atrophy; CHN, congenital hypomyelination neuropathy; HMSNs, hereditary motor and sensory neuropathy; IND, infantile neuronal degeneration; DP, demyelinating polyneuropathy.

## DISCUSSION

Only a few cases of neonatal CHN have been described in medical literature. Hypotonia was a common feature in all of the previously reported cases of neonatal CHN.<sup>1</sup> The neonatal course is characterized by severe weakness often leading to ventilator support, delayed motor development, and death from 5 weeks to 7 years of age. Nerve biopsy usually shows severe hypomyelination of the nerve fibers. Onion bulbs, which represent reinnervation, may or may not be present in CHN.

The neurologic findings in the present case were significant for profound weakness in the distal muscles encompassing multiple peripheral nerves. This is a somewhat unusual distribution of neuromuscu-

lar weakness in newborns, who usually have more proximal weakness.

The differential diagnosis of isolated peripheral neuropathy in newborns and infants includes CHN, Charcot-Marie-Tooth disease, spinal muscular atrophy, hereditary motor and sensory neuropathies (HMSNs), Dejerine-Sotat syndrome (DSS), infantile neuronal degeneration, and acquired demyelinating polyneuropathy.

CHN shares many characteristics HMSN III (or DSS). DSS is also a congenital neuropathy that presents in childhood with hypotonia and weakness and slow nerve conductions.

In patients with various forms of HMSN, more than 250 distinct mutations have been identified in

various genes, including the early growth response 2 gene (EGR2), peripheral myelin protein 22 gene (PMP 22), myelin protein zero gene (MPZ or MP0) and connexin32 gene (Cx32/GJB1). To date there have been 15 cases reported of neonatal CHN. In some of these cases, mutations have been identified in the MPZ gene, PMP22 gene, or the EGR2 gene.<sup>1–6</sup> CHN, therefore, appears to be a heterogeneous disorder, as several distinct genetic mutations can cause a similar clinical and pathologic picture.

There is considerable overlap between the clinical presentation as well as nerve conduction studies among the different neuropathies. A nerve biopsy is essential in making the diagnosis. In DSS and CHN the biopsy shows hypomyelination. Some consider CHN to be an extreme form of DSS. Our case is somewhat unusual in that there was absence of onion bulb formation. This finding is often, but not always, reported in CHN. Onion bulb formation is a sign of reinnervation. In our patient, there did not seem to be evidence of reinnervation, at least not in the sural nerve. Our case was also unusual in that there was evidence of some Wallerian degeneration in some of the axons. This implies that there is a component of axonopathy in our patient, in addition to the hypomyelination. The EMG also found evidence of axonopathy. This is somewhat atypical, because axonopathy is not usually seen in CHN.

The quadriceps muscle biopsy revealed no evidence of denervation. This is not surprising because the EMG of the proximal muscles showed normal patterns, while the distal muscles showed electrophysiological evidence of active denervation. Therefore, the lack of denervation seen in the quadriceps may reflect the length-dependent nature of the severity of the neuropathy.

Our case was also unusual in that there was hemidiaphragmatic and vocal cord paralyzes. These findings suggest neuropathy affecting the phrenic and vagus nerve, respectively. These specific types of denervation have not been reported previously in neonatal CHN.

Infantile neuronal degeneration is a rare form of congenital polyneuropathy that share features with CHN. However, in addition to hypomyelination of peripheral nerves, in infantile neuronal degeneration there is diffuse neuronal loss in the central nervous system.<sup>7</sup> The neuronal loss occurs in the anterior horn cells, motor nuclei of the brainstem, cerebellum, pons, and thalamus. In our case, the magnetic resonance imaging study of the brain was normal, making this diagnosis less likely.

Although very rare in newborns, acquired demyelinating polyneuropathy may present with hypotonia in the neonatal period. The postulated immune-mediated process that causes demyelination may

even start in utero. Infants with this disorder may have a fluctuating course of weakness and may even improve spontaneously. It is important to consider acquired demyelinating polyneuropathy because immunosuppressive agents may expedite recovery.

In our case, no mutations were found in MPZ, PMP22, and EGR2. Cx32 has not yet been studied in this patient. Given that this child had an unusual form of CHN with axonopathy, it is possible that the patient has an unusual as yet uncharacterized mutation in another gene. CHN appears to be a heterogeneous disorder resulting from many different mutations.

When faced with a newborn with extreme hypotonia and weakness, molecular tests will be useful for certain diagnoses (eg, spinal muscular atrophy, congenital muscular dystrophy, and congenital myotonic dystrophy). However, when these tests are negative and the electrophysiologic studies suggest a peripheral neuropathy, a nerve biopsy may be required to establish the diagnosis. An algorithm for approaching a newborn with hypotonia and weakness attributable to a disorder of the motor unit is shown in Fig 2.

This rare form of neonatal neuropathy should be considered in the differential diagnosis of a newborn with profound hypotonia and weakness. Recent advances in molecular genetics will allow us to make the diagnosis less invasively in some cases. Perhaps with greater recognition of this rare condition, we will gain an understanding of the natural history and various modes of presentation of this disease. A national registry for such rare disorders would be helpful for advancing our knowledge about this disease and other disorders that are yet undefined by a specific gene mutation.

## REFERENCES

1. Phillips JP, Warner LE, Lupski JR, Garg BP. Congenital hypomyelinating neuropathy: two patients with long-term follow-up. *Pediatr Neurol*. 1999;20:226–232
2. Wrabetz L, Feltri ML, Quattrini A, et al. P(0) glycoprotein overexpression causes congenital hypomyelination of peripheral nerves. *J Cell Biol*. 2000;148:1021–1034
3. Fabrizi GM, Simonati A, Taioli F, et al. PMP22 related congenital hypomyelination neuropathy. *J Neurol Neurosurg Psychiatry*. 2001;70:123–126
4. Mandich P, Mancardi GL, Varese A, et al. Congenital hypomyelination due to myelin protein zero Q215X mutation. *Ann Neurol*. 1999;45:676–678
5. Simonati A, Fabrizi GM, Rasquinelli A, et al. Congenital hypomyelination neuropathy with Ser72Leu substitution in PMP22. *Neuromuscul Disord*. 1999;9:257–261
6. Warner LE, Svaren J, Milbrandt J, Lupski JR. Functional consequences of mutations in the early growth response 2 gene (EGR2) correlate with severity of human myelinopathies. *Hum Mol Genet*. 1999;8:1245–1251
7. Steiman GS, Rorke LB, Brown MJ. Infantile neuronal degeneration masquerading as Werdnig-Hoffman disease. *Ann Neurol*. 1980;8:317–324

**Congenital Hypomyelination Neuropathy in a Newborn Infant: Unusual Cause of Diaphragmatic and Vocal Cord Paralyses**

Jin S. Hahn, Marion Henry, Louanne Hudgins and Ashima Madan

*Pediatrics* 2001;108;e95

DOI: 10.1542/peds.108.5.e95

<b>Updated Information &amp; Services</b>	including high resolution figures, can be found at: <a href="http://pediatrics.aappublications.org/content/108/5/e95">http://pediatrics.aappublications.org/content/108/5/e95</a>
<b>References</b>	This article cites 7 articles, 2 of which you can access for free at: <a href="http://pediatrics.aappublications.org/content/108/5/e95#BIBL">http://pediatrics.aappublications.org/content/108/5/e95#BIBL</a>
<b>Subspecialty Collections</b>	This article, along with others on similar topics, appears in the following collection(s): <b>Neurology</b> <a href="http://www.aappublications.org/cgi/collection/neurology_sub">http://www.aappublications.org/cgi/collection/neurology_sub</a>
<b>Permissions &amp; Licensing</b>	Information about reproducing this article in parts (figures, tables) or in its entirety can be found online at: <a href="http://www.aappublications.org/site/misc/Permissions.xhtml">http://www.aappublications.org/site/misc/Permissions.xhtml</a>
<b>Reprints</b>	Information about ordering reprints can be found online: <a href="http://www.aappublications.org/site/misc/reprints.xhtml">http://www.aappublications.org/site/misc/reprints.xhtml</a>

American Academy of Pediatrics

DEDICATED TO THE HEALTH OF ALL CHILDREN™



# PEDIATRICS®

OFFICIAL JOURNAL OF THE AMERICAN ACADEMY OF PEDIATRICS

## **Congenital Hypomyelination Neuropathy in a Newborn Infant: Unusual Cause of Diaphragmatic and Vocal Cord Paralyses**

Jin S. Hahn, Marion Henry, Louanne Hudgins and Ashima Madan

*Pediatrics* 2001;108:e95

DOI: 10.1542/peds.108.5.e95

The online version of this article, along with updated information and services, is located on the World Wide Web at:

<http://pediatrics.aappublications.org/content/108/5/e95>

Pediatrics is the official journal of the American Academy of Pediatrics. A monthly publication, it has been published continuously since 1948. Pediatrics is owned, published, and trademarked by the American Academy of Pediatrics, 141 Northwest Point Boulevard, Elk Grove Village, Illinois, 60007. Copyright © 2001 by the American Academy of Pediatrics. All rights reserved. Print ISSN: 1073-0397.

American Academy of Pediatrics

DEDICATED TO THE HEALTH OF ALL CHILDREN™

