

Varicella in a Pediatric Heart Transplant Population on Nonsteroid Maintenance Immunosuppression

Debra A. Dodd, MD*; Judy Burger, RN*; Kathryn M. Edwards, MD‡; and J. Stephen Dummer, MD§

ABSTRACT. *Objective.* Varicella-zoster virus has been reported to produce serious, often life-threatening, disease in immunosuppressed patients with a variety of diagnoses. The impact of this virus on the young child after heart transplantation has not been reported.

Methods. We reviewed the charts of 28 children who were <10 years of age at heart transplantation and had at least 1 year of follow-up. The median follow-up period was 7 years (1.4–13.0 years). All were seronegative for varicella-zoster virus before transplantation. Fourteen (50%) developed varicella at a median time posttransplantation of 3.3 years. The first 7 were admitted for intravenous acyclovir for 3 days followed by oral acyclovir for 7 days. The last 7 were treated as outpatients with oral valacyclovir for 7 days ($n = 6$) or with oral acyclovir for 10 days ($n = 1$).

Results. Intravenous and oral regimens both were well tolerated and were without complications. No patient was receiving steroids at the time that they developed their initial episode of varicella. One patient was receiving steroids for therapy of posttransplantation lymphoproliferative disease when she developed recurrent varicella or generalized zoster. No episodes of rejection were attributed to the varicella-zoster virus infection. There were no episodes of localized zoster. All patients experienced seroconversion from undetectable to detectable antibody titers early after varicella, and 12 of the 14 patients continued to have persistent detectable titers in late follow-up. Two of the 14 who received chemotherapy or enhanced immunosuppression after retransplantation transiently lost detectable varicella-zoster virus antibodies but currently have detectable titers.

Conclusions. Primary varicella-zoster infection was well tolerated in our young pediatric heart transplant recipients, with no serious complications. We now reserve inpatient/intravenous therapy for those who are unable to tolerate oral medications or those who are receiving enhanced immunosuppression. *Pediatrics* 2001; 108(5). URL: <http://www.pediatrics.org/cgi/content/full/108/5/e80>; *heart transplantation, varicella, pediatric.*

ABBREVIATIONS. VZIG, varicella-zoster immune globulin.

From the Department of Pediatrics, *Division of Pediatric Cardiology, †Division of Pediatric Infectious Disease, and §Department of Medicine/Infectious Disease, Vanderbilt University School of Medicine, Nashville, Tennessee.

Received for publication Sep 26, 2000; accepted Jun 13, 2001.

Reprint requests to (D.A.D.) Division of Pediatric Cardiology, Vanderbilt University Medical Center, D-2220 MCN, Nashville, TN 37232-2572. E-mail: debra.dodd@mcmail.vanderbilt.edu

PEDIATRICS (ISSN 0031 4005). Copyright © 2001 by the American Academy of Pediatrics.

Varicella is a common childhood illness that has been noted to cause increased morbidity and often life-threatening disease in patients who are on immunosuppression after organ transplantation. Fortunately, the majority of organ transplant recipients have varicella before transplantation. Many of the remainder can electively receive varicella vaccine before transplantation with an anticipated reduction in both the incidence and the severity of illness. We chose to review our experience in infants and young children who were undergoing heart transplantation. These patients are unique from several standpoints: 1) they are primarily seronegative before transplantation, 2) they often are too young or too sick to receive vaccination before transplantation, 3) they are treated primarily with steroid-free immunosuppressive regimens, and 4) their outcome with varicella-zoster virus infections has not been reported.

METHODS

We reviewed the charts of all patients who were <10 years of age at the time of orthotopic heart transplantation and had at least 1 year of follow-up after transplantation. Twenty-eight patients met these criteria for the period April 1986 through December 1999. The median age at transplantation was 96 days (range: 13 days–8.4 years), and the median follow-up was 7 years (range: 1.4–13.0 years). All patients were seronegative for varicella-zoster virus at transplantation either by assumption (neonates; $n = 17$) or by measurement (infants and older children; $n = 11$). In addition to the pretransplant varicella-zoster virus titers, follow-up titers were checked at annual follow-up visits. The assay used from 1986 to 1994 was immunofluorescence assay (from 1986 to 1993, Electro Nucleonics Inc, Columbia, MD; from 1993 to 1994, Schiaparelli Biosystems Inc, Fairfield, NJ). Since 1994, samples have been screened by enzyme immunoassay (from 1994 to 1996, Whittaker Bioproducts, Walkersville, MD; from 1996 to present, Gull Laboratories, Salt Lake City, UT), which is less sensitive in our hands, and then all negatives are assayed by immunofluorescence assay (from 1994 to 1995, Schiaparelli Biosystems Inc; from 1995 to present, Hemagen Diagnostics, Waltham, MA). By chance, no pediatric heart transplant patients who were <10 years of age had detectable titers before transplantation; therefore, no exclusions were made on the basis of baseline positive varicella-zoster virus serology. As noted below, 1 patient in this age group never tolerated the wean from steroids, but that patient never developed varicella. Two patients died during follow-up: 1 who died 9.5 years after transplantation had varicella infection 13 months after transplantation, and 1 who died 5 years after transplantation was still seronegative. No other patients were lost to follow-up.

Our induction immunosuppression protocol during this time period included cyclosporine A, azathioprine, and steroids \pm antithymocyte globulin (rabbit ATG/Nashville). The protocol for infants is intravenous methylprednisolone for 3 days followed by no maintenance oral steroids; the protocol for older children is intravenous methylprednisolone for 3 days followed by a taper from oral prednisone over several months. Some of the earliest children to receive transplantation remained on prednisone for a

longer period before the adoption of this protocol. The actual prednisone course for the study patients was no maintenance steroids ($n = 13$), maintenance steroid taper over median of 3.5 months (range: 1.3–57 months; $n = 14$), and never weaned from steroids ($n = 1$). Eighteen of the 28 patients received antithymocyte globulin as part of induction.

Twenty-three of the 28 patients received cytomegalovirus prophylaxis with oral acyclovir for a median of 6 months (range: 3–15 months) after transplantation. Two patients received intravenous ganciclovir during the first 1 to 2 months after transplantation. Known varicella exposures have received varicella-zoster immune globulin (VZIG) prophylaxis within 96 hours of exposure. The diagnosis of varicella was made clinically on the basis of the typical generalized vesicular exanthem. No enumeration of the number of lesions was performed. Signs of visceral involvement were not sought unless severity or length of illness was believed to be unusual for varicella. The Mann-Whitney U test was used to compare group demographics.

RESULTS

The median number of rejection episodes was 1 episode/patient, with a mean of 0.02 episodes/patient-month. Fourteen cases of primary infection with varicella-zoster virus were identified in our 28 patients. We observed no asymptomatic serologic conversions. Two patients in the group that was treated with intravenous acyclovir had received VZIG shortly before their presentation with varicella, which might have ameliorated their course. The rate of seroconversion is constant at 10% per year for the first 8 years, with a median of 3 years posttransplantation (Fig 1). The mean age at the time of varicella infection was 6 years (range: 1–10 years), and the mean time posttransplantation was 3 years (range: 9 months–7.5 years). The percentage of freedom from varicella was 100% at 1 year of age, 90% at 3 years of age, 75% at 5 years of age, and 20% at 11 years of age. Thus, most cases occurred after entry into the classroom situation. No differences in gender, ethnic group, or presence of siblings were found between the patients who developed varicella and the patients who did not. However, the median age at transplantation trended older (1.0 years; range: 13 days–8.4 years) in the patients who developed varicella compared with the patients who did not (2.2 months; range: 13 days–3.9 years; $P = .06$) and the median follow-up was longer (8.4 years; range: 2.9–10.8 years) in the patients who developed varicella compared with the patients who did not (5.0 years; range: 1.4–13.0 years; $P = .04$). Thus, our group of

children who have not had varicella are believed to represent young children who are likely to develop varicella over the next few years, rather than be intrinsically different from those who had already acquired the disease.

From the initial episode in 1990 until June 1996, our protocol was to admit all pediatric heart transplant patients with varicella for intravenous acyclovir until afebrile and new lesions were no longer appearing (usually 3 days), followed by oral acyclovir for 1 week as an outpatient. Subsequently, oral valacyclovir became available with reported improved bioavailability (70% vs 22% for oral acyclovir) and fewer interindividual variations in bioavailability (21% vs 50% for oral acyclovir).^{1,2} With this information regarding valacyclovir, our lack of significant complications during our early experience, and a desire to avoid unnecessary hospitalizations, we switched to an outpatient protocol using valacyclovir, 500 to 750 mg 3 times daily (mean: 77 mg/kg/d; range: 61–88 mg/kg/d), for 1 week if the patients were taking the oral medication well. This dose was based on approximating the adult dose of 1 g 3 times daily for 7 days (43–60 mg/kg/d) recommended for treatment of zoster in adults using the 500-mg capsules. Valacyclovir dosages of 2 g 4 times daily (100–150 mg/kg) in adults have been shown subsequently to produce plasma area under the curve of acyclovir that approximated that seen after intravenous administration of acyclovir, 10 mg/kg every 8 hours.¹ One child received oral acyclovir for 10 days as prescribed by her local physician instead of valacyclovir. The interval from onset of rash until initiation of treatment was not recorded for the patients who were receiving oral therapy. For the patients who were admitted to the hospital for intravenous acyclovir, symptoms were present for <48 hours before admission.

During this time period, no patient on maintenance immunosuppression (cyclosporine, 13; tacrolimus, 1; azathioprine, 13; mycophenolate mofetil, 1; steroids, 0) required admission to the hospital or developed significant complications. There was only 1 episode of rejection within the 2 months after varicella. This episode occurred 7 weeks after varicella and also was associated with parental admission of

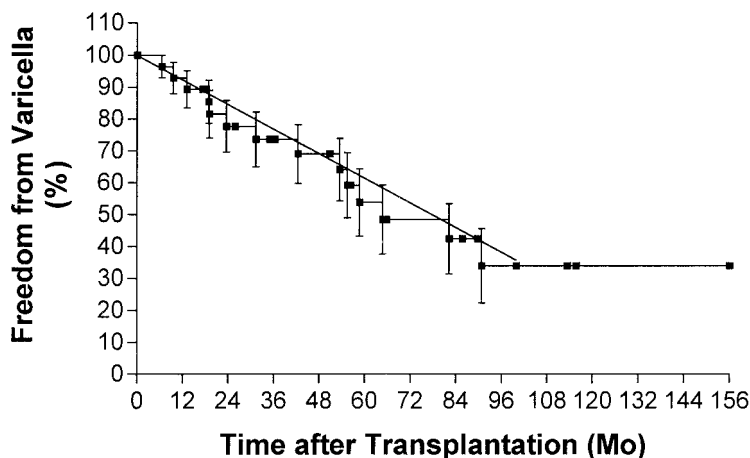


Fig 1. Freedom from varicella after heart transplantation. Mean values and standard error of the mean.

noncompliance with the immunosuppressive regimen, which was believed to be the major precipitating factor. All patients seroconverted and have positive titers in follow-up (mean: 6.6 years). One patient who underwent retransplantation for graft arteriosclerosis had a transient disappearance of antibody with the increased immunosuppression after the retransplantation but did not develop recurrent varicella. One patient with posttransplantation lymphoproliferative disease became seronegative while on chemotherapy and was electively admitted with varicella, characterized by fever to 103°F and generalized vesicular exanthem, 2 years after the primary infection. Clinically, she was believed to have recurrent varicella, although atypical generalized zoster was not excluded by molecular typing of the strains. She is the only recurrent episode of varicella in this patient population. There have been no episodes of localized zoster.

Total leukocyte counts and absolute lymphocyte counts during the 8-week period before the diagnosis of varicella are available for 13 of the 14 patients. The mean total leukocyte count was 7053/ μ L (range: 2800–13 000/ μ L), at an average of 22 days (range: 6–49 days) before varicella. The mean absolute lymphocyte count was 1784/ μ L (range: 749–2635/ μ L).

DISCUSSION

Varicella typically is a disease of childhood; >90% of cases occur in children between 1 and 14 years.³ Infants and young children who are undergoing heart transplantation are at high risk for primary infection with varicella-zoster virus because most are seronegative at transplantation. Typically, varicella is a self-limited illness with few complications in the nonimmunosuppressed young child beyond early infancy, compared with adolescents and adults, who have a high incidence of complications even when not immunosuppressed. However, studies have demonstrated that immunocompromised children are at risk for increased risk for complications, including pulmonary involvement, visceral involvement, and death. Early studies of varicella in immunocompromised patients tended to combine patients on chemotherapy for cancers with those on immunosuppression after transplantation. In addition, most older maintenance regimens for immunosuppression after organ transplantation included prednisone. Finally, only intravenous antiviral regimens have been reported for the treatment of these immunocompromised children. Therefore, we report our experience in a young varicella-zoster-naïve population that was not receiving prednisone as part of their immunosuppressive regimen after heart transplantation.

Feldman et al⁴ reported that in 60 children who developed varicella while on chemotherapy for malignancies, 32% had visceral involvement and 7% died. Prolonged fever and recurrent crops of cutaneous lesions were the first signs of visceral involvement. Pneumonia, hepatitis, and encephalitis were the most common complications. Feldhoff et al⁵ reported their experience with 19 cases of varicella in pediatric renal transplant patients who were receiv-

ing double therapy with azathioprine and prednisone. They had a high incidence of severe disease (42%) with 1 death. Patients in these studies did not receive antiviral therapy.

Prober et al⁶ demonstrated reduced incidence of pulmonary involvement during varicella in immunocompromised patients (19 malignancies and 1 transplant) who were randomized to receive intravenous acyclovir, 500 mg/m²/dose 3 times daily for 7 days. When limited to patients without evidence of pulmonary involvement at enrollment, the incidence of pneumonitis was 0 of 7 if treated with intravenous acyclovir and 5 of 11 if not treated. During the open-label portion of this protocol, 2 deaths occurred in 6 children whose intravenous acyclovir was not initiated until 5 days and 9 days, respectively, after the initial appearance of skin lesions. Feldman and Lott⁷ also demonstrated that antiviral therapy with either intravenous acyclovir or adenine arabinoside could reduce morbidity and mortality associated with varicella infection in children with cancer. In their study, lymphopenia (absolute lymphocyte count <500/ μ L) was associated with a higher risk of pneumonitis and death. By this criterion, all of our patients would fit into the lower risk group without significant lymphopenia. Subsequent studies of children after renal transplantation have continued to emphasize the high morbidity and mortality associated with varicella. Kashtan et al⁸ reviewed their experience with 69 cases of varicella in pediatric renal transplant patients who were receiving double or triple immunosuppressive therapy including prednisone. They used a protocol of intravenous acyclovir and reduction in azathioprine dose and still had 1 death and 3 episodes of acute allograft rejection. Ten of their patients were believed to have "severe" disease with prolonged fever and/or hepatitis/pneumonitis. Furth et al⁹ reviewed the data from the North American Pediatric Renal Transplant Cooperative Study for the years 1987 to 1993. In contrast to the earlier studies with high rates of morbidity and mortality, they found no mortality or increased risk of rejection or graft loss for 44 hospitalized patients with varicella in the first year after renal transplantation "in the cyclosporine era." The vast majority of their patients were receiving triple immunosuppression with prednisone, cyclosporine, and azathioprine. Our experience in pediatric heart transplant patients who are receiving single or double therapy not including prednisone is that the risk of serious disease is much lower than other immunosuppressed patient groups.

The majority of infants who undergo heart transplantation are treated with prednisone-free maintenance immunosuppression. The lower level of immunosuppression, especially with the elimination of prednisone from the regimen, might be associated with a low risk of complications with varicella. No previous study had evaluated the risks in a group of young patients who were receiving an immunosuppressive regimen after organ transplantation that did not include prednisone. In our study, we showed that most young children will develop varicella within the first 10 years after transplantation at a constant rate of approximately 10% per year (Fig 1).

This occurred most commonly after entering school, probably because of increased exposure. However, in this population that was receiving prednisone-free immunosuppression, there were no complications and prolonged courses of intravenous acyclovir or oral valacyclovir were not required. Thus, there seems to be a group of patients who can be treated safely in the outpatient setting with oral valacyclovir. Certainly, all high-risk patients should be followed for progression, regardless of the route of administration of antiviral therapy.

This study was not designed to compare the efficacy of valacyclovir and oral acyclovir. We chose valacyclovir because data suggest that its pharmacokinetics are similar to those of intravenous acyclovir. Several large studies that have compared the 2 oral drugs in various clinical settings also suggested that there may be a clinical benefit to the improved bioavailability of valacyclovir.¹⁰ Therefore, valacyclovir may have distinct advantages over acyclovir in the treatment of varicella in the immunocompromised patient, and oral acyclovir should not be relied on in this setting.

Broyer et al¹¹ compared outcome in pediatric renal transplant patients who had not received varicella vaccine before transplantation with those who had received vaccination. Only 62% of vaccinated patients had detectable antibodies at 1 year. Consequently, 12% of vaccinated children still developed varicella, but this is lower than the 45% rate in their unvaccinated children. Also, 3 deaths occurred in the naive patients and none in the vaccinated group. Vaccination before transplantation certainly seems to be beneficial if this option exists. However, varicella vaccine is approved only for patients who are older than 12 months. In addition, children who are evaluated and listed for heart transplantation often are clinically unstable and require intensive care in the brief interval before transplantation or death and are poor candidates for vaccination. Therefore, few of our pediatric heart transplant patients are eligible for vaccination before transplantation. Varicella vaccine is still contraindicated in patients with cellular immunodeficiencies and is not recommended after transplantation.¹² Zamora et al¹³ gave live attenuated varicella vaccine to 17 renal transplant recipients at a mean of 52 months posttransplantation. Although adverse reactions to the vaccine were minimal, the renal transplant patients had reduced seroconversion and 3 patients developed varicella 2 to 4 years after vaccination.

Zayas et al¹⁴ reported their experience with prophylaxis of known exposures demonstrating no cases of varicella in 61 of 61 patients who were received VZIG within 72 hours of the exposure and 9 of 9 cases of varicella in those who did not receive VZIG. We adopted the prophylaxis regimen as recommended by the American Academy of Pediatrics.¹⁵ However, 2 of our patients were exposed to varicella in siblings and developed varicella despite

having received VZIG. The remaining patients had not received VZIG. Undocumented exposures at school and play are common, and this protocol will not prevent varicella in this setting.

In general, the immune response as reflected in antibody titers after varicella seemed to be sustained in our patient population up to at least 6.6 ± 2.7 years, our length of follow-up. The only exception to this was 2 patients who had undergone intensified immunosuppression after their initial episode of varicella, including increased immunosuppression after retransplantation or chemotherapy for post-transplantation lymphoproliferative disease. Treatment of varicella with antiviral agents did not seem to interfere significantly with induction of a sustained B-cell response in our immunosuppressed population. This was demonstrated previously for normal children for both humoral and cellular immunity.^{16,17}

REFERENCES

1. Acosta EP, Fletcher CV. Valacyclovir. *Ann Pharmacother.* 1997;31:185–191
2. Steingrimsdottir H, Gruber A, Palm C, Grimfors G, Kalin M, Eksborg S. Bioavailability of aciclovir after oral administration of aciclovir and its prodrug valaciclovir to patients with leukemia after chemotherapy. *Antimicrob Agents Chemother.* 2000;44:207–209
3. Preblud SR, Orenstein WA, Bart KJ. Varicella: clinical manifestations, epidemiology and health impact on children. *Pediatr Infect Dis J.* 1984;3:505–509
4. Feldman S, Hughes WT, Daniel CB. Varicella in children with cancer: seventy-seven cases. *Pediatrics.* 1975;56:388–397
5. Feldhoff CM, Balfour HH, Simmons RL, Najarian JS, Mauer SM. Varicella in children with renal transplants. *J Pediatr.* 1981;98:25–31
6. Prober CG, Kirk LE, Keeney RE. Acyclovir therapy of chickenpox in immunosuppressed children: a collaborative study. *J Pediatr.* 1982;101:622–625
7. Feldman S, Lott L. Varicella in children with cancer: impact of antiviral therapy and prophylaxis. *Pediatrics.* 1987;80:465–472
8. Kashtan CE, Cook M, Chavers BM, Mauer SM, Nevins TE. Outcome of chickenpox in 66 pediatric renal transplant recipients. *J Pediatr.* 1997;131:874–877
9. Furth SL, Sullivan EK, Neu AM, Tejani M, Fivush BA. Varicella in the first year after renal transplantation: a report of the North American Pediatric Renal Transplant Cooperative Study (NAPRTCS). *Pediatr Transplant.* 1997;1:37–42
10. Bell AR. Valaciclovir update. *Adv Exp Med Biol.* 1999;458:149–157
11. Broyer M, Tete MJ, Guest G, Gagnadoux MF, Rouzioux C. Varicella and zoster in children after kidney transplantation: long-term results of vaccination. *Pediatrics.* 1997;99:35–39
12. Centers for Disease Control and Prevention. Prevention of varicella. Update recommendations of the Advisory Committee on Immunization Practices (ACIP). *MMWR Morb Mortal Wkly Rep.* 1999;48(RR-6):1–5
13. Zamora I, Simon JM, DaSilva ME, Piqueras AI. Attenuated varicella virus vaccine in children with renal transplants. *Pediatr Nephrol.* 1994;8:190–192
14. Zayas E, Gonzalez C, Otero LM, Delpin EAS. Varicella Zoster in a transplant program: experience with 15 cases and 70 contacts. *Transplant Proc.* 1996;28:3296–3297
15. American Academy of Pediatrics. *Red Book: Report of the Committee on Infectious Diseases.* Elk Grove Village, IL: American Academy of Pediatrics; 1997:576–579
16. Rotbart HA, Levin MJ, Hayward AR. Immune responses to varicella zoster virus infections in healthy children. *J Infect Dis.* 1993;167:195–199
17. Levin MJ, Rotbart HA, Hayward AR. Immune response to varicella-zoster virus 5 years after acyclovir therapy in childhood varicella. *J Infect Dis.* 1995;171:1383–1384

Varicella in a Pediatric Heart Transplant Population on Nonsteroid Maintenance Immunosuppression

Debra A. Dodd, Judy Burger, Kathryn M. Edwards and J. Stephen Dummer

Pediatrics 2001;108:e80

DOI: 10.1542/peds.108.5.e80

Updated Information & Services	including high resolution figures, can be found at: http://pediatrics.aappublications.org/content/108/5/e80
References	This article cites 15 articles, 4 of which you can access for free at: http://pediatrics.aappublications.org/content/108/5/e80#BIBL
Subspecialty Collections	This article, along with others on similar topics, appears in the following collection(s): Infectious Disease http://www.aappublications.org/cgi/collection/infectious_diseases_su_b
Permissions & Licensing	Information about reproducing this article in parts (figures, tables) or in its entirety can be found online at: http://www.aappublications.org/site/misc/Permissions.xhtml
Reprints	Information about ordering reprints can be found online: http://www.aappublications.org/site/misc/reprints.xhtml

American Academy of Pediatrics

DEDICATED TO THE HEALTH OF ALL CHILDREN™



PEDIATRICS®

OFFICIAL JOURNAL OF THE AMERICAN ACADEMY OF PEDIATRICS

Varicella in a Pediatric Heart Transplant Population on Nonsteroid Maintenance Immunosuppression

Debra A. Dodd, Judy Burger, Kathryn M. Edwards and J. Stephen Dummer

Pediatrics 2001;108:e80

DOI: 10.1542/peds.108.5.e80

The online version of this article, along with updated information and services, is located on the World Wide Web at:

<http://pediatrics.aappublications.org/content/108/5/e80>

Pediatrics is the official journal of the American Academy of Pediatrics. A monthly publication, it has been published continuously since 1948. Pediatrics is owned, published, and trademarked by the American Academy of Pediatrics, 141 Northwest Point Boulevard, Elk Grove Village, Illinois, 60007. Copyright © 2001 by the American Academy of Pediatrics. All rights reserved. Print ISSN: 1073-0397.

American Academy of Pediatrics

DEDICATED TO THE HEALTH OF ALL CHILDREN™

