

Imperforate Hymen: Congenital or Acquired From Sexual Abuse?

Ann S. Botash, MD, and Florence Jean-Louis*

ABSTRACT. Imperforate hymen diagnosed beyond the newborn period may present a dilemma for the physician. Three case studies are reviewed in which children with the diagnoses of imperforate hymen presented for evaluation of suspected sexual abuse. Clear descriptions of genital anatomy documented at well-child visits may be critical to later interpretations of findings encountered during examinations for suspected sexual abuse. *Pediatrics* 2001;108(3). URL: <http://www.pediatrics.org/cgi/content/full/108/3/e53>; sexual abuse, imperforate hymen, congenital anomaly.

ABBREVIATIONS. CARE, Child Abuse Referral and Evaluation; SUNY, State University of New York.

Imperforate hymen is a rare vaginal anomaly in which a layer of epithelialized connective tissue that forms the hymen has no opening and completely obstructs the vaginal introitus. Hydrocolpos and hydrometrocolpos can occur secondary to this condition. Congenital imperforate hymen is probably the most common obstructive anomaly of the female reproductive tract. Familial occurrences of imperforate hymen have been reported, although most cases are isolated events.¹ The diagnosis of congenital imperforate hymen should be made at birth, as pediatricians should determine if there is a patent hymen during the newborn period. However, many young women with imperforate hymen may reach menarche before the diagnosis is made.²

Although imperforate hymen has been described as a congenital anomaly usually presenting in infancy and early childhood, it can also be acquired from sexual abuse as documented by Berkowitz et al.³ Although this 1987 case study suggests an important link between imperforate hymen and sexual abuse, no subsequent case reports have been published. Recognizing imperforate hymen as an indicator of sexual abuse is complicated by the fact that the anomaly may be congenital and present before any sexual abuse.

In this article we report 3 cases of children with imperforate hymen evaluated in the Child Abuse

Referral and Evaluation (CARE) program of State University of New York (SUNY) Upstate Medical University, Syracuse, New York. The CARE program is located in central New York State and provides specialized medical evaluations for suspected child abuse victims.

CASE REPORTS

Case 1

A 9-year-old girl in foster care with a history of physical abuse was examined by her pediatrician at SUNY Upstate Medical University during April 1993 for poor weight gain. She was subsequently admitted for 17 days to University Hospital for failure to thrive and a perforated tympanic membrane. She was examined during this hospitalization by the CARE director (A.S.B.) and noted to have an imperforate hymen. Genital examination findings using colposcopy (Zeiss Opto-Systems, Inc, Newton, PA) and 35-mm camera showed an imperforate hymen with a microperforation at 7 o'clock and multiple adhesions (Fig 1). An ultrasound of the pelvis indicated the internal genitourinary structures were normal. This presentation was a change from her previous genital examination findings that were documented in emergency department medical records in December 1987 as normal. This previous evaluation occurred after her younger sibling's death from maltreatment and neglect. At that time, she had bruises on her arms and legs and poor general hygiene, and she disclosed that the bruises came from being hit by her father. The examination was performed by a third-year pediatric resident and a precise description of the hymen configuration is lacking. The follow-up visit during January of 1988 at the newly founded CARE program (before the purchase of a colposcope) also concluded that the external vaginal examination as normal. This subsequent examination was performed by a different third-year resident. Although protocol of the CARE program included performing thorough examination of the external genitalia, the hymen configuration was not clearly described and examination positions not documented. The patient had no other symptoms or history of symptoms such as vaginal bleeding or genital injury.

The patient did not disclose sexual abuse but other children in the foster home disclosed sexual acts perpetrated on them by the foster father. The foster home was closed and the patient was eventually adopted by another family. Authors were unable to contact the patient's adoptive parents to ascertain whether she has subsequently disclosed additional details regarding abuse.


Case 2

A 12-year-old mildly developmentally delayed girl diagnosed with attention-deficit/hyperactivity disorder was evaluated by the CARE program during January 1997. Several weeks before she had disclosed to her foster mother that her biological father on an unsupervised visit had molested her. Specifics of the abuse disclosure included fondling, kissing, and father urinating on her in the shower. There was no history of vaginal penetration or bleeding. Physical examination with videocolposcopy (Cabot, Cryomedics, Inc, Langhorne, PA) during the appointment in January, using both the supine and knee chest positions and small, moistened swabs to probe the hymenal opening and obtain cultures revealed an imperforate hymen. The finding is described as bands of tissue across the fossa with no hymenal opening (Fig 2, digital video). The urethra and anus were normal.

This child had a previous evaluation at the CARE program during January 1991 at the age of 6 years. She was brought by her

From the Department of Pediatrics, State University of New York, Upstate Medical University, Syracuse, New York.

*Medical student, class of 2002.

 Online version of this article contains video material for Figs 1-3. Online version available at www.pediatrics.org.

Received for publication Jan 18, 2001; accepted May 3, 2001.

Address correspondence to Ann S. Botash, MD, Department of Pediatrics, State University of New York, Upstate Medical University, 90 Presidential Plaza, Syracuse, NY 13202. E-mail: botasha@upstate.edu

PEDIATRICS (ISSN 0031 4005). Copyright © 2001 by the American Academy of Pediatrics.

Fig 1. Digital scan of a 35-mm slide photograph of the colposcopic findings on genital examination in the supine position of a 9-year-old girl with a functionally imperforate hymen. The arrow indicates a small microperforation noted in the hymenal tissue. There was no other opening to the vagina.

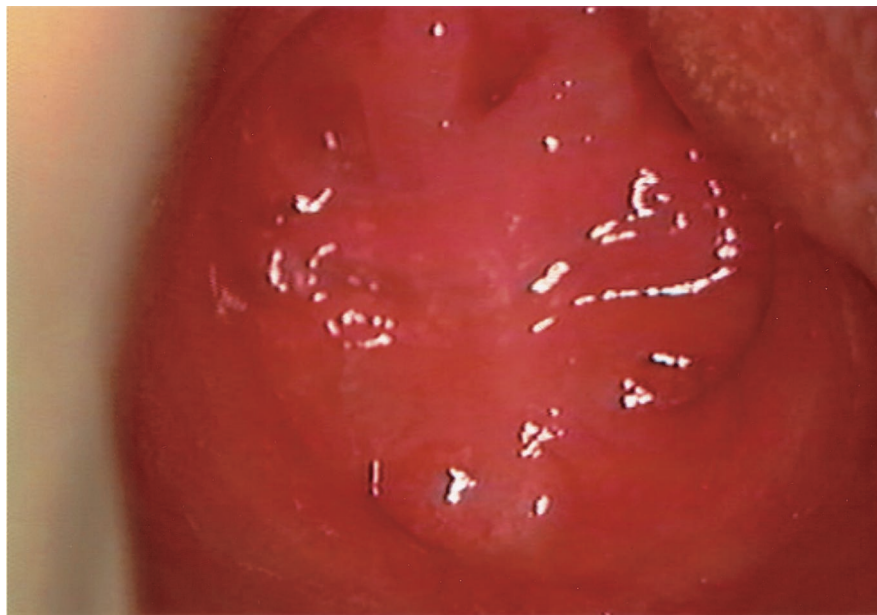
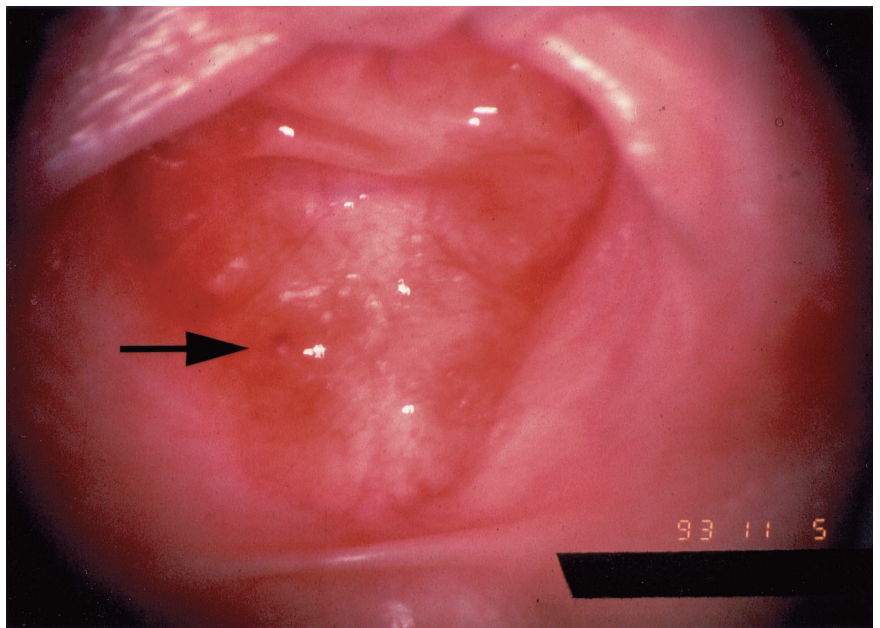


Fig 2. Digitized captured image from a VHS videotape of the genital examination of a 12-year-old girl in the supine position. The image reveals hymenal tissue covering the opening of the vagina. Areas of indentation can be seen, but careful probing with a small, moistened swab revealed no openings to the vagina. There are several areas of artifact resulting from reflected colposcope lighting. The digitized video demonstrates the imperforate hymen after labial traction in the supine position.

biological mother and Child Protective Services. The patient had told her biological mother that she was molested by her father. She verbalized very few details but child protective authorities suspected fondling and finger penetration. Her only clear statement to Child Protective Services was that her father had put "green pills up her." The record indicates that the patient's biological mother noticed behavioral changes and intermittent dysuria since the patient began unsupervised visits with her father. Physical examination during the January appointment using supine and knee chest positions revealed that the hymen was annular in configuration and the conclusion indicated a normal examination. No photographs were obtained, however, the examination was performed by an experienced examiner (A.S.B.) and the medical record includes a drawing clearly documenting the normal anatomy. These early allegations were dismissed as unfounded, attributable to the lack of clear evidence and inconsistent disclosure from the child. Four years later, the patient was placed in foster care after her mother attempted suicide in front of her. Subsequent to the patient's disclosure of abuse in 1997 and diagnosis of imperforate hymen at the age of 12, she required institutional care in a psychiatric facility where she now resides.

Case 3

The CARE program evaluated a 3-year-old girl in foster care in March 1995, after a sibling disclosed sexual abuse. Physical examination performed by an experienced examiner (A.S.B.) with the colposcope (Cabot, Cryomedics, Inc) in supine position with traction and use of a moist swab revealed an imperforate hymen. A photo was taken with the attached 35-mm camera (Fig 3). The anus was normal. There was no history of recent trauma, bleeding, fresh lacerations, contusions, or bruising. However, medical records from the newborn period documented the birth of a full-term female infant with an imperforate hymen. This documentation led examiners to conclude that this child's imperforate hymen was congenital and existed before any sexual abuse she may have sustained. A pelvic ultrasound was recommended to rule out abnormalities of the genitourinary structures but was not obtained before the family's relocation to another city.

DISCUSSION

Although imperforate hymen is the most common obstructive anomaly of the female genital tract, the

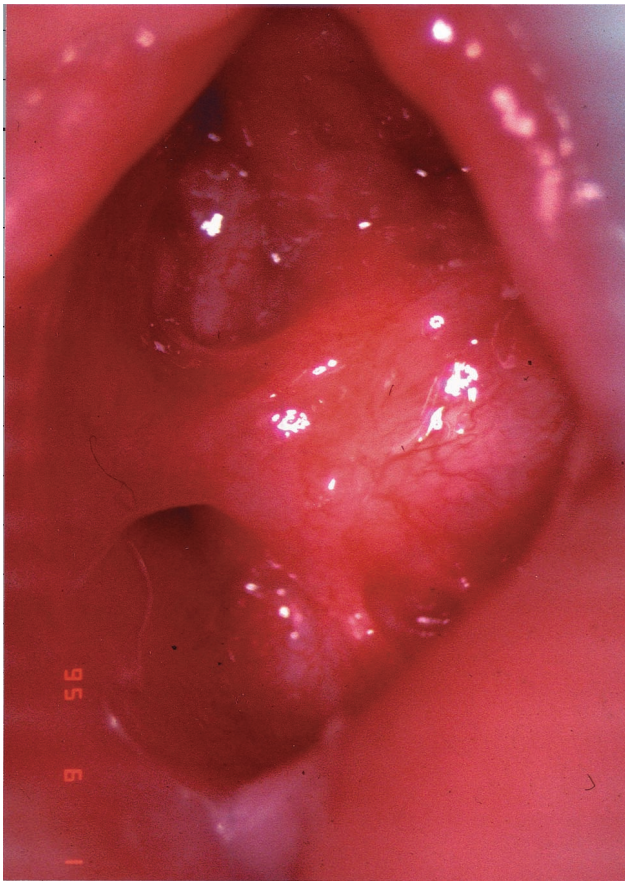


Fig 3. Digital scan of a 35-mm slide photograph of the colposcopic findings on genital examination of a 3-year-old girl. The photo illustrates a congenital imperforate hymen with thick tissue covering the vaginal introitus. There is a thick band of tissue extending from the edge of the imperforate area to the perihymenal area at the 9 o'clock position.

congenital frequency is low, estimated to be approximately 0.1% in female newborns.¹ Most children who are sexually abused do not have abnormal physical findings, and the history is critical for diagnosis.⁴ The growing literature describing the appearance of genitalia and perianal tissues in nonabused prepubertal children and of the hymen in newborns has helped medical providers understand which variations should be considered normal or nonspecific for abuse. Yet, descriptions of imperforate hymens are scarce in the child sexual abuse literature.

The CARE program has evaluated an additional 4 cases of children presenting with imperforate hymen and a suspicion of sexual abuse. However, inadequate or incomplete medical records of previous genital examination findings has made it impossible to determine the cause of these anomalies.⁵⁻⁷

In the cases described in this report, examiners concluded that 2 of these children developed an imperforate hymen secondary to genital trauma from sexual abuse and 1 child had a congenital imperforate hymen before possible sexual abuse. The emergency department records and the records from the CARE program support the conclusion that the patient in case 1 had a normal vaginal introitus before April 1993. Unfortunately, the documentation did not describe the hymen configuration (ie, crescent,

annular, etc) for both previous visits. However, given the suspicion of sexual abuse and the available documentation of these 2 separate previous normal genital examination findings, the imperforate hymen observed in case 1 was concluded to have been acquired and the result of trauma to the hymen. In case 2, because the examinations were performed by the same experienced examiner for both the earlier and later examinations using appropriate examination techniques of positioning, hymenal visualization, and record documentation, the finding of an imperforate hymen was concluded to be acquired. It is most likely that these 2 children experienced hymenal trauma attributable to sexual abuse and developed an imperforate hymen secondary to scarring.

In case 3, the finding of imperforate hymen might have been mistaken as secondary to sexual abuse trauma. However, previous records indicated that this was a congenital anomaly.

In all 3 cases, the conclusions would be much more convincing if prior photographic evidence of normal or abnormal findings existed. As a result of these cases, the CARE Program recommends that programs with a specialization in the medical evaluation of suspected sexual abuse consider photographic documentation (at least 1 or 2 photographs or video) of all normal as well as suspicious genital examination findings. Objective documentation of the appearance of tissues at one point in time is extremely useful in subsequent months or years if the child returns for reevaluation. When children are examined by their primary care providers for well-child care, a 1-sentence description or a simple drawing of the hymenal configuration and appearance would be particularly useful for possible future review by child abuse specialists who need to compare before and after findings.

This review and the earlier case report documented by Berkowitz et al³ are currently the only reports in medical literature known to these authors to describe an association of acquired imperforate hymen and genital trauma attributable to sexual abuse. Berkowitz et al³ report on a 5-year-old girl, a victim of sexual abuse, who experienced tears, scars, and distortions of the hymen. Follow-up examination at 7 months after the injury revealed a thick, opaque scar without an orifice in place of the hymen. The question of whether acquired imperforate hymen can result from accidental trauma is a possibility that must be considered; however, the authors have not yet identified such a case.

A possible distinguishing characteristic between a congenital and acquired imperforate hymen may lie in the possible anatomic and microanatomic differences between vaginal mucosa and scar tissue. Edwards⁸ describes wound healing documenting that injuries to deeper tissues heal through a process of repair. This involves the formation of granulation tissue and the development of scar tissue. As granulation tissue forms, the wound takes on a red appearance due to neovascularization. With additional maturation, the healing injury becomes paler as scar tissue is laid down. Significant anatomic differences

between genital scars and the anatomy of true congenital imperforate hymen may be advantageous in assessing possible sexual abuse. A body of clinical research that has systematically followed the healing chronology of acute genital and anal trauma is lacking.^{9,10}

Teixeira followed the healing process after acute molestation in 500 children and women.¹¹ The study reported a wide range of genital injuries, but there were no cases of apparent imperforate hymen as a result of the healing process. A comparison of Figs 1 and 2 with Fig 3 suggests that acquired imperforate hymen may be observed to be smoother, paler, and have less perihymenal bands. The microperforation in Fig 1 does not assist with differentiating congenital versus acquired obstructing tissue, because microperforations may be present congenitally. Such small microperforations are not clinically significant because the hymen is still functionally imperforate.

The finding of a small or anterior placed vaginal opening or sleeve-like hymen must be clinically distinguished from a labial adhesion and from a truly imperforate hymen.¹³ A thorough examination, using traction of the labia, moistened swabs, or floating the hymen with irrigation (squirting the opening with water) coupled with the use of supportive relaxation and appropriate positioning should enable the examiner to differentiate the hymenal configurations.¹⁴

These 3 case reports serve to illustrate the importance of descriptive documentation of genital examination findings regardless of whether the findings are normal or aberrant. The external examination of genitalia including the anus should occur as part of the natural progression of a comprehensive physical examination of every child at every well-child visit.¹² Medical records of all female children at all well-child examinations should describe the hymen configuration as well as changes in configuration with time. Physical findings do not usually provide clear evidence of sexual abuse and the history continues to be the most important factor when attempting to

conclude whether or not a child has been sexually abused. When a new physical finding such as an imperforate hymen or other finding consistent with sexual abuse is apparent, medical providers must properly document this and consider referral to a specialized child abuse center for a comprehensive evaluation. Thorough and detailed accounts of both the history and the physical examination observations in previous routine medical records often play a crucial role when evaluating cases of suspected abuse.

REFERENCES

1. Usta IM, Awwad JT, Usta JA, Makarem MM, Karam KS. Imperforate hymen: report of an unusual familial occurrence. *Obstet Gynecol.* 1993; 82:655-656
2. Laufer MR, Goldstein DP. Structural abnormalities of the female reproductive tract. In: Emans SJ, Laufer MR, Goldstein DP, eds. *Pediatric and Adolescent Gynecology.* 4th ed. Philadelphia, PA: Lippincott Williams & Wilkins; 1998
3. Berkowitz CD, Elvik SL, Logan M. A simulated acquired imperforate hymen following the genital trauma of sexual abuse. *Clin Pediatr.* 1987; 26:307-309
4. Adams JA, Harper K, Knudson S, Revilla J. Examination findings in legally confirmed child sexual abuse: it's normal to be normal. *Pediatrics.* 1994;93:310-317
5. Berenson AB, Heger A, Andrews S. Appearance of the hymen in newborns. *Pediatrics.* 1991;87:458-465
6. McCann J, Voris J. Perianal findings in pre-pubertal children selected for non-abuse: a descriptive study. *Child Abuse Negl.* 1989;13:179-193
7. Paradise JE, Finkel MA, Beiser AS, Berenson AB, Greenberg DB, Winter MR. Assessments of girls' genital findings and the likelihood of sexual abuse. *Arch Pediatr Adolesc Med.* 1997;151:883-891
8. Edwards LC, Dunphy JE. Wound healing in injury and normal repair. *N Engl J Med.* 1958;259:224-233
9. Finkel MA. Anogenital trauma in sexually abused children. *Pediatrics.* 1989;84:317-322
10. McCann J, Voris J. Perianal injuries resulting from sexual abuse: a longitudinal study. *Pediatrics.* 1993;91:390-397
11. Teixeira WRG. Hymenal colposcopic examination in sexual offenses. *Am J Forensic Med Pathol.* 1981;2:209-215
12. Botash AS. Examination for sexual abuse in prepubertal children: an update. *Pediatr Ann.* 1997;26:315-319
13. Berenson AB, Heger AH, Hayes JM, Bailey RK, Emans SJ. Appearance of the hymen in prepubertal girls. *Pediatrics.* 1992;89:387-394
14. Emans SJ, Laufer MR, Goldstein DP. *Office Evaluation of the Child and Adolescent, in Pediatric and Adolescent Gynecology.* 4th ed. Philadelphia, PA; Lippincott-Raven Publishers; 1998

Imperforate Hymen: Congenital or Acquired From Sexual Abuse?

Ann S. Botash and Florence Jean-Louis

Pediatrics 2001;108;e53

DOI: 10.1542/peds.108.3.e53

Updated Information & Services

including high resolution figures, can be found at:
<http://pediatrics.aappublications.org/content/108/3/e53>

References

This article cites 12 articles, 5 of which you can access for free at:
<http://pediatrics.aappublications.org/content/108/3/e53#BIBL>

Subspecialty Collections

This article, along with others on similar topics, appears in the following collection(s):
Washington Report
http://www.aappublications.org/cgi/collection/washington_report
Adolescent Health/Medicine
http://www.aappublications.org/cgi/collection/adolescent_health:medicine_sub

Permissions & Licensing

Information about reproducing this article in parts (figures, tables) or in its entirety can be found online at:
<http://www.aappublications.org/site/misc/Permissions.xhtml>

Reprints

Information about ordering reprints can be found online:
<http://www.aappublications.org/site/misc/reprints.xhtml>

American Academy of Pediatrics

DEDICATED TO THE HEALTH OF ALL CHILDREN®



PEDIATRICS®

OFFICIAL JOURNAL OF THE AMERICAN ACADEMY OF PEDIATRICS

Imperforate Hymen: Congenital or Acquired From Sexual Abuse?

Ann S. Botash and Florence Jean-Louis

Pediatrics 2001;108;e53

DOI: 10.1542/peds.108.3.e53

The online version of this article, along with updated information and services, is located on the World Wide Web at:

<http://pediatrics.aappublications.org/content/108/3/e53>

Data Supplement at:

<http://pediatrics.aappublications.org/content/suppl/2001/08/31/108.3.e53.DC1>

Pediatrics is the official journal of the American Academy of Pediatrics. A monthly publication, it has been published continuously since 1948. Pediatrics is owned, published, and trademarked by the American Academy of Pediatrics, 345 Park Avenue, Itasca, Illinois, 60143. Copyright © 2001 by the American Academy of Pediatrics. All rights reserved. Print ISSN: 1073-0397.

American Academy of Pediatrics

DEDICATED TO THE HEALTH OF ALL CHILDREN®

