

Spinal Epidural Abscess in a Young Child

Megan H. Bair-Merritt, MS*; Charles Chung, MD†; and Albert Collier, MD§

ABSTRACT. This is a case report of a spinal epidural abscess, caused by *Staphylococcus aureus*, in a 3-year-old girl. The child presented with fever and hip pain, but without any neurologic deficit. After normal plain films and a normal bone scan were obtained, the diagnosis was made via magnetic resonance imaging (MRI). The neurosurgery and pediatric infectious disease teams evaluated the patient, and the decision was made to forgo surgical drainage and to treat medically with appropriate intravenous and then oral antibiotics. Several months later, the child was doing well without any signs of neurologic sequelae. Because of the rarity of this disease in children, the treatment guidelines are controversial. Many suggest that a spinal epidural abscess must be drained surgically. Our experience adds to the literature a case of a child successfully treated with antibiotics alone. We believe that this success is related to the fact that the child was diagnosed by MRI early in the course of the disease and that she never displayed any neurologic deficits. *Pediatrics* 2000;106(3). URL: <http://www.pediatrics.org/cgi/content/full/106/3/e39>; spinal epidural abscess, magnetic resonance imaging, antibiotic treatment, child.

ABBREVIATIONS. UNC-CH, University of North Carolina-Chapel Hill; L5, fifth lumbar vertebra; S1, first sacral vertebra; IV, intravenous; MRI, magnetic resonance imaging; ESR, erythrocyte sedimentation rate.

Development of an epidural abscess is a rare event in the adult population; in the pediatric population, this diagnosis is seen even less frequently, with one review indicating <90 cases in the medical literature.¹ Because of the rarity of this clinical entity in children, treatment is controversial and lacks consistent precedent. We present the case of a 3-year-old girl who was transferred to University of North Carolina-Chapel Hill (UNC-CH) Children's Hospital for evaluation and treatment of a fifth lumbar vertebra (L5)/first sacral vertebra (S1) epidural abscess attributable to *Staphylococcus aureus*.

CASE REPORT

A 3-year-old girl was sent from an outside hospital for the evaluation and treatment of an epidural abscess. According to the patient's history and medical records, she had been previously

healthy and was not known to be immunocompromised. Three days before admission at the outside hospital, the patient developed a low grade fever and malaise, and 1 day before admission the patient developed right hip pain. Because of the pain, the child refused to bear weight. On the day before admission, the child's mother took her to the emergency department, where her temperature was found to be 38.4°C. Physical examination was unremarkable. Two blood cultures were drawn. The child was given 1 dose of ceftriaxone and then was sent home with ibuprofen.

On the following day, the child returned to the hospital with a temperature of 39.4°C and worsening right hip pain. On examination, she was febrile and ill-appearing. The right hip was tender to palpation. The range of motion of the hips was normal bilaterally. She walked with an antalgic gait, favoring the left, but no neurologic deficits were apparent. Both blood cultures from the previous day returned as positive for oxacillin-sensitive *S aureus*. Two repeat blood cultures drawn on that day also returned as positive for oxacillin-sensitive *S aureus*. The patient was admitted and placed on intravenous (IV) nafcillin and ceftriaxone.

Plain films of the femur and lumbosacral spine were obtained and were normal; aspiration of the hip under ultrasound guidance was attempted unsuccessfully because of lack of localizable fluid in the joint. A 3-phase nuclear medicine bone scan was performed and considered normal. Because of the desire to locate a source of the bacteremia, magnetic resonance imaging (MRI) of the pelvis was ordered. This MRI revealed an L5/S1 multiloculated epidural abscess (Fig 1A). Significant laboratory studies included an elevated erythrocyte sedimentation rate (ESR) of 93; the initial white blood cell count was 12.5 (69% neutrophils, 17% lymphocytes, 14% monocytes, and no eosinophils or basophils).

On the third hospital day, the patient was transferred to UNC-CH for evaluation by the neurosurgery and pediatric infectious disease teams. Her neurologic examination remained normal. Blood cultures were drawn, which were also positive for oxacillin-sensitive *S aureus*, despite 2 days of IV nafcillin and ceftriaxone. The patient's antibiotics were changed to IV gentamicin and oxacillin. Neurosurgery recommended conservative treatment without surgical drainage because of concern about iatrogenic complications and because of the patient's normal neurologic status. A Broviac catheter was placed in anticipation of long-term antibiotic treatment.

The patient was observed at our hospital for a total of 7 days. Throughout the hospital course, she continued to have a nonfocal neurologic examination, including normal range of motion of the hips. Two repeat blood cultures were negative on day 4 and day 5 of her stay at UNC-CH and her ESR dropped to 76. A repeat MRI performed 9 days after the initial MRI (therefore, after 2 days of IV nafcillin and ceftriaxone and after 7 days of IV oxacillin and gentamicin) demonstrated dramatic improvement with normal circumference of the thecal sac and with no abnormal enhancement noted (Fig 1B). The gentamicin was discontinued after 7 days of administration.

The patient was then transported back to the outside hospital with instructions to continue IV oxacillin (every 4 hours to maximize blood concentrations) for a total of 6 weeks. After IV therapy was complete, the patient and her physicians were instructed to change to oral dicloxacillin for 2 weeks. The local physicians were also asked to continue to follow the patient's neurologic examination and ESR, and to obtain a follow-up MRI if symptoms returned or progressed.

Approximately 2½ months after being discharged from our institution (and ~1 month after cessation of all antibiotics), a follow-up call was made to the patient's primary care physician. The physician reported that the patient continued to do well without evidence of neurologic sequelae. Overall, since discharge,

From the *University of North Carolina School of Medicine; and the Departments of †Pediatric Radiology and §Pediatric Infectious Disease, University of North Carolina Children's Hospital, Chapel Hill, North Carolina. Received for publication Nov 15, 1999; accepted Mar 13, 2000.

Reprint requests to (A.C.) Pediatric Infectious Disease, Rm 535, Burnett-Womack, CB 7220, University of North Carolina-Chapel Hill, Chapel Hill, NC 27599-7220. E-mail: uncacl@med.unc.edu
PEDIATRICS (ISSN 0031 4005). Copyright © 2000 by the American Academy of Pediatrics.

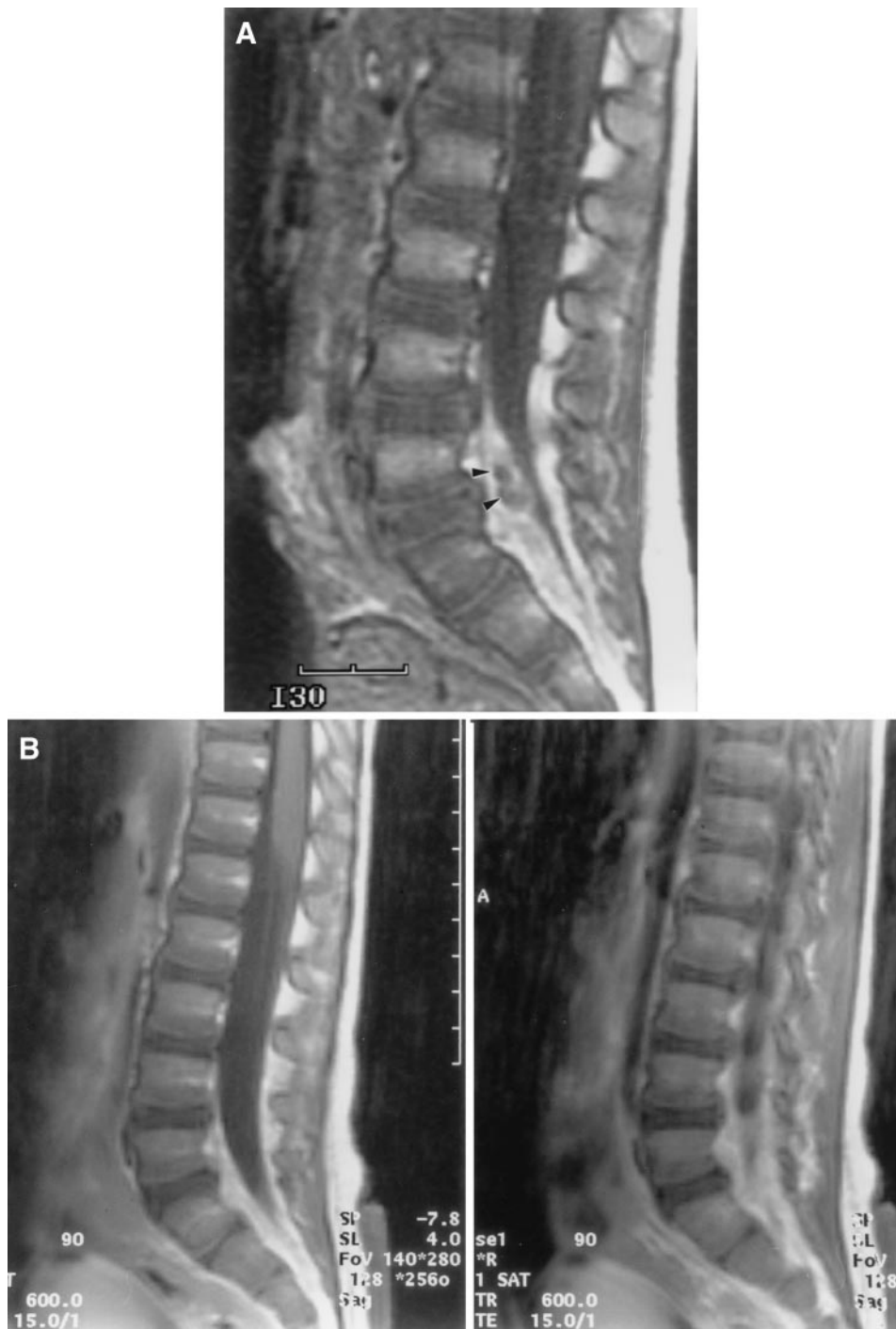


Fig 1. A, Sagittal T1-weighted MRI demonstrates a lesion anterior to the thecal sac behind the L5/S1 disk (black arrow heads) consistent with an epidural abscess. The lesion is isointense with cerebrospinal fluid and displaces the thecal sac posteriorly. B, The epidural abscess is no longer visible on 2 sagittal T1-weighted MRI images obtained 9 days after the initial examination.

she had been afebrile without signs of sepsis, and clinically seemed to be an active and healthy child.

DISCUSSION

With an incidence of $<.2$ to 1.2 per 10 000 hospital admissions, spinal epidural abscess in children is a rare clinical entity that is often not diagnosed until the development of significant neurologic sequelae.² In children, the most common cause is thought to be via hematogenous spread from a previous infection. Other speculated sources include direct extension

from a vertebral osteomyelitis or spread from bacterial seeding of a hematoma after blunt trauma.¹ One literature review of cases of pediatric epidural abscess between 1945 and 1991 found that 86% were caused by *S aureus* infection.¹ Other reports of epidural abscess in children concur that *S aureus* is the most common pathogen. Other bacteria that have been implicated include *Pseudomonas*, *Pneumococcus*, *Escherichia coli*, *Fusobacterium*, and *Salmonella*.¹

Common early presentations of this disease in-

clude fever, malaise, and spinal tenderness. Additionally, as was the case with our patient, children may present with hip tenderness rather than back pain. The hip tenderness is presumed to be caused by radicular pain.¹ However, the aforementioned early symptoms are generally nonspecific and are not uniformly present. Therefore, many children are not diagnosed until they present with neurologic deficits including limb weakness, paraplegia, or paraparesis. As described in our patient, plain films, ultrasound, and bone scan are generally normal. Although some older reports describe the use of computed tomography or computed tomography-myelogram for diagnosis, other studies describe cases in which the diagnosis has been missed with this modality.¹ Overall, MRI is considered to be the gold standard in diagnosis.

Treatment of spinal epidural abscess remains controversial. Several articles in the adult literature describe the successful use of antibiotic therapy alone for eradication of the abscess. Leys et al³ reported 4 adults who were treated with medical therapy only. Of these 4, 1 developed minor neurologic sequelae and the remaining 3 had no further difficulties. Mampalam et al⁴ reported on 6 adults who presented with epidural abscess, but without neurologic deficit, who were treated with medical therapy with similar success. The authors of this article stress that patients who present early in the course of the disease, without neurologic changes, may be managed nonsurgically.

However, in the pediatric literature, reports of successful treatment of epidural abscess with antibiotics alone are considerably more difficult to find. Overall, the consensus seems to be that both surgical drainage (usually by laminectomy) and antibiotic therapy are necessary for treatment. Enberg and Kaplan⁵ described 10 children with epidural abscess who did not undergo surgery; all of these children died. These authors, along with others,^{1,2,6} all strongly advise surgical treatment in addition to antibiotic therapy.

But, the common surgical procedures used to drain and debride epidural abscesses also have potential for significant morbidity. The goal of these procedures is both to decompress the lesion through the removal of the purulent material and to apply antibiotics locally.⁷ To approximate the abscess, layers of ligaments and bone must be removed or displaced. Anterior lesions, like the abscess of our patient, are considerably more difficult to approach and remove. One older report in the literature suggests that on rare occasion, depending on the location and the extent of the lesion, the surgeon may preserve the ligaments and bone by elevating the lamina⁷; therefore, she may reposition the lamina when the procedure is complete. But generally, if an abscess spans several vertebral levels or if the lesion is predominantly granulation tissue, the established procedure for adequate drainage is a multilevel laminectomy.⁷ The morbidity of multilevel laminectomy in children is significant, often leading to kyphosis and spinal instability.

Percutaneous drainage has been considered as an

alternative possibility. In a case report by Walter et al,⁸ the authors describe a neurologically intact infant with an epidural abscess who, after diagnosis with MRI, was successfully treated by percutaneous drainage. But this is an isolated case report of success in one neurologically intact infant. One author indicates that the use of percutaneous drainage will potentially increase in the future as endoscopic technology develops.⁹

Our patient was treated with 6 weeks of appropriate IV antibiotic therapy and then 2 weeks of oral antibiotics. Surgical drainage was not attempted. Surgery most likely would have only minimally shortened the duration of antibiotic treatment as the consensus in the literature indicates the need for antibiotic coverage for 3 to 6 weeks postoperatively.^{1,8,9}

Our patient remains asymptomatic. We believe that our success with medical therapy alone may be related to the early diagnosis made with MRI. In most of the aforementioned reports, children were diagnosed after the onset of neurologic deficit. In contrast, our patient was diagnosed within ~3 days after the initial onset of symptoms. At presentation, and throughout the course of therapy, she never developed neurologic sequelae.

Therefore, based on our experience, we encourage consideration of MRI imaging in young patients who present with fever and back or hip tenderness of unknown cause. Additionally, although we recognize that our findings are isolated to this particular case, we add to the literature collection an example of a neurologically intact child with an epidural abscess who was successfully treated with antibiotics alone. This case raises the question of whether all children with an epidural abscess require surgical drainage. We propose that children without neurologic deficits may be able to be successfully managed with antibiotics. Further research and study are necessary to confirm the efficacy of using medical therapy alone in pediatric patients with uncomplicated epidural abscesses.

REFERENCES

1. Jacobsen FS, Sullivan B. Spinal epidural abscess in children. *Orthopedics*. 1994;17:1131-1138
2. Rubin G, Shalom M, Ashenasi A, Tadmor R, Rappaport Z. Spinal epidural abscess in the pediatric age group: case report and review of the literature. *Pediatr Infect Dis J*. 1993;12:1007-1011
3. Leys D, Lesoin F, Viaud C, Pasquier F, et al. Decreased morbidity from acute bacterial spinal epidural abscess using computed tomography and nonsurgical treatment in selected patients. *Ann Neurol*. 1985;17:350-355
4. Mampalam TJ, Rosegay, H, Andrews BT, Rosenblum ML, Pitts LH. Nonoperative treatment of spinal epidural infections. *J Neurosurg*. 1989;71:208-210
5. Enberg RN, Kaplan RJ. Spinal epidural abscess in children. *Neurology*. 1974;13:247-253
6. Rockney R, Ryan R, Knucky N. Spinal epidural abscess: an infectious emergency. *Clin Pediatr*. 1989;28:332-334
7. Hulme A, Dott NM. Spinal epidural abscess. *Br Med J*. 1954;1:64-68
8. Walter RS, King JC, Manley J, Rigamonti D. Spinal epidural abscess in infancy: successful percutaneous drainage in a nine-month-old and review of the literature. *Pediatr Infect Dis J*. 1994;19:860-864
9. Martin RJ, Yuan HA. Neurosurgical care of spinal epidural, subdural, and intramedullary abscesses and arachnoiditis. *Orthop Clin North Am*. 1996;27:125-136

Spinal Epidural Abscess in a Young Child
Megan H. Bair-Merritt, Charles Chung and Albert Collier
Pediatrics 2000;106:e39
DOI: 10.1542/peds.106.3.e39

Updated Information & Services

including high resolution figures, can be found at:
<http://pediatrics.aappublications.org/content/106/3/e39>

References

This article cites 9 articles, 0 of which you can access for free at:
<http://pediatrics.aappublications.org/content/106/3/e39#BIBL>

Subspecialty Collections

This article, along with others on similar topics, appears in the following collection(s):
Infectious Disease
http://www.aappublications.org/cgi/collection/infectious_diseases_sub
Pharmacology
http://www.aappublications.org/cgi/collection/pharmacology_sub
Therapeutics
http://www.aappublications.org/cgi/collection/therapeutics_sub

Permissions & Licensing

Information about reproducing this article in parts (figures, tables) or in its entirety can be found online at:
<http://www.aappublications.org/site/misc/Permissions.xhtml>

Reprints

Information about ordering reprints can be found online:
<http://www.aappublications.org/site/misc/reprints.xhtml>

American Academy of Pediatrics

DEDICATED TO THE HEALTH OF ALL CHILDREN®



PEDIATRICS[®]

OFFICIAL JOURNAL OF THE AMERICAN ACADEMY OF PEDIATRICS

Spinal Epidural Abscess in a Young Child

Megan H. Bair-Merritt, Charles Chung and Albert Collier

Pediatrics 2000;106:e39

DOI: 10.1542/peds.106.3.e39

The online version of this article, along with updated information and services, is located on the World Wide Web at:

<http://pediatrics.aappublications.org/content/106/3/e39>

Pediatrics is the official journal of the American Academy of Pediatrics. A monthly publication, it has been published continuously since 1948. Pediatrics is owned, published, and trademarked by the American Academy of Pediatrics, 345 Park Avenue, Itasca, Illinois, 60143. Copyright © 2000 by the American Academy of Pediatrics. All rights reserved. Print ISSN: 1073-0397.

American Academy of Pediatrics

DEDICATED TO THE HEALTH OF ALL CHILDREN[®]

