

Chickenpox Attributable to a Vaccine Virus Contracted From a Vaccinee With Zoster

Philip Alfred Brunell, MS, MD, and Takele Argaw, DVM

ABSTRACT. Five months after 2 siblings were immunized with varicella vaccine, 1 developed zoster. Two weeks later the second sibling got a mild case of chicken pox. Virus isolated from the latter was found to be vaccine type. Thus, the vaccine strain was transmitted from the vaccinee with zoster to his sibling. Vaccinees who later develop zoster must be considered contagious. *Pediatrics* 2000;106(2). URL: <http://www.pediatrics.org/cgi/content/full/106/2/e28>; varicella-zoster, zoster, vaccine, transmission, rash, PstI.

ABBREVIATION. VZV, varicella-zoster virus.

Varicella is the initial manifestation of varicella-zoster virus (VZV) infection. After clinical recovery, as with other herpes viruses, VZV persists in a latent form. The virus may become activated resulting in zoster. This occurs most commonly in older individuals, but also is seen in immunocompromised younger people, eg, those infected with human immunodeficiency disease virus or transplant recipients. It also is known to occur in normal varicella vaccine recipients.¹

Exposure of susceptible individuals to zoster has been recognized for more than a century to result in varicella.² We now report the occurrence of varicella in a child whose brother developed zoster after immunization with varicella vaccine. It has been advised that vaccinees that develop a rash soon after immunization avoid contact with persons at high risk for complications of varicella.³ Similar precautions would be appropriate for contact with vaccinees that develop zoster. Heretofore, transmission of vaccine virus was recognized to occur primarily from vaccinees with leukemia that developed rashes after immunization.^{4,5} Although far less common, vaccine virus also has spread from normal vaccinees with,^{6,7} and possibly without, a rash.⁸

From Ahmanson Pediatrics Department, Cedars Sinai Medical Center, Los Angeles, California; and the Laboratory of Clinical Investigation, National Institute of Allergy and Infectious Diseases, National Institutes of Health, Bethesda, Maryland.

Received for publication Sep 24, 1999; accepted Mar 17, 2000.

Reprint requests to (P.A.B.) National Institutes of Health, National Institute of Allergy and Infectious Diseases, Bldg 10, Room 11N228, 9000 Rockville Pike, Bethesda, MD 20892. E-mail: pbrunell@niaid.nih.gov
PEDIATRICS (ISSN 0031 4005). Copyright © 2000 by the American Academy of Pediatrics.

METHODS

Clinical Observations

Five months after receipt of varicella vaccine a 3-year-old boy who was otherwise normal was noted to have thoracic zoster. Fourteen days later, his healthy normal brother, who had been immunized at the same time as he was, developed a mild case of varicella. On the second day of his illness, he was observed to have ~50 vesicular lesions in a generalized distribution on the trunk and scalp. He was playful and did not seem to be very ill. Their mother had not had varicella during her pregnancy and the brothers had no known exposure to varicella except for contact 3 days before their immunization with a child who had the onset of rash 3 days later.

Virologic Studies

Human embryonic diploid fibroblast cultures were inoculated with vesicular fluid collected from the child with varicella. Focal cytopathic changes characteristic of VZV were observed 4 days later. DNA was extracted from the isolate and the region flanking the *PstI* site was amplified by polymerase chain reaction, using appropriate primers.⁹ The products were separated on an agarose gel.

DISCUSSION

The occurrence of zoster in normal varicella vaccine recipients is well-recognized.¹ Thus, there did not seem to be any reason to investigate the sibling who developed zoster. The risk of normal children developing zoster after immunization has been reported to be no greater than if they had had varicella rather than being immunized.¹⁰ Children with leukemia who have received the vaccine seem to be less likely to develop zoster than leukemic children who have had chicken pox.^{11,12}

It was important to establish whether a vaccine or wild strain of VZV had caused varicella, although there was no known exposure likely to have caused infection. If it were a wild strain, one might have attributed the child's chickenpox to infection from an unrecognized exposure. Wild strain has been isolated from a vaccinee who developed zoster, which apparently resulted from reinfection with wild type VZV.¹³ In this case, it was the wild strain rather than the vaccine strain that became activated and produced zoster.

In 1987, we observed that digestion of VZV DNA with a restriction enzyme *PstI* could distinguish wild types from vaccine types of virus.⁵ Restriction enzymes, eg, *PstI*, have very specific target substrates, and changes in the base sequences where the enzyme acts will affect its ability to digest the viral DNA strand. A change in the base sequence in vaccine strains at the site where *PstI* cuts wild strains makes it impossible for *PstI* to cut vaccine strains. Thus, the

wild type will have 2 fragments after *Pst*I treatment, while the vaccine strain will remain uncut in this region and have a single fragment. When the products of *Pst*I treatment are separated on a gel, a single fragment will be found in vaccine strains that is approximately twice the size of the corresponding 2 fragments obtained from wild strains (Fig 1).

The illness in the child who developed varicella after exposure to his brother with zoster was very mild, as are most breakthrough cases of chicken pox resulting from wild virus.¹⁴ It has been assumed that these vaccinees may have some residual protection from their previous immunization.

However, children who have been immunized previously generally do not develop a rash after exposure to a vaccine-induced rash. This would suggest that the child who developed chickenpox may not have had a take from his immunization, and thus, may have been susceptible to VZV at the time of exposure to zoster. Infection of susceptible normal individuals with vaccine virus is expected to result in mild illness.^{4,5} Alternatively, vaccinees who develop zoster may be more likely to transmit VZV to contacts than vaccinees who develop a varicella-like rash shortly after immunization.

The risk of a vaccinee who develops zoster infect-

ing contacts is not known. The likelihood of transmission of vaccine virus to contacts of vaccinees has been reported to be related to the number of skin lesions that develop after immunization.⁴ In a study of transmission of vaccine virus from children with leukemia to susceptible household members, only vaccinees who developed a rash infected contacts. None of the 56 subjects exposed to vaccinees without rash seroconverted, whereas 2 of 7 subjects exposed to vaccinees with rash seroconverted.⁵ Whether vaccinees develop zoster or a rash after immunization, they pose a potential hazard to individuals at high risk to develop complications of chickenpox. Thus, the same caveat of avoiding exposure to vaccinees with a postvaccination rash³ also pertains to vaccinees who subsequently develop zoster. In the case reported, the child with zoster infected his normal sibling.

ACKNOWLEDGMENTS

We thank Drs Stephen E. Straus, Jeffrey Cohen, and Phillip Krause for their helpful suggestions.

REFERENCES

- Centers for Disease Control and Prevention. Prevention of varicella updated. *MMWR CDC Surveill Summ.* 1999;48:1-5
- Bokay J. Das Austreten ser Schafblättern unter besonderen Umständen. *Ungar Arch f Med Wiesb.* 1892;1:159-161
- Centers for Disease Control and Prevention. Prevention of varicella. *MMWR CDC Surveill Summ.* 1996;45:1-36
- Tsolia M, Gershon AA, Steinberg SP, Gelb L. Live attenuated varicella vaccine: evidence that the virus is attenuated and the importance of skin lesions in transmission of varicella-zoster virus. *J Pediatr.* 1990;116:184-189
- Brunell PA, Geiser CF, Novelli V, Lipton S, Narkewicz S. Varicella-like illness caused by live varicella vaccine in children with acute lymphocytic leukemia. *Pediatrics.* 1987;79:992-927
- LaRussa P, Steinberg S, Meurice F, Gershon A. Transmission of vaccine strain varicella-zoster virus from a healthy adult with vaccine associated rash to susceptible household contacts. *Infect Dis.* 1997;176:1072-1075
- Saltzman M, Sharrar R, Steinberg S, La Russa P. Transmission of varicella-vaccine virus from a healthy 12 month old child to his pregnant mother. *J Pediatr.* 1997;131:151-154
- Weibel RE, Kuter BJ, Neff BJ, et al. Live Oka/Merck varicella vaccine in healthy children. *JAMA.* 1985;254:2435-2439
- LaRussa P, Lungu O, Hardy I, Gershon A, Steinberg S, Silverstein S. Restriction fragment length polymorphism of polymerase chain reaction products from vaccine and wild type varicella-zoster virus isolates. *J Virol.* 1992;66:1016-1020
- Plotkin SA, Starr SE, Connor K, Morton D. Zoster in normal children after varicella vaccine. *J Infect Dis.* 1989;159:1000
- Brunell PA, Taylor-Wiedeman J, Geiser C, Frierson L, Lydick E. Risk of herpes zoster in children with leukemia: varicella vaccine compared with history of chickenpox. *Pediatrics.* 1986;77:53-56
- Hardy I, Gershon AA, Steinberg SP, LaRussa P. The incidence of zoster after immunization with live attenuated varicella vaccine: study in children with leukemia. Varicella Vaccine Collaborative Study Group. *N Engl J Med.* 1991;325:1545-1550
- Gelb L, Dohner DE, Gershon AA, et al. Molecular epidemiology of live attenuated varicella virus vaccine in children with leukemia and in normal adults. *J Infect Dis.* 1987;155:633-640
- Watson B, Piercy S, Plotkin S, Starr S. Modified chicken pox in children immunized with the Oka/Merck varicella vaccine. *Pediatrics.* 1993;91:17-22

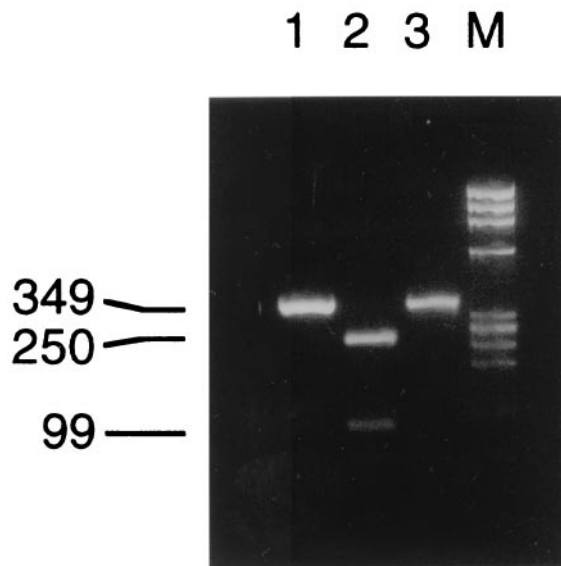


Fig 1. Polymerase chain reaction analysis of the patient's isolate, compared with wild strains and vaccine strains of VZV. The polymerase chain reaction products are separated by gel electrophoresis. Lane 1 is the Oka vaccine strain; lane 2, a US wild strain (Emily); lane 3, the isolate from the sibling who developed varicella. The Oka strain and the isolate both have changes in the bases in the region where *Pst*I digests the wild type virus. Thus, *Pst*I is unable to digest the vaccine or isolate, so there is only a single 349-kb band. The wild strain, which contains the *Pst*I site, is split into 2 fragments, both of which are smaller (99 kb and 250 kb) than the single nonsplit fragment from the Oka or isolate strains.

Chickenpox Attributable to a Vaccine Virus Contracted From a Vaccinee With Zoster

Philip Alfred Brunell and Takele Argaw

Pediatrics 2000;106:e28

DOI: 10.1542/peds.106.2.e28

Updated Information & Services

including high resolution figures, can be found at:
<http://pediatrics.aappublications.org/content/106/2/e28>

References

This article cites 14 articles, 3 of which you can access for free at:
<http://pediatrics.aappublications.org/content/106/2/e28#BIBL>

Subspecialty Collections

This article, along with others on similar topics, appears in the following collection(s):
Infectious Disease
http://www.aappublications.org/cgi/collection/infectious_diseases_sub
Vaccine/Immunization
http://www.aappublications.org/cgi/collection/vaccine:immunization_sub

Permissions & Licensing

Information about reproducing this article in parts (figures, tables) or in its entirety can be found online at:
<http://www.aappublications.org/site/misc/Permissions.xhtml>

Reprints

Information about ordering reprints can be found online:
<http://www.aappublications.org/site/misc/reprints.xhtml>

American Academy of Pediatrics

DEDICATED TO THE HEALTH OF ALL CHILDREN™



PEDIATRICS®

OFFICIAL JOURNAL OF THE AMERICAN ACADEMY OF PEDIATRICS

Chickenpox Attributable to a Vaccine Virus Contracted From a Vaccinee With Zoster

Philip Alfred Brunell and Takele Argaw

Pediatrics 2000;106:e28

DOI: 10.1542/peds.106.2.e28

The online version of this article, along with updated information and services, is located on the World Wide Web at:

<http://pediatrics.aappublications.org/content/106/2/e28>

Pediatrics is the official journal of the American Academy of Pediatrics. A monthly publication, it has been published continuously since 1948. Pediatrics is owned, published, and trademarked by the American Academy of Pediatrics, 141 Northwest Point Boulevard, Elk Grove Village, Illinois, 60007. Copyright © 2000 by the American Academy of Pediatrics. All rights reserved. Print ISSN: 1073-0397.

American Academy of Pediatrics

DEDICATED TO THE HEALTH OF ALL CHILDREN™

