

# Initial Intravenous Gammaglobulin Treatment Failure in Kawasaki Disease

Carol A. Wallace, MD; James W. French, MD; Stuart J. Kahn, MD; and David D. Sherry, MD

**ABSTRACT.** *Objectives.* To determine initial intravenous gammaglobulin (IVIG) treatment failures in Kawasaki disease (KD) and to report the outcome of retreatment and our use of pulse intravenous (IV) methylprednisolone and cyclophosphamide in patients with persistent KD.

*Study Design.* Retrospective analysis of the treatment and response of children with KD over 3 years.

*Results.* Fifty (77%) of 65 patients completely responded to a single treatment with IVIG (2 g/kg). Fifteen patients (23%) required retreatment; 10 patients fully responded but 5 had persistent disease (3 developed coronary aneurysms and 4 developed coronary artery thrombosis). Four of these 5 patients with persistent disease were treated with pulse IV methylprednisolone and 2 were also treated with IV cyclophosphamide. There was no progression of coronary aneurysms and no deaths. No initial patient characteristics predicted IVIG treatment failure or the development of coronary aneurysms.

*Conclusion.* Nearly 23% of patients with KD may require retreatment and 8% may develop coronary aneurysm. Additional antiinflammatory therapy, such as IV methylprednisolone and IV cyclophosphamide, may be helpful in treating persistent KD. *Pediatrics* 2000;105(6). URL: <http://www.pediatrics.org/cgi/content/full/105/6/e78>; corticosteroids, vasculitis, Kawasaki disease, heart disease, gammaglobulin therapy, cyclophosphamide.

ABBREVIATIONS. KD, Kawasaki disease; IVIG, intravenous gammaglobulin; CRP, C-reactive protein; ESR, erythrocyte sedimentation rate; IV, intravenous.

Kawasaki disease (KD) is a potentially life-threatening acute vasculitis in young children with a predilection for involvement of the muscular arteries, particularly the coronary arteries. The use of intravenous gammaglobulin (IVIG) with aspirin is standard treatment and successful in most patients.<sup>1</sup> The rapidity of response to treatment with IVIG is gratifying, and it has significantly decreased the incidence of subsequent coronary aneurysms.<sup>1</sup> However, there are few options, except retreatment with IVIG, for those who do not fully respond or who have recurrent KD. Recently, corticosteroids

have been efficacious in a small number of children who do not respond to initial IVIG treatment.<sup>2-5</sup>

We were impressed with several severe cases of KD that were unresponsive to repeated doses of IVIG and that required a large amount of corticosteroid to suppress the inflammatory response. Therefore, we were interested in our institution's experience with KD patients unresponsive to IVIG. We retrospectively analyzed all children admitted for KD over a 3-year period to determine the incidence of failure to fully respond to IVIG and to report our experience treating these children.

## METHODS

All patients treated for KD between September 1, 1993 and September 30, 1996, who fulfilled criterion for KD<sup>6,7</sup> were reviewed by 1 of us (C.A.W.). All patients were initially treated with 2 g/kg IVIG and aspirin (80–100 mg/kg/day in divided doses) until the second week of treatment, after which it was reduced to 5 mg/kg/day. Aspirin was continued until all signs of inflammation resolved and there were no coronary aneurysms on echocardiogram. Initial response was defined as defervescence by 48 hours after IVIG and no return of fever (>100°C) for at least 7 days after IVIG, with marked improvement or normalization of conjunctivitis, mouth and lip changes; rash; and swollen hands and feet. Treatment failure was defined as return of fever and 1 or more of the initial symptoms that led to the diagnosis of KD within 2 to 7 days of treatment with IVIG.<sup>2,3</sup> No patient was referred to our center because of failed treatment elsewhere; we did not include patients with atypical KD.

Definitions of coronary dilatation and aneurysm were based on published criteria<sup>8-10</sup>:

1. Lumen diameter at least 3 mm in a child <5 years old or at least 4 mm in a child ≥5 years old.
2. Internal diameter of a segment at least 1.5 times as large as that of an adjacent segment; or
3. Clearly irregular lumen. Giant aneurysm was defined as >8 mm in diameter.<sup>11,12</sup>

Statistical analyses included Fisher's exact test, 2-sided, and Student's *t* test, 2-sided, using SPSS 7.5 for Windows 95 (SPSS, Inc, Chicago, IL).

## RESULTS

Sixty-two (95%) of 65 children with KD initially improved after treatment with IVIG and aspirin. The 3 patients who did not initially respond, plus 12 others who had return of fever and symptoms (2–7 days after initial treatment, mean: 2.6 days; median: 2 days), were retreated with a second course of IVIG (2 g/kg). These 15 patients with failure to respond to IVIG were compared with the 50 who responded to a single course of IVIG. There was no difference in age, sex, length of symptoms to treatment, initial C-reactive protein (CRP), erythrocyte sedimentation rate (ESR), or the presence of abnormal initial echo-

From the Department of Pediatrics, University of Washington; and Children's Hospital and Regional Medical Center, Seattle, Washington.

Received for publication Sep 2, 1999; accepted Jan 11, 2000.

Reprint requests to (C.A.W.) Children's Hospital and Regional Medical Center, 4800 Sand Point Way NE, POB 5371 (CH-73), Seattle WA 98105-0371. E-mail: [cwallace@u.washington.edu](mailto:cwallace@u.washington.edu)

PEDIATRICS (ISSN 0031 4005). Copyright © 2000 by the American Academy of Pediatrics.

**TABLE 1.** Characteristics of Those Patients Responding and Not Responding to Single-Dose IVIG

Response	Yes <i>n</i> = 50	No <i>n</i> = 15	
Age			
Mean	3.4 y	3.0 y	
Median	2.45	2.25	<i>P</i> = .6
Range	(.3–9.0)	(.9–12.0)	
	10% < 1	7% < 1	
	32% = 1–2	40% = 1–2	
	58% > 2	53% > 2	
Sex (female/male)	25/25	5/10	
Mean d of illness to treatment	7.9	6.9	<i>P</i> = .4
	(68% < 7)	(73% < 7)	
Number of patients treated >10 d into illness	8	1	<i>P</i> = .7
Mean initial CRP	12.5	13.7	<i>P</i> = .9
Range (normal limits < .8)	(<.8–25.3)	(<.8–24.8)	
Initial ESR (normal limits < 20)	64	64	<i>P</i> = .06
Initial echocardiogram			
Normal	31	11	
Abnormal	Perivascular brightness = 13 Enlarged coronary = 5 Decrease LV contractility = 1	Perivascular brightness = 2 Giant aneurysm with thrombosis = 1 Perivascular brightness and decrease LV contractility = 1	

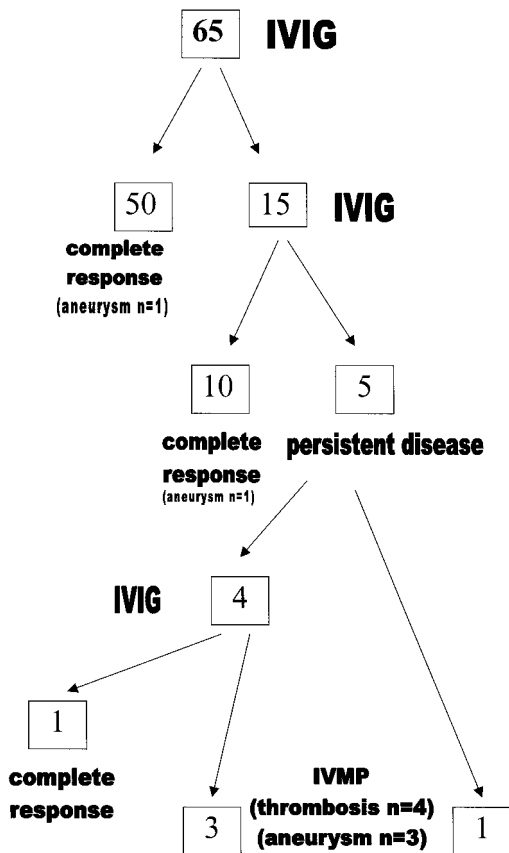
LV indicates left ventricle.

cardiogram (Table 1). Abnormal echocardiograms were similar in both groups and included perivascular brightness of the coronaries, decreased left ventricular contractility, or dilated coronaries. In the failure to respond group, 1 patient had a thrombosis in an aneurysm on initial echocardiogram.

Ten (76%) of the 15 patients requiring retreatment with IVIG responded to a second dose of IVIG (2

g/kg; Fig 1). Of the remaining 5, 4 were treated with a third dose of IVIG and 1 patient fully responded. Three patients who did not respond to 3 doses of IVIG, and 1 who did not respond to 2 doses, were treated with pulse intravenous (IV) methylprednisolone at 30 mg/kg/day for 3 days. All 4 developed thrombosis and 3 of these 4 patients had aneurysms. The thromboses were identified before IV methylprednisolone in 2 patients and after it in 2 others (Table 2). Initially, all 4 patients responded to IV methylprednisolone, but 2 required 1 to 3 more courses of methylprednisolone (30 mg/kg/day IV for 3–5 days) to control fever, conjunctivitis, rash, or mucous membrane changes. In these 2 patients, each time the IV methylprednisolone pulses were discontinued, conjunctivitis and mucous membrane changes returned and CRP increased. For these 2 patients, IV cyclophosphamide at 2 mg/kg/day was added (Table 2). IV methylprednisolone (30 mg/kg/day) was resumed and slowly decreased to 2 mg/kg/day divided twice daily over 2 weeks. There was no return of fever, conjunctivitis, mucous membrane changes, or increased CRP. At discharge, prednisone and cyclophosphamide were continued and gradually tapered over 1½ to 7 months. Complete control of inflammation and symptoms was accomplished in all patients; no patient died. Once methylprednisolone was started, no patient had progression of coronary aneurysms.

Five (8%) of the total 65 patients developed coronary aneurysms; 2 patients were <1 year of age. One patient with aneurysm (initial echocardiogram revealed a dilated coronary artery) resolved all symptoms after 1 treatment with IVIG and had a mildly enlarged coronary artery on echocardiogram 8 months and 2 years later. The other 4 patients required retreatment (3 of these 4 developed thromboses). Two patients with thromboses had giant coronary aneurysms, both before methylprednisolone was started. Six of the total 65 patients were <1 year of age. Of these, 2 developed coronary aneurysms; 1



**Fig 1.** Overview of treatment of 65 patients with KD. IVIG indicates intravenous gammaglobulin (2 g/kg); IVMP, intravenous methylprednisolone (30 mg/kg).

**TABLE 2.** Clinical Details and Follow-Up of Patients Failing Two Doses of IVIG

Sex	Age at Onset	First Treatment*	Initial Echocardiogram*	Number of Doses of IVIG	Aneurysm*	Thrombosis*	IV Methylprednisolone* (Number of Courses)	IV Cyclophosphamide	Last Echocardiogram
Male	.9 y	5 d	6 d; normal	3	29 d; 5.5 mm	29 d	18 d (4)	Yes	2.5 y; normal†
Female	1.8 y	23 d	20 d; echogenic coronaries	3	40 d; 9 mm (giant)	40 d	72 d (1)	No	4.1 y; LAD enlarged, aneurysm R coronary
Male	2.3 y	9 d	12 d; giant aneurysm and thrombosis and hypokinetic area LV apex	2	12 d; 9 mm (giant)	12 d	26 d (1)	No	4.0 y; enlarged, irregular LAD, small area hypokinesis LV
Male	2.7 y	5 d	6 d; echogenic coronaries	3	None	16 d	13 d (2)	Yes	2.8 y; normal†
Male	3.5 y	3 d	4 d; normal	3	None	None	None	No	2.8 y; normal†

LV indicates left ventricle; LAD, left anterior descending coronary artery.

\* d = day of illness.

† Does not confirm normal vessel wall histology.

responded to a single dose of IVIG and 1 failed 3 doses of IVIG but responded to IV methylprednisolone and cyclophosphamide. Patients with perivascular brightness of the coronaries who clinically responded to a single dose of IVIG resolved this finding .5 to 7 months later ( $n = 13$ ; mean: 1.0 months).

At the last echocardiogram follow-up, of the patients with thrombosis (mean: 2.8 years; range: 2.5–4.1 years), 2 had normal coronary vessels, whereas 2 had persistently abnormal coronaries (Table 2). There was no short-term toxicity from cyclophosphamide in the 2 patients who received it.

## DISCUSSION

The high rate of incomplete response of KD to IVIG in our patients (15/65; 23%) is surprising and higher than reported by others.<sup>2,3</sup> Because our center is both a community hospital and a regional referral center, it is possible that the perceived difficult cases were more likely to be referred for treatment, whereas the milder cases were treated elsewhere. However, no patient was initially treated elsewhere for KD and then referred to our institution for retreatment, and we did not include patients with atypical KD. The inability to identify factors at the time of initial treatment, which could predict the need for subsequent retreatment or the development of aneurysm, was disappointing but similar to findings of Sundel et al.<sup>2</sup> Not even the presence of an abnormal initial echocardiogram (35% of all patients) predicted the possible need for retreatment. The true incidence of coronary involvement is not known. Although the finding of perivascular brightness of the coronary arteries is subjective, it is suspicious for inflammation and did not differ between those patients who responded to treatment and those requiring retreatment. Eight percent of our patients with KD developed coronary aneurysms. This is similar to other reports of patients treated with 2 g/kg IVIG as a single dose.<sup>1</sup> However, our report is a small, retrospective study and a larger, prospective study may reveal predictors of disease requiring retreatment or progression to coronary aneurysm formation.

Historically, there has been considerable reticence among clinicians to use steroids in the treatment of KD for several reasons. The cause of KD is unknown and epidemiologic data had suggested an infectious cause. Intense investigation for an infectious agent has been unsuccessful to date. Recent investigators have focused on the possibility of microbial production of superantigens that lead to this overwhelming host response.<sup>6</sup> Concern about the procoagulant effect of IV methylprednisolone in severe vasculitis has also contributed to caution regarding its use. For 2 of our 4 patients with thromboses, the thrombotic event preceded the use of IV methylprednisolone. The major fear regarding the use of steroids followed an article by Kato et al,<sup>13</sup> which reported poor results in a small series of patients treated with oral steroid (2–3 mg/kg/day). This study does not describe how patients were chosen to receive steroids; it did not stratify for illness severity; and no echocardiographic data were available. Three years later, a report by Kijima et al<sup>14</sup>

demonstrated significant improvement in coronary dilatation and aneurysm with the use of IV methylprednisolone (30 mg/kg/day for 3 days). This investigation received little consideration because attention focused on the dramatic results with IVIG treatment.

In the last 6 years, the use of corticosteroids in KD reemerged with reports of 8 patients who had prompt, complete responses to IV pulse methylprednisolone.<sup>2-5</sup> Unlike these reported patients, 2 of our patients were unable to tolerate discontinuation of methylprednisolone without the symptoms of active KD reoccurring. The addition of cyclophosphamide in these 2 patients seemed to allow methylprednisolone to be tapered and slowly discontinued. Because KD is a self-limited disease, it is possible that the improvement in these 2 children was coincidental with starting cyclophosphamide. However, the temporal relationship with improvement and the repeated inability to stop methylprednisolone, before starting cyclophosphamide, is noteworthy. There were no deaths in our patients, no progression of coronary artery dilatation, and no formation of new aneurysms once pulse IV methylprednisolone had been started, supporting the study by Kijima et al<sup>14</sup> of IV methylprednisolone. Perhaps the worrisome results demonstrated by Kato et al<sup>13</sup> were attributable to the oral route of administration or too small of a dose, because the response in our patients and those previously reported was dramatic.<sup>2-5</sup>

Recently Shinohara et al<sup>15</sup> reviewed their use of IV prednisolone (2 mg/kg/day) with and without IVIG in the treatment of nearly 300 children with KD. Those treated with IV prednisolone had fewer aneurysms and more rapid resolution of fever. Although these patients were very different from ours (new onset vs treatment failures), the conclusions are relevant. Patients receiving corticosteroids seemed to do better than those not receiving corticosteroids; and there were no thrombotic events or adverse events attributable to the corticosteroids.

### CONCLUSION

In summary, KD is an intense life-threatening vasculitis. We agree with Sundel et al<sup>2</sup> that those patients with recurrence of symptoms have ongoing active vasculitis, which, if not aggressively treated, may lead to significant vascular damage. In our patients, IV methylprednisolone, and, perhaps cyclophosphamide, was helpful in resolving this intense vasculitis. It is unknown whether earlier treatment with pulse IV methylprednisolone in our patients

requiring repeat IVIG could have prevented coronary aneurysms or thrombosis. The use of corticosteroids theoretically makes sense, because it is the mainstay of treatment for many other vasculidities.<sup>16</sup> Most children with KD respond to IVIG, but up to a quarter may require retreatment. Careful multicenter, prospective studies are needed to determine patients at risk for treatment failure and to establish the role of immunosuppressive agents in patients with persistent KD.

### ACKNOWLEDGMENTS

We thank Michelle Gurr and Courtenay Michmerhuizen for assistance with manuscript preparation.

### REFERENCES

1. Durongpitsitkul K, Gururaj VJ, Park JM, Martin CF. The prevention of coronary artery aneurysm in Kawasaki disease: a meta-analysis of the efficacy of aspirin and immunoglobulin treatment. *Pediatrics*. 1995;96:1057-1061
2. Sundel RP, Burns JC, Baker A, Beiser AS, Newburger JW.  $\gamma$ -globulin retreatment in Kawasaki disease. *J Pediatr*. 1993;123:657-659
3. Wright DA, Newburger JW, Baker A, Sundel RP. Treatment of immune globulin-resistant Kawasaki disease with pulsed doses of corticosteroids. *J Pediatr*. 1996;128:146-149
4. Shetty AK, Homsy O, Ward K, Gedalia A. Massive lymphadenopathy and airway obstruction in a child with Kawasaki disease: success with pulse steroid therapy. *J Rheumatol*. 1998;25:1215-1217
5. Felz MW, Patni A, Brooks SE, Tesser RT. Periorbital vasculitis complicating Kawasaki syndrome in an infant. *Pediatrics*. 1998;101(6). URL: <http://www.pediatrics.org/cgi/content/full/101/6/e9>
6. Morens DM, O'Brien RJ. Kawasaki disease in the United States. *J Infect Dis*. 1978;137:91-93
7. Melish ME. Kawasaki syndrome. *Pediatr Rev*. 1996;17:153-162
8. Arjunan K, Daniels SR, Meyer RA, et al. Coronary artery caliber in normal children and patients with Kawasaki disease but without aneurysms: an echocardiographic and angiographic study. *J Am Coll Cardiol*. 1986;8:1119-1124
9. Takahashi M, Mason W, Lewis A. Regression of coronary artery aneurysms in patients with Kawasaki syndrome. *Circulation*. 1987;75:387-394
10. De Zorzi A, Colan SD, Gauvreau K, et al. Coronary artery dimensions may be misclassified as normal in Kawasaki disease. *J Pediatr*. 1998;133:254-258
11. Nakano H, Ueda K, Saito A, Nojima K. Repeated quantitative angiograms in coronary arterial aneurysms in Kawasaki disease. *Am J Cardiol*. 1985;56:846-851
12. Tataru K, Kusakawa S. Long-term prognosis of giant coronary aneurysm in Kawasaki disease: an angiographic study. *J Pediatr*. 1987;111:705-710
13. Kato H, Sigeyuki K, Yokoyama T. Kawasaki disease: effect of treatment of coronary artery involvement. *Pediatrics*. 1979;63:175-179
14. Kijima Y, Kayima T, Suzuki A, Hirose O, Manabe H. A trial procedure to prevent aneurysm formation of the coronary arteries by steroid pulse therapy in Kawasaki disease. *Jpn Circ J*. 1982;46:1239-1242
15. Shinohara M, Sone K, Tomomasa T, Morikawa A. Corticosteroids in the treatment of the acute phase of Kawasaki disease. *J Pediatr*. 1999;135:465-469
16. Newburger J. Treatment of Kawasaki disease: corticosteroids revisited. *J Pediatr*. 1999;46:411-412

## Initial Intravenous Gammaglobulin Treatment Failure in Kawasaki Disease

Carol A. Wallace, James W. French, Stuart J. Kahn and David D. Sherry

*Pediatrics* 2000;105:e78

DOI: 10.1542/peds.105.6.e78

### Updated Information & Services

including high resolution figures, can be found at:  
<http://pediatrics.aappublications.org/content/105/6/e78>

### References

This article cites 15 articles, 4 of which you can access for free at:  
<http://pediatrics.aappublications.org/content/105/6/e78#BIBL>

### Subspecialty Collections

This article, along with others on similar topics, appears in the following collection(s):  
**Infectious Disease**  
[http://www.aappublications.org/cgi/collection/infectious\\_diseases\\_sub](http://www.aappublications.org/cgi/collection/infectious_diseases_sub)

### Permissions & Licensing

Information about reproducing this article in parts (figures, tables) or in its entirety can be found online at:  
<http://www.aappublications.org/site/misc/Permissions.xhtml>

### Reprints

Information about ordering reprints can be found online:  
<http://www.aappublications.org/site/misc/reprints.xhtml>

# American Academy of Pediatrics

DEDICATED TO THE HEALTH OF ALL CHILDREN®



# PEDIATRICS®

OFFICIAL JOURNAL OF THE AMERICAN ACADEMY OF PEDIATRICS

## **Initial Intravenous Gammaglobulin Treatment Failure in Kawasaki Disease**

Carol A. Wallace, James W. French, Stuart J. Kahn and David D. Sherry

*Pediatrics* 2000;105:e78

DOI: 10.1542/peds.105.6.e78

The online version of this article, along with updated information and services, is located on the World Wide Web at:

<http://pediatrics.aappublications.org/content/105/6/e78>

Pediatrics is the official journal of the American Academy of Pediatrics. A monthly publication, it has been published continuously since 1948. Pediatrics is owned, published, and trademarked by the American Academy of Pediatrics, 345 Park Avenue, Itasca, Illinois, 60143. Copyright © 2000 by the American Academy of Pediatrics. All rights reserved. Print ISSN: 1073-0397.

American Academy of Pediatrics

DEDICATED TO THE HEALTH OF ALL CHILDREN®

