

Post-Varicella Epiglottitis and Necrotizing Fasciitis

Christopher L. Slack, MD*; Gregory C. Allen, MD*; John E. Morrison, MD, FAAP‡; Kurt C. Garren, MD*; and Mark G. Roback, MDS§

ABSTRACT. Varicella is a nearly ubiquitous acquired childhood disease. Infectious complications of varicella can be life- or limb-threatening. These complications appear 3 to 4 days after the appearance of varicella exanthem and are heralded by fever, pain, and erythema of the overlying skin. Airway complications of varicella are rare, rapidly evolving, and, unfortunately, difficult to visualize. We report a child who presented with a unique combination of varicella-induced airway complications—acute epiglottitis and subsequent necrotizing fasciitis of the head and neck. *Pediatrics* 2000;105(1). URL: <http://www.pediatrics.org/cgi/content/full/105/1/e13>; varicella, epiglottitis, necrotizing fasciitis, group A β -hemolytic streptococcus, nasopharyngoscopy.

ABBREVIATIONS. Hib, *Haemophilus influenzae* type b; CT, computed tomography; GABHS, group A β -hemolytic streptococcus.

Serologic studies indicate that >90% of the US population is exposed to varicella before 20 years of age.¹ Reports of life- and limb-threatening superinfection of varicella lesions are increasing. We present the case of a rapidly evolving post-varicella airway emergency.

CASE REPORT

An 8-year-old boy with a 3-day history of varicella exanthem presented to the pediatrician's office after 15 hours of rapidly evolving sore throat, high fever, vomiting, and stridor. He was immediately transported by ambulance to our pediatric tertiary care facility with notification enroute given to the otolaryngologist by the emergency physician. On emergency department arrival, the patient exhibited biphasic stridor with severe retractions of the rib cage and sternum. Pulse oximetry on 100% oxygen by face mask was 98%. Nasopharyngoscopy revealed a swollen, erythematous epiglottitis with a possible right parapharyngeal abscess. He was taken immediately to the operating room for definitive airway management.

The patient was anesthetized with intravenous midazolam 2 mg, and sevoflurane 8% in oxygen. Muscle relaxant was administered after a trial of mask ventilation was successful. After 2 unsuccessful intubation attempts by experienced pediatric anesthesiologists and failed rigid bronchoscopy, an emergent tracheotomy was performed under mask anesthesia. Diagnostic laryngoscopy and bronchoscopy thereafter revealed epiglottitis with multiple varicella ulcerations on the hypopharynx and posterior pharyngeal wall (Fig 1). Aerobic, anaerobic, and viral wound

cultures were taken. The right lateral pharyngeal wall was bulging, further obscuring the airway. The right parapharyngeal space was aspirated but no fluid was encountered.

On arrival to the intensive care unit, the patient's vital signs were: temperature 38.4°C, respiratory rate 37 breaths/minute, pulse 116 beats/minute, and blood pressure 126/87 mm Hg. His white blood cell count was 14.1 with 43% neutrophils and 51% bands. His immunization status was up to date. He had received the entire series of *Haemophilus influenzae* type b vaccine (Hib) but not the varicella vaccine. The epiglottal swab showed Gram-positive cocci in pairs and chains.

The patient initially was given vancomycin, acyclovir, and cefotaxime. Later that evening, his neck swelling worsened and bedside palpation resulted in the expression of foul smelling fluid about and within the tracheotomy. A computed tomography (CT) scan was performed that showed extensive soft tissue swelling with fascial plane separation and subcutaneous emphysema in the posterior pharynx, carotid sheath, and mediastinum (Fig 2). A radiolucency consistent with abscess was observed in the retropharynx.

A provisional diagnosis of necrotizing fasciitis with retropharyngeal abscess was made. Open neck exploration confirmed the diagnosis. Bilateral neck fasciotomy, irrigation, and intraoral retropharyngeal drainage with drain placement were performed. He required blood pressure support with dopamine, 5 μ g/kg/minute, for 32 hours after his initial exploration. Cultures of the blood, epiglottis, retropharynx, and neck grew group A β -hemolytic streptococcus (GABHS; *Streptococcus pyogenes*). *Staphylococcus aureus* was cultured from his retropharyngeal abscess and neck exploration. Viral culture results were negative. His antibiotics were changed to clindamycin and penicillin. Acyclovir was discontinued when the last varicella lesion had scabbed over.

Over the course of a 3-week hospital stay he received 3 more neck wound explorations to irrigate and debride with eventual tracheal decannulation 1 day before departure. He was sent home on oral clindamycin with penrose neck drains in place. He received a total of 6 weeks of antibiotic therapy.

DISCUSSION

Varicella is a nearly ubiquitous pathogen, infecting ~3.8 million children annually in the United States alone.¹ Complications of varicella led to hospitalization of ~177 per 100 000 children infected.² Bacterial superinfection of the skin is the most common complication of varicella, with GABHS the most frequent causative organism.³

Predisposing factors for GABHS bacteremia in children include varicella, leukemia, and conditions that compromise the integument.⁴ Post-varicella GABHS has a well-documented association with necrotizing fasciitis and toxic shock. It has recently been reported as a causative organism in epiglottitis.⁵

The incidence of epiglottitis and Hib disease has declined dramatically since the introduction of the Hib vaccine in 1988.⁶ Before the vaccine, 80% of epiglottitis was caused by Hib. Introduction of this vaccine has made epiglottitis a rare entity.⁷ Epiglottitis is a rapidly evolving disease with a median prodrome of 17 hours and blood culture proven bac-

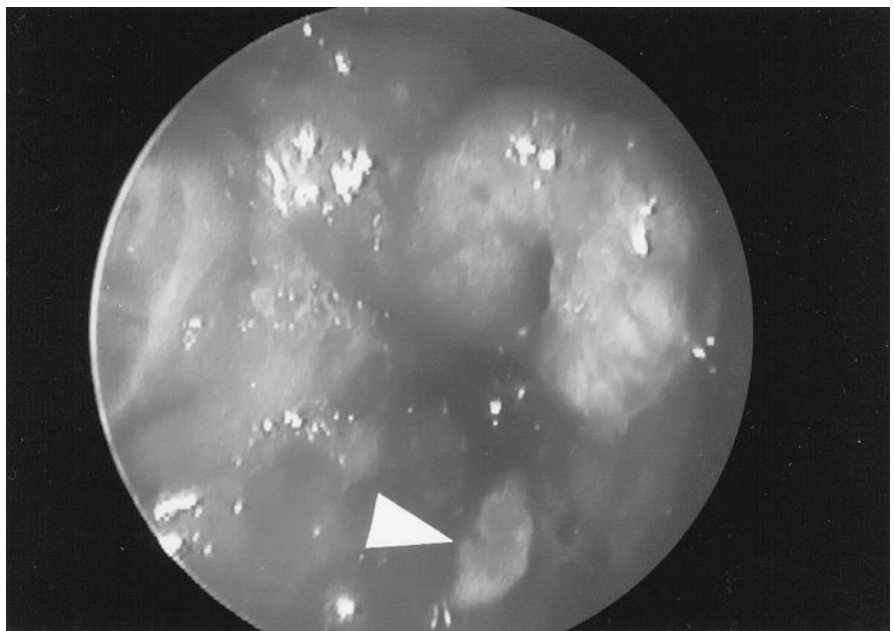
From the Departments of *Otolaryngology, Head and Neck Surgery, ‡Anesthesiology, and §Emergency Medicine, University of Colorado School of Medicine, Children's Hospital, Denver, Colorado.

Received for publication Jun 22, 1999; accepted Aug 17, 1999.

Reprint requests to (C.L.S.) Department of Pediatric Otolaryngology, Children's Hospital, 1056 E 19th Ave, Denver, CO 80218. E-mail: cnvslack@concentric.net

PEDIATRICS (ISSN 0031 4005). Copyright © 2000 by the American Academy of Pediatrics.

Fig 1. Acute epiglottitis with varicella ulceration on the posterior hypopharyngeal wall (white arrowhead).



teremia in 79%.⁷ It manifests with respiratory distress, fever, and a toxic appearance. An artificial airway is required in >75% of cases.⁷

When epiglottitis is suspected, current pediatric emergency texts recommend minimal patient stimulation and visualization of the epiglottitis in a controlled environment (operating room) by physicians highly skilled in airway management (anesthesiologists and surgeons).⁸ Agitation of the patient may lead to complete airway obstruction. Although soft

tissue films of the lateral neck are often used to evaluate suspected epiglottitis, they require precious time and an attendant with the ability and equipment to provide definitive airway management should airway obstruction occur. Nasopharyngoscopy by the otolaryngologist was used effectively and safely in this case of a toxic-appearing child with suspected epiglottitis to quickly and noninvasively evaluate the airway in the trauma bay. However, a cricothyrotomy kit was available and all aggressive

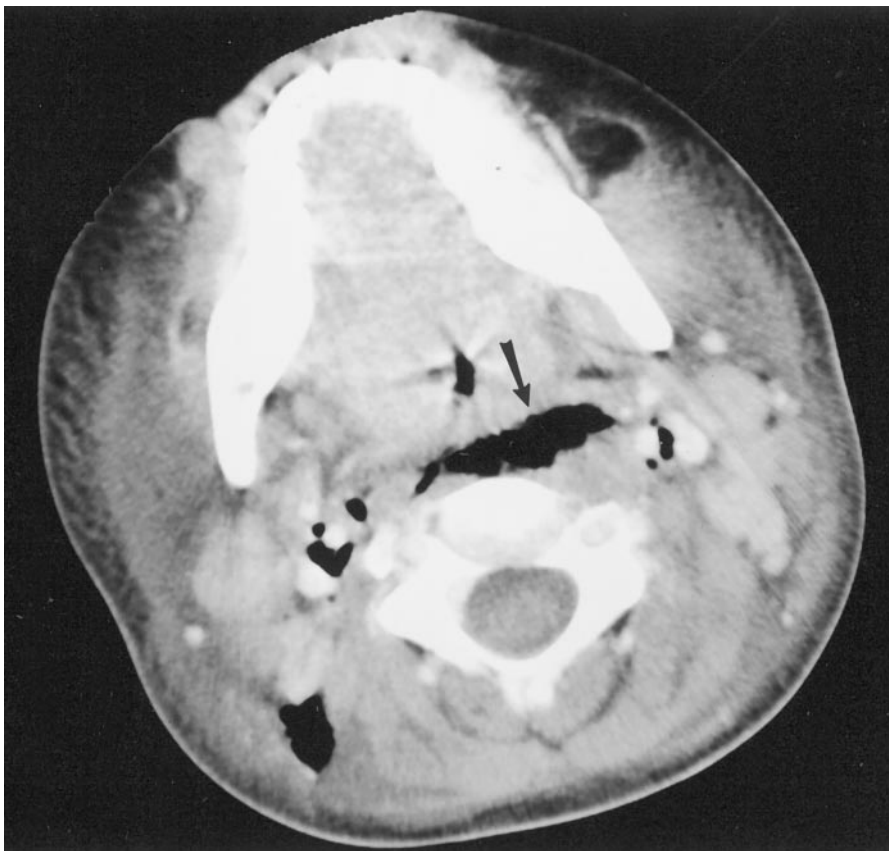

Fig 2. Axial CT scan showing extensive soft tissue swelling and subcutaneous emphysema in the retropharyngeal space (black arrow) and bilateral carotid sheaths.

airway visualization and management procedures occurred in the operating room.

Unsuccessful intubation and bronchoscopy coupled with difficult mask ventilation in our patient with varicella induced ulceration of the posterior pharyngeal wall may have caused the extensive subcutaneous air demonstrated by CT scan. Whether this initiated or facilitated the spread of the necrotizing fasciitis is uncertain.

The association of post-varicella necrotizing fasciitis and GABHS is being documented more frequently.⁹⁻¹¹ The mean duration of varicella exanthem before secondary symptoms of necrotizing fasciitis is 3 to 4 days.^{9,11} After this time, children will present with persistent or recurrent fever >38.5°C, erythema, focal pain, and localized tissue swelling. Admission leukocyte counts are typically elevated but may be normal. A bandemia is usually present. Hypotension and tachycardia are common; 36% will require fluid resuscitation and inotropic support for the treatment of streptococcal toxic shock.¹¹ Mortality is typically cited as between 20% and 50%.¹² Urgent surgical debridement may reduce mortality and morbidity.¹³

Streptococcal toxic shock is mediated by the GABHS antiphagocytic antigens (M-proteins) and pyrogenic exotoxins. The rapid growth of GABHS can result in a stationary growth phase rendering penicillin ineffective when inocula exceeds 10⁷ organisms/mm³.¹⁴ These conditions are only reached in abscess cavities, necrotizing fasciitis, and overwhelming sepsis. Clindamycin is perhaps the ideal antibiotic choice, because it is not effected by inoculum size and covers possible concomitant anaerobic infection. Clindamycin also enhances penicillin killing of GABHS and has been shown to suppress both the expression of the cell-surface M protein and extracellular toxin formation.¹⁴ The treatment of necrotizing fasciitis mandates urgent operative debridement with survivors requiring an average of 3.8 operations.¹⁵

This case illustrates several key points. Nasopharyngoscopy has provided the means to diagnose the difficult airway quickly and noninvasively. Management of the difficult airway is performed best in the operating room. The presence of fever, pain, and

signs of infection in children with varicella exanthem of 3 to 4 days' duration warrants urgent evaluation. The use of clindamycin to treat GABHS and immediate operative intervention in necrotizing fasciitis is strongly recommended. Lastly, the varicella vaccine, with a 98% seroconversion rate, may prevent complications of varicella by eliminating the primary infection. It may ultimately prove as far reaching as the Hib vaccine in mediating epiglottitis.¹⁶

REFERENCES

1. Choo PW, Donahue JG, Manson JE, Platt R. The epidemiology of varicella and its complications. *J Infect Dis.* 1995;172:706-711
2. Shreck P, Shreck P, Bradley J, Chambers H. Musculoskeletal complications of varicella. *J Bone Joint Surg.* 1996;78A:1713-1719
3. Aebi C, Ahmed A, Ramilo O. Bacterial complications of primary varicella in children. *Clin Infect Dis.* 1996;23:698-705
4. Wong VK, Wright HT. Group A beta-hemolytic streptococci as a cause of bacteremia in children. *Am J Dis Child.* 1988;142:831-833
5. Belfer RA. Group A beta-hemolytic streptococcal epiglottitis as a complication of varicella infection. *Pediatr Emerg Care.* 1996;12:203-204
6. Broadhurst LE, Erickson RL, Kelley PW. Decreases in invasive *Haemophilus influenzae* diseases in US Army children, 1984 through 1991. *JAMA.* 1993;269:227-231
7. Sly PD, Landau LI, Wagener JS. Acute epiglottitis in childhood: report of an increased incidence in Victoria. *Aust N Z J Med.* 1984;14:131-134
8. Fleisher GR. Infectious diseases emergencies. In: Fleisher GR, Ludwig S, eds. *Textbook of Pediatric Emergency Medicine.* 3rd ed. Baltimore, MD: Williams & Wilkins; 1993:617-621
9. Waldhausen JH, Holterman MJ, Sawin RS. Surgical implications of necrotizing fasciitis in children with chickenpox. *J Pediatr Surg.* 1996;31:1138-1141
10. Wilson GJ, Talkington DF, Gruber W, Edwards K, Dermody TS. Group A streptococcal necrotizing fasciitis following varicella in children: case reports and review. *Clin Infect Dis.* 1995;20:1333-1338
11. Brogan TV, Nizet V, Waldhausen JH, Rubens CE, Clarke WR. Group A streptococcal necrotizing fasciitis complicating primary varicella: a series of fourteen patients. *Pediatr Infect Dis J.* 1995;14:588-594
12. Stevens DL. Invasive group A streptococcus infections. *Clin Infect Dis.* 1992;14:2-11
13. Sudarsky LA, Laschinger JC, Coppa GF, Spencer FC. Improved results from a standardized approach in treating patients with necrotizing fasciitis. *Ann Surg.* 1987;206:661-665
14. Stevens DL, Gibbons AE, Bergstrom R, Winn V. The eagle effect revisited: efficacy of clindamycin, erythromycin, and penicillin in the treatment of streptococcal myositis. *J Infect Dis.* 1988;158:23-28
15. Moss RL, Musemeche CA, Kosloske AM. Necrotizing fasciitis in children: prompt recognition and aggressive therapy improve survival. *J Pediatr Surg.* 1996;31:1142-1146
16. Johnson CE, Stancin T, Fattlar D, Rome LP, Kumar ML. A long-term prospective study of varicella vaccine in healthy children. *Pediatrics.* 1997;100:761-766

Post-Varicella Epiglottitis and Necrotizing Fasciitis

Christopher L. Slack, Gregory C. Allen, John E. Morrison, Kurt C. Garren and Mark G. Roback

Pediatrics 2000;105:e13

DOI: 10.1542/peds.105.1.e13

Updated Information & Services

including high resolution figures, can be found at:
<http://pediatrics.aappublications.org/content/105/1/e13>

References

This article cites 15 articles, 1 of which you can access for free at:
<http://pediatrics.aappublications.org/content/105/1/e13#BIBL>

Permissions & Licensing

Information about reproducing this article in parts (figures, tables) or in its entirety can be found online at:
<http://www.aappublications.org/site/misc/Permissions.xhtml>

Reprints

Information about ordering reprints can be found online:
<http://www.aappublications.org/site/misc/reprints.xhtml>

American Academy of Pediatrics

DEDICATED TO THE HEALTH OF ALL CHILDREN®



PEDIATRICS®

OFFICIAL JOURNAL OF THE AMERICAN ACADEMY OF PEDIATRICS

Post-Varicella Epiglottitis and Necrotizing Fasciitis

Christopher L. Slack, Gregory C. Allen, John E. Morrison, Kurt C. Garren and Mark G. Roback

Pediatrics 2000;105:e13

DOI: 10.1542/peds.105.1.e13

The online version of this article, along with updated information and services, is located on the World Wide Web at:

<http://pediatrics.aappublications.org/content/105/1/e13>

Pediatrics is the official journal of the American Academy of Pediatrics. A monthly publication, it has been published continuously since 1948. Pediatrics is owned, published, and trademarked by the American Academy of Pediatrics, 345 Park Avenue, Itasca, Illinois, 60143. Copyright © 2000 by the American Academy of Pediatrics. All rights reserved. Print ISSN: 1073-0397.

American Academy of Pediatrics

DEDICATED TO THE HEALTH OF ALL CHILDREN®

