

Congenital Hypothyroidism and Nonimmune Hydrops Fetalis: Associated?

ABSTRACT. Hydrops fetalis (HF) consists of an abnormal accumulation of fluid in two or more fetal compartments, including ascites, pleural effusion, pericardial effusion, and skin edema. Almost all observed cases of HF are of the nonimmune type, the causes of which remain undetermined in 15% of patients. We report a newborn infant with nonimmune hydrops fetalis (NIHF) and congenital hypothyroidism. The infant's mother was healthy and there were no malformations of the placenta or umbilical cord. The infant did not show any structural abnormalities of his central nervous, cardiovascular, gastrointestinal, or urinary tract systems, and there was no evidence of anemia, infectious disease, or inborn error of metabolism. An immune-based process was unlikely, because the blood group of the mother and infant was A-positive and results of an indirect Coombs test in the mother and a direct Coombs test in the infant were negative. The patient's condition gradually improved with mechanical ventilation, repeated thoracentesis, and total parenteral nutrition. By day 5 of age the skin edema, pericardial effusion, and ascites disappeared, but accumulation of significant amounts of chylous pleural fluid persisted. Because of lethargy, FT₄ and thyroid-stimulating hormone levels were obtained and showed hypothyroidism. Thyroid hormone supplementation was then started, and within 4 days the infant became more vigorous and was weaned from mechanical ventilation. After 7 days, the chylothorax resolved completely as the serum thyroxine level normalized. No reaccumulation of pleural effusion was noticed. The infant started to gain weight and was discharged from the hospital at 35 days of age. A possible pathophysiologic association between congenital hypothyroidism and NIHF is discussed. NIHF may be caused by lymphatic congestion attributable to an impairment of lymphatic flow and a delayed return of lymph to the vascular compartment. There could be a possibility that because of thyroid hormone deficiency in this patient, there was reduced adrenergic stimulation of the lymphatic system. This could result in a sluggish flow of the lymph with engorgement of the lymphatic system, leakage of lymph into the pleura and the interstitial spaces, and the production of chylothorax with NIHF. Animal studies demonstrate a direct relationship between lymph flow rate or lung liquid clearance and adrenergic receptor activity in the lymphatic system. These observations support our hypothesis that deficient adrenergic activity in congenital hypothyroidism might lead to chylothorax with NIHF in the fetus. We speculate that thyroid hormone may play a role in the regulation of adrenergic receptors in the lymphatic system and lungs, thus modulating both the lymphatic flow rate and lung liquid clearance, and facilitating the resolution of chylothorax. Examination

of thyroid functions should be included in the investigation of fetuses and neonates with NIHF of an obscure origin. *Pediatrics* 1999;103(1). URL: <http://www.pediatrics.org/cgi/content/full/103/1/e9>; *hypothyroidism, hydrops fetalis, newborn infant*.

ABBREVIATIONS. HF, hydrops fetalis; Hb, hemoglobin; NIHF, nonimmune hydrops fetalis.

Hydrops fetalis (HF) consists of an abnormal accumulation of fluid in two or more fetal compartments, including ascites, pleural effusion, pericardial effusion, and skin edema. In some patients, it also may be associated with polyhydramnios and placental edema.¹ HF may be attributable to immune or nonimmune causes.² With the advent of routine anti-D globulin prophylaxis of Rh isoimmunization, almost all observed cases of HF are of the nonimmune type, the causes of which remain undetermined in 15% of patients.² We report a newborn with nonimmune HF and congenital hypothyroidism. The pleural fluid was chylothorax that persisted until normalization of serum thyroxine level by thyroid hormone replacement therapy. A possible pathophysiologic association between congenital hypothyroidism and nonimmune HF is discussed.

CASE REPORT

This 3500-g male infant was born after 35 weeks' gestation to a 20-year-old healthy mother by induced vaginal delivery. The parents are unrelated Moslem Arabs and have two other healthy children (a 3-year-old boy and a 2-year-old girl). The pregnancy had been uneventful until 34 weeks, when the mother noticed a decrease in fetal movements. Fetal ultrasound examination revealed massive bilateral hydrothorax, a small pericardial effusion, ascites, thickening of scalp skin, and mild polyhydramnios. Cordocentesis showed normal karyotype and normal blood count, and no evidence of intrauterine infection. No placental or cord abnormalities were found.

At birth the infant presented with generalized edema and severe respiratory failure, necessitating cardiopulmonary resuscitation and mechanical ventilation. After stabilization of his condition, he was transferred to the neonatal intensive care unit. Physical examination on admission revealed severe generalized edema, decreased breath sounds bilaterally, and abdominal distention. No malformations or dysmorphic features were noticed. Chest tubes were inserted, through which 90 mL and 160 mL of clear fluid were drained from the left and right pleural cavities, respectively.

Additional laboratory tests were performed in an attempt to detect a possible cause of hydrops fetalis (HF). An immune-based process was unlikely, because the blood group of the mother and infant was A-positive, and results of an indirect Coombs test in the mother and a direct Coombs test in the infant were negative. Echocardiography demonstrated minimal pericardial effusion with normal structure and function of the heart. Central venous pressure was not measured. Results of ultrasound examination of the brain were normal. The pleural fluid initially was clear, but after initiation of enteral feeding, it became chylous (albumin, 1.9 g/dL; glucose, 89 mg/dL; LDH, 157 U/L; triglycerides, 260

Drs Kessel and Makhoul are primary co-authors.

Received for publication Jun 9, 1998; accepted Aug 24, 1998.

Address correspondence to Imad R. Makhoul, MD, DSc, Department of Neonatology, Rambam Medical Center, Bat-Galim, Haifa 31096, Israel.

PEDIATRICS (ISSN 0031 4005). Copyright © 1999 by the American Academy of Pediatrics.

mg/dL; white blood cells, 2070/mm³; lymphocytes, 97.4%; no virus could be isolated; negative culture for bacteria and fungi). Complete blood count was hemoglobin (Hb) = 14.1 g/dL; white blood cells = 9400; platelet = 402 000; band forms = 7%; neutrophils = 54%; eosinophils = 1%; basophils = 2%; monocytes = 15%; lymphocyte = 21%; with normal red cell morphology. In this patient, there was no evidence of hemolysis or hyperbilirubinemia; thus, the levels of fetal Hb and glucose 6-phosphate dehydrogenase were not obtained. Serum electrolytes, creatinine, blood urea nitrogen, and liver enzymes were normal. The initial serum protein level was low (3.7 g/dL), as well as the serum albumin level (2.5 g/dL). There was no metabolic acidosis. IgM antibodies for parvovirus B19, toxoplasmosis, rubella, cytomegalovirus, herpes simplex virus, Epstein-Barr virus, and adenovirus were negative. Urinary amino acids, organic acids, and mucopolysaccharides were normal.

The patient's condition improved gradually with mechanical ventilation, two infusions of 5% albumin, and two doses of furosemide (days 1 and 2 of life), repeated thoracentesis, and total parenteral nutrition. By day 5 of age, skin edema, pericardial effusion, and ascites disappeared, but the infant continued to accumulate significant amounts of chylous pleural fluid despite continued drainage and parenteral nutrition, along with enteral medium-chain triglycerides-rich formula.

At day 14 of age, the infant was noticed to be lethargic and hypotonic. A low serum FT₄ level of 4.9 pmol/L (normal values, 10.5 to 25) and an elevated thyroid-stimulating hormone level of 87.2 mU/L (normal values, 0.3 to 2.83) confirmed the diagnosis of congenital hypothyroidism. The results of the Neonatal Thyroid Screening Program (obtained at the 9th day of life) also demonstrated hypothyroidism: TT₄ = 4.2 μg/dL (normal values, 5 to 20) and thyroid-stimulating hormone = 14 μIU/mL (normal values, <10). No thyroid autoantibodies were detected in the mother or the infant. Thyroid hormone supplementation was then started, and within 4 days the infant became more vigorous and was weaned from mechanical ventilation. After 7 days, the chylothorax resolved completely as serum thyroxine level normalized (FT₄ = 27 pmol/L). Medium-chain triglycerides-rich formula was switched gradually to cow milk-based formula without reaccumulation of pleural effusion. The infant started to gain weight and was discharged from the hospital at 35 days of age.

DISCUSSION

The list of conditions associated with nonimmune hydrops fetalis (NIHF) is long and still increasing.² Included are a number of fetal focal and generalized abnormalities, placental and umbilical cord causes, and maternal disorders. Investigation of the NIHF in our patient did not reveal any of the known etiologies or associations, but disclosed congenital hypothyroidism. The infant's mother was healthy, and there were no malformations of the placenta or umbilical cord. The infant did not show any structural abnormalities of his central nervous, cardiovascular, gastrointestinal, or urinary tract systems, and there was no evidence of anemia, infectious disease, or inborn error of metabolism.

Chylothorax, regardless of its cause, can be associated occasionally with NIHF.² Furthermore, congenital hypothyroidism may manifest with pericardial effusion at birth. If left untreated, congenital hypothyroidism may cause effusions in pleura, pericardium, and skin edema in infancy.³ A question that arises is whether fetal hypothyroidism can lead to chylothorax and hydrops fetalis. We hereby discuss the possible mechanism that might underlie this association (Fig 1).

NIHF also may be caused by lymphatic congestion attributable to an impairment of lymphatic flow and a delayed return of lymph to the vascular compartment, or may be attributable to a primary malformation of the lymphatic vessels.¹ The possibility of a

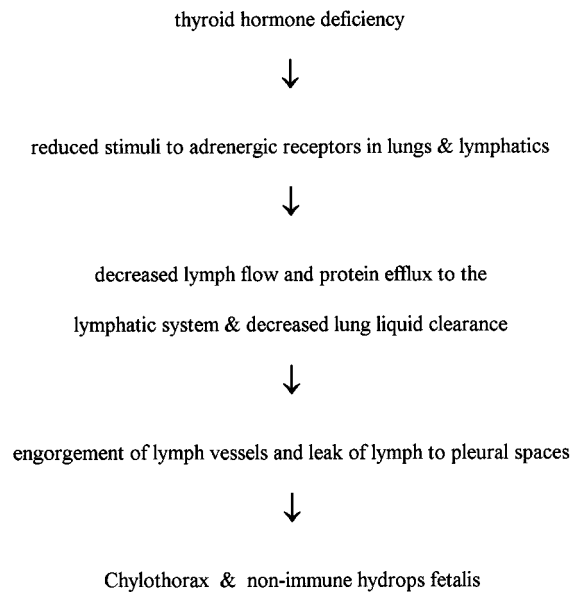


Fig 1. Proposed pathophysiology of the association of congenital hypothyroidism with chylothorax and NIHF.

lymphatic network malformation in our infant can be discarded, in consideration of the rapid resolution of his chylothorax after thyroxine treatment of his hypothyroidism. On the other hand, there could be a possibility that because of thyroid hormone deficiency in this patient, there was a reduced adrenergic stimulation of the lymphatic system. This could result in a sluggish flow of the lymph with engorgement of the lymphatic system, leakage of lymph into the pleura and the interstitial spaces, and the production of chylothorax with NIHF (Fig 1). Several experimental observations support our hypothesis that a deficient adrenergic activity in congenital hypothyroidism might lead to NIHF.

Thyroid hormone effects are known to be mediated by adrenergic receptors. Hypothyroidism in the rat fetus reduces the number of α -1 receptors in kidneys,⁴ whereas thyroid hormone exerts a positive inotropic effect on the primate heart, upregulating β -1 and particularly β -2 adrenergic receptors.⁵ Perinatal administration of propylthiouracil in the rat reduces α -2 receptor binding sites, whereas administration of triiodothyronine in rat neonates has the opposite effect.⁶

Animal studies demonstrate a direct relationship between lymph flow rate or lung liquid clearance and adrenergic receptor activity in the lymphatic system. Intracoronary infusion of a β -agonist in dogs led to an increase in lymphatic flow and protein efflux to lymph.⁷ A β -adrenergic agonist in sheep increased lung liquid clearance, an effect inhibited by adding a β -blocking agent.⁸ In a canine moving hind limb, low intraarterial doses of either adrenaline or noradrenaline increased lymphatic flow in the femoral triangle.⁹ α -Adrenergic blockade in sheep decreased pulmonary lymph flow.¹⁰ Furthermore, stimulation of the sympathetic chain in sheep was found to increase popliteal lymph flow that could be blocked by α -adrenergic blockers.¹¹

If our "reduced adrenergic stimulation" hypothe-

sis indeed is correct, then the question that remains is why do not all hypothyroid fetuses develop NIHF? We could not find any association reported of congenital hypothyroidism and chylothorax or NIHF in infants. There is, however, a single case report that describes an acquired hypothyroidism and chylothorax that resolved only after initiation of thyroxine treatment.¹² This was an adult patient with malignancy, in whom chylothorax appeared after radiation therapy of the chest. We did not measure the level of acid mucopolysaccharides in the pleural fluid, although such test would have been of interest for proving the proposed association of NIHF and hypothyroidism.

Gestation is commonly prolonged in patients with congenital hypothyroidism. In this case, signs of chylothorax and NIHF, presumably attributed to hypothyroidism, appeared in the fetus before birth and dictated early induction of labor. Symptoms and signs of congenital hypothyroidism usually appear later in infancy. However, in a few patients, they can be apparent at birth.¹³

In this patient, features of NIHF (other than chylothorax) such as skin edema and pericardial effusion did remit before the initiation of thyroxine therapy. Our proposed association, as illustrated in Fig 1, refers primarily to the development of chylothorax attributable to reduced adrenergic stimulation in the lymphatic system. Severe fetal chylothorax by itself, in combination with hypoalbuminemia, may lead to NIHF. NIHF probably would have been worse had the delivery occurred at term.

We speculate that thyroid hormone may play a role in the regulation of adrenergic receptors in the lymphatic system and lungs, thus modulating both the lymphatic flow rate and lung liquid clearance and facilitating the resolution of chylothorax. Based on this constellation, we propose that NIHF might be associated with congenital hypothyroidism, and examination of thyroid functions should be included in the investigation of fetuses and neonates with NIHF of obscure origin. Detecting hypothyroidism in a fetus with NIHF will raise questions regarding the efficacy of

fetal thyroxine replacement therapy on the course of NIHF.

IRENE KESSEL, MD
IMAD R. MAKHOUL, MD, DSc
POLO SUJOV, MD
Department of Neonatology
Rambam Medical Center
Rappaport Faculty of Medicine
Technion, Israel Institute of Technology
Haifa 31096, Israel

REFERENCES

1. Apkon M. Pathophysiology of hydrops fetalis. *Semin Perinatol.* 1995;19:437-446
2. Jones DC. Nonimmune fetal hydrops: diagnosis and obstetric management. *Semin Perinatol.* 1995;19:447-61
3. Gotteher A, Roa J, Stanford GG, Chernow B, Sahn SA. Hypothyroidism and pleural effusions. *Chest.* 1990;98:1130-1132
4. Tan JP, Seidler FJ, Schwinn DA, Page SO, Slotkin TA. A critical period for the role of thyroid hormone in development of renal alpha-adrenergic receptors. *Pediatr Res.* 1997;42:93-102
5. Hoit BD, Khoury SF, Shao Y, Gabel M, Liggett SB, Walsh RA. Effects of thyroid hormone on cardiac beta-adrenergic responsiveness in conscious baboons. *Circulation.* 1997;15:592-598
6. Metz LD, Seidler FJ, McCook EC, Slotkin TA. Cardiac alpha-adrenergic receptor expression is regulated by thyroid hormone during a critical developmental period. *J Mol Cell Cardiol.* 1996;28:1033-1044
7. Saito D, Hasui M, Shiraki T, Kono H. Effects of coronary blood flow, myocardial contractility and heart rate on cardiac lymph circulation in open-chest dogs. Use of direct cannulation method for subepicardial lymph vessel. *Arzneimittelforschung.* 1997;47:119-124
8. Berthiaume Y, Staub NC, Matthay MA. Beta-adrenergic agonists increase lung liquid clearance in anesthetized sheep. *J Clin Invest.* 1987;79:335-343
9. De Micheli P, Glasser AH. The effects of catecholamines and adrenoceptor blocking drugs on the canine peripheral lymph flow. *Br J Pharmacol.* 1975;53:499-504
10. Hakim TS, Minnear FL, van der Zee H, Barie PS, Malik AB. Adrenoceptor control of lung fluid and protein exchange. *J Appl Physiol.* 1981;51:68-72
11. McHale NG. Lymphatic innervation. *Blood Vessel.* 1990;27:127-136
12. Kollef MH. Recalcitrant chylothorax and chylous ascites associated with hypothyroidism. *Mil Med.* 1993;158:63-65
13. Moshang T Jr, Thornton PS. Endocrine disorders. In: Avery GB, Fletcher MA, MacDonald MG, eds. *Neonatology. Pathophysiology and Management of the Newborn.* 4th ed. Philadelphia, PA: JB Lippincott Company; 1994:787

Congenital Hypothyroidism and Nonimmune Hydrops Fetalis: Associated?

Irene Kessel, Imad R. Makhoul and Polo Sujov

Pediatrics 1999;103:e9

DOI: 10.1542/peds.103.1.e9

Updated Information & Services

including high resolution figures, can be found at:
<http://pediatrics.aappublications.org/content/103/1/e9>

References

This article cites 12 articles, 0 of which you can access for free at:
<http://pediatrics.aappublications.org/content/103/1/e9#BIBL>

Permissions & Licensing

Information about reproducing this article in parts (figures, tables) or in its entirety can be found online at:
<http://www.aappublications.org/site/misc/Permissions.xhtml>

Reprints

Information about ordering reprints can be found online:
<http://www.aappublications.org/site/misc/reprints.xhtml>

American Academy of Pediatrics

DEDICATED TO THE HEALTH OF ALL CHILDREN®



PEDIATRICS®

OFFICIAL JOURNAL OF THE AMERICAN ACADEMY OF PEDIATRICS

Congenital Hypothyroidism and Nonimmune Hydrops Fetalis: Associated?

Irene Kessel, Imad R. Makhoul and Polo Sujov

Pediatrics 1999;103:e9

DOI: 10.1542/peds.103.1.e9

The online version of this article, along with updated information and services, is located on the World Wide Web at:

<http://pediatrics.aappublications.org/content/103/1/e9>

Pediatrics is the official journal of the American Academy of Pediatrics. A monthly publication, it has been published continuously since 1948. Pediatrics is owned, published, and trademarked by the American Academy of Pediatrics, 345 Park Avenue, Itasca, Illinois, 60143. Copyright © 1999 by the American Academy of Pediatrics. All rights reserved. Print ISSN: 1073-0397.

American Academy of Pediatrics

DEDICATED TO THE HEALTH OF ALL CHILDREN®

