

Cost-effective Treatment of Phimosis

Robert S. Van Howe, MD

ABSTRACT. *Objective.* To determine the most cost-effective treatment for phimosis.

Design. The costs of three treatment strategies for treating phimosis were evaluated using a decision-tree analysis. Three therapeutic approaches were considered: circumcision, preputial plasty (the use of plastic surgical techniques to enlarge the preputial opening without removing tissue), and topical therapy with steroids and nonsteroidal antiinflammatories. Published failure and complication rates were used to calculate the cost per case.

Outcome Measures. Cost in dollars to treat each case of phimosis.

Results. Topical steroid therapy was the most cost-effective strategy, costing between \$758 and \$800 per case. Preputial plasty cost between \$2515 and \$2580 per case. Circumcision cost between \$3009 and \$3241 per case.

Conclusions. The most cost-effective management for treating phimosis is to initiate topical therapy. Daily external application from the tip of the foreskin to the glandis corona with betamethasone 0.05% cream for 4 to 6 weeks has been demonstrated to be very effective, resulting in a 75% savings compared with circumcision. Surgical intervention should not be considered until topical therapy has been given an adequate trial. When contemplating surgery, the lower morbidity, lower costs, and tissue preservation of preputial plasty may make it preferable. *Pediatrics* 1998;102(4). URL: <http://www.pediatrics.org/cgi/content/full/102/4/e43>; *phimosis, betamethasone, preputial plasty, circumcision.*

ABBREVIATION. BXO, balanitis xerotica obliterans.

It has recently been demonstrated that patients with true phimosis can be treated successfully with topical creams in 65% to 95% of cases.¹⁻¹⁰ Also, a number of prepuce-sparing surgical treatments (preputial plasty) for phimosis have been developed.¹¹⁻¹⁸ Two studies have compared the results of preputial plasty with conventional circumcision,¹⁹⁻²⁰ finding that the plastic procedure lowered morbidity and recovery time as well as the incidence of meatal stenosis after surgery.

With the advent of these newer, less invasive, less morbid alternatives, it is important to document the most cost-effective manner of treating phimosis.

From the Department of Pediatrics, Marshfield Clinic—Lakeland Center, Minocqua, Wisconsin.

Received for publication Sep 9, 1997; accepted May 18, 1998.

Reprint requests to (R.S.V.H.) Marshfield Clinic, Lakeland Center, 9601 Townline Rd, PO Box 1390, Minocqua, WI 54548.

PEDIATRICS (ISSN 0031 4005). Copyright © 1998 by the American Academy of Pediatrics.

METHODS

A decision-tree analysis was performed for three initial treatment strategies: circumcision, preputial plasty, and topical steroids. The costs, complication rates, failure rates, and time missed from work (parental or personal) are listed in Table 1.

The failure rate for topical therapy was calculated by combining the results of the 10 studies published to date (Table 2).¹⁻¹⁰ Time lost from work was based on the mean time it took after surgery for underpants to be worn comfortably.¹⁹ Income was assumed to be \$35 000 per annum.

Although the British study by Cuckow et al¹⁹ documented a 20% overnight hospitalization rate after circumcision, the rate in the United States is unknown. Most of the overnight hospitalizations were secondary to anesthesia complications. Overnight hospitalization rates of 6% (the rate of reoperation for bleeding) and 20% were used for calculations. Hospitalization rates for preputial plasty were 40% of those for circumcision.¹⁹ The reported rates of meatal stenosis requiring meatotomy after circumcision range from 2.8%²¹ to 11.1%.²² Calculations were made using meatotomy rates of 2.8% and 8%.²⁰

For the preputial plasty group, failures were treated with circumcision. For the topical therapy, failures were treated with circumcision under the assumption that those who failed topical therapy did not respond because the underlying pathology was balanitis xerotica obliterans (BXO) based on the determination that the failure rate of topical therapy was nearly the same as the incidence of BXO in circumcision specimens (Table 3).²³⁻²⁹

RESULTS

For each case of phimosis it costs between \$3009 and \$3241 to use circumcision as the primary treatment modality. Preputial plasty costs between \$2515 and \$2579 per case. Using topical therapy as the initial therapy costs between \$758 and \$800, a 75% savings compared with circumcision.

Topical therapy would need to exhibit a 93% failure rate to be as costly as initially relying on circumcision. A failure rate of 20% to 24% for preputial plasty would make that option as costly as circumcision. In those treated initially with topical therapy, treatment failure accounted for more of the costs than their initial therapy (Fig 1).

These calculations demonstrate that topical therapy is the most cost-efficient initial therapy for phimosis.

DISCUSSION

The definition of phimosis has never been precise and has been applied to foreskins which do not retract,³⁰ have adhesions to the glans,³¹ have a "tightness,"³² are elongated,¹⁸ are "redundant,"³³ are thickened,³⁴ are inflamed,³⁵ have a fibrous ring,¹⁵ or have a narrow orifice.³⁶ In the United States physicians are encouraged to list "redundant prepuce and phimosis" as the indication for elective circumcisions on normal foreskins to receive third-party payment.³⁷ Unfortunately, the term phimosis is often incorrectly

TABLE 1. Assumptions Used to Calculate the Cost-efficiency of Treating Phimosis

	Circumcision	Preputial Plasty	Topical Steroids	Meatotomy
Cost per procedure	\$2000	\$2000	\$120	\$1000
Failure rate		4% ¹⁹	18%	
Overnight hospital stay	6–20% ¹⁹	2.4–8% ¹⁹		
Reoperation rate	3–6% ¹⁹			
Meatal stenosis rate	2.8 ²¹ –8% ²⁰			
Time lost from work (days)	9.215 ¹⁹	3.85 ¹⁹	1	2

applied to any foreskin that cannot be retracted,³⁸ which includes 96% of newborns, 85% of 3 month olds, 50% of 1 year olds,³⁹ and 1% of 17 year olds.⁴⁰

The reported incidence of phimosis varies. In a population of military dependents receiving post-neonatal circumcisions, the incidence of true phimosis was between 0.2 and 0.3%.⁴¹ Krueger and Osborn⁴² found phimosis in 3 of 28 boys (10.7%) more than the age of 4, Herzog and Alvarez⁴³ saw symptomatic phimosis in 8 of 272 intact boys (2.94%) they studied, and following a cohort of 1265 children in Christchurch, New Zealand, Fergusson et al⁴⁴ found that 16% of noncircumcised boys aged 0 to 8 had phimosis. Whether these authors could distinguish between pathologic and physiologic phimosis through retrospective chart reconstructions is debatable. How many of these boys required intervention is likewise unknown.

Prospective studies have demonstrated phimosis to be a rare finding. Smith et al⁴⁵ found 1 case of phimosis in 1000 boys. In 213 Japanese boys under age 2 years, only 4 (1.88%) had a “pinhole prepuce.”⁴⁶ In France the rate is 2.6%,⁴⁷ whereas in England, the incidence of true pathologic phimosis was calculated to be 0.9%.⁴⁸

Øster,⁴⁰ who examined nearly 2000 schoolchildren between the ages of 6 and 17, found that 91% of the 6- to 7-year-old age group had retractile prepuces and the incidence of spontaneously retractile foreskins increased yearly until age 17 years when only 1% of the foreskins remained nonretractile. The incidence of a completely retractile prepuce in a study of 603 Japanese boys showed a gradual increase from 0% at age 6 months to 62.9% by 11 to 15 years, while the incidence of a tight preputial ring decreased with age from 84.3% to 8.6%.⁴⁶ One large study failed to find a case of pathologic phimosis in a boy under 5 years of age.⁴⁹

Without clear diagnostic criteria, confusion exists about what constitutes pathologic phimosis as distinct from a physiologic nonretractile foreskin.³⁸ The majority of referrals to pediatric urologists for circumcision constitute developmentally nonretractile foreskin rather than true phimosis.^{49–51}

When applying gentle retraction to the normal but nonretractable infant foreskin the distal part of the foreskin puckers and the narrow portion is proximal to the preputial tip. When the same gentle retraction is applied to the foreskin with true phimosis it results in a cone-shaped foreskin with a fibrotic, circular band forming the most distal and narrowest part of the prepuce.⁹

Topical therapy has resulted in consistently favorable results (Table 2), a finding that has prompted the Australasian Association of Paediatric Surgeons⁵² to recommend circumcision only for BXO, recurrent balanoposthitis, and phimosis resistant to topical steroid cream. All three placebo-controlled studies have demonstrated topical therapy’s superiority (Table 4).^{5,7,8} The antiinflammatory and immunosuppressive effects as well as the skin thinning effects of the topical steroids may explain their effectiveness.⁹ Betamethasone has been the most studied cream, with

TABLE 3. Incidence of Balanitis Xerotica Obliterans in Circumcision Specimens

Study	Number of Specimens	Number With Balanitis Xerotica Obliterans	%
Clemmensen ²³	78	15	19.2
Meuli ²⁴	100	10	10.0
Kristiansen ²⁵	59	9	15.3
Bale ²⁶	232	44	19.0
Flentje ²⁷	140	6	4.3
Chalmers ²⁸	100	14	14.0
Liatsikos ²⁹	75	8	10.7
Total	709	98	13.8

TABLE 2. Studies Using Topical Creams to Treat Phimosis

Author	Therapy Used	Number of Patients	Number Responding	%
Wright ¹	Betamethasone 0.5% three times a day	139	111	80
Kikiros ²	Hydrocortisone 1% and 2%, betamethasone 0.05% twice a day four times a day	63	51	81
Jorgensen ³	Clobetasol 0.05% once daily	54	38	70
Lange ⁴	HCG injection, corticoid cream	56	53	95
Golubovic ⁵	Betamethasone 0.05% twice a day	20	19	95
Müller ⁶	Estrogen 0.1% twice a day	30	27	90
Linghagen ⁷	Clobetasol 0.05% once daily	27	24	89
Atilla ⁸	Diclofenac three times a day	32	24	75
Dewan ⁹	Hydrocortisone 1% three times a day*	20	13	65
Ruud ¹⁰	Potent steroid ointment†	41	35	85
Total		482	395	82

* Those who did not respond to 1% hydrocortisone cream were subsequently successfully treated with 0.05% betamethasone cream.

† Twelve of the patients who initially responded relapsed.

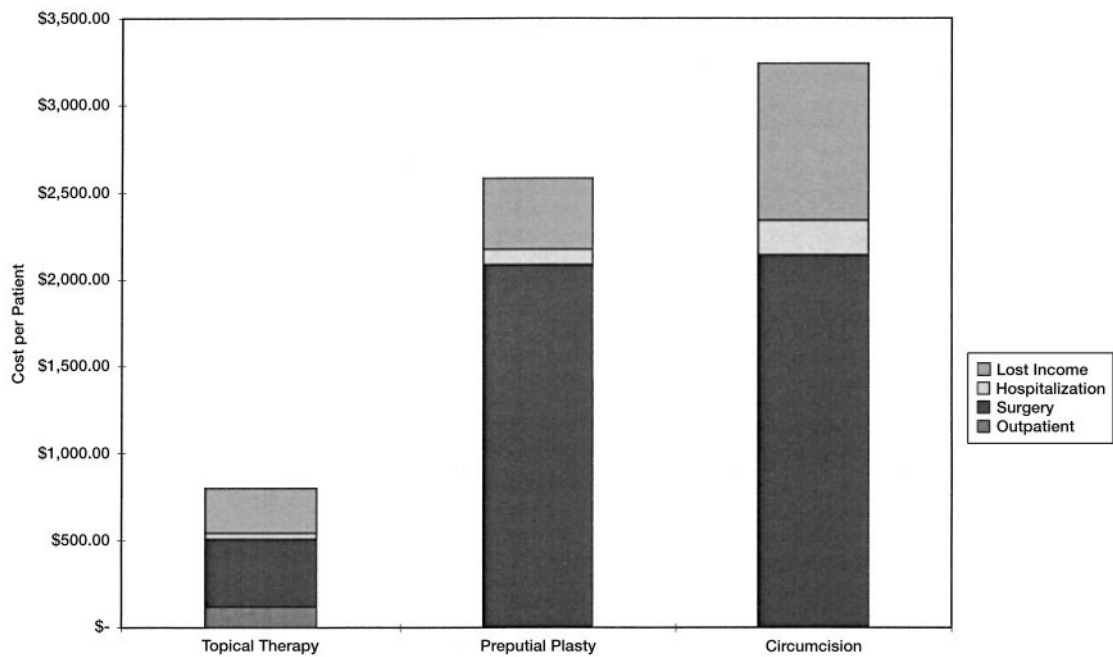


Fig 1. Costs of treating phimosis.

TABLE 4. Placebo-controlled Studies of Topical Therapy for Phimosis Response to Therapy

Study	Medication		Placebo		Odds Ratio	95% Confidence Interval
	Yes	No	Yes	No		
Atilla ⁸	24	8	3	17	17.00	3.93–73.58
Lindhagen ⁷	10	3	7	7	3.33	0.63–17.56
Golubovic ⁵	19	1	4	16	76.00	5.27–30.23
Total	53	12	14	40	12.62	5.27–30.23

external application giving similar results to mucosal application.

Although the studies using topical creams have produced dramatic results, the boys studied were often younger than 5 years old. How many of these boys merely had a normal, nonretractile prepuce is unknown. Topical therapy may have only accelerated the normal developmental process in these boys. Still, these boys would have been considered candidates for circumcision if topical therapy had not been offered. Lindhagen⁷ noted that placebo responders were 2.4 years older than placebo nonresponders, “reinforcing the opinion that this is a physiological process with increasing potential for spontaneous resolution with increasing age.”

The failure rate of topical creams (19%) is nearly identical with the rate of BXO (14%) found on histologic examination of prepuces excised from patients with phimosis.^{23–29} Of the boys who failed after a complete course of topical therapy, 14 had a histologic examination performed. BXO was diagnosed in 12 (86%) of them.^{1,3,7} Although topical steroids are recommended for early BXO,⁵³ their use may act as a screening tool to identify those with more advanced BXO. With the development of effective topical therapy and preputial plasty, the indication for circumcision in the treatment of phimosis has been reduced to the rare cases of BXO.

Meatal stenosis requiring meatotomy after circumcision is seen in 2.8%²¹ to 11.1%²² of patients. Persad et al²⁰ found that after 88 circumcisions for phimosis, 7 (8%) boys developed meatal stenosis, whereas none of the 91 boys who underwent preputial plasty did ($P < .01$). Traumatic meatitis of the unprotected post-circumcision urethral meatus and/or meatal ischemia after damage to the frenular artery at circumcision have been cited as possible etiologic factors.

Of two similar groups of 50 boys, one underwent circumcision and the other underwent preputial plasty in a recent British study.¹⁹ Of the boys who underwent circumcision, 20% required an overnight stay, 14% had anesthetic complications, and 6% required reoperation because of bleeding. Only 8% of patients had an overnight stay after preputial plasty. None of these patients required reoperation and no bleeding problems were noted. Parental assessment of both operations showed that morbidity was significantly less and of shorter duration for the preputial plasty group. Two patients in the preputial plasty group (4%) had recurrent narrowing of the foreskin caused by scarring and contraction of the incision. The acceptance of preputial plasty as an alternative to circumcision may not occur immediately, despite reductions in cost, morbidity, and the amount of tissue excised, because most surgeon will need to be convinced of the need for change.⁵⁴

Several noneconomic factors deserve consideration. The ridged band at the tip of the prepuce may be the most neurologically complex portion of the penis.⁵⁵ Topical therapy and preputial plasty both spare this highly erogenous tissue. Likewise, severe emotional problems have been documented after circumcision in young boys.⁵⁶ The vast majority of males with a prepuce are not eager to part with it, and these newly developed therapies provide reasonable alternatives.

Lindhagen⁷ states, “contrary to epidemiological

data that showed spontaneous resolution of most cases of phimosis, circumcision has become the first line of treatment for these patients. The argument that circumcision is a minor surgical procedure without complications is not only erroneous, but also irrelevant. It is ethically as well as economically questionable to operate on a child to treat a physiological process."

ACKNOWLEDGMENT

I thank Christopher J. Cold, MD, for his invaluable assistance in explaining the pathology of BXO.

REFERENCES

- Wright JE. The treatment of childhood phimosis with topical steroid. *Aust N Z J Surg*. 1994;64:327-328
- Kikiros CS, Beasley SW, Woodward AA. The response of phimosis to local steroid application. *Pediatr Surg Int*. 1993;8:329-332
- Jorgensen ET, Svensson A. The treatment of phimosis in boys, with a potent topical steroid (clobetasol propionate 0.05%) cream. *Acta Derm Venereol (Stockh)*. 1993;73:55-56
- Lang K. Eine konservative Therapie der phimose. *Monatsschr Kinderheilkd*. 1986;134:824-825
- Golubovic Z, Milanovic D, Vukadinovic V, Rakic I, Perovic S. The conservative treatment of phimosis in boys. *Br J Urol* 1996;78:786-788
- Müller I, Müller H. Eine neue konservative Therapie der phimose. *Monatsschr Kinderheilkd*. 1993;141:607-608
- Lindhagen T. Topical clobetasol propionate compared with placebo in the treatment of unretractable foreskin. *Eur J Surg*. 1996;162:969-972
- Atila MK, Dündaröz R, Odabas O, Öztürk H, Akin R, Gökçay E. A non-surgical approach to the treatment of phimosis: local nonsteroidal anti-inflammatory ointment application. *J Urol*. 1997;158:196-197
- Dewan PA, Tieu HC, Chieng BS. Phimosis: is circumcision necessary? *J Paediatr Child Health*. 1996;32:285-289
- Ruud E, Holt J. Fimose kan behandles med lokale steroider. *Tidsskr Nor Lægeforen*. 1997;117:513-514
- Wahlin N. "Triple incision plasty". A convenient procedure for preputial relief. *Scand J Urol Nephrol*. 1992;26:107-110
- Hoffman S, Metz P, Ebbehøj J. A new operation for phimosis: prepuce-saving technique with multiple Y-V-plasties. *Br J Urol*. 1984;56:319-321
- Emmett AJ. Four V-flap repair of preputial stenosis (phimosis). *Plast Reconstr Surg*. 1975;55:687-689
- de Castella H. Prepuceplasty: an alternative to circumcision. *Ann R Coll Surg Engl*. 1994;76:257-258
- Holmlund DE. Dorsal incision of the prepuce and skin closure with Dexon in patients with phimosis. *Scand J Urol Nephrol*. 1973;7:97-99
- Diaz A, Kantor HI. Dorsal slit. A circumcision alternative. *Obstet Gynecol*. 1971;37:619-622
- Parkash S. Phimosis and its plastic correction. *J Indian Med Assoc*. 1972;58:389-390
- Ohjimi H, Ogata K, Ohjimi T. A new method for the relief of adult phimosis. *J Urol*. 1995;153:1607-1609
- Cuckow PM, Rix G, Mouriquand PD. Preputial plasty: a good alternative to circumcision. *J Pediatr Surg*. 1994;29:561-563
- Persad R, Sharma S, McTavish J, Imber C, Mouriquand PD. Clinical presentation and pathophysiology of meatal stenosis following circumcision. *Br J Urol*. 1995;75:91-93
- Griffiths DM, Atwell JD, Freeman NV. A prospective survey of the indications and morbidity of circumcision in children. *Eur Urol*. 1985; 11:184-187
- Stenram A, Malmfors G, Okmian L. Circumcision for phimosis—indications and results. *Acta Paediatr Scand*. 1986;75:321-323
- Clemmensen OJ, Krogh J, Petri M. The histologic spectrum of prepuces from patients with phimosis. *Am J Dermatopathol*. 1988;10:104-108
- Meuli M, Briner J, Hanimann B, Sacher P. Lichen sclerosus et atrophicus causing phimosis in boys: a prospective study with 5-year followup after complete circumcision. *J Urol*. 1994;152:987-989
- Kristiansen VB, Sorensen C, Kryger AI, Nielsen JB, Mejdahl S. Genital lichen sclerosus et atrophicus hos drenge. *Ugeskr Laeger*. 1989;151:1111
- Bale PM, Lochhead A, Martin HC, Gollow I. Balanitis xerotica obliterans in children. *Pediatr Pathol*. 1987;7:617-627
- Flentje D, Benz G, Daum R. Lichen sclerosus et atrophicus als Ursache der erworbenen Phimose—Zirkumzision als Präventivmassnahme gegen das Peniskarzinom? *Z Kinderchir*. 1987;42:308-311
- Chalmers RJ, Burton PA, Bennett RF, Goring CC, Smith PJ. Lichen sclerosus et atrophicus. A common and distinctive cause of phimosis in boys. *Arch Dermatol*. 1984;120:1025-1027
- Liatsikos EN, Perimenis P, Dandinis K, Kaladelfou E, Barbalias G. Lichen sclerosus et atrophicus. Findings after complete circumcision. *Scand J Urol Nephrol*. 1997;31:453-456
- Kaufman JJ. *Current Urologic Therapy*. Philadelphia, PA: WB Saunders Co; 1980
- Blandy J. *Urology, II*. Oxford, England: Blackwell Scientific Publications; 1976
- Brueschke EE, editor. *The World Book Medical Encyclopedia*. Chicago, IL: World Book, Inc; 1988
- Eastman NJ. *Williams Obstetrics*. New York, NY: Appleton-Century-Crofts, Inc; 1956
- M'Kaig A. A remarkable case of phimosis. *Edinburgh Med J*. 1909;2: 252-253
- Hunter J. *A Treatise on the Venereal Disease*. Philadelphia, PA: J Webster; 1818
- Otis FN. Reflex hemiplegia and paralysis of the bladder from congenital phymosis in children. *Am J Obstet*. 1874;7:478
- Reimbursement adviser: how to get reimbursed for circumcision. *OBG Management* 1993(Oct);25
- Gordon A, Collin J. Save the normal foreskin. *Br Med J*. 1993;306:1-2
- Gairdner D. The fate of the foreskin: a study of circumcision. *Br Med J*. 1949;2:1433-1437
- Øster J. Further fate of the foreskin. Incidence of preputial adhesions, phimosis, and smegma among Danish schoolboys. *Arch Dis Child*. 1968; 43:200-203
- Wiswell TE, Tencer HL, Welch CA, Chamberlain JL. Circumcision in children beyond the neonatal period. *Pediatrics*. 1993;92:791-793
- Krueger H, Osborn L. Effects of hygiene among the uncircumcised. *J Fam Pract*. 1986;22:353-355
- Herzog LW, Alvarez SR. The frequency of foreskin problems in uncircumcised children. *Am J Dis Child*. 1986;140:254-256
- Fergusson DM, Lawton JM, Shannon FT. Neonatal circumcision and penile problems: an 8-year longitudinal study. *Pediatrics*. 1988;81: 537-541
- Smith GC, Powell A, Reynolds K, Campbell CA. The five year school medical—time for change. *Arch Dis Child*. 1990;65:225-227
- Kayaba H, Tamura H, Kitajima S, Fujiwara Y, Kato T, Kato T. Analysis of shape and retractability of the prepuce in 603 Japanese boys. *J Urol*. 1996;156:1813-1815
- Branger B, Sable A, Picherot G, et al. Examen du prépuce chez 511 enfants en maternelle. Rôle des manoeuvres de décalottage. *Ann Pediatr (Paris)* 1991;38:618-622
- Rickwood AM, Hemalatha V, Batcup G, Spitz L. Phimosis in boys. *Br J Urol*. 1980;52:147-150
- Rickwood AM, Walker J. Is phimosis overdiagnosed in boys and are too many circumcisions performed in consequence? *Ann R Coll Surg Engl*. 1989;71:275-277
- Griffiths D, Frank JD. Inappropriate circumcision referrals by Gps. *J R Soc Med*. 1992;85:324-325
- Matsuoka H, Kajiwara I, Tahara H, Oshima K. Phimosis as a pathogenetic factor in urinary tract infection and vesicoureteral reflux. *Nippon Hinyokika Gakkai Zasshi*. 1994;85:953-957
- Australasian Association of Paediatric Surgeons. *Guidelines for Circumcision*. Herson, Queensland, Australia: Australasian Association of Paediatric Surgeons; April 1996
- Fortier Beaulieu M, Thominé E, Mitrofanof P, Lauret P, Hemet J. Lichen scléro-atrophique préputial de l'enfant. *Ann Pediatr (Paris)*. 1990;37: 673-676
- Davenport M. Problems with the penis and prepuce: author's reply. *Br Med J*. 1996;312:1230
- Taylor JR, Lockwood AP, Taylor AJ. The prepuce: specialized mucosa of the penis and its loss to circumcision. *Br J Urol*. 1996;77:291-295
- Cansever G. Psychological effects of circumcision. *Br J Med Psychol*. 1965;38:321-331

Cost-effective Treatment of Phimosi

Robert S. Van Howe

Pediatrics 1998;102:e43

DOI: 10.1542/peds.102.4.e43

Updated Information & Services

including high resolution figures, can be found at:
<http://pediatrics.aappublications.org/content/102/4/e43>

References

This article cites 49 articles, 7 of which you can access for free at:
<http://pediatrics.aappublications.org/content/102/4/e43#BIBL>

Subspecialty Collections

This article, along with others on similar topics, appears in the following collection(s):
Letter from the President
http://www.aappublications.org/cgi/collection/letter_from_the_president

Permissions & Licensing

Information about reproducing this article in parts (figures, tables) or in its entirety can be found online at:
<http://www.aappublications.org/site/misc/Permissions.xhtml>

Reprints

Information about ordering reprints can be found online:
<http://www.aappublications.org/site/misc/reprints.xhtml>

American Academy of Pediatrics

DEDICATED TO THE HEALTH OF ALL CHILDREN®



PEDIATRICS®

OFFICIAL JOURNAL OF THE AMERICAN ACADEMY OF PEDIATRICS

Cost-effective Treatment of Phimosis

Robert S. Van Howe

Pediatrics 1998;102:e43

DOI: 10.1542/peds.102.4.e43

The online version of this article, along with updated information and services, is located on the World Wide Web at:

<http://pediatrics.aappublications.org/content/102/4/e43>

Pediatrics is the official journal of the American Academy of Pediatrics. A monthly publication, it has been published continuously since 1948. Pediatrics is owned, published, and trademarked by the American Academy of Pediatrics, 345 Park Avenue, Itasca, Illinois, 60143. Copyright © 1998 by the American Academy of Pediatrics. All rights reserved. Print ISSN: 1073-0397.

American Academy of Pediatrics

DEDICATED TO THE HEALTH OF ALL CHILDREN®

