

Oseltamivir-Warfarin Interaction in Hypoplastic Left Heart Syndrome: Case Report and Review

Jonathan Wagner, DO^{a,b,c}, Susan M. Abdel-Rahman, PharmD^{b,c}

An 8-year-old boy with hypoplastic left heart syndrome with a previous history of thrombosis within the inferior vena cava receiving stable warfarin dosing for anticoagulation was diagnosed with influenza B. He was subsequently placed on oseltamivir therapy according to the Centers for Disease Control and Prevention clinical practice guidelines. During the hospitalization, his international normalized ratio steadily increased to supratherapeutic levels and returned to baseline after discontinuation of oseltamivir therapy. This case represents a drug-drug interaction that has not been previously reported in children or adolescents. An extensive review of the pharmacokinetic and pharmacodynamic literature did not uncover a definitive etiology for this interaction. However, several undefined aspects in each drug's disposition pathway need further elucidation. Until this interaction is understood, caution is warranted, and close monitoring of the international normalized ratio should be performed in all patients prescribed oseltamivir concomitantly with warfarin.

Oseltamivir, a neuraminidase inhibitor used for the prophylaxis and treatment of influenza, is a well-tolerated agent with a mild side-effect profile and relatively few reported drug-drug interactions.¹⁻³ Oseltamivir is administered as an ethyl ester prodrug, which is converted in the liver by carboxylesterase 1A1 (HCE1) to its active metabolite oseltamivir carboxylate (OC).^{4,5} OC is a direct inhibitor of neuraminidase, thereby blocking replication of the influenza virus within the host cell and subsequent penetration into unaffected mucosal tissues.⁶ Neither the parent drug nor the active metabolite appear to serve as substrates, inducers, or inhibitors of cytochrome P450, although the literature in this regard is limited.⁷ However, a case series in adults suggested an increase in international normalized ratio (INR) and bleeding events when oseltamivir was given concurrently with warfarin.⁸

We report what is, to our knowledge, the first case of a possible oseltamivir-warfarin interaction in children.

PATIENT PRESENTATION

Our patient was an 8-year-old Caucasian boy born with hypoplastic left heart syndrome (severe mitral valve stenosis, aortic valve hypoplasia) status post extracardiac, nonfenestrated Fontan palliation at 3.5 years of age. No medical or family history of coagulopathy was present. His preoperative cardiac catheterization demonstrated an excellent candidacy for Fontan completion, with a mean pulmonary artery pressure of 11 mm Hg and pulmonary vascular resistance of 1.22 indexed Wood units. Angiographically, his pulmonary arteries were well developed without any focal stenosis or hypoplasia. His immediate postoperative period was

abstract

^aSection of Cardiology, and ^bDivision of Clinical Pharmacology, Medical Toxicology and Therapeutic Innovation, Children's Mercy Hospital, Kansas City, Missouri; and ^cDepartment of Pediatrics, University of Missouri-Kansas City School of Medicine, Kansas City, Missouri

Dr Wagner gathered the clinical information, drafted the initial manuscript, and also revised the manuscript; Dr Abdel-Rahman revised the manuscript and created the figure; and both authors approved the final manuscript as submitted.

www.pediatrics.org/cgi/doi/10.1542/peds.2014-2578

DOI: 10.1542/peds.2014-2578

Accepted for publication Feb 2, 2015

Address correspondence to Jonathan Wagner, DO, Children's Mercy Hospital, 2401 Gillham Rd, Kansas City, MO 64108. E-mail: jbwagner@cmh.edu

PEDIATRICS (ISSN Numbers: Print, 0031-4005; Online, 1098-4275).

Copyright © 2015 by the American Academy of Pediatrics

FINANCIAL DISCLOSURE: The authors have indicated they have no financial relationships relevant to this article to disclose.

FUNDING: No external funding.

POTENTIAL CONFLICT OF INTEREST: The authors have indicated they have no potential conflicts of interest to disclose.

unremarkable without evidence of Fontan physiology intolerance (eg, pleural effusions, protein-losing enteropathy). At ~6 years of age, he was noted to have a small, mobile, nonocclusive thrombus in his inferior vena cava on a routine transthoracic echocardiography and was started on warfarin therapy with an INR goal of 1.5 to 2.5. There were no other hemodynamic changes noted at the time, and a thrombophilia laboratory evaluation was negative. His INR values have remained stable and within the target range since the initiation of warfarin. During the previous 12 months he had been maintained on a daily warfarin dose of 3.5 mg (0.17 mg/kg). Other medications included digoxin, captopril, furosemide, and esomeprazole, all of which were unchanged over the past 2 years. The family denied any change in diet (specifically vitamin K-containing foods) in the days preceding his illness.

The patient presented to our emergency department during the winter season with a history of fevers, cough, congestion, and emesis over

48 hours. A rapid influenza test confirmed influenza type B infection. Because of dehydration and lack of adequate oral intake, he was admitted for further management. Given his history of complex congenital heart disease and need for hospitalization, a 5-day course of oral oseltamivir was initiated at 45 mg twice daily as recommended in the Food and Drug Administration product label and Centers for Disease Control and Prevention guidelines. On day 3 of oseltamivir treatment, the patient's INR had increased to 3.33. By day 4 of treatment (day 6 of illness) his INR was 4.78 (Fig 1).

Cardiology was consulted and recommended a decrease in warfarin to 2 mg daily. On day 7 of illness, the patient completed his 5-day course of oseltamivir and was clinically stable for discharge. Outpatient laboratory evaluation post-hospital day 2 (day 9 of illness) revealed an extremely elevated INR of 7.46.

Recommendations were made to hold the warfarin for 2 days after which his INR decreased to 1.91. The patient was subsequently restarted on his original dose of warfarin and

repeated INR values over the past 12 months have been within target (Fig 1).

DISCUSSION

To our knowledge, this is the first reported case of a possible oseltamivir-warfarin interaction in a child with influenza. Although our patient did not experience any bleeding events, he was at high risk of bleeding during his illness, with a more than threefold increase in his INR over baseline. Notably, a small retrospective Korean study in patients stably maintained on warfarin reported that nearly one-half of these patients ($n = 7$ of 15) showed a 2.5-fold increase in INR and 3 experienced bleeding events within 10 days of initiating oseltamivir treatment.⁸ Baseline liver function, influenza serotype, and oseltamivir dosing regimen did not appear to explain the elevations in INR. In contrast, a 2-way crossover study in 20 non-influenza-infected adults revealed no pharmacokinetic or pharmacodynamic effects when oseltamivir was coadministered with warfarin.⁹

Whether the presence of influenza infection is necessary but insufficient to precipitate an oseltamivir-warfarin drug-drug interaction is unclear. Influenza A subtype H1N1 has been reported to induce bleeding (eg, pulmonary hemorrhage) in adults; however, bleeding in this situation may occur as a byproduct of the respiratory injury as opposed to a primary coagulation abnormality.^{10,11} A placebo-controlled trial and a recent systematic review demonstrated that influenza vaccination had no significant impact on INR values or warfarin dosing.^{12,13} The accumulated oseltamivir-warfarin data collectively seem to suggest that there may exist a subpopulation that is genetically susceptible to experiencing this drug-drug interaction. The possible

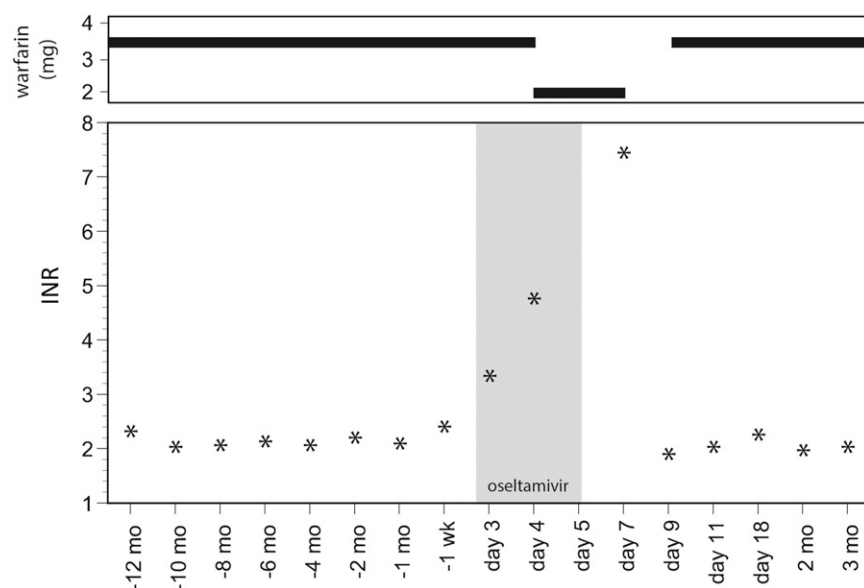


FIGURE 1 Changes in INR values from baseline during oseltamivir treatment course. Top panel, warfarin dosing before, during, and after exposure. Bottom panel, INR values before, during, and after treatment course. The gray shaded rectangle shows the 5-day oseltamivir treatment course.

pharmacokinetic and pharmacodynamic scenarios by which this interaction could occur to increase the INR were examined with specific attention to the full disposition pathway.

From a pharmacokinetic perspective, it is doubtful that oseltamivir enhanced warfarin absorption because warfarin is rapidly and completely absorbed and thereby not subject to any further enhancement.¹⁴ It is also unlikely that the modestly protein-bound oseltamivir would increase the free fraction of warfarin by displacing this highly bound drug from circulating proteins.⁶ It remains unknown if oseltamivir could enhance the cellular uptake of warfarin because specific hepatic uptake transporters for warfarin have not been identified.

Last, there is no evidence to suggest that oseltamivir or OC serves as an inhibitor or competitive substrate for cytochrome P450 enzymes (CYPs) 1A2, 2C9, and 3A4, which metabolize warfarin.⁷ However, these data have never been published nor peer-reviewed and are data on file at the manufacturer and needs further elucidation. Thus, many of the pharmacokinetic scenarios appear unlikely based on our systematic evaluation of the disposition pathway of each drug. However, additional investigations of oseltamivir and metabolite interactions with CYPs would aid in making this determination. Interestingly, the previous case series did not include any pharmacogenetic evaluations of the patients described therein.⁸ Sequence variations that alter warfarin disposition (eg, CYP2C9*2 and CYP2C9*3) may disproportionately impair warfarin clearance in the presence of oseltamivir.¹⁵

Pharmacodynamically, it is not expected that oseltamivir decreases the absorption of vitamin K₁ because it does not alter serum vitamin K₁ concentrations in patients receiving

stable warfarin dosing.⁹ Currently, there are no published studies describing the pharmacodynamic impact of oseltamivir on intestinal microflora and whether this antiviral could decrease bacterial production of vitamin K₂. Hepatic uptake of vitamin K occurs via the apolipoprotein E receptor,¹⁶ but there is a paucity of published studies evaluating the interaction between oseltamivir and apolipoprotein E receptor. To prevent vitamin K clearance, an interaction would have to occur between oseltamivir, or its metabolites, and vitamin K epoxide reductase complex subunit 1 (VKORC1), γ glutamyl-carboxylase (GGCX), or CYP4F2, for which there are no data. It has also not been identified whether oseltamivir affects the consumption of clotting factors.

Because the data available to date suggest that the pharmacokinetic scenarios presented above may be less likely to contribute to an interaction than the pharmacodynamic scenarios, additional investigations should be directed toward an examination of oseltamivir's impact on vitamin K disposition. The pharmacogenomic impact of altered vitamin K activation has been heavily investigated in altered warfarin dosing.^{17,18} For instance, variations in CYP2C9 (*2, *3) and vitamin K epoxide reductase complex (VKORC) are significantly associated with warfarin sensitivity.¹⁸ Although we did not examine CYP2C9 and VKORC genotype in our patient, he was stable at a weight-normalized dose near the expected mean for age to maintain a targeted INR of 2 to 3 since the start of warfarin therapy.¹⁹ Nonetheless, selected sequence variations in VKORC may alter an individual's susceptibility to an interaction.

Whether observations of an elevated INR in the current and previous report reflect a drug-drug or drug-disease interaction remains

uncertain.⁸ Further analysis is warranted in this cohort of patients using collaborative databases involving pediatric cardiology therapeutics to explore the prevalence and impact of this interaction. Nonetheless, there is clear evidence for an interaction of some sort, which merits additional exploration. Targeted oseltamivir and OC interactions with selected CYPs of varying pharmacogenetic constitution would likely be of highest yield. Until this interaction is understood, caution is warranted, and close monitoring of the INR and consultation with anticoagulation specialists should be performed in all patients prescribed oseltamivir concomitantly with warfarin.

REFERENCES

1. Hayden FG, Atmar RL, Schilling M, et al. Use of the selective oral neuraminidase inhibitor oseltamivir to prevent influenza. *N Engl J Med*. 1999;341(18):1336–1343
2. Hayden FG, Treanor JJ, Fritz RS, et al. Use of the oral neuraminidase inhibitor oseltamivir in experimental human influenza: randomized controlled trials for prevention and treatment. *JAMA*. 1999;282(13):1240–1246
3. Kimberlin DW, Acosta EP, Prichard MN, et al; National Institute of Allergy and Infectious Diseases Collaborative Antiviral Study Group. Oseltamivir pharmacokinetics, dosing, and resistance among children aged <2 years with influenza. *J Infect Dis*. 2013; 207(5):709–720
4. Shi D, Yang J, Yang D, et al. Anti-influenza prodrug oseltamivir is activated by carboxylesterase human carboxylesterase 1, and the activation is inhibited by antiplatelet agent clopidogrel. *J Pharmacol Exp Ther*. 2006; 319(3):1477–1484
5. Hoffmann G, Funk C, Fowler S, et al. Nonclinical pharmacokinetics of oseltamivir and oseltamivir carboxylate in the central nervous system. *Antimicrob Agents Chemother*. 2009; 53(11):4753–4761
6. He G, Massarella J, Ward P. Clinical pharmacokinetics of the prodrug

- oseltamivir and its active metabolite Ro 64-0802. *Clin Pharmacokinet.* 1999;37(6): 471–484
7. Wiltshire H. An investigation of the potential inhibitory effect of Ro 64-0796 and Ro 64-0802 on the metabolism of cytochrome P450 model substrates. Research Report W-142919. (Data on file). 1998
 8. Lee SH, Kang HR, Jung JW, et al. Effect of oseltamivir on bleeding risk associated with warfarin therapy: a retrospective review. *Clin Drug Investig.* 2012;32(2):131–137
 9. Davies BE, Aceves Baldó P, Lennon-Chrimes S, Brewster M. Effect of oseltamivir treatment on anticoagulation: a cross-over study in warfarinized patients. *Br J Clin Pharmacol.* 2010;70(6):834–843
 10. Gilbert CR, Vipul K, Baram M. Novel H1N1 influenza A viral infection complicated by alveolar hemorrhage. *Respir Care.* 2010; 55(5):623–625
 11. Yokoyama T, Tsushima K, Ushiki A, et al. Acute lung injury with alveolar hemorrhage due to a novel swine-origin influenza A (H1N1) virus. *Intern Med.* 2010;49(5):427–430
 12. Iorio A, Basileo M, Marcucci M, et al. Influenza vaccination and vitamin K antagonist treatment: a placebo-controlled, randomized, double-blind crossover study. *Arch Intern Med.* 2010; 170(7):609–616
 13. Kuo AM, Brown JN, Clinard V. Effect of influenza vaccination on international normalized ratio during chronic warfarin therapy. *J Clin Pharm Ther.* 2012;37(5):505–509
 14. O'Reilly RA. Vitamin K and the oral anticoagulant drugs. *Annu Rev Med.* 1976;27:245–261
 15. Lee CR, Goldstein JA, Pieper JA. Cytochrome P450 2C9 polymorphisms: a comprehensive review of the in-vitro and human data. *Pharmacogenetics.* 2002;12(3):251–263
 16. Lamon-Fava S, Sadowski JA, Davidson KW, O'Brien ME, McNamara JR, Schaefer EJ. Plasma lipoproteins as carriers of phylloquinone (vitamin K1) in humans. *Am J Clin Nutr.* 1998;67(6):1226–1231
 17. Wadelius M, Chen LY, Downes K, et al. Common VKORC1 and GGCC polymorphisms associated with warfarin dose. *Pharmacogenomics J.* 2005;5(4):262–270
 18. Johnson JA, Gong L, Whirl-Carrillo M, et al; Clinical Pharmacogenetics Implementation Consortium. Clinical Pharmacogenetics Implementation Consortium Guidelines for CYP2C9 and VKORC1 genotypes and warfarin dosing. *Clin Pharmacol Ther.* 2011;90(4):625–629
 19. Andrew M, Marzinotto V, Brooker LA, et al. Oral anticoagulation therapy in pediatric patients: a prospective study. *Thromb Haemost.* 1994;71(3):265–269

Oseltamivir-Warfarin Interaction in Hypoplastic Left Heart Syndrome: Case Report and Review

Jonathan Wagner and Susan M. Abdel-Rahman
Pediatrics originally published online April 27, 2015;

Updated Information & Services

including high resolution figures, can be found at:
<http://pediatrics.aappublications.org/content/early/2015/04/21/peds.2014-2578>

Permissions & Licensing

Information about reproducing this article in parts (figures, tables) or in its entirety can be found online at:
<http://www.aappublications.org/site/misc/Permissions.xhtml>

Reprints

Information about ordering reprints can be found online:
<http://www.aappublications.org/site/misc/reprints.xhtml>

American Academy of Pediatrics

DEDICATED TO THE HEALTH OF ALL CHILDREN™



PEDIATRICS®

OFFICIAL JOURNAL OF THE AMERICAN ACADEMY OF PEDIATRICS

Oseltamivir-Warfarin Interaction in Hypoplastic Left Heart Syndrome: Case Report and Review

Jonathan Wagner and Susan M. Abdel-Rahman
Pediatrics originally published online April 27, 2015;

The online version of this article, along with updated information and services, is located on the World Wide Web at:

<http://pediatrics.aappublications.org/content/early/2015/04/21/peds.2014-2578>

Pediatrics is the official journal of the American Academy of Pediatrics. A monthly publication, it has been published continuously since 1948. Pediatrics is owned, published, and trademarked by the American Academy of Pediatrics, 141 Northwest Point Boulevard, Elk Grove Village, Illinois, 60007. Copyright © 2015 by the American Academy of Pediatrics. All rights reserved. Print ISSN: 1073-0397.

American Academy of Pediatrics

DEDICATED TO THE HEALTH OF ALL CHILDREN™

