Immediate Treatment Versus Sonographic Surveillance for Mild Hip Dysplasia in Newborns

AUTHORS: Karen Rosendahl, MD, PhD,[a,b] Carol Dezateux, FMedSci,[c] Kari Røine Fosse, MD,[d] Hildegunn Aase, MD,[d] Stein Magnus Aukland, MD,[d] Hallvard Reigstad, MD,[e] Terje Alsaker, MD,[e] Dag Moster, MD, PhD,[e] Rolv Terje Lie, PhD,[f] and Trond Markestad, MD, PhD[e]

[a]Diagnostic Radiology, Great Ormond Street Hospital for Children, London, United Kingdom; [b]Institute of Surgical Sciences and [f]Department of Public Health and Primary Health Care, University of Bergen, Bergen, Norway; [c]MRC Centre of Epidemiology for Child Health, UCL Institute of Child Health, London, United Kingdom; and Departments of [d]Radiology and [e]Pediatrics, Haukeland University Hospital, Bergen, Norway

KEY WORDS
randomized, controlled trial, hip dislocation, congenital, therapy

ABBREVIATIONS
AI—acetabular index
AVN—avascular necrosis
DDH—developmental dysplasia of the hip

This trial has been registered at www.clinicaltrials.gov (identifier NCT00843258).

www.pediatrics.org/cgi/doi/10.1542/peds.2009-0357

doi:10.1542/peds.2009-0357

Accepted for publication Jul 30, 2009

Address correspondence to Karen Rosendahl, MD, PhD, Great Ormond Street Hospital for Children, Diagnostic Radiology, Great Ormond Street, London WC1N 3JH, United Kingdom. E-mail: rosenk@gosh.nhs.uk

PEDIATRICS (ISSN Numbers: Print, 0031-4005; Online, 1098-4275).

Copyright © 2009 by the American Academy of Pediatrics

FINANCIAL DISCLOSURE: *The authors have indicated they have no financial relationships relevant to this article to disclose.*

WHAT'S KNOWN ON THIS SUBJECT: Recent observational and small randomized studies have indicated that active surveillance in stable but mildly dysplastic hips is appropriate in newborns; however, data have been lacking on accurate radiological outcomes.

WHAT THIS STUDY ADDS: We report the long-term outcomes of watchful waiting for mild hip dysplasia.

abstract

FREE

OBJECTIVE: We conducted a blinded, randomized, controlled trial to examine whether mildly dysplastic but stable or instable hips would benefit from early treatment, as compared with watchful waiting.

PATIENTS AND METHODS: A total of 128 newborns with mild hip dysplasia (sonographic inclination angle [α angle] of 43°–49°) and stable or instable but not dislocatable hips were randomly assigned to receive either 6 weeks of abduction treatment (immediate-treatment group) or follow-up alone (active-sonographic-surveillance group). The main outcome measurement was the acetabular inclination angle, measured by radiograph, at 1 year of age.

RESULTS: Both groups included 64 newborns, and there was no loss to follow-up. With the exception of a small but statistically significant excess of girls in the active-sonographic-surveillance group, there were no statistically significant differences in baseline characteristics between the 2 groups. The mean inclination angle at 12 months was 24.2° for both groups (difference: 0.1 [95% confidence interval (CI): −0.8 to 0.9]), and all children had improved and were without treatment. The mean α angle was 59.7° in the treatment group and 57.1° in the active-surveillance group for a difference of 2.6° evaluated after 1.5 and 3 months (95% CI: 1.8 to 3.4; $P < .001$). At 1.5 months of age, the hips had improved in all treated children but not in 5 children under active surveillance ($P = .06$). Among the sonographic-surveillance group, 47% received treatment after the initial surveillance period of 1.5 months.

CONCLUSIONS: Active-sonographic-surveillance halved the number of children requiring treatment, did not increase the duration of treatment, and yielded similar results at 1-year follow-up. Given a reported prevalence of 1.3% for mildly dysplastic but stable hips, a strategy of active surveillance would reduce the overall treatment rate by 0.6%. Our results may have important implications for families as well as for health care costs. *Pediatrics* 2010;125:e9–e16

Downloaded from by guest on February 11, 2016

Developmental dysplasia of the hip (DDH) is the most common musculoskeletal disorder in infancy and varies in severity, ranging from neonatal hip instability with or without associated acetabular dysplasia to irreducible dislocation.[1] In its severe form and even with surgical treatment, DDH results in shortening of the affected leg and early osteoarthritis. Clinical tests for DDH were described by Le Damany and Saiget[2] in 1910, Ortolani[3] in 1937, Marx[4] in 1938, Palmen[5] in 1961, and Barlow[6] in 1962. Although newborn screening programs based on the Ortolani[3] and Barlow[6] tests were introduced in the 1950s and 1960s with early abduction splinting in 2% of patients who tested positive,[7–9] the prevalence of late cases warranting surgery has remained stable, at approximately 1 per 1000.[10–12] Consequently, ultrasound has been introduced as an additional diagnostic test,[13] and ultrasound screening is currently offered to all newborns in Austria and Germany[14,15] and to newborns with selected risk factors in the United Kingdom, Scandinavia, Italy, and France.[16–22] These variations reflect the uncertain evidence base for DDH screening policies, including that for treatment effectiveness, as highlighted in 2 recent systematic reviews.[23,24]

These differences are important, because 5% to 7% of all newborns are treated after universal ultrasound screening, compared to 2% of newborns treated with clinical screening alone.[15,25,26] This increase in abduction splinting treatment is partly due to the initiation of treatment of infants in whom mild, stable hip dysplasia has been identified. Furthermore, abduction splinting is not without risk, with avascular necrosis (AVN) being reported in approximately 2% of those patients being referred before the age of 2 months.[24,27,28] Although the justification for such treatment has been questioned, randomized trials to inform clinical practice have been lacking.[23,24]

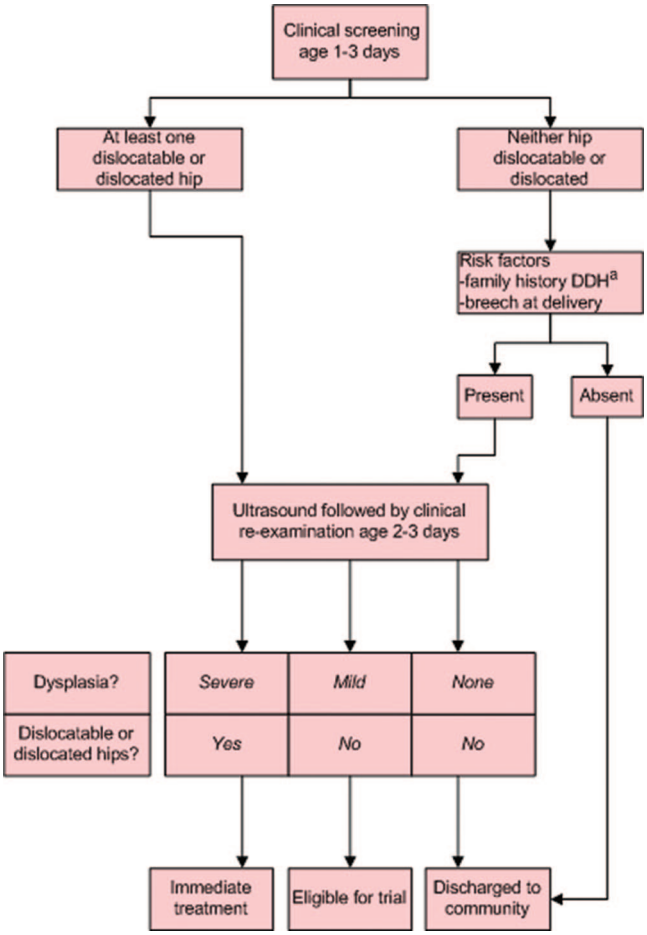

FIGURE 1
Routine management of infants undergoing a neonatal hip screening at Haukeland University Hospital during the trial. [a] Family history in 1 or more first-degree relatives or 2 or more second-degree relatives.

We aimed to determine whether active sonographic surveillance would reduce the likelihood of abduction splinting treatment without increasing the risk of persistent or more severe dysplasia in later infancy.

PATIENTS AND METHODS

Participants

Participants recruited were healthy term newborns born at the maternity unit at Haukeland University Hospital, Bergen, Norway, from February 1998 to April 2003. Infants were eligible if mild dysplasia in 1 or both hips was identified on hip ultrasound. This ultrasound is routinely undertaken at Haukeland University Hospital after either the detection of clinical hip instability or the identification of other risk factors for DDH (breech presentation at delivery, or first- or second-degree family history of DDH) recognized at the newborn screening examination (Fig 1). The current practice is to review infants with mild dysplasia at 6 weeks of age before initiating any treatment. Infants with dislocated, dislocatable, or severely dysplastic hips were excluded from this study because these infants warrant immediate treatment. We also excluded those who weighed <2.5 kg

Downloaded from by guest on February 11, 2016

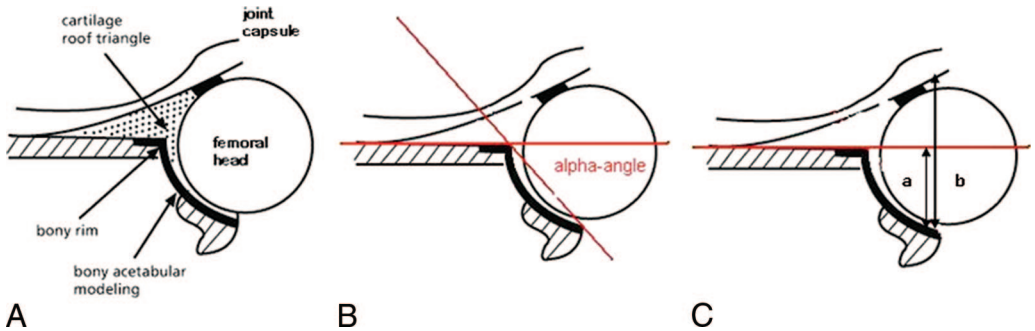

FIGURE 2
Graf's standard coronal section through the deepest part of the acetabulum illustrating key structures (A), the α angle (B), and the femoral head coverage (C).

at birth or with major congenital anomalies.

Newborn screening examinations were undertaken at 1 to 3 days of age by 1 of 8 physicians, who all had at least 2 years' pediatric experience. Each hip was classified as either stable, instable (significant movement of the femoral head but not dislocatable), dislocatable (femoral head moves completely out of the acetabulum during the Barlow maneuver), or dislocated.

Ultrasound examinations were performed the following day at the maternity unit by 1 of 3 senior pediatric radiologists, who used a GE RT200 machine and a linear 5-MHz transducer (General Electric, Munchen, Germany). Hip morphology and stability were assessed separately in each hip by using a modified Graf technique to measure the α angle (Fig 2).[29,30] The α angle is a measure of acetabular depth and was used to classify each hip as either normal ($\alpha \geq 60°$), immature ($50° \leq \alpha < 60°$), mildly dysplastic ($43° \leq \alpha < 50°$), or severely dysplastic ($\alpha < 43°$) (Fig 3). Hip stability was assessed sonographically by performing a maneuver similar to the Barlow test with the infant in a lateral position, and each hip was classified as stable, instable, dislocatable, or dislocated.

Mothers of eligible infants identified at ultrasound in the maternity unit were given written information about the trial by the same senior pediatric radiologist, and written informed consent was obtained according to our institutional guidelines. The study was approved by the Medical Research Ethics Committee of the Western Region of Norway.

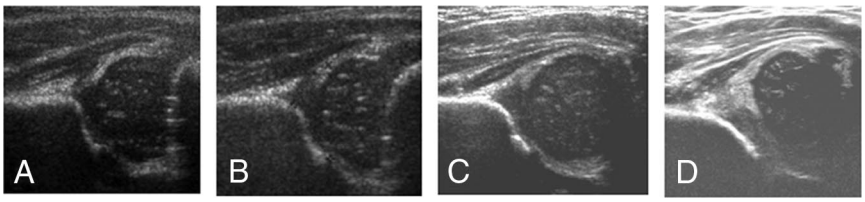

FIGURE 3
Rosendahl's modification of the Graf classification based on the standard coronal section: A, normal, $\alpha \geq 60°$; B, immature, $50° \leq \alpha < 60°$; C, mild dysplasia $43° \leq \alpha < 50°$; D, significant dysplasia, $\alpha < 43°$.

Once recruited, infants were referred to the pediatric outpatient department, where an experienced pediatric radiologist (Dr Rosendahl) performed another ultrasound examination by using a high-resolution ultrasound machine (Acuson XP or ATL HDI 5000, linear 5–10/12 MHz transducer) to confirm sonographic mild dysplasia. A clinical reexamination was undertaken by 1 of 4 senior pediatricians.

Interventions

Infants with persistent mild stable dysplasia were then randomly assigned to receive either immediate abduction splinting treatment for at least 6 weeks using a Frejka pillow splint with sonographic follow-up (immediate-treatment group) or to receive active sonographic surveillance but no treatment before 6 weeks of age (active-sonographic-surveillance group). A statistician (Dr Lie) performed the randomization as 1 single block by using a computerized random-number generator, and group assignments were put in opaque, sealed, and numbered envelopes. With the parent present but the radiologist absent, a senior nurse opened the envelopes in numerical sequence for each infant at the outpatient clinic.

The treatment protocols included a specific plan for discontinuing or initiating abduction treatment after 6 weeks of age as appropriate in each group. Thus, infants allocated to the immediate-treatment group were fitted with a Frejka pillow splint, with review at 2 to 3 weeks of age for fitting and adjustment, and at 6 weeks and 3 months for hip ultrasounds. Treatment was to be discontinued for those pa-

Downloaded from by guest on February 11, 2016

tients with an α angle of >53° at 6 weeks or ≥55° at 3 months. A study coordinator was responsible for managing appointments and following up with nonattendees.

Infants allocated to the active-sonographic-surveillance group were first reviewed at 6 weeks of age and again at 3 months, with hip ultrasounds performed on both occasions. Abduction splinting was not to be started before 6 weeks of age but was to be initiated after 6 weeks for those patients with persistent dysplasia, as indicated by an α angle of <50° at 6 weeks or <55° at 3 months.

The same pediatric radiologist performed the majority (80%) of follow-up ultrasound examinations, and 2 other pediatric radiologists performed the remainder. All treated infants had their abduction splinting device removed before entering the radiology department for imaging. In addition, parents were instructed not to discuss their child's treatment with the radiologists to ensure that the radiologists were blinded to the intervention assigned.

If treatment was to be continued beyond 3 months in either group, the Frejka pillow splint was replaced with a simple, custom-fitted plastic cast that provided better support for the hips. Treatment was only discontinued when the α angle was normal (≥60°), or the acetabular index (AI), assessed by standardized anteroposterior pelvic radiographs at 6 months of age, was within 2 SDs of the reference values for age published by Tönnis and Brunken[31] (<35° at age 4.5 months [mean: 25°], <33° at age 5 to 6 months [mean 24°], and <30° at age 7 to 12 months [mean: 23°]) (Fig 4). Similar to the Frejka pillow splint, the plastic cast was simple to use, and could be removed easily to facilitate diaper changes.

In this trial we tested the hypothesis that acetabular depth at 1 year of age would be greater in infants assigned to immediate treatment than in those assigned to active sonographic surveillance.

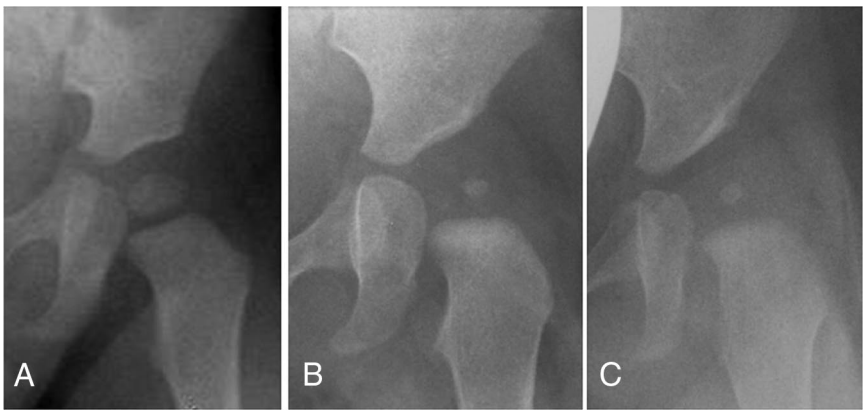

FIGURE 4
On the basis of the AI, the hips were radiographically classified as normal (A), having delayed acetabular ossification (B), or dysplastic (C).

Primary Outcome

The main aim of abduction splinting treatment for DDH is to ensure that the hip is functionally unimpaired at skeletal maturity, specifically through promoting normal acetabular development by ensuring hip stability and concentric location of the femoral head within the acetabulum. Because it was not feasible to specify outcomes at skeletal maturity for this trial and hip function at this age is not a reliable indicator of longer-term hip function, we selected the radiologic appearance of the hip at the end of the first year of life as a primary outcome. Specifically, we used the AI (Fig 4), assessed from anteroposterior pelvic radiographs obtained with the child lying supine, with the thighs parallel and slightly elevated to avoid hip adduction and a pelvic tilt (in the sagittal plane).

All AI measurements were repeated by a fourth experienced radiologist (Dr Aase) who was blinded to the study group and previous findings and had not been involved in ultrasound assessments. On the basis of the AI, the hips were classified as normal (AI within 1 SD), acetabular ossification delay (1 SD < AI < 2 SD), or dysplasia (AI > 2 SD), according to the classification system used by Tönnis and Brunken[31] (Fig 4).

Statistical Analysis

We assumed that a 3° difference in the AI between the 2 groups was clinically important at 1 year of age, which represented approximately 1 normal SD at this age.[10] A sample size of 128 patients would have 80% power to detect a difference significant at the 5% level, and the size was increased to 140 participants in anticipation of a 10% loss to follow-up.

All analyses compared the immediate-treatment and active-sonographic-surveillance groups on an intention-to-treat basis. We used t tests to compare continuous variables at baseline with χ^2 or exact tests when appropriate. Both hips of each child were measured at several time points during the follow-up. In models estimating the difference in mean α angle during the follow-up period between the immediate-treatment group and the active-surveillance group, random effects were used to account for correlations between the right and left hips and between subsequent follow-up observations of the same child. To look for consistency with the overall results, we also performed analyses that included only the initially worse hip

Downloaded from by guest on February 11, 2016

FIGURE 5
Flow of participants through the trial as shown in CONSORT (Consolidated Standards of Reporting Trials) format.

of each child and for each time point during follow-up. All analyses were adjusted for gender. The statistical analyses were performed using the xtmixed program in Stata 9 (Stata Corp LP, College Station, TX). All significance tests were 2 sided.

RESULTS

Patients

Figure 5 summarizes the flow of patients through the trial.[32,33] There was a small but statistically significant excess of girls in the active surveillance group, but with that exception no statistically significant differences in baseline characteristics between the 2 groups (Table 1).

All infants in the immediate-treatment group were treated according to the protocol, and none were lost to follow-up. At 6 weeks of age, treatment was discontinued in 24 infants and continued in 40 participants in whom the α angle was $\leq 53°$. At 3 months of age, treatment was continued for an additional 2 weeks for 5 infants in whom the α angle was $<55°$. At 6 months, treatment was restarted on 5 infants for whom splinting had been discontinued at 6 weeks because pelvic radiographs revealed the presence of dysplasia as defined by an AI of >2 SDs above the mean. All 5 infants had discontinued treatment by 1 year of age.

All infants in the active-sonographic-surveillance group were treated according to the protocol. No infants in this group received abduction splinting treatment before 6 weeks of age, and none were lost to follow-up. With the exception of 1 infant who was reviewed at 8 weeks, all patients were examined at 6 weeks of age. Abduction splinting was initiated for 12 infants in whom the α angle was $<50°$, for an additional 12 infants in whom the α angle was $\leq 55°$ at the 3-month review, and for 1 infant who was seen at 10 weeks. At 6 months, treatment was initiated for the first time in 5 infants in whom the AI was >2 SDs above the mean. All 5 infants had discontinued treatment by 1 year of age.

The median treatment duration was 12 weeks (range: 6–24 weeks) in both the immediate-treatment and active-sonographic-surveillance groups (Fig

TABLE 1 Baseline Characteristics According to Treatment Allocation

Characteristic	Immediate-Treatment Group ($n = 64$)	Active-Surveillance Group ($n = 64$)
Girls, *n* (%)	43 (67)	54 (84)[a]
Birth weight, mean (SD), g	3686 (465)	3758 (529)
Family history of DDH, *n* (%)		
≥1 first- degree relative	23 (36)	23 (36)
≥2 second-degree relative	6 (9)	10 (16)
Breech presentation at delivery	8 (13)	6 (9)
Findings on first clinical examination, *n* (%)		
At least 1 instable hip	18 (28)	14 (22)
Bilateral instable hips	7 (10.9)	7 (10.9)
Hip instability on clinical reexamination, *n* (%)		
At least 1 hip	14 (22)	13 (20)
Both hips	7 (11.5)	9 (14.5)
Sonographic hip instability, *n* (%)		
At least 1 hip	52 (81)	45 (70)
Both hips	31 (48.4)	30 (46.9)
Acetabular morphology		
α angle worse hip, mean (SD), °	47.0 (1.7)	47.0 (1.8)

[a] $P = .04$.

Downloaded from by guest on February 11, 2016

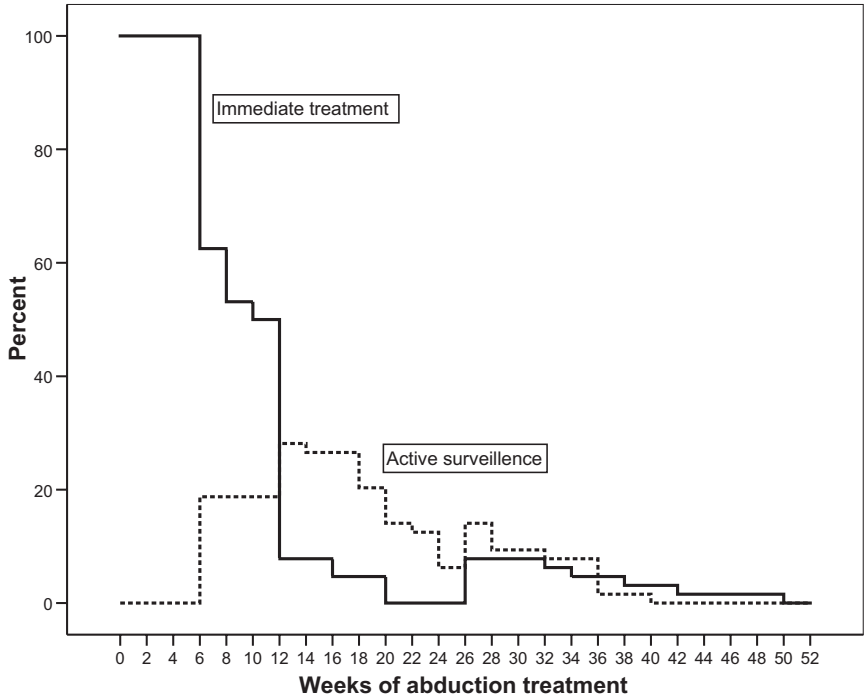

FIGURE 6
The time course of treatment discontinuation and initiation in each of the groups.

TABLE 2 The Effect of Treatment on AI (radiography) and on α Angle (ultrasound) at Various Times of Follow-up

Primary End Point, °	Immediate-Treatment Group ($n = 64$), Mean (SE)[a]	Active-Surveillance Group ($n = 64$), Mean (SE)[a]	Treatment Effect (95% CI)[b]	P[b]
AI, 12 mo	24.2 (0.40)	24.2 (0.40)	0.1 (−0.8 to 0.9)	.82
α angle, 1.5 mo	58.4 (0.48)	55.2 (0.51	3.2 (2.1 to 4.4)	<.001
α angle, 3 mo	61.0 (0.49)	59.0 (0.48)	2.0 (0.9 to 3.1)	<.001
AI, 6 mo	24.2 (0.38)	24.7 (0.42)	−0.4 (−1.3 to 0.4)	.32

[a] Robust estimate accounting for correlated observations of hips of the same child.
[b] Estimated from original measurements by using random-effects models accounting for the correlation of hips from each child. The analyses were adjusted for gender.

6). There were no gender differences in treatment duration. Over the period of follow-up, no complications of treatment were observed, and none of the children developed abnormal clinical findings on hip examination.

At 6 weeks, the mean α angle was 3.2° higher for the infants treated from birth (95% CI: 2.1 to 4.4; $P < .001$) (Table 2). The difference in mean was consistent at 3 months (2.0°, 95% CI: 0.9 to 3.1; $P < .001$). Similar findings were observed when the analysis was restricted to the initially worse hip (data not shown).

At 1 year of age, there were no differences in AI between the 2 groups (Table 2). Overall, 47% (29 infants) in the active-sonographic-surveillance group received treatment compared with 100% in the immediate-treatment group (Fig 6). In the immediate-treatment and active-surveillance groups, 38 and 40 infants had radiologically normal hips at 12 months of age, whereas 19 and 20 had radiologic evidence of delayed ossification, and 7 and 4 had at least 1 dysplastic hip, respectively. None of the participants' hips were subluxated or dislocated.

No differences according to gender were found for either of the measurements performed (data not shown).

DISCUSSION

We have shown that active sonographic surveillance of infants with stable but mildly dysplastic hips can reduce use of abduction splinting treatment without increasing the risk of persistent or more severe dysplasia. Although early splinting led to more rapid and consistent improvement, active surveillance and treatment of those patients who did not improve spontaneously (45.3%) did not increase the proportion of children with delayed acetabular ossification (30%) or persistent dysplasia (8%) at 1 year of age. The duration of treatment was also similar for the 2 groups. To our knowledge, this work is the largest randomized trial to evaluate treatment for mild sonographic dysplasia.[24,34]

The strengths of our study include the robust ultrasound method used, the high level of adherence to protocols, high compliance, and the randomized and blinded design. We have previously shown that the combined static and dynamic ultrasound technique used, with measurement of an acetabular inclination (α) angle from a standardized coronal section, has moderate repeatability.[30] Only a few such studies addressing interexamination as compared to interreader repeatability alone have been published.[30,35–39] Most of those studies addressed techniques using Graf's standard section as a basis for measurements, be it the α angle[30,35,37,38] or the femoral head coverage[36] (Fig 2), whereas studies on hip stability alone have been rare.[39] The α angle is the only marker for acetabular dysplasia for which all measurement points are fixed, favoring this measurement over the femoral head coverage, particularly in the assessment of instable hips.

A slightly higher number of girls in the active-surveillance group is likely to be random, and subsequent analyses were therefore adjusted for

Downloaded from by guest on February 11, 2016

gender, although no differences in either AI or α angles were found between genders at follow-up. Because the parents could not be blinded to the intervention allocation, it is possible that they could have disclosed this information to the staff responsible for taking the outcome radiograph; however, because the reporting radiologist was blinded to allocation and had no direct contact with families, we consider the outcome assessments to be unbiased.

Previous studies have shown that most immature acetabular resolve physiologically during the first weeks of life, and that the acetabular inclination as measured by the α angle reaches a plateau after 2 to 3 months of age.[10,40] Our results are consistent with these observations and also demonstrate that acetabular maturation accelerates if treatment is given during the first 6 weeks of life. Although 5 infants under active surveillance in this study deteriorated from birth to 6 weeks of age, rapid improvement was seen after the treatment was initiated. Interestingly, acetabular maturation was not different for the 2 groups by 12 months of age. Residual immaturity as measured by the AI was, however, demonstrated in more than one third of the patients.[31]

Our results support observations made by Sampath et al[41] in a study that included 35 infants with stable, but mildly dysplastic hips. All but 2 infants improved without treatment and none required surgical intervention (follow-up was not noted). Wood et al[34] used a randomized design to examine the effect of 6 weeks of early treatment in 44 infants (29 girls) with dysplastic but stable hips who presented at the age of 2 to 6 weeks. Although the femoral head coverage as measured by ultrasound increased from an average of 32.8% to 54.3% in the splinted group during the first 3 months compared to 36.7% to 48.6% in the unsplinted group, there was no difference in AI by 3 months and 2 years of age. It is reasonable to believe that a low femoral head coverage of 32% in stable hips corresponds to mild dysplasia as assessed by an α angle of 43° to 50°.[42] Neither of the 2 studies reported details of the final AIs; the researchers reported only that they were within the "normal range" for the children's age.

The threshold for initiating or continuing treatment at 6 weeks of age or later was not clearly justified by any established risks of later dysplasia or dislocation. This result reflected a low threshold for treatment that is generally considered more acceptable in early infancy despite the small risk of AVN, which is typically reported in 2% of treated infants after early referral.[28] Our study lacked power to compare complication rates between the 2 groups. Furthermore, there has been an insufficient duration of follow-up to comment on the risk of AVN, which was not seen in any infant. On the other hand, treatment initiated after 2 months of age is associated with higher rates of AVN, up to 11% according to a recent meta-analysis.[28] It is recognized that abduction splinting immobilizes the infant, impedes daily care, and might, therefore, interfere with the relationship between infants and their carers.[43] Of interest is the fact that watchful waiting resulted in later treatment as well as less treatment, potentially allowing mothers time to care for their infants and establish breastfeeding. Conversely, delaying treatment may limit an increasingly mobile child. We were unable to assess these more qualitative but important outcomes in this trial. However, the decision to treat should take into account the positive and negative effects of treatment from a variety of perspectives.

CONCLUSIONS

Although universal treatment from birth of infants with stable but mildly dysplastic hips may cause more rapid normalization, surveillance and treatment reconsideration at the age of 6 weeks did not result in more abnormal hips at 1 year of age. Given a reported prevalence of 1.3% for mildly dysplastic but stable hips, a strategy of active surveillance would reduce the overall treatment rate by 0.6%. Our results may have important implications for families as well as for health care costs.

REFERENCES

1. Aronsson DD, Goldberg MJ, Kling TF Jr, Roy DR. Developmental dysplasia of the hip. *Pediatrics.* 1994;94:201–208
2. Le Damany P. La luxation congénitale de la hanche. Études d'anatomie comparée d'anthropogenie normale et pathologique, deductions therapeutique. Alcan, Paris 1912
3. Ortolani M. Un segno noto e sua importanza per la diagnosi precoce di prelussazione congenita dell'anca. *Pediatria (Napoli).* 1937;45:129–136
4. Marx VO. New observations in congenital dislocation of the hip in the newborn. *J Bone Joint Surg.* 1938;20:1095
5. Palmén K. Preluxation of the hip joint. Diagnosis and treatment in the newborn and the diagnosis of congenital dislocation of the hip joint in Sweden during the years 1948–1960. *Acta Paediatr Suppl.* 1961;50:1–71
6. Barlow TG. Early diagnosis and treatment of congenital dislocation of the hip. *Proc R Soc Med.* 1962;56:804–806
7. Barlow TG. Congenital dislocation of the hip. *Nurs Mirror Midwives J.* 1968; 126(13):25
8. Catford JC, Bennet GC, Wilkinson JA. Congenital hip dislocation: an increasing and still uncontrolled disability? *Br Med J.* 1982; 285(6354):1527–1530
9. Chan A, Cundy PJ, Foster BK, Keane RJ, Byron-Scott R. Late diagnosis of congenital dislocation of the hip and presence of a screening programme: South Australian

Downloaded from by guest on February 11, 2016

population-based study. *Lancet.* 1999; 354(9189):1514–1517

10. Burger BJ, Burger JD, Bos CF, Obermann WR, Rozing PM, Vandenbroucke JP. Neonatal screening and staggered early treatment for congenital dislocation or dysplasia of the hip. *Lancet.* 1990;336:1549–1553
11. Mitchell GP. Problems in the early diagnosis and management of congenital dislocation of the hip. *J Bone Joint Surg Br.* 1972;54:4–12
12. Hiertonn T, James U. Congenital dislocation of the hip. Experiences of early diagnosis and treatment. *J Bone Joint Surg Br.* 1968; 50:542–545
13. Graf R. The diagnosis of congenital hip-joint dislocation by the ultrasonic Combound treatment. *Arch Orthop Trauma Surg.* 1980; 97:117–133
14. Grill F, Muller D. [Ergebnisse des Huftultraschallscreenings in Osterreich.][in German]. *Orthopade.* 1997;26:25–32
15. von Kries R, Ihme N, Oberle D, et al. Effect of ultrasound screening on the rate of first operative procedures for developmental hip dysplasia in Germany. *Lancet.* 2003;362: 1883–1887
16. Brown J, Dezateux C, Karnon J, Parnaby A, Arthur R. Efficiency of alternative policy options for screening for developmental dysplasia of the hip in the United Kingdom. *Arch Dis Child.* 2003;88:760–766
17. Holen KJ, Tegnander A, Bredland T, et al. Universal or selective screening of the neonatal hip using ultrasound? A prospective, randomised trial of 15,529 newborn infants. *J Bone Joint Surg Br.* 2002;84:886–890
18. Rosendahl K, Markestad T, Lie RT. Ultrasound screening for developmental dysplasia of the hip in the neonate: the effect on treatment rate and prevalence of late cases. *Pediatrics.* 1994;94:47–52
19. Baronciani D, Atti G, Andiloro F, et al. Screening for developmental dysplasia of the hip: from theory to practice. Collaborative Group DDH Project. *Pediatrics.* 1997;99:E5
20. Riboni G, Bellini A, Serantoni S, Rognoni E, Bisanti L. Ultrasound screening for developmental dysplasia of the hip. *Pediatr Radiol.* 2003l;33:475–481
21. Ortore P, Fodor G, Silverio R, Milani C, Psenner K. [Ecografia dell'anca neonatale: stato dell'arte e prospettive.]. *Radiol Med (Torino).* 1996;92:10–15
22. Rosendahl K, Toma P. Ultrasound in the diagnosis of developmental dysplasia of the hip in newborns. The European approach. A review of methods, accuracy and clinical validity. *Eur Radiol.* 2007;17:1960–1967
23. Woolacott NF, Puhan MA, Steurer J, Kleijnen J. Ultrasonography in screening for developmental dysplasia of the hip in newborns: systematic review. *BMJ.* 2005;330:1413
24. Shipman SA, Helfand M, Moyer VA, Yawn BP. Screening for developmental dysplasia of the hip: a systematic literature review for the US Preventive Services Task Force. *Pediatrics.* 2006;117:e557–e576
25. Duppe H, Danielsson LG. Screening of neonatal instability and of developmental dislocation of the hip. A survey of 132,601 living newborn infants between 1956 and 1999. *J Bone Joint Surg Br.* 2002;84:878–885
26. Altenhofen L, Allhoff PG, Niethard FU. [Hip ultrasound screening within the scope of U3–initial experiences][in German]. *Z Orthop Ihre Grenzgeb.* 1998;136:501–507
27. Kalamchi A, MacEwen GD. Avascular necrosis following treatment of congenital dislocation of the hip. *J Bone Joint Surg Am.* 1980;62:876–888
28. Lehmann HP, Hinton R, Morello P, Santoli J. Developmental dysplasia of the hip practice guideline: technical report. Committee on Quality Improvement, and Subcommittee on Developmental Dysplasia of the Hip. *Pediatrics.* 2000;105:E57
29. Rosendahl K, Markestad T, Lie RT. Ultrasound in the early diagnosis of congenital dislocation of the hip: the significance of hip stability versus acetabular morphology. *Pediatr Radiol.* 1992;22:430–433
30. Rosendahl K, Aslaksen A, Lie RT, Markestad T. Reliability of ultrasound in the early diagnosis of developmental dysplasia of the hip. *Pediatr Radiol.* 1995;25:219–224
31. Tonnis D, Brunken D. [Differentiation of normal and pathological acetabular roof angle in the diagnosis of hip dysplasia. Evaluation of 2294 acetabular roof angles of hip joints in children]. *Arch Orthop Unfallchir.* 64: 197–228, 1968
32. Moher D, Schulz KF, Altman DG. The CONSORT statement: revised recommendations for improving the quality of reports of parallel-group randomised trials. *Lancet.* 2001;357: 1191–1194
33. Altman DG, Schulz KF, Moher D, et al. The revised CONSORT statement for reporting randomized trials: explanation and elaboration. *Ann Intern Med.* 2001;134:663–694
34. Wood MK, Conboy V, Benson MK. Does early treatment by abduction splintage improve the development of dysplastic but stable neonatal hips? *J Pediatr Orthop.* 2000;20: 302–305
35. Bar-On E, Meyer S, Harari G, Porat S. Ultrasonography of the hip in developmental hip dysplasia. *J Bone Surg Br.* 1998;80:321–324
36. Holen KJ, Terjesen T, Tegnander A, Bredland T, Saether OD, Eik-Nes SH. Ultrasound screening for hip dysplasia in newborns. *J Pediatr Orthop.* 1994;14:667–673
37. Roovers EA, Boere-Boonekamp MM, Geertsma TS, Zielhuis GA, Kerkhoff AH. Ultrasonographic screening for developmental dysplasia of the hip in infants. *Reproducibility of assessments made by radiographers. J Bone Joint Surg Br.* 2003;85:726–730
38. Zieger M. Ultrasound of the infant hip. Part 2. Validity of the method. *Pediatr Radiol.* 1986;16:488–492
39. Andersson JE. Neonatal hip instability: normal values for physiological movement of the femoral head determined by an anterior-dynamic ultrasound method. *J Pediatr Orthop.* 1995;15:736–740
40. Dunn PM, Evans RE, Thearle MJ, Griffiths HE, Witherow PJ. Congenital dislocation of the hip: early and late diagnosis and management compared. *Arch Dis Child.* 1985;60: 407–414
41. Sampath JS, Deakin S, Paton RW. Splintage in development dysplasia of the hip: how low can we go? *J Pediatr Orthop.* 2003;23: 352–355
42. Falliner A, Schwinzer D, Hahne HJ, Hedderich J, Hassenpflug J. Comparing ultrasound measurements of neonatal hips using the methods of Graf and Terjesen. *J Bone Joint Surg Br.* 2006;88:104–106
43. Gardner F, Dezateux C, Elbourne D, Gray A, King A, Quinn A. The hip trial: psychosocial consequences for mothers of using ultrasound to manage infants with developmental hip dysplasia. *Arch Dis Child Fetal Neonatal Ed.* 2005;90:F17–F24

Downloaded from by guest on February 11, 2016

Immediate Treatment Versus Sonographic Surveillance for Mild Hip Dysplasia in Newborns

Karen Rosendahl, Carol Dezateux, Kari Røine Fosse, Hildegunn Aase, Stein Magnus Aukland, Hallvard Reigstad, Terje Alsaker, Dag Moster, Rolv Terje Lie and Trond Markestad

Pediatrics; originally published online December 21, 2009;
DOI: 10.1542/peds.2009-0357

Updated Information & Services	including high resolution figures, can be found at: /content/early/2009/12/21/peds.2009-0357.citation
Citations	This article has been cited by 7 HighWire-hosted articles: /content/early/2009/12/21/peds.2009-0357.citation#related-urls
Permissions & Licensing	Information about reproducing this article in parts (figures, tables) or in its entirety can be found online at: /site/misc/Permissions.xhtml
Reprints	Information about ordering reprints can be found online: /site/misc/reprints.xhtml

PEDIATRICS is the official journal of the American Academy of Pediatrics. A monthly publication, it has been published continuously since 1948. PEDIATRICS is owned, published, and trademarked by the American Academy of Pediatrics, 141 Northwest Point Boulevard, Elk Grove Village, Illinois, 60007. Copyright © 2009 by the American Academy of Pediatrics. All rights reserved. Print ISSN: 0031-4005. Online ISSN: 1098-4275.

American Academy of Pediatrics
DEDICATED TO THE HEALTH OF ALL CHILDREN™

Downloaded from by guest on February 11, 2016

PEDIATRICS®
OFFICIAL JOURNAL OF THE AMERICAN ACADEMY OF PEDIATRICS

Immediate Treatment Versus Sonographic Surveillance for Mild Hip Dysplasia in Newborns

Karen Rosendahl, Carol Dezateux, Kari Røine Fosse, Hildegunn Aase, Stein Magnus Aukland, Hallvard Reigstad, Terje Alsaker, Dag Moster, Rolv Terje Lie and Trond Markestad

Pediatrics; originally published online December 21, 2009;
DOI: 10.1542/peds.2009-0357

The online version of this article, along with updated information and services, is located on the World Wide Web at:
/content/early/2009/12/21/peds.2009-0357.citation

PEDIATRICS is the official journal of the American Academy of Pediatrics. A monthly publication, it has been published continuously since 1948. PEDIATRICS is owned, published, and trademarked by the American Academy of Pediatrics, 141 Northwest Point Boulevard, Elk Grove Village, Illinois, 60007. Copyright © 2009 by the American Academy of Pediatrics. All rights reserved. Print ISSN: 0031-4005. Online ISSN: 1098-4275.

American Academy of Pediatrics
DEDICATED TO THE HEALTH OF ALL CHILDREN™

Downloaded from by guest on February 11, 2016