

A 33-Month-Old With Fever and Altered Mental Status

Andrew J. Lutz, MD^a, Brian Jenssen, MD^{a,b}, Jennifer McGuire, MD, MSCE^{c,d}, Joseph W. St. Geme III, MD^{a,e,f}

abstract

A 33-month-old girl presented with 3 days of fever and 1 day of multiple paroxysmal episodes of screaming with apparent unresponsiveness, flexed lower extremities, clenched hands, and upward eye deviation. These events lasted seconds to a minute at a time and occurred only during sleep. She slept peacefully between episodes and was easily awakened. She had a history of mild speech delay and mild intermittent asthma but was otherwise healthy. She was tired-appearing and fussy on examination with dry mucous membranes, but her examination was otherwise normal. A complete blood count with differential and serum levels of sodium, potassium, chloride, and calcium were normal, but her bicarbonate level was 12 mmol/L. Her fingerstick glucose level was 69 mg/dL. Urine dipstick was notable for large ketones, and a urine drug screen was normal. Cerebrospinal fluid examination yielded 2 white blood cells and 1040 red blood cells/mm³ with normal chemistries. A computed tomography (CT) scan of her head was unremarkable, and an abdominal ultrasound demonstrated no evidence of intussusception. Over the course of her hospitalization, these paroxysmal episodes persisted, and she subsequently developed mutism, right-sided weakness, and difficulty swallowing liquids. Here we present her case, diagnostic evaluation, and ultimate diagnosis.

Divisions of ^aGeneral Pediatrics, ^cNeurology, and ^fInfectious Disease, The Children's Hospital of Philadelphia, Philadelphia, Pennsylvania; Departments of ^bNeurology and ^ePediatrics, The Perelman School of Medicine at the University of Pennsylvania, Philadelphia, Pennsylvania; and the ^dRobert Wood Johnson Foundation Clinical Scholars Program, University of Pennsylvania, Philadelphia, Pennsylvania

Dr Lutz contributed to the conception and design of this case presentation, drafted the initial manuscript, and revised the manuscript; Drs Jenssen, McGuire, and St. Geme III contributed to the conception and design of this case presentation and reviewed and revised the manuscript; and all authors approved the final manuscript as submitted.

www.pediatrics.org/cgi/doi/10.1542/peds.2014-2405

DOI: 10.1542/peds.2014-2405

Accepted for publication Sep 8, 2014

Address correspondence to Andrew J. Lutz, MD, The Children's Hospital of Philadelphia, 34th St and Civic Center Blvd, Room 7C26, Philadelphia, PA 19104.

E-mail: lautza@email.chop.edu

PEDIATRICS (ISSN Numbers: Print, 0031-4005; Online, 1098-4275).

Copyright © 2015 by the American Academy of Pediatrics

FINANCIAL DISCLOSURE: The authors have indicated they have no financial relationships relevant to this article to disclose.

FUNDING: No external funding.

POTENTIAL CONFLICT OF INTEREST: The authors have indicated they have no potential conflicts of interest to disclose.

CASE HISTORY WITH SUBSPECIALTY INPUT

Dr Andrew Lutz (Pediatrics, Chief Resident):

A 33-month-old girl was admitted to the general pediatrics inpatient service for fever and altered mental status. During the 3 days preceding admission, she was febrile with a maximum temperature of 102°F. Her fever was accompanied by decreased activity, diminished oral intake, and limited urine output. On the night before admission, the patient's mother noted multiple paroxysmal episodes of screaming with apparent unresponsiveness waking the child from sleep, each lasting seconds to a minute at a time. During these episodes the patient's lower

extremities were flexed to her abdomen, hands were clenched, and eyes were deviated upward. Afterward, she quickly returned to sleep. When awakened from sleep later, she seemed to be at her baseline mental status.

Dr Goldberg, are there features of this history concerning for seizures? What else is in the differential diagnosis of these paroxysmal episodes?

Dr Ethan Goldberg (Pediatric Neurology):

These movements could be seizures. Seizures are extremely common in the pediatric age group, affecting up to 10% of children.¹ As a neurologist, I am often asked about whether abnormal movements represent an epileptic seizure or a non-epileptic paroxysmal

movement of childhood. Fever can lower seizure threshold and can be an initial presenting trigger for epilepsy, but fever also lowers the threshold for many types of non-epileptic abnormal movements.

In considering this patient, a history of eyes rolled back in the head is often present with a seizure, but this is not pathognomonic of seizures. Hands clenched into fists can be a seizure or a movement disorder but is often a response to pain or discomfort. Although this history could represent seizure activity, the child may simply be responding to pain.

Dr Lautz:

The patient was born at term via spontaneous vaginal delivery, and there were no complications with pregnancy or delivery. She had a history of mild speech delay, which improved with speech therapy, and mild intermittent asthma, which had never required hospitalization. Her half-brother (by her father) had autism spectrum disorder; her other 2 siblings and both of her parents were healthy. She occasionally used albuterol as needed for wheezing; her last dose was several months before admission in association with an upper respiratory infection. She had no known drug allergies, and her immunizations were up to date.

On examination in the emergency department, she was noted to have a temperature of 38.4°C and was tachycardic with a heart rate of 130 bpm. Her respiratory rate was 26 breaths per minute, and her blood pressure was 97/54 mm Hg. Her oxygen saturation was 96% on room air by pulse oximetry. She was very tired-appearing; when she was aroused, she was fussy and difficult to console. Her mucous membranes were dry. She had no cardiac murmur, her pulses were symmetric, and her capillary refill was normal. Her lungs were clear and her abdomen was soft, nontender, and nondistended, without palpable organomegaly. The

remainder of her examination was normal.

Dr Blackstone, given this child's history and physical examination, what are your primary diagnostic considerations?

Dr Mercedes Blackstone (Pediatric Emergency Medicine):

This patient has a vast differential diagnosis, but the combination of pulling her legs to her abdomen and somnolence suggests a possible diagnosis of intussusception. She had a possible viral prodrome, which occurs in about one-third of cases of intussusception. Meningitis, encephalitis, sepsis, seizures, increased intracranial pressure, and drug ingestion are also considerations in this child presenting to the emergency department with fever and altered mental status.

Dr Lautz:

The serum levels of sodium, potassium, chloride, and total calcium and the complete blood count and differential were normal, but the serum bicarbonate was 12 mmol/L. Her fingerstick glucose level was 69 mg/dL. Urine dipstick was notable for large ketones. Urine drug screen was negative for amphetamines, barbiturates, benzodiazepines, cannabinoids, cocaine, methadone, opiates, and phencyclidine. A lumbar puncture was performed, revealing 2 white blood cells and 1040 red blood cells/mm³, with glucose 62 mg/dL and total protein 15 mg/dL in her cerebrospinal fluid (CSF). Blood, urine, and CSF were sent for culture. Selected laboratory test results are detailed in Table 1. An abdominal ultrasound was normal without evidence of intussusception. A plain radiograph of her abdomen demonstrated no evidence of obstruction. A CT scan of her head without contrast was normal.

She received a total of 40 mL/kg of normal saline intravenously for her tachycardia, resulting in

normalization of her heart rate, and she was initiated on dextrose-containing intravenous (IV) fluids at a rate 1.5 times her maintenance requirements. She received empirical IV vancomycin and ceftriaxone for presumed sepsis and was admitted to the inpatient ward for further management.

On admission, the IV fluid rate was decreased to maintenance. That night, the patient had continued intermittent episodes of agitation, characterized by sudden awakening from sleep with inconsolable screaming, crying, and upward eye deviation, lasting 15 to 30 seconds and associated with tachycardia. At the conclusion of these episodes, she fell back to sleep and when awakened appeared to be normally responsive. Similar episodes also occurred periodically during waking hours over the next 2 days, occasionally but not consistently accompanied by upper extremity stiffening. When questioned between episodes, she was unable to localize a source of pain.

The blood, urine, and CSF cultures remained negative at 48 hours, and empirical antibiotics were discontinued. Serum electrolytes were repeated on the second hospital day and revealed an increase in bicarbonate from 12 to 18 mmol/L. A repeat urinalysis was notable for persistent, large ketones. See Table 1 for selected laboratory data sent at this time.

Dr Ganesh, are you concerned about this persistent ketonuria and metabolic acidosis after 24 hours of IV hydration? What is your differential diagnosis of persistent ketonuria?

Dr Jaya Ganesh (Pediatric Metabolism):

An elevated anion gap acidosis with ketosis on presentation with persistent ketonuria despite intravenous dextrose supplementation is worrisome for a possible underlying

TABLE 1 Laboratory Data

Test	Reference Range	ED Laboratories	Laboratories on Second Hospital Day
Sodium, mmol/L	138–145	137	133
Potassium, mmol/L	4.1–5.8	5.0	4.0
Chloride, mmol/L	98–106	102	99
Carbon dioxide, mmol/L	20–26	12	18
Urea nitrogen, mg/dL	2–19	22	<2
Creatinine, mg/dL	0.1–0.4	0.4	0.2
Glucose, mg/dL	74–127	58	84
Calcium, mg/dL	8.7–9.8	9.8	9.2
Total bilirubin, mg/dL	0.6–1.4	0.6	0.4
Total protein, g/dL	5.4–7.0	7.9	6.1
Albumin, g/dL	3.5–4.6	4.8	3.6
Alkaline phosphatase, U/L	145–320	253	162
Alanine aminotransferase, U/L	5–45	35	37
Aspartate aminotransferase, U/L	20–60	67	61
Lipase, U/L	15–130	26	
WBC count, THOU/ μ L	4.86–13.18	5.9	
Differential, %			
Immature granulocytes	0.0–0.8	0.2	
Segmented neutrophils	22.4–69.0	68.3	
Lymphocytes	18.1–68.6	20.1	
Monocytes	4.1–11.4	11.2	
Eosinophils	0.0–3.3	0	
Nucleated RBC count (per 100 WBC)	0.0–0.0	0	
Hemoglobin, g/dL	11.5–13.5	12.2	
Platelet count, THOU/ μ L	189–394	234	
Ammonia, umol/L	9–33		14

ED, emergency department; RBC, red blood cells; THOU, thousand; WBC, white blood cells.

inborn error of metabolism. In any child who has unexplained mental status changes, it is important to measure a free-flowing serum ammonia level. If the ammonia level is elevated, the associated hypoglycemia, metabolic acidosis, and ketosis suggest the possibility of pyruvate carboxylase deficiency or a urea cycle defect. There is also a group of disorders called ketone utilization defects that are characterized by a block in a pathway of metabolizing ketones, leading to persistent ketonuria even when well. When children who have these disorders are ill, they can become hypoglycemic with a metabolic acidosis.

Dr Lautz:

The patient's newborn screen was normal. Serum ammonia level, plasma amino acids, and acylcarnitine profile were normal. Urine organic acid evaluation was notable for increased excretion of acetoacetate and

3-hydroxybutyrate. The patient's ketonuria resolved on repeat testing on the seventh hospital day. Genetic testing for β -ketothiolase deficiency was sent and ultimately returned normal, decreasing the likelihood of a ketone utilization disorder.

On the third hospital day, the patient had her first fever since admission to a maximum temperature of 38.5°C. Additionally, her mother expressed concern that she had been unable to ambulate over the previous few days. At that time, she refused to stand unassisted and preferentially bore more weight on her left lower extremity compared with the right. Her abdominal examination and musculoskeletal examination were normal. A CT scan of her abdomen and pelvis with contrast was performed to assess for possible occult infection, revealing thickening and irregularity of the terminal ileum with nodular tubular soft-tissue prominence protruding into the cecum.

Dr Maqbool, based on the information presented to this point, are there any primary gastrointestinal processes that would explain her symptoms and imaging findings?

Dr Asim Maqbool (Pediatric Gastroenterology):

Based on the CT scan, I would first think intussusception; it is unlikely to be a fixed lesion given the lack of an abdominal mass on examination and the previously negative ultrasound. I would then consider what might cause the lead point for the intussusception, specifically inflammation related to infection. A Meckel diverticulum could serve as a lead point in this patient. Mesenteric adenopathy is also a possibility but is less likely, because it was not noted on CT imaging. This presentation would be atypical for inflammatory bowel disease.

Dr Lautz:

A Meckel scan showed no scintigraphic evidence of a Meckel diverticulum containing ectopic gastric mucosa. Stool viral polymerase chain reaction (PCR) testing, rapid *Giardia* and *Cryptosporidium* antigen tests, and evaluation for ova and parasites were negative. *Clostridium difficile* PCR testing was positive for toxigenic *C. difficile*.

Dr Maqbool, in the absence of diarrhea or bloody stool, would you recommend treatment of this child who has PCR evidence of *C. difficile*?

Dr Maqbool:

No, in the absence of clinical colitis, I would consider this test to be evidence of colonization. There is no history of diarrhea or history of preceding antibiotic intake. The inflammation on CT scan was limited to the terminal ileum, which is not the typical pattern of pancolitis seen with *C. difficile* infection. The patient is probably a carrier of *C. difficile*, so I would not recommend treatment at this time.

Dr Lautz:

On the fourth and fifth hospital days, the patient had continued fevers with temperatures exceeding 38.5°C. She continued to have poor oral intake, necessitating continued IV fluid hydration. Furthermore, she persisted in having alternating periods of intense agitation as previously described, followed by somnolence and then return to baseline mental status, although these episodes were occurring less frequently. By the fifth day in the hospital, her mother noted she began having difficulty swallowing liquids, coughing with even small sips. She stopped speaking and had markedly diminished use of her right upper and lower extremities. Examination revealed 4/5 strength in her right upper and lower extremities with normal left-sided strength. She had normal tone, normal reflexes, and normal sensation to pain bilaterally. She was noted to have new rhinorrhea and a mild cough at this time.

Dr Goldberg, what is your differential diagnosis of her mutism and right-sided weakness?

Dr Goldberg:

Mutism can localize to multiple places in the central nervous system and oropharynx. It can be caused by diffuse cerebral cortical dysfunction, left hemispheric dysfunction (eg, owing to occlusion of the internal carotid artery), damage to Broca's area resulting in an expressive aphasia, damage to the mesencephalic reticular formation resulting in akinetic mutism, damage to the cerebellum (most often attributable to neurosurgical removal of the cerebellar vermis, and termed "cerebellar mutism"),² injury to the muscles and nerves that control speech, and bilateral vocal cord paralysis. In the context of altered mental status, difficulty swallowing, and weakness, I am concerned about dysfunction at the level of the brainstem.

Given her fever, infectious etiologies, such as an abscess or encephalitis, and inflammatory causes, including demyelinating processes and NMDA receptor encephalitis, should be high on the differential diagnosis for this clinical picture.

Dr Lautz:

By the sixth hospital day, the patient defervesced and had no further febrile episodes during hospitalization. In conjunction with defervescence, the previously described paroxysmal episodes abated, although she continued to be intermittently fussy for several more days. A routine EEG showed nonspecific slowing but no epileptiform discharges. An MRI of her cervical spine and magnetic resonance venography of her head were normal. Selected images from the MRI of her brain with and without gadolinium are shown in Fig 1.

A rapid respiratory viral PCR panel obtained from a nasopharyngeal aspirate returned positive for pandemic 2009 H1N1 influenza A infection.

Dr Shekdar, can you describe her MRI findings?

Dr Karuna Shekdar (Pediatric Neuroradiology):

The MRI of her brain demonstrated T2 hyperintense signal throughout her right cerebellar hemisphere with effacement of the cerebellar sulci consistent with edema. The fluid-attenuated inversion recovery (FLAIR) sequences confirmed abnormal signal in the right cerebellum, with partial effacement of the fourth ventricle and mild mass effect on the brainstem. There was no evidence of restricted diffusion. Contrast administration revealed leptomeningeal enhancement in the bilateral cerebellar hemispheres, more prominent on the right. The basal ganglia, thalami, and remainder of the supratentorial brain were unremarkable. In the context of the

viral PCR results, this imaging was thought to be consistent with H1N1 influenza cerebellitis.

Dr Offit, would you consider oseltamivir for this patient?

Dr Paul Offit (Pediatric Infectious Disease):

An important consideration is the pathogenesis of this particular problem. Is virus replicating in the cerebellum, and would giving a neuraminidase inhibitor prevent the virus from spreading? Or is this a postinfectious phenomenon characterized by an aberrant immune response? Influenza, like many respiratory viruses, is not typically associated with viremia,^{3,4} and virus replication is not usually part of the pathophysiologic mechanism of influenza encephalitis or cerebellitis.⁵

An additional consideration is when does one best benefit from oseltamivir administration? It is clear that oseltamivir administered to the hospitalized patient decreases length of hospitalization and decreases mortality, but the most benefit occurs when therapy is started within the first 48 hours of illness.⁶ Oseltamivir is unlikely to be of benefit after 5 days, but there are some recent data showing that there is some value in treating within 3 to 5 days of onset of disease.^{6,7}

Because this patient's cerebellitis is unlikely to be the result of active viral replication, and because oseltamivir is likely to be of limited efficacy in an afebrile patient after 5 days of illness (even if this pathophysiology was mediated by active viral replication), I would not recommend oseltamivir for this patient.

FINAL DIAGNOSIS AND DISCUSSION: INFLUENZA ENCEPHALITIS

Dr Jennifer McGuire (Pediatric Neurology):

As an overview of the varied neurologic manifestations of influenza infection, here is a sample

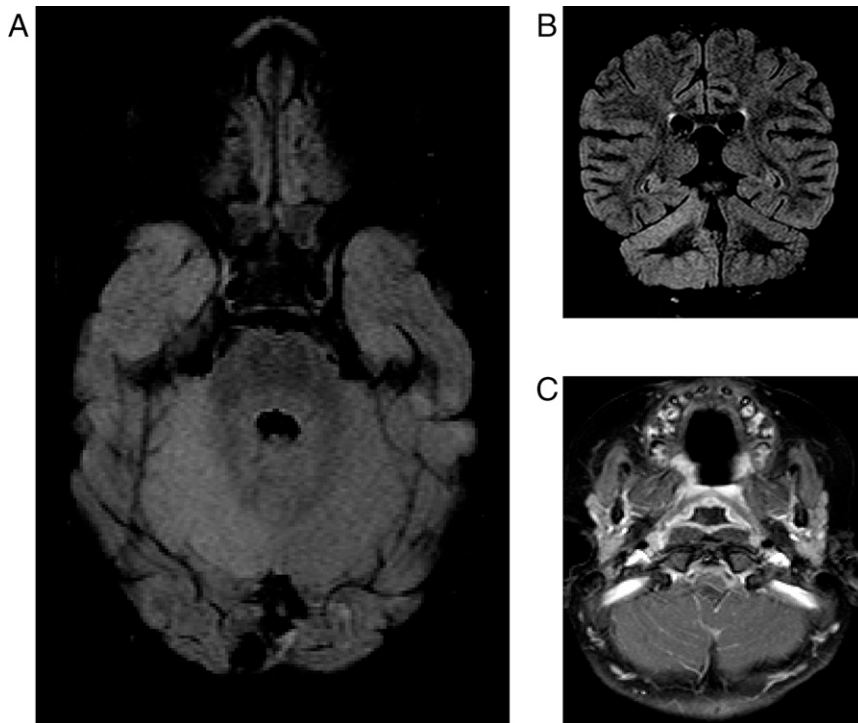


FIGURE 1

Selected images from the MRI brain study performed on this patient. A, FLAIR axial image showing hyperintense signal throughout the right cerebellar hemisphere with effacement of the right cerebellar sulci. B, FLAIR coronal image showing hyperintense signal in the right cerebellar hemisphere with mild mass effect on the fourth ventricle. C, Post-contrast axial T1 image demonstrating leptomeningeal enhancement in the bilateral cerebellar hemispheres, more prominent in the right cerebellum.

of patients followed by our division, all of whom were ultimately diagnosed with complications of influenza infection: a 5-year-old boy who presented with dysarthria, central seventh cranial nerve palsy, left-sided weakness, pain, and dysmetria, found to have a toxic leukoencephalopathy; a 4-year-old boy who presented in status epilepticus and subsequently developed hallucinations, ataxia, and confusion after the seizures stopped; a 13-year-old boy who presented with expressive aphasia and difficulty walking who progressed to coma and was found to have acute disseminated encephalomyelitis; an 11-month-old girl who had a known seizure disorder whose baseline seizure rate increased from 1 seizure per week to 200 to 300 per day; a 15-year-old boy who presented with confusion and dysarthria; a 27-month-old girl who presented with ataxia; and a 5-year-old girl who presented with

ataxia, hypotonia, and areflexia, who was later diagnosed with Guillain-Barré syndrome.

The most common neurologic complication of influenza infection in children is seizure (78%), many of which (but not all) are febrile seizures.^{8,9} In the United States, 2% to 4% of all children will have a febrile seizure in their life. However, up to 20% of children hospitalized with influenza have a febrile seizure, which is significantly higher than children hospitalized with parainfluenza or adenovirus, suggesting this is at least partially influenza-specific.^{10,11}

Encephalopathy, frontal lobe syndromes, visual hallucinations, mutism, movement disorders, and neuropsychiatric problems are also common.^{9,11-13} In the bigger clinical picture, some children meet criteria for acute necrotizing encephalopathy, a fulminant process with multifocal necrotizing lesions in the thalamus,

brainstem, and periventricular white matter. Guillain-Barré syndrome can occur, with a length-dependent acute inflammatory demyelinating polyneuropathy. Notably, encephalitis lethargica (or von Economo encephalitis) was described during the 1918 influenza pandemic as a postinfectious Parkinsonism; it is not actually clear if influenza is causative of this syndrome. Reye syndrome can occur with influenza as well. Finally, influenza encephalitis and cerebellitis are common, and these were the ultimate diagnoses for this patient.¹³

Encephalitis in general is characterized by inflammation of the brain on histopathology associated with clinical neurologic dysfunction. However, brain biopsies are not routinely performed to make this diagnosis. Therefore, one may clinically define encephalitis as acute central nervous system dysfunction, such as a seizure, focal neurologic deficit, or altered mental status, in the context of laboratory or radiographic evidence of brain parenchymal infection or inflammation. This patient clearly met these clinical criteria based on her presentation and MRI findings.

Influenza-associated encephalitis is most commonly associated with influenza A and is most common in children under the age of 5 years.¹²⁻¹⁴ Symptoms generally start a few days to 1 week after clinical onset of infection. Mortality is up to 37%, with a high prevalence of persistent neurologic morbidity in survivors in some Japanese cohorts¹⁵; mortality appears to be much lower in North American studies.^{8,14} Interestingly, although this patient was diagnosed with influenza A, influenza B encephalitis is more often associated with speech abnormalities, including mutism.¹²

It is important to remember that encephalopathy in the setting of influenza infection may not always be attributable to encephalitis. Instead, it

may be attributable to indirect effects of systemic illness, including metabolic derangements, systemic cytokine storming, and vasogenic cerebral edema.^{11,14,16} For unknown reasons, Japan has a higher incidence of influenza-associated encephalopathy than other countries.^{9,11,16} Additionally, different strains of influenza appear to have higher rates of encephalopathy than others; influenza A H3/N2 is particularly neuropathogenic.⁹ It is unclear if these neuropathogenic strains are particularly neurotropic, or simply more likely to lead to a systemic host inflammatory response resulting in encephalopathy.

There are no set diagnostic criteria that are pathognomonic for influenza encephalitis outside of the clinical encephalitis case definition above in the context of laboratory-confirmed influenza infection. Notably, viremia is rare, and virus is rarely found in CSF or in brain tissue from autopsy cases.^{9,11} Pleocytosis is not typical, and when present is commonly mononuclear in origin.¹³ Although antiviral treatment does diminish the overall risk for complications from influenza, data are lacking for specific prevention of influenza-related encephalitis or encephalopathy.^{9,12} Moreover, the role of steroids is unclear. Prognosis is highly variable, and persistent morbidity can occur in the absence of abnormal imaging.

Dr Lautz:

She received 3 doses of oseltamivir, but therapy was discontinued after the treatment team discussed the case with consulting services. By the thirteenth hospital day, her mother noted that she was acting much more like her usual self. Although she was not yet speaking, she was making use of nonverbal communication (pointing and grunting while making

eye contact). She had improved motor function and was able to move and point her right upper extremity with mild dysmetria. She could ambulate with her hand held using a steppage gait of her right lower extremity. She had improved oral intake and had no further coughing episodes with intake of solids or liquids. She was transferred to an inpatient rehabilitation facility to continue intensive physical, occupational, and speech therapy. Within several months of hospitalization, she regained normal motor function and near-normal speech and was receiving continued support with ongoing speech therapy.

ACKNOWLEDGMENTS

We thank Mercedes Blackstone, MD, Jaya Ganesh, MD, Ethan Goldberg, MD, PhD, Asim Maqbool, MD, Paul Offit, MD, and Karuna Shekdar, MD for sharing their time and expertise.

REFERENCES

1. Kliegman RM, Stanton B, St. Geme J, Schor NF, Behrman RE. *Nelson Textbook of Pediatrics*, 19th ed. Philadelphia, PA: Elsevier Saunders; 2011
2. Reed-Berendt R, Phillips B, Picton S, et al. Cause and outcome of cerebellar mutism: evidence from a systematic review. *Childs Nerv Syst*. 2014;30(3):375–385
3. Likos AM, Kelvin DJ, Cameron CM, Rowe T, Kuehnert MJ, Norris PJ; National Heart, Lung, Blood Institute Retrovirus Epidemiology Donor Study-II (REDS-II). Influenza viremia and the potential for blood-borne transmission. *Transfusion*. 2007;47(6):1080–1088
4. Kuiken T, Taubenberger JK. Pathology of human influenza revisited. *Vaccine*. 2008; 26(Suppl 4):D59–D66
5. Kawada J, Kimura H, Ito Y, et al. Systemic cytokine responses in patients with influenza-associated encephalopathy. *J Infect Dis*. 2003;188(5):690–698
6. Muthuri SG, Myles PR, Venkatesan S, Leonardi-Bee J, Nguyen-Van-Tam JS.

Impact of neuraminidase inhibitor treatment on outcomes of public health importance during the 2009-2010 influenza A(H1N1) pandemic:

a systematic review and meta-analysis in hospitalized patients. *J Infect Dis*. 2013; 207(4):553–563

7. Yu H, Feng Z, Uyeki TM, et al. Risk factors for severe illness with 2009 pandemic influenza A (H1N1) virus infection in China. *Clin Infect Dis*. 2011;52(4):457–465
8. Newland JG, Laurich VM, Rosenquist AW, et al. Neurologic complications in children hospitalized with influenza: characteristics, incidence, and risk factors. *J Pediatr*. 2007;150(3):306–310
9. Maricich SM, Neul JL, Lotze TE, et al. Neurologic complications associated with influenza A in children during the 2003-2004 influenza season in Houston, Texas. *Pediatrics*. 2004;114(5). Available at: www.pediatrics.org/cgi/content/full/114/5/e626
10. Chiu SS, Tse CY, Lau YL, Peiris M. Influenza A infection is an important cause of febrile seizures. *Pediatrics*. 2001;108(4). Available at: www.pediatrics.org/cgi/content/full/108/4/E63
11. Toovey S. Influenza-associated central nervous system dysfunction: a literature review. *Travel Med Infect Dis*. 2008;6(3): 114–124
12. Newland JG, Romero JR, Varman M, et al. Encephalitis associated with influenza B virus infection in 2 children and a review of the literature. *Clin Infect Dis*. 2003; 36(7):e87–e95
13. Studahl M. Influenza virus and CNS manifestations. *J Clin Virol*. 2003;28(3): 225–232
14. Amin R, Ford-Jones E, Richardson SE, et al. Acute childhood encephalitis and encephalopathy associated with influenza: a prospective 11-year review. *Pediatr Infect Dis J*. 2008;27(5):390–395
15. Sugaya N. Influenza-associated encephalopathy in Japan. *Semin Pediatr Infect Dis*. 2002;13(2):79–84
16. Mizuguchi M, Yamanouchi H, Ichijama T, Shiomi M. Acute encephalopathy associated with influenza and other viral infections. *Acta Neurol Scand Suppl*. 2007;186:45–56

A 33-Month-Old With Fever and Altered Mental Status

Andrew J. Lautz, Brian Jenssen, Jennifer McGuire and Joseph W. St. Geme III

Pediatrics 2015;135;120

DOI: 10.1542/peds.2014-2405 originally published online December 8, 2014;

Updated Information & Services

including high resolution figures, can be found at:
<http://pediatrics.aappublications.org/content/135/1/120>

References

This article cites 15 articles, 1 of which you can access for free at:
<http://pediatrics.aappublications.org/content/135/1/120#BIBL>

Subspecialty Collections

This article, along with others on similar topics, appears in the following collection(s):
Infectious Disease
http://www.aappublications.org/cgi/collection/infectious_diseases_sub
Neurology
http://www.aappublications.org/cgi/collection/neurology_sub

Permissions & Licensing

Information about reproducing this article in parts (figures, tables) or in its entirety can be found online at:
<http://www.aappublications.org/site/misc/Permissions.xhtml>

Reprints

Information about ordering reprints can be found online:
<http://www.aappublications.org/site/misc/reprints.xhtml>

American Academy of Pediatrics

DEDICATED TO THE HEALTH OF ALL CHILDREN™



PEDIATRICS®

OFFICIAL JOURNAL OF THE AMERICAN ACADEMY OF PEDIATRICS

A 33-Month-Old With Fever and Altered Mental Status

Andrew J. Lautz, Brian Jenssen, Jennifer McGuire and Joseph W. St. Geme III

Pediatrics 2015;135;120

DOI: 10.1542/peds.2014-2405 originally published online December 8, 2014;

The online version of this article, along with updated information and services, is located on the World Wide Web at:

<http://pediatrics.aappublications.org/content/135/1/120>

Pediatrics is the official journal of the American Academy of Pediatrics. A monthly publication, it has been published continuously since 1948. Pediatrics is owned, published, and trademarked by the American Academy of Pediatrics, 141 Northwest Point Boulevard, Elk Grove Village, Illinois, 60007. Copyright © 2015 by the American Academy of Pediatrics. All rights reserved. Print ISSN: 1073-0397.

American Academy of Pediatrics

DEDICATED TO THE HEALTH OF ALL CHILDREN™

