

Anogenital Injuries in Child Pedestrians Run Over by Low-Speed Motor Vehicles: Four Cases With Findings That Mimic Child Sexual Abuse

Stephen C. Boos, MD*; Angela J. Rosas, MD‡; Cathy Boyle, PNP‡; and John McCann, MD‡

ABSTRACT. *Objective.* Differentiating between child sexual abuse and nonintentional causes of anogenital injury can be challenging, and a misdiagnosis can have a profound impact on the child and family. This case series documents an important nonintentional mechanism of anogenital injury that mimics the physical findings of child sexual abuse.

Methods. Four children were examined after being run over by a slow-moving motor vehicle. In each case, the wheel of the vehicle passed longitudinally over the child's torso.

Results. Two children had perianal lacerations, and 2 had hymenal lacerations. One child with hymen injuries was followed for 4 weeks and developed findings identical to those seen in healed sexual abuse.

Conclusions. Children run over by motor vehicles should be evaluated for anogenital injury. If such injury is suspected, it should be fully delineated and documented with colposcopy and follow-up examination. Although the possibility of sexual abuse must be considered, awareness of the occurrence of anogenital injuries in children run over by motor vehicles may prevent the misdiagnosis of acute sexual abuse in children. Conversely, children presenting for evaluation of acute or past sexual abuse should be questioned as to whether they were ever run over by a motor vehicle. *Pediatrics* 2003;112:e77–e84. URL: <http://www.pediatrics.org/cgi/content/full/112/1/e77>; child sexual abuse, motor vehicle injury, genital injury, anal injury.

ABBREVIATIONS. UCDC, University of California Davis, Children's Hospital; CAARE, Child and Adolescent Abuse Resource and Evaluation; CT, computed tomography; CPS, child protection services.

Anogenital injury is unusual in most cases of nonintentional pediatric trauma. When injury to the anus or genitals does occur, the examiner will at least ponder the possibility of child sexual abuse, especially if the history is vague or

appears implausible. In many cases, the finding of an anogenital injury becomes a diagnostic dilemma in distinguishing child sexual abuse from nonintentional injury. Differentiating between these 2 causes of trauma has great importance to the injured child and the family. In this case series, the literature to support the differentiation of anogenital findings caused by sexual versus nonintentional trauma will be reviewed. Four cases will then be presented that demonstrate a new nonintentional mechanism for anogenital injury that mimics the findings of child sexual abuse.

A recent large population study of girls with perineal injuries describes the incidence of the various mechanisms of injury.¹ Among 358 girls up to 16 years of age presenting with perineal injuries, motor vehicle crash was the most common mechanism of injury, responsible for 63% of the cases. In 28% of the cases, the injuries were caused by another nonintentional mechanism, including falls, bicycles, or activities around a playground or pool. In 9% of all the cases, the perineal injury was caused by sexual abuse, but in girls <4 years of age, the incidence of sexual abuse was significantly greater at 17%. Although this study documented that nonintentional mechanisms are more commonly the cause of perineal injury in girls, there were no details of the specific pattern of injury seen on examination to assist the medical provider in distinguishing nonintentional injury from child sexual abuse.

Other case series and larger articles, however, do describe the specific anogenital findings resulting from various mechanisms of injury. In cases of acute sexual abuse, the most common findings are injuries to the posterior genital structures. In several child sexual abuse studies, 36% to 100% of the genital injury cases in each study had hymen or vaginal injuries, and 50% to 100% had injuries to the posterior fourchette or fossa navicularis.^{2–5} In each of these articles, injuries to the labia and external genitalia were uncommon, occurring in 20% or fewer of the genital trauma cases in each study. Furthermore, there are several published classification systems that record acute injuries to the hymen and posterior vestibule as highly suggestive if not indicative of child sexual abuse.^{6–8} These same classification systems also list injuries to the external genitalia as nonspecific.

Anal injury from acute child sexual abuse has been described in 2 small case series.^{4–9} In each case there was a significant single anal laceration or multiple

From the *Department of Pediatrics, Armed Forces Center for Child Protection, National Naval Medical Center, Bethesda, Maryland; †Department of Pediatrics, Child and Adolescent Abuse Resource and Evaluation Center, University of California Davis Medical Center, Sacramento, California.

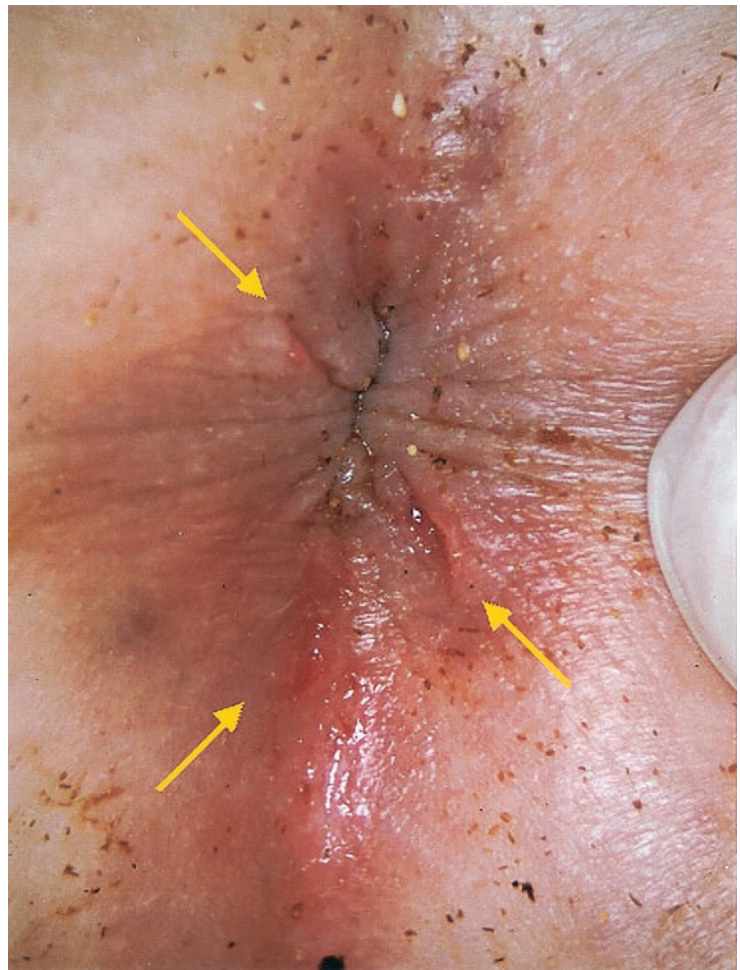
Received for publication May 3, 2000; accepted Mar 21, 2003.

Address correspondence to Angela J. Rosas, MD, Assistant Professor of Clinical Pediatrics, Department of Pediatrics, Child and Adolescent Abuse Resource and Evaluation Center, University of California Davis Medical Center, 3300 Stockton Blvd, Sacramento, CA 95820-1451. E-mail: angela.rosas@ucdmc.ucdavis.edu

The opinions in this article are those of the authors and are not intended to represent the official positions of the US Air Force, US Department of Defense, or other government agency.

PEDIATRICS (ISSN 0031 4005). Copyright © 2003 by the American Academy of Pediatrics.

Fig 1. Case 1. Supine view, initial examination. Fresh perianal lacerations run radially, extending from the anus at 5, 6, and 10 o'clock.



perianal lacerations. The published classification systems also support deep perianal lacerations as findings of child sexual abuse.⁶⁻⁸

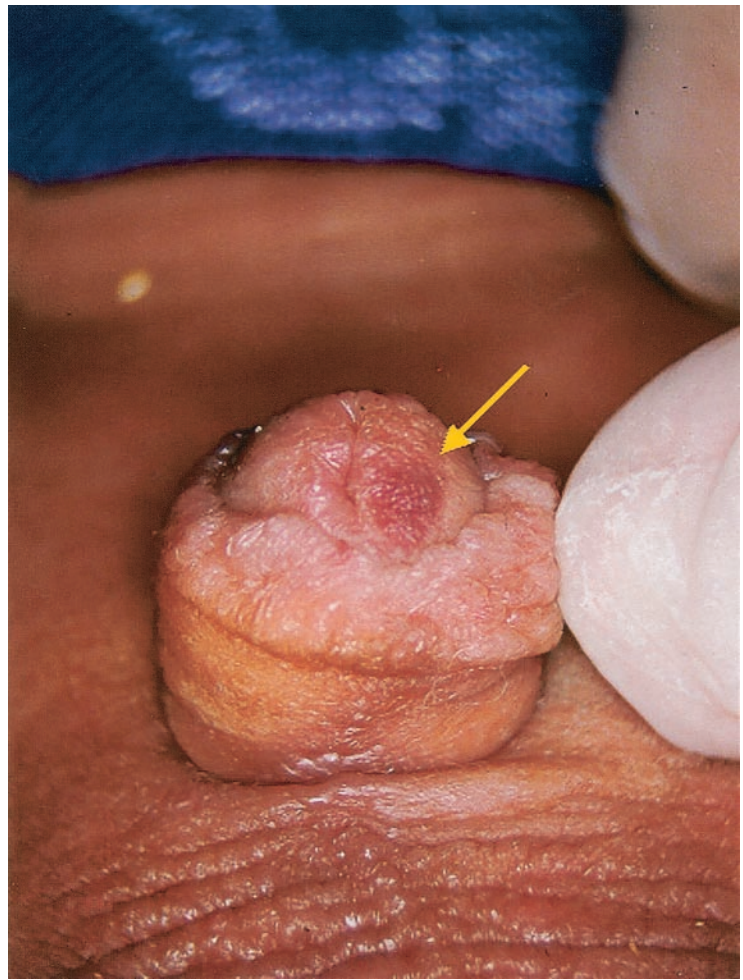
Several articles and case reports also describe the specific anogenital findings of straddle fall injuries. In a collection of 3 articles, there were 141 cases of girls presenting for emergency care for straddle fall injuries.¹⁰⁻¹² The most common injury was to the labia majora or minora, which occurred in 67% to 95% of the straddle fall cases in each article. In these same studies, injuries to the hymen or vagina were unusual, occurring in 2% to 16% of the cases in each article. Recently, Herrmann and Crawford¹³ reported 2 cases of higher force straddle falls from inline skating, both of which had significant lacerations in the perineum and through the posterior genital structures, but no direct hymen or vaginal injury. In a separate large study of anogenital injuries in children presenting for emergency care, Jones and Bass³ described 143 children with straddle injuries and also noted labial injuries as "common" and vaginal injuries as "uncommon." In 2 other studies that reviewed a total of 29 surgical straddle fall cases, hymen or vaginal injuries were found in 15% to 36% of patients who suffered a straddle fall, whereas injuries to the labia or perineum were found in at least 60%.^{5,14} These 2 studies of surgical cases likely represented patients that were more severely injured,

which may explain the higher rate of vaginal injuries compared with the studies including all cases presenting to emergency departments. Additionally, Dowd et al¹¹ looked at 28 boys presenting for anogenital trauma and found that boys with straddle fall mechanism commonly injured the scrotum (57%) and penis (43%) with only 1 case of perineal injury and no injuries to the perianal area.

In the few reported cases of nonintentional genital impalement, the findings are similar to child sexual abuse. Dowd et al¹¹ described 3 cases of girls with nonintentional vaginal impalement injury, all with injuries to the vagina or hymen, and 2 with injuries to the posterior fourchette. Boos¹⁵ described 1 case of nonintentional vaginal impalement that resulted in acute hymen transection and a fossa navicularis abrasion with limited injury to the labia minora. Additionally, nonintentional anal penetration in children has been described by Jona.¹⁶ He noted 4 cases referred for surgical repair that involved anal tears and rectal perforations.

Although motor vehicle collision is an important cause of anogenital injuries in children, there is little documentation of the specific findings on examination and the specific type of collision.^{3,5,10,14,17} Porkorny et al¹⁰ described 2 cases of motor vehicle collision with injury to the labia minora and the vestibule, specifically indicating that there were no

Fig 2. Case 1. Supine position, initial examination. Purple hematoma of the glans penis.



injuries to the hymen. One child was injected from a motorcycle, and one was crushed between the car and a wall. Wynne⁵ described one case with an extensive laceration from the clitoris to the anus and another case in which a fragment of pelvic bone lacerated the urethra and the vagina. More recently, Silen et al¹⁸ reviewed 24 cases of young children run over in the driveway, in which one case had anal and vaginal lacerations. The cases of anogenital injury from motor vehicle collisions are often associated with intraabdominal organ injuries, pelvic fractures, limb fractures, and a high mortality rate from head injuries.

In summary, the literature shows that sexual penetrating trauma and the rare case of nonintentional anogenital impalement have similar patterns of injury including lacerations and abrasions of the hymen and posterior genital structures or perianal lacerations. In contrast, nonintentional anogenital injury from straddle falls commonly involve injuries to the external genitalia in both boys and girls with only occasional injury to the hymen or perianal tissues in cases presenting for emergency care. Additionally, as often as children are injured in motor vehicle collisions, there is little description of anogenital injury except perhaps in very high force trauma cases. A single case noted by Silen¹⁸ represents the first reported case of anogenital injury in child pedestrians run over by motor vehicles, but the

report lacks specific details about the injury. The following 4 cases offer a detailed description of anogenital injuries suffered by children who were run over by a motor vehicle.

METHODS

The University of California Davis Children's Hospital (UCDCH) is a level 1 Pediatric Trauma Center, serving all of Northern California. In the year 2000 alone, there were 320 children under 16 years old evaluated for injuries from motor vehicle collisions. A total of 142 of these injured children were pedestrians (non-bicycle). The UCDCH is also home to the Child and Adolescent Abuse Resource and Evaluation (CAARE) Center, a multidisciplinary clinical program evaluating and treating over 2000 cases of suspected child abuse annually. The CAARE team performs all sexual assault examinations of patients under 16 years old at UCDCH.

The 4 cases to be described represent a convenience sample of young children presenting to the UCDCH Pediatric Trauma Center after having been run over by a motor vehicle at low speed. Each patient had various injuries, including anogenital bleeding. In each case, the treating physician consulted the CAARE team because the anogenital injury created concern for sexual abuse. All of the cases presented between 1995 and 1999.

The CAARE team assessment included a history of the injury events, a review of the medical record, a general physical examination of the patient and clothing when available, and colposcopic examination of the anogenital region. Colposcopic examination was performed at the bedside using 6- to 16-power magnification with photodocumentation via a 35-mm camera mounted on a side arm of the colposcope with a concentrically mounted ring flash. All photographs were reviewed at a case conference with the senior examiners, each with at least 500 cases of experience. Follow-up examinations in the hospital or in the CAARE Center offices were performed when possible.

Case Presentations

Case 1

A 16-month-old Hispanic male was run over by an adult family member who was backing the car out of the garage. The family member reported feeling a bump, and got out to find this child lying on the ground under the car. There was no loss of consciousness and the child cried immediately. An ambulance was called and brought the child to the UCDCH emergency department. Examiners noted multiple superficial lacerations, petechia, superficial lacerations, and ecchymoses over the left lower quadrant and left thigh, suggesting the passage of a car tire over these areas. The CAARE team was asked to consult when blood and tiny bits of glass and debris were found in the diaper. On the day of injury, a colposcopic examination demonstrated fresh, radially oriented anal lacerations extending out from the anal verge at 5, 6, and 10 o'clock in supine position (Fig 1). He also had a small hematoma on the glans and abrasions at the base of the penis (Fig 2). There were also abrasions over the left ischial tuberosity. Follow-up examination 3 days later noted significant interval healing of the perianal lacerations and a resolving hematoma of the glans penis.

Because of chaotic family circumstances and the unexpected physical findings, the county Child Protection Service (CPS) was asked to investigate. Local law enforcement completed a scene investigation, and both agencies interviewed the family and witnesses. CPS made several home visits and found no other concerns beyond lack of supervision resulting in the motor vehicle injury. It was never discovered how the tiny bits of glass and debris got into the toddler's diaper. The case was eventually closed by CPS and law enforcement. There were no other substantiated reports of abuse or neglect to date, which is now 7 years after the injury.

Case 2

A 5-year-old Southeast Asian female was run over by a car as her aunt backed it out of the driveway. The child was found

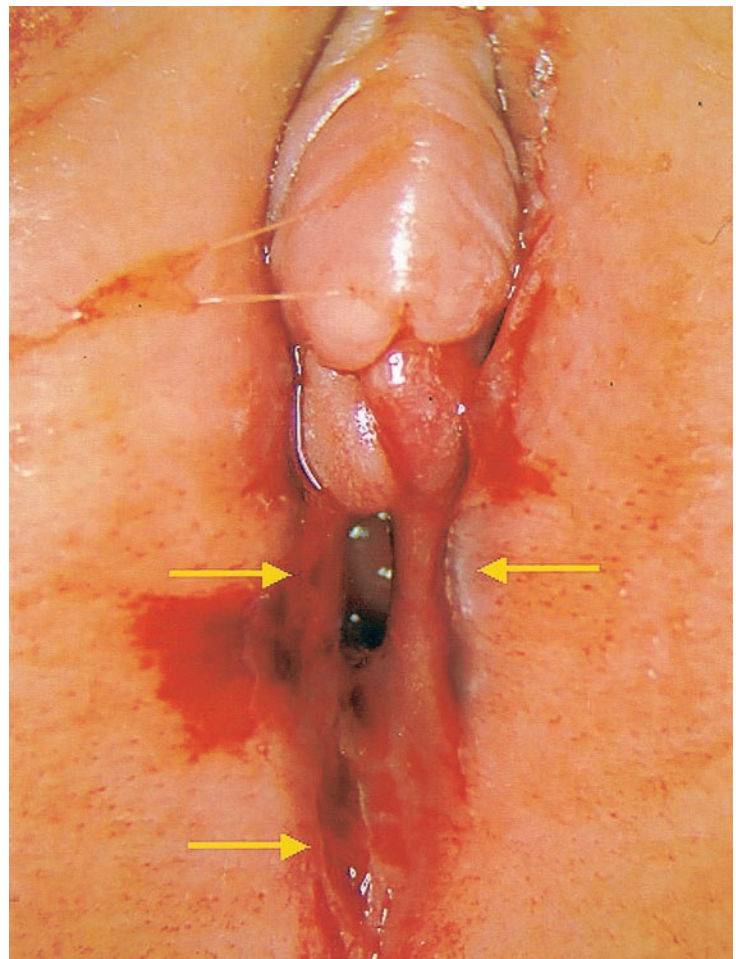
beneath the car. Witnesses at the scene reported no loss of consciousness, but bleeding was noted from the perineum and there was fecal soiling of the clothing. In the emergency department, abrasions were noted on the back, arms, hips, and perineum. There was bruising on the medial right thigh. Computed tomography (CT) scans of the pelvis and abdomen were normal. There was no fracture of the pelvis. Examination of the clothing revealed tire tread marks running longitudinally along the right posterior side. Because of the genital bleeding, the CAARE team was asked to evaluate the child. On the day of injury, a colposcopic examination revealed multiple abrasions, lacerations, and hematomas involving the left labium majora and minora, perineum, fossa navicularis, and posterior fourchette (Fig 3). At the time of the initial examination, the hymen was swollen with a hematoma on the posterior rim. There were no injuries to the perianal tissue. Follow-up examination 4 weeks later documented a healed cleft at 1 o'clock in the prone position, equivalent to 7 o'clock in the supine position (Fig 4). The other genital injuries had healed completely.

The case was referred to CPS for lack of supervision and possibly sexual abuse. Law enforcement also conducted a scene investigation. The child was interviewed at a multidisciplinary interviewing center in her native language where she denied any type of physical or sexual abuse ever. Subsequently, however, there have been 2 reports to CPS of physical abuse and neglect in this large family, both of which were investigated and unfounded.

Case 3

A 13-month-old white female was run over by a child care provider who was backing her car out of her own driveway. The child was found lying in the driveway, and witnesses at the scene reported no loss of consciousness or other apparent injury. The child was brought to the UCDCH emergency department, where bruises were noted on the right upper arm, shoulder, and left groin. In addition, linear superficial abrasions were noted to cross

Fig 3. Case 2. Supine position, initial examination. Hematoma is visible along the labium minora. Lacerations extend from the posterior fourchette through the median raphe.



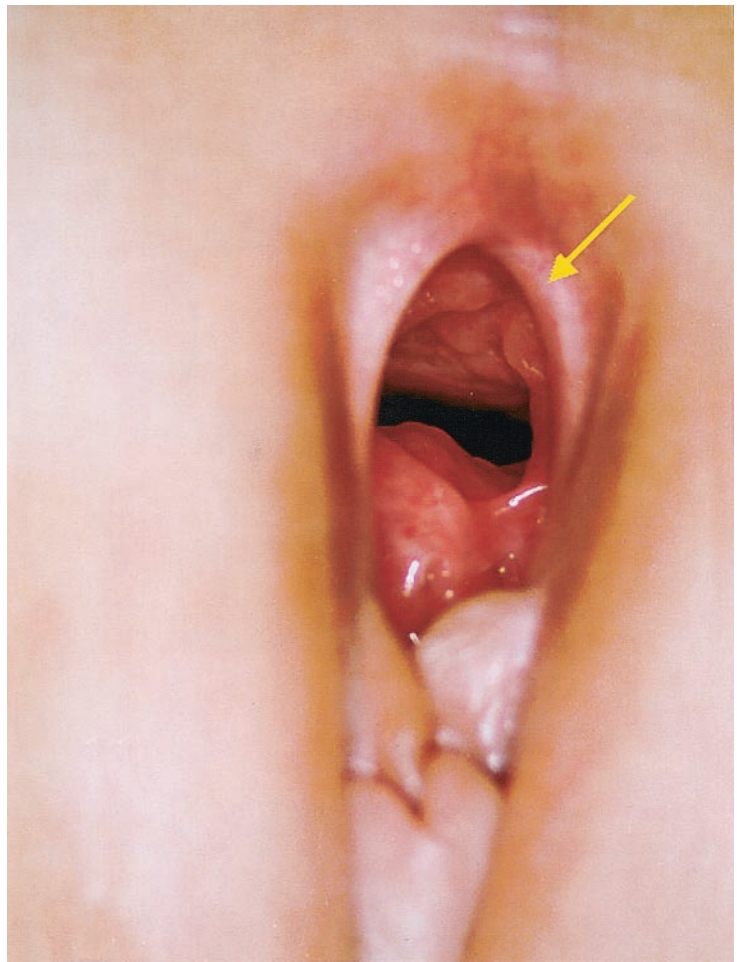


Fig 4. Case 2. Prone position, 1 month postinjury. Healed hymen cleft at 1 o'clock prone position, equivalent to 7 o'clock supine position.

the anterior trunk diagonally between the right shoulder and the left lower abdomen. A CT scan of the abdomen and pelvis demonstrated extensive laceration of the liver, contusion of the colon, and free fluid in the abdomen and pelvis. No pelvic fracture was noted. Examination of the clothing revealed tire marks running across the shirt in an orientation that paralleled the abrasions of the chest. The CAARE team was requested to evaluate the anal bleeding. A colposcopic examination demonstrated normal genitalia without any injury. A series of acute lacerations were noted on the perianal skin. These were single or paired radially oriented lacerations at 5, 6, and 12 o'clock (Fig 5). Laxity of the anal sphincters was seen under general anesthesia, but was gone on a follow-up examination. No injuries were found within the distal anal canal.

The case was investigated by local law enforcement agents, who evaluated the scene and interviewed the child care provider. The parents were at work at the time of the incident. Neither the parents nor the child care provider had any prior CPS or criminal history. CPS was notified about concerns of lack of supervision on the part of the child care provider, but the case was unsubstantiated. Law enforcement and CPS concurred that the injuries were unintentional. One year after the child's injuries, the father was murdered and the mother was reported multiple times to CPS for substance abuse, mental illness, and general neglect. The child has been adopted by a foster family.

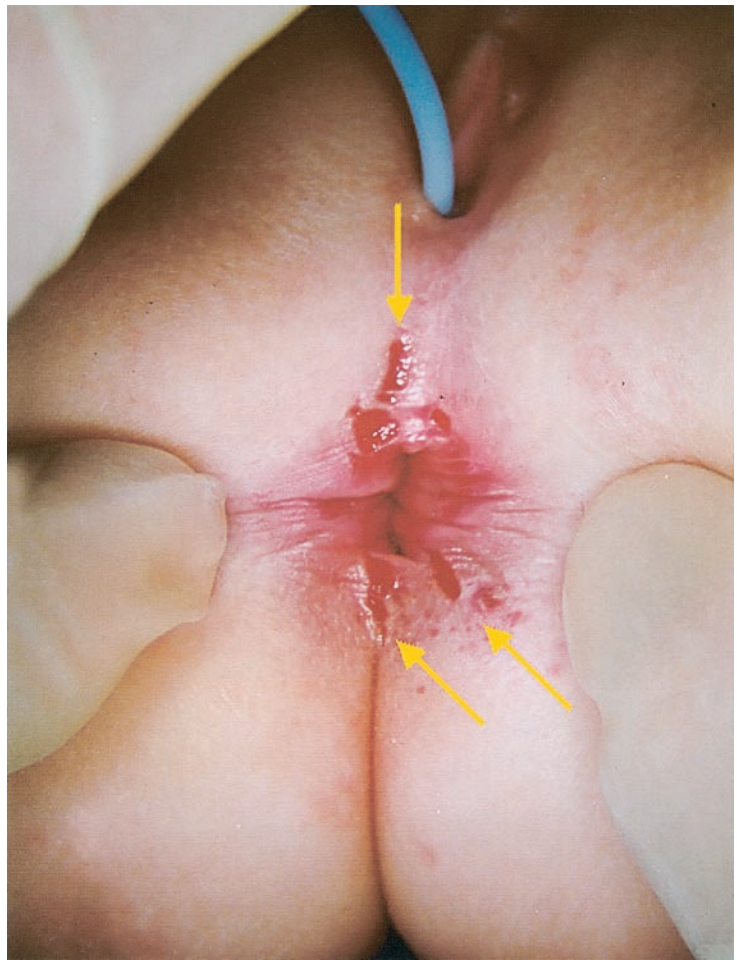
Case 4

A 6-year-old Hispanic girl fell off of a moving tractor driven by her father and was found in a ditch ~6 to 8 feet below the level of the tractor cab. There was no loss of consciousness and the child stated that the tractor ran over her abdomen and she slid into the ditch. At the scene, she complained of pelvic and leg pain, and blood was seen coming from her perineum. She was taken to a local hospital and transferred to the UCDC emergency depart-

ment. She had contused abrasions on the left mastoid process and an extensive area of 2- to 4-cm long linear abrasions along the left chest, abdomen, and flank, oriented in the longitudinal axis. She also had transverse lacerations over the left lower ribs and iliac crest. CT scans of her thorax, abdomen, and pelvis revealed contusions of the right lung and bilateral pelvic superior rami fractures. Skeletal films showed a right tibia fracture and multiple fractures of the right metatarsals. Cystography and sigmoidoscopy were performed and both were normal. A gynecologist visually examined the genitals under anesthesia with a long nasal speculum and found a small laceration in the left vestibule and a 1-cm laceration of the anterior vaginal wall. There was no mention of a hymen injury. Both lacerations were sutured. On day 4, the CAARE Team was consulted because of the genital injuries and somewhat unusual history. The child's multiple fractures allowed only a visual inspection of the genitals, which demonstrated bilateral bruising of the labia majora and confirmed the laceration in the left vestibule. However, the view of the hymen was limited. On day 8, the CAARE Team performed a colposcopic examination and found a hymen laceration at 7 o'clock and a submucosal hemorrhage at 10 o'clock in supine position, both with granulation tissue (Fig 6). A brown serosanguinous vaginal discharge was noted. The perianal tissues were not injured.

Although the hymenal and vestibular injuries resembled penetrating sexual injury of the hymen and vagina, the child denied any sexual abuse. Nonetheless, CPS was contacted and verified that there were no previous reports on the statewide database on this child or her family. An interview by the hospital social worker revealed that the father had a history of alcoholism, incarceration for domestic violence against the mother, and psychosis that required hospitalization. At the time of the child's injury, he had been sober for 2 years and had no psychiatric symptoms. CPS was concerned about the lack of supervision and the history of domestic violence and mental illness, but did not substantiate

Fig 5. Case 3. Supine position, initial examination. Multiple fresh perianal lacerations run radially, extending from the anus at 5, 6, and 12 o'clock.



any current abuse or neglect. A review of the statewide CPS database to date showed 1 subsequent substantiated report of child physical abuse in this family, 2 years after the child's motor vehicle injury.

RESULTS

The 4 cases presented are similar in that they have a clear mechanism of injury involving the child's abdomen or trunk being run over by a slow-moving motor vehicle. The vehicle appears to have run over the child in a longitudinal or diagonal direction based on the pattern of abdominal, pelvic, and cutaneous injuries as well as the markings on the clothing. In no child was there evidence that the wheel passed between the legs or that the child suffered anogenital impalement or straddle injury. Although in case 1 it was never discovered how the tiny bits of glass got into the toddler's diaper, it is unlikely that this debris was responsible for the extensive perianal lacerations or the hematoma on the glans penis. The tiny bits of glass debris may have contributed to the abrasions on the shaft of the penis. Additionally in case 4, it is possible that the hymen laceration and submucosal hemorrhage may have happened iatrogenically during the vaginal speculum examination. The vestibule and vaginal lacerations, however, were clearly present before any instrumentation.

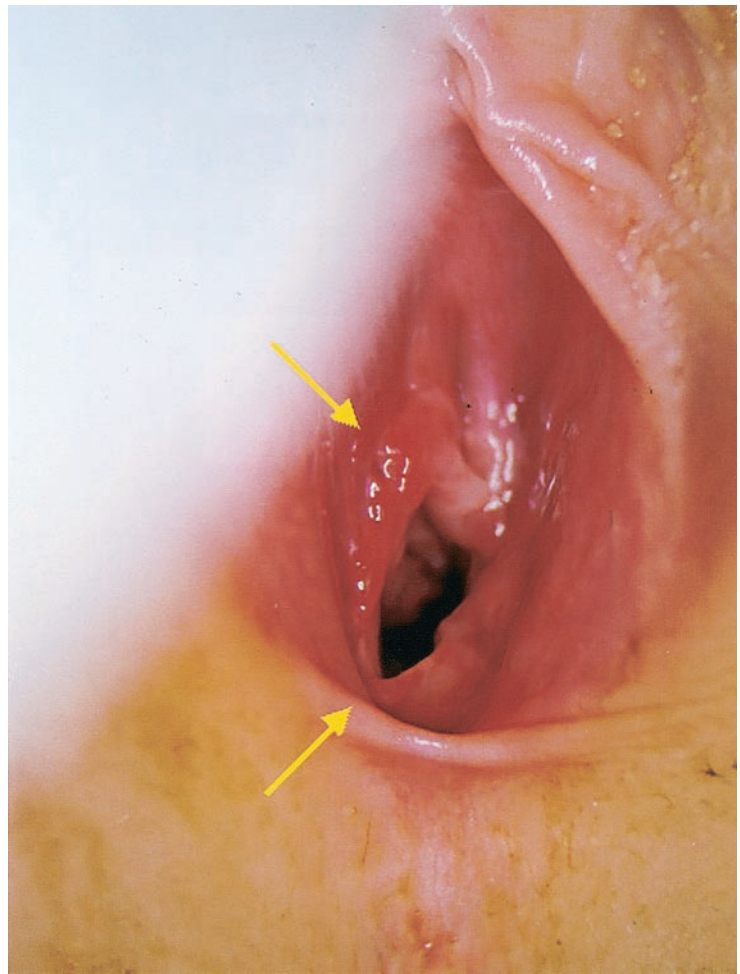
All of the cases were investigated by the local child protection agency and/or law enforcement, and all of the cases were unsubstantiated for any concerns of

sexual abuse. There have been no subsequent sexual abuse reports to date in any of the cases that occurred 3 to 7 years before this writing. It is interesting, however, that in every case there was a lack of supervision contributing to the child's injury, and in 3 families there were subsequent allegations of neglect or physical abuse.

In all 4 cases, the anogenital findings included lacerations to the hymen or anus, much like that described with acute child sexual abuse or nonintentional impalement injury. Three of the cases also had evidence of injury to the external genitalia. Two of the 3 female cases had acute lacerations or hematomas on the hymen and/or posterior vestibule structures as well as injuries to the labia and external genitalia. One female patient had injuries isolated to the anus similar to child sexual abuse or nonintentional anal impalement injury without external genital injury. The 1 male patient had perianal lacerations as well as bruises on the external genitalia. Finally, in the 1 female case with an adequate follow-up examination, the hymen injury healed as a hymen cleft much like that seen in healed hymen trauma from sexual abuse.

In all 4 cases, visual inspection identified the source of the bleeding, but in the 2 cases with hymen injury, the hymen findings were seen only with colposcopy. In 1 case, the hymen injury was not identified by the experienced child sexual abuse exam-

Fig 6. Case 4. Supine position, 8 days postinjury. Healing hymen laceration at 7 o'clock. Healing submucosal hemorrhage at 10 o'clock.



iner using visual inspection nor the gynecologist using speculum examination under general anesthesia. Colposcopy was successfully performed in all cases at the bedside on the hospital ward with the patient assisting in the procedure and with little discomfort.

DISCUSSION

The similarities between the 4 cases demonstrate that young children who suffer a motor vehicle injury in which a low-velocity vehicle runs over the child's torso in a direction with some longitudinal component, the child may suffer anogenital injuries that mimic child sexual abuse. Although the mechanics of this injury is a matter of speculation, we propose 2 theories. In the first, high intraabdominal pressure, resulting from the passage of a tire over the chest and abdomen, causes extrusion of pelvic contents through perineal orifices, forcing distention and laceration of those orifices. In the second, traction on the skin, caused by the tires passing over the pelvis, creates shearing forces, which also produce laceration about the anus and hymenal orifice. Additionally, the anogenital injuries in these 4 cases do not match those commonly seen in straddle injury; therefore, we suggest that the mechanism of anogenital injury from being run over is not direct blunt force to the perineum. In these 4 cases, there also is

no history of impalement related to the motor vehicle incident.

Based on the results of this case series, the examiner can expect anogenital injury in some cases of children run over by low-speed motor vehicles. On close inspection or colposcopy, the examiner may find acute injuries to the posterior vestibule, hymen, and/or the anus. There may also be bruises or abrasions on the external genitalia. When presented with such a case, the examiner may still be concerned about acute sexual abuse and an initial level of questioning would be appropriate. The examiner may request the assistance of CPS or local law enforcement to verify the incident history and to evaluate the family for other indicators of abuse and neglect. If there are no social concerns or disclosures of abuse and the rest of the physical examination reveals no suspicious findings, then, the anogenital injuries can be safely attributed to the motor vehicle trauma.

Further implications of this case series are that evidence of healed hymen trauma can be found long after the acute injury. This would imply that if a female child undergoes a colposcopic examination for sexual abuse or a routine genital examination by her medical provider and is found to have healed hymen trauma, such findings could be explained by a history of being run over by a motor vehicle. As in all of the cases described here, the child would be

expected to have a history of bleeding from the anus or genitals after the injury. The child with healed hymen trauma must also still be interviewed about a history of sexual abuse, but if the case draws no other concerns, the findings can be explained by the history of being run over by a motor vehicle.

The interpretation of this case series does have some limitations. This case series only documents anogenital trauma that mimics the findings of acute sexual abuse as a result of a specific type of motor vehicle trauma. Without further study, the results of this case series cannot be extended to explain acute anogenital injuries as a result of other types of motor vehicle trauma, especially where the child is a passenger.

Finally, our experience also documents that many traumatic hymenal findings may be missed without colposcopy. Visual inspection with the patient awake or under anesthesia seems to be adequate to identify the source of the bleeding, but colposcopy is indicated to provide a more accurate view of the hymen. Follow-up colposcopy will also document whether healed hymen trauma persists from the nonintentional mechanism, and thus prevent subsequent misdiagnosis of sexual abuse.

CONCLUSIONS

Children run over by slow-moving motor vehicles across their torso may have anogenital injuries identical to those sustained in acute child sexual abuse. Sexual abuse should be considered, but if a thorough investigation brings forth no concerns, the explanation of injury as having been run over by a motor vehicle should be accepted as the sole cause of the anogenital injuries. Additionally, as these injuries heal, they can be expected to produce the same changes as those found in victims of child sexual abuse. The findings of this case series, however, cannot be extended to explain anogenital injuries from other types of motor vehicle trauma. As a practical guideline, children who are run over by motor vehicles should be evaluated for anogenital injury and bleeding. If such injury is suspected, the findings will

be best delineated and documented with colposcopy and follow-up examination. Such documentation will prevent later confusion between injuries sustained from being run over by a motor vehicle and injuries from possible subsequent sexual abuse.

REFERENCES

1. Scheidler MG, Shultz BL, Schall L, Ford HR. Mechanisms of blunt perineal injury in female pediatric patients. *J Ped Surg.* 2000;35:1317-1319
2. McCann J, Voris J, Simon M. Genital injuries resulting from sexual abuse: a longitudinal study. *Pediatrics.* 1992;89:307-317
3. Jones LW, Bass DH. Perineal injuries in children. *Br J Surg.* 1991;78:1105-1107
4. Finkel MA. Anogenital trauma in sexually abused children. *Pediatrics.* 1989;84:317-322
5. Wynne JM. Injuries to the genitalia in female children. *S Afr Med J.* 1980;57:47-50
6. Adams JA. Evolution of a classification scale: medical evaluation of suspected child sexual abuse. *Child Maltreat.* 2001;6:31-36
7. Muram D. The medical evaluation in cases of child sexual abuse. *J Pediatr Adolesc Gynecol.* 2001;14:55-64
8. American Academy of Pediatrics Committee on Child Abuse and Neglect. Guidelines for the evaluation of sexual abuse of children: subject review. *Pediatrics.* 1999;103:186-191
9. McCann J, Voris J. Perianal injuries resulting from sexual abuse: a longitudinal study. *Pediatrics.* 1993;91:390-397
10. Pokorny SF, Pokorny WJ, Kramer W. Acute genital injury in the prepubertal girl. *Am J Obstet Gynecol.* 1992;166:1461-1466
11. Dowd MD, Fitzmaurice L, Knapp JF, Mooney D. The interpretation of urogenital findings in children with straddle injuries. *J Pediatr Surg.* 1994;29:7-10
12. Bond GR, Dowd MD, Landsman I, Rimsza M. Unintentional perineal injury in prepubescent girls: a multicenter prospective report of 56 girls. *Pediatrics.* 1995;95:628-631
13. Herrmann B, Crawford J. Genital injuries in prepubertal girls from inline skating accidents. *Pediatrics.* 2002;110(2 Pt 1). Available at: <http://www.pediatrics.org/cgi/content/full/110/2/e16>
14. Lynch JM, Gardner MJ, Albanese CT. Blunt urogenital trauma in prepubescent female patients: more than meets the eye! *Pediatr Emerg Care.* 1995;11:372-375
15. Boos SC. Accidental hymenal injury mimicking sexual trauma. *Pediatrics.* 1999;103:1287-1290
16. Jona JZ. Accidental anorectal impalement in children. *Pediatr Emerg Care.* 1997;13:40-43
17. Okur H, Kucikaydin M, Kazez A, Turan C, Bozkurt A. Genitourinary tract injuries in girls. *B J Urol.* 1996;78:446-449
18. Silen ML, Kokoska ER, Fendya DG, Kurkchubasche AG, Webe TR, Tracy TF. Rollover injuries in residential driveways: age-related patterns of injury. *Pediatrics.* 1999;104(1). Available at: <http://www.pediatrics.org/cgi/content/full/104/1/e7>

Anogenital Injuries in Child Pedestrians Run Over by Low-Speed Motor Vehicles: Four Cases With Findings That Mimic Child Sexual Abuse

Stephen C. Boos, Angela J. Rosas, Cathy Boyle and John McCann

Pediatrics 2003;112:e77

DOI: 10.1542/peds.112.1.e77

Updated Information & Services

including high resolution figures, can be found at:
<http://pediatrics.aappublications.org/content/112/1/e77>

References

This article cites 16 articles, 6 of which you can access for free at:
<http://pediatrics.aappublications.org/content/112/1/e77#BIBL>

Subspecialty Collections

This article, along with others on similar topics, appears in the following collection(s):
Administration/Practice Management
http://www.aappublications.org/cgi/collection/administration:practice_management_sub

Permissions & Licensing

Information about reproducing this article in parts (figures, tables) or in its entirety can be found online at:
<http://www.aappublications.org/site/misc/Permissions.xhtml>

Reprints

Information about ordering reprints can be found online:
<http://www.aappublications.org/site/misc/reprints.xhtml>

American Academy of Pediatrics

DEDICATED TO THE HEALTH OF ALL CHILDREN™



PEDIATRICS®

OFFICIAL JOURNAL OF THE AMERICAN ACADEMY OF PEDIATRICS

Anogenital Injuries in Child Pedestrians Run Over by Low-Speed Motor Vehicles: Four Cases With Findings That Mimic Child Sexual Abuse

Stephen C. Boos, Angela J. Rosas, Cathy Boyle and John McCann

Pediatrics 2003;112:e77

DOI: 10.1542/peds.112.1.e77

The online version of this article, along with updated information and services, is located on the World Wide Web at:

<http://pediatrics.aappublications.org/content/112/1/e77>

Pediatrics is the official journal of the American Academy of Pediatrics. A monthly publication, it has been published continuously since 1948. Pediatrics is owned, published, and trademarked by the American Academy of Pediatrics, 141 Northwest Point Boulevard, Elk Grove Village, Illinois, 60007. Copyright © 2003 by the American Academy of Pediatrics. All rights reserved. Print ISSN: 1073-0397.

American Academy of Pediatrics

DEDICATED TO THE HEALTH OF ALL CHILDREN™

