

# Successful Treatment of Bowenoid Papulosis in a 9-Year-Old Girl With Vertically Acquired Human Immunodeficiency Virus

James C. Godfrey, MD\*; Mary C. Vaughan, MD, MS‡; and Judith V. Williams, MD§

**ABSTRACT.** A 9-year-old black girl with vertically acquired human immunodeficiency virus (HIV) and no history of condyloma acuminata presented with a 4-year history of enlarging and spreading dark brown flat papules in the perineum. Some of the lesions were confluent and extended from the clitoris to the labia majora and posteriorly to the buttocks and perianal region. A biopsy of one of the lesions showed bowenoid features. Our patient had a normal Pap smear, but vaginal and cervical biopsy specimens revealed human papillomavirus type 16.

Therapy with topical imiquimod cream every other day was started, but little improvement was noted after 2 months. Application of 25% podophyllin every 4 to 8 weeks was added, and improvement was noted within 1 month. After 1 year of treatment, the patient had complete resolution of all lesions, and she has had no further appearance of lesions.

Our case emphasizes the need for increased awareness of the potential for development of bowenoid papulosis in HIV-positive children as well as the successful treatment of our patient with topical therapy alone. *Pediatrics* 2003;112:e73–e76. URL: <http://www.pediatrics.org/cgi/content/full/112/1/e73>; *bowenoid papulosis, human papillomavirus, human immunodeficiency virus, vertical transmission, imiquimod, podophyllin, immunocompromised.*

ABBREVIATIONS. HIV, human immunodeficiency virus; HPV, human papillomavirus; LEEP, loop electrosurgical excision procedure.

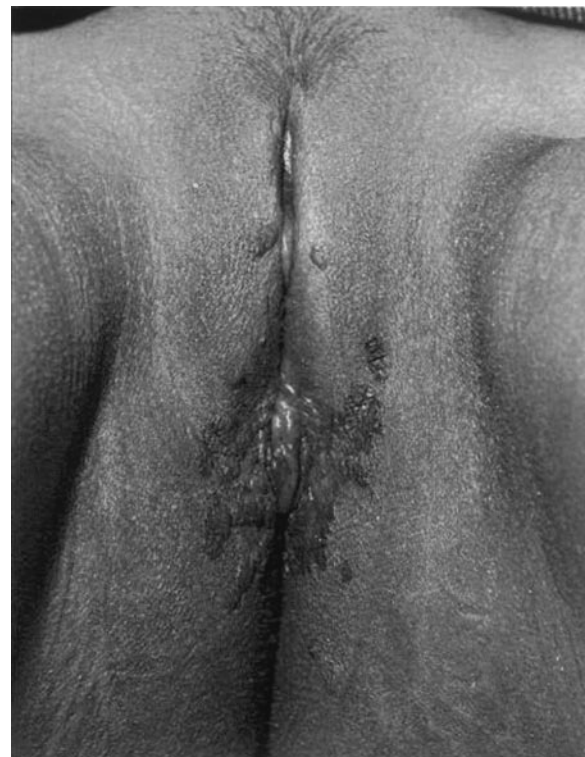**B**owenoid papulosis, an acquired immunodeficiency syndrome-defining illness in adults with human immunodeficiency virus (HIV), has traditionally been thought of as a disease that affects younger sexually active adults ages 20 to 35 years. These lesions usually present as reddish-brown flat papules that can easily be misdiagnosed as condyloma acuminata, lichen planus, seborrheic keratoses, psoriasis, squamous cell carcinomas, basal cell carcinomas, melanomas, or even cutaneous Hodgkin's disease. Bowenoid papulosis, classified as vulvar intraepithelial neoplasia by gynecologic pa-

thologists,<sup>1</sup> has been linked to human papillomavirus (HPV), specifically types 16, 18, 31, 32, 34, 39, 42, 48, 51, 52, 53, and 54 (with type 16 present in an overwhelming majority of cases). Females with this disease are at increased risk for developing cervical dysplasia and invasive neoplasia.<sup>2</sup>

This disease has been reported in a small number of children in the English literature,<sup>3–6</sup> the youngest being a 2-year-old boy. To date, the only other reported case of bowenoid papulosis in a child with HIV was in a 12-year-old girl, also with vertically acquired HIV. In that patient, HPV type 16 was isolated from the involved areas, and she developed invasive vulvar carcinoma requiring surgical excision.<sup>4</sup>

## CASE REPORT

A 9-year-old black girl with HIV presented with a 4-year history of asymptomatic brown papules in the genital area. The patient's past medical history was significant for HIV with the onset of HIV encephalitis at age 4. She also had residual spastic quadriplegic



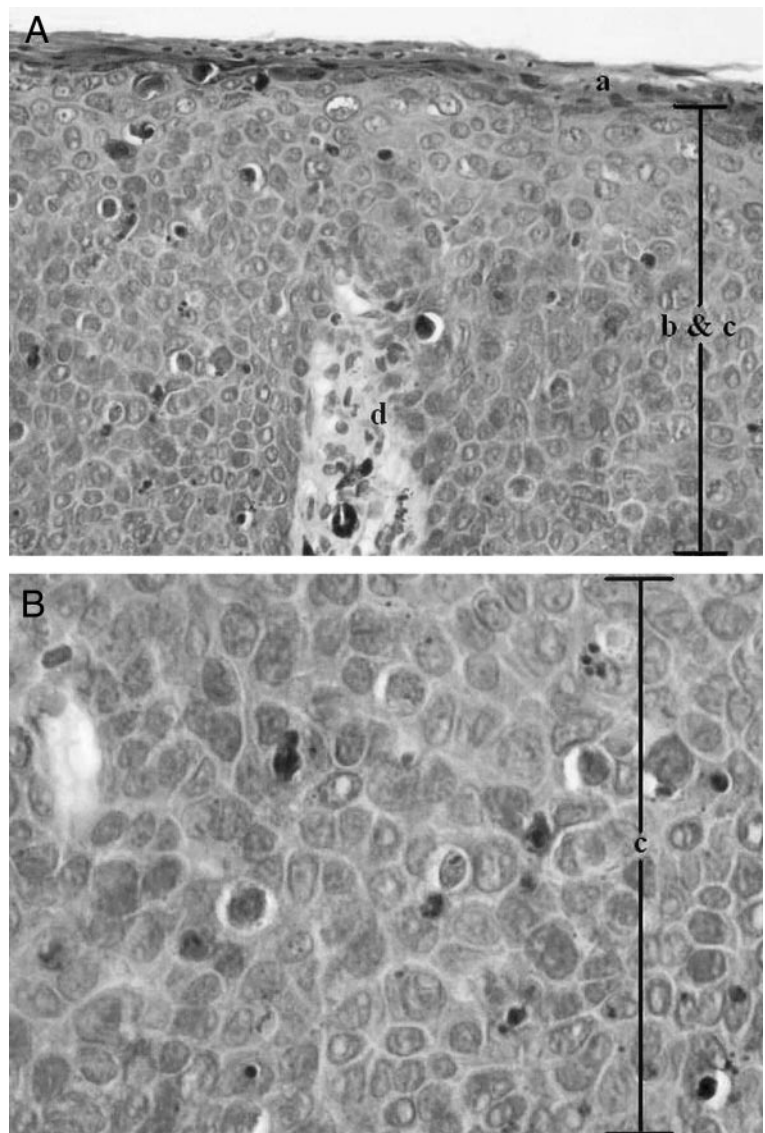
**Fig 1.** Multiple dark-brown papules and confluent plaques are present before initiation of treatment.

From the Departments of \*Pediatrics and §Pediatric Dermatology, Children's Hospital of The King's Daughters, Eastern Virginia Medical School, Norfolk, Virginia; and †Pediatric and Adolescent Gynecology, Eastern Virginia Medical School, Norfolk, Virginia.

Received for publication Dec 18, 2002; accepted Mar 18, 2003.

Address correspondence to James C. Godfrey, MD, Department of Pediatrics, Eastern Virginia Medical School, Children's Hospital of The King's Daughters, 601 Children's Lane, Norfolk, VA 23507-1971. E-mail: jcgodfrey@mindspring.com

PEDIATRICS (ISSN 0031 4005). Copyright © 2003 by the American Academy of Pediatrics.



**Fig 2.** 100× (A) and 400× (B) views stained with hematoxylin and eosin show (a) hyperkeratosis, (b) irregular acanthosis, and (c) full-thickness keratinocytic atypia with (d) an intact basement membrane.

cerebral palsy as a result of neurologic insults from encephalitis. Her antiretroviral therapy regimen at the time of presentation included nelfinavir, stavudine, and lamivudine. Other medications included ranitidine, metoclopramide, haloperidol, loperamide, and baclofen. Her total CD4+ count was 1036 (range: 562-2692) with a CD4+ T-helper cell percentage of 32% (range: 29%–52%), and her viral load was <400 copies per milliliter by polymerase chain reaction. The papular lesions were localized initially and then progressed over 4 years to involve bilateral labia majora, the clitoris, and the perianal region at the time of presentation. Neither our patient nor her mother had a history of condyloma acuminata, although the mother had had an abnormal Pap smear 4 years earlier which required a loop electrosurgical excision procedure. Biopsy specimens from this loop electrosurgical excision procedure yielded HPV of unknown type, but more recent biopsy specimens from the mother revealed HPV types 6, 11, 42, 43, and 44.

Examination of the child revealed multiple dark-brown papules and small confluent plaques on the

right labia majora and extending posteriorly toward the anus (Fig 1). On histologic examination there was hyperkeratosis, irregular acanthosis, and full-thickness keratinocytic atypia with an intact basement membrane, consistent with bowenoid papulosis (Fig 2). HPV typing performed on the tissue obtained at initial biopsy showed HPV type 16. Gynecologic examination under anesthesia showed no evidence of disease extending past the labia majora and clitoris. Her Pap smear was normal. Vaginal and cervical biopsy specimens were sent for HPV typing, with both yielding type 16. Given the mother's position as a reliable caretaker, no further investigation concerning possible sexual abuse was undertaken.

The girl was started on imiquimod cream topically every other day applied by the mother at home as initial treatment. Two months later, no regression of the lesions was noted. Therapy was initiated with 25% podophyllin application by the pediatric dermatologist every 4 to 8 weeks and imiquimod every 1 to 2 days at home as tolerated. Follow-up visits were every 1 to 3 months with the pediatric dermatologist. Complete resolution of lesions occurred after 14

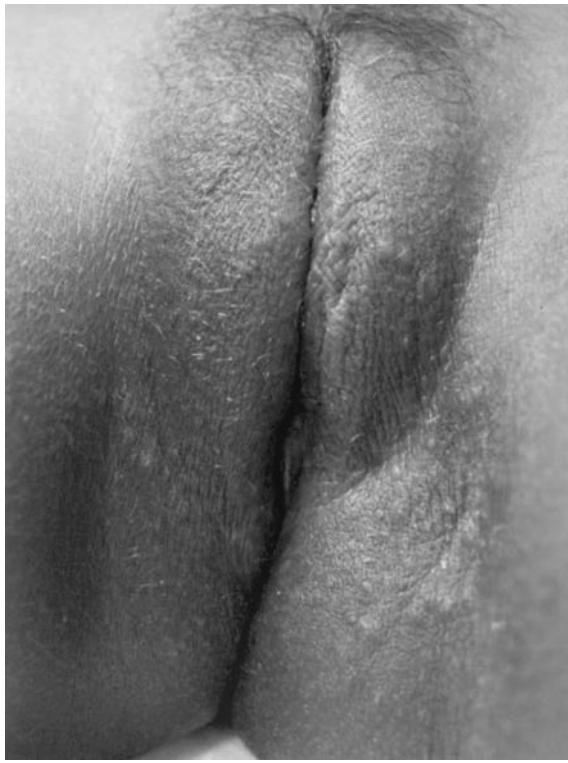

Fig 3. Complete resolution of lesions after 14 months of therapy with topical imiquimod and podophyllin.

months (Fig 3). No dysplastic or neoplastic changes have been noted. To date, our patient has had no recurrence of the lesions on external genital examination, and a repeat gynecologic examination under anesthesia has been scheduled.

#### DISCUSSION

Bowenoid papulosis represents a virus-induced cytopathic change that many consider to be part of a spectrum ranging from condyloma acuminata to carcinoma in situ. As such, treatment for Bowenoid papulosis also consists of a spectrum of conservative topical therapies to more invasive modalities. Some sources argue that bowenoid papulosis, similar to condyloma acuminata, will resolve spontaneously, even after months or years.<sup>2</sup> However, the behavior of HPV cannot be predicted histologically and local invasion seems to be more common in older adult patients and patients who are immunocompromised.<sup>6</sup> Bowenoid papulosis is often resistant to treatment in immunocompromised individuals.<sup>7</sup> Therapy was initiated in our patient to prevent invasive disease.

Local conservative therapies with electrodesiccation, cryosurgery, or scissors excision are documented to be effective.<sup>3</sup> Topical retinoic acid and topical 5-fluorouracil are other local therapeutic options.<sup>3</sup> In addition, argon, Neodymium:YAG, and carbon dioxide lasers have all been shown to be useful therapeutic modalities, with 1 cohort of 8 patients showing complete resolution of lesions with laser therapy alone.<sup>8</sup> A German study showed that interferon- $\gamma$  injection seemed to be effective against bowenoid papulosis.<sup>9</sup>

Topical cidofovir, an acyclic nucleoside phospho-

nate analog with broad-spectrum activity against DNA viruses, has produced resolution of bowenoid lesions in 2 HIV-infected patients after three 5-day courses of therapy.<sup>10,11</sup> We attempted to obtain topical cidofovir for our patient, but the Food and Drug Administration has not approved it for use in the United States.

Podophyllin has been well-established as an effective treatment for external genital warts, which are caused primarily by HPV types 6 and 11.<sup>12</sup> It has also been used effectively in the treatment of Bowen's disease and bowenoid papulosis.<sup>13</sup>

Imiquimod, a potent agent which induces local interferon production, is currently approved for the treatment of anogenital warts in patients 12 years of age or older, but is commonly used in infants and younger children as well.<sup>14</sup> Imiquimod has also been shown to be effective in the treatment of bowenoid papulosis and Bowen's disease. In a cohort of 16 patients with Bowen's disease, Mackenzie-Wood et al<sup>15</sup> reported effective therapy with imiquimod in 14 of the 16 patients and no recurrence in 13 of the 16 patients at 6 months. A case report of a 38-year-old woman for whom topical podophyllin therapy had previously failed also revealed the effectiveness of topical imiquimod in bowenoid papulosis.<sup>16</sup>

To our knowledge, no published data exists addressing the efficacy of podophyllin combined with imiquimod as therapy for HPV-induced skin lesions, such as bowenoid papulosis, as used successfully in our patient.

This case emphasizes the need for heightened awareness of the presentation of bowenoid papulosis in children with vertically acquired HIV, especially if the mother has a previously documented abnormal Pap smear or previously diagnosed HPV-associated cervical or vaginal lesion. Interestingly, the specific HPV types eventually obtained from the mother did not match the specific type found in our patient. It is possible that the mother was a carrier of HPV type 16 at the time of delivery and could have transmitted this strain to the child perinatally.

Nonetheless, children with bowenoid papulosis should undergo a thorough gynecologic examination (under anesthesia if necessary) to evaluate for further invasion of vaginal or cervical tissues, and these examinations should be repeated annually.

Based on the outcome in this case, topical therapy alone may be a reasonable approach to the therapy of bowenoid papulosis in children. In immunocompromised children with bowenoid papulosis, topical therapy may be an appropriate first line therapy, but close follow-up and regular gynecologic examinations are indicated because of the risk for recurrent or invasive disease in this population.

#### REFERENCES

1. Crum CP, Liskow A, Petras P, Keng WC, Frick HC 2nd. Vulvar intraepithelial neoplasia (severe atypia and carcinoma in situ). A clinicopathologic analysis of 41 cases. *Cancer*. 1984;54:1429-1434
2. Schwartz RA, Janniger CK. Bowenoid papulosis. *J Am Acad Dermatol*. 1991;24:261-264
3. Weitzner JM, Fields KW, Robinson MJ. Pediatric bowenoid papulosis: risks and management. *Pediatr Dermatol*. 1989;6:303-305

4. Giaquinto C, Del Mistro A, De Rossi A, et al. Vulvar carcinoma in a 12-year-old girl with vertically acquired human immunodeficiency virus infection. *Pediatrics*. 2000;106(4). Available at: [www.pediatrics.org/cgi/content/full/106/4/e57](http://www.pediatrics.org/cgi/content/full/106/4/e57)
5. Halasz C, Silvers D, Crum C. Bowenoid papulosis in three-year-old girl. *J Am Acad Dermatol*. 1986;14:326–330
6. Stafford EM, Greenberg H, Miles PA. Cervical intraepithelial neoplasia III in an adolescent with bowenoid papulosis. *J Adolesc Health Care*. 1990;11:523–526
7. Feldman SB, Sexton FM, Glenn JD, Lookingbill DP. Immunosuppression in men with bowenoid papulosis. *Arch Dermatol*. 1989;125:651–654
8. Landthaler M, Haina D, Brunner R, Waidelich W, Braun-Falco O. Laser therapy of bowenoid papulosis and Bowen's disease. *J Dermatol Surg Oncol*. 1986;12:1253–1257
9. Gross G, Roussaki A, Papendick U. Efficacy of interferons on bowenoid papulosis and other precancerous lesions. *J Invest Dermatol*. 1990;95(suppl):152S–157S
10. Snoeck R, Van Laethem Y, De Clercq E, De Maubeuge J, Clumeck N. Treatment of a bowenoid papulosis of the penis with local applications of cidofovir in a patient with acquired immunodeficiency syndrome. *Arch Intern Med*. 2001;161:2382–2384
11. Descamps V, Duval X, Grossin M, Crickx B, Leport C. Topical cidofovir for bowenoid papulosis in and HIV-infected patient. *Br J Dermatol*. 2001;144:642–643
12. Schaeen L, Mercurio MG. Treatment of human papilloma virus in a 6-month-old infant with imiquimod 5% cream. *Pediatr Dermatol*. 2001;18:450–451
13. Gross G. Clinical aspects and therapy of anogenital warts and papillomavirus-associated lesions. *Hautarzt*. 2001;52:6–17
14. Moresi JM, Herbert CR, Cohen BA. Treatment of anogenital warts in children with topical 0.05% podofilox gel and 5% imiquimod cream. *Pediatr Dermatol*. 2001;18:448–452
15. Mackenzie-Wood A, Kossard S, de Launey J, Wilkinson B, Owens ML. Imiquimod 5% cream in the treatment of Bowen's disease. *J Am Acad Dermatol*. 2001;44:462–470
16. Petrow W, Gerdson R, Uerlich M, Wilkinson B, Owens ML. Successful topical immunotherapy of bowenoid papulosis with imiquimod. *Br J Dermatol*. 2001;145:1022–1023

**Successful Treatment of Bowenoid Papulosis in a 9-Year-Old Girl With  
Vertically Acquired Human Immunodeficiency Virus**

James C. Godfrey, Mary C. Vaughan and Judith V. Williams

*Pediatrics* 2003;112:e73

DOI: 10.1542/peds.112.1.e73

**Updated Information &  
Services**

including high resolution figures, can be found at:  
<http://pediatrics.aappublications.org/content/112/1/e73>

**References**

This article cites 15 articles, 0 of which you can access for free at:  
<http://pediatrics.aappublications.org/content/112/1/e73#BIBL>

**Permissions & Licensing**

Information about reproducing this article in parts (figures, tables) or  
in its entirety can be found online at:  
<http://www.aappublications.org/site/misc/Permissions.xhtml>

**Reprints**

Information about ordering reprints can be found online:  
<http://www.aappublications.org/site/misc/reprints.xhtml>

American Academy of Pediatrics

DEDICATED TO THE HEALTH OF ALL CHILDREN™



# PEDIATRICS®

OFFICIAL JOURNAL OF THE AMERICAN ACADEMY OF PEDIATRICS

## **Successful Treatment of Bowenoid Papulosis in a 9-Year-Old Girl With Vertically Acquired Human Immunodeficiency Virus**

James C. Godfrey, Mary C. Vaughan and Judith V. Williams

*Pediatrics* 2003;112:e73

DOI: 10.1542/peds.112.1.e73

The online version of this article, along with updated information and services, is  
located on the World Wide Web at:

<http://pediatrics.aappublications.org/content/112/1/e73>

Pediatrics is the official journal of the American Academy of Pediatrics. A monthly publication, it has been published continuously since 1948. Pediatrics is owned, published, and trademarked by the American Academy of Pediatrics, 141 Northwest Point Boulevard, Elk Grove Village, Illinois, 60007. Copyright © 2003 by the American Academy of Pediatrics. All rights reserved. Print ISSN: 1073-0397.

American Academy of Pediatrics

DEDICATED TO THE HEALTH OF ALL CHILDREN™

