

Congenital Salivary Gland Anlage Tumor of the Nasopharynx

Erik G. Cohen, MD*; Michael Yoder, MD‡; Rebecca M. Thomas, MD‡; Denise Salerno, MD, FAAP§; and Glenn Isaacson, MD, FACS, FAAP*

ABSTRACT. *Objective.* Nasal and upper respiratory tract obstruction in the neonatal period can result from a variety of conditions, and may present with variable symptoms. In the absence of dysmorphic features or other abnormalities, causes of nasal obstruction may be difficult to differentiate on initial examination. We report an unexpected and potentially life-threatening condition arising during the work-up of this common neonatal complaint.

Design. Case report with literature review.

Results. A male neonate presented with complaints of nasal obstruction and feeding difficulties. A common diagnostic approach to neonatal nasal obstruction was performed, resulting in an unexpected and potentially life-threatening, albeit curative, result. Cannulation of the nasal cavity to rule out choanal atresia resulted in a burst of bleeding from the nose and mouth. A finger sweep of the oropharynx produced a dislodged mass lesion. Pathology revealed a salivary gland anlage tumor of the nasopharynx.

Conclusions. The diagnosis of a nasopharyngeal mass lesion should be considered in neonates with nasal obstructive symptoms. It is wise to place an index finger in the oropharynx when passing catheters to rule out choanal atresia to feel a dislodged mass lesion before it can become an airway foreign body. Should passage of nasal catheters result in bleeding and/or respiratory distress, the possibility of a displaced mass lesion must be considered immediately to institute prompt intervention. *Pediatrics* 2003;112:e66–e69. URL: <http://www.pediatrics.org/cgi/content/full/112/1/e66>; *nasopharyngeal tumor, salivary gland tumor, congenital tumor, nasal obstruction.*

ABBREVIATIONS. SGAT, salivary gland anlage tumor; EMA, epithelial membrane antigen; CT, computed tomography.

Nasal and upper respiratory tract obstruction in the neonatal period can result from a variety of congenital malformations, inflammatory conditions, hamartomas, and tumors. Obligate nose breathing in neonates makes nasal obstruction potentially life-threatening. Respiratory difficulties may be present at birth, or develop over the first few weeks or months of life. Neonates may present with

symptoms ranging from nasal discharge to feeding difficulties to severe respiratory distress and hypoxia.

The causes of nasal obstruction in the neonatal period are varied. These include bony abnormalities, cystic lesions, meningoencephalocele, glioma, nasal mucosal edema, and several infectious causes. Nasopharyngeal neoplasms less commonly cause nasal obstruction in this age group, but may occur with similar, nonspecific presenting features. In the absence of dysmorphic features or other abnormalities, causes of nasal obstruction may be difficult to differentiate on initial examination.

Salivary gland anlage tumor (SGAT), also referred to as congenital pleomorphic adenoma, is a benign congenital tumor of the nasopharynx, which may produce nasal obstruction and other associated, nonspecific symptoms. We report a case of SGAT causing nasal obstruction and feeding difficulties in the neonatal period. A common diagnostic approach to neonatal nasal obstruction was performed, resulting in an unexpected and potentially life-threatening, albeit curative, result. The differential diagnosis and clinical approach to managing neonates with symptoms of nasal obstruction is discussed.

METHODS

Medical records and pathology reports were retrospectively reviewed. The English language literature was reviewed using a PubMed-based search (www.ncbi.nlm.nih.gov).

A frozen section of the tumor was performed and the diagnosis was made on the routine hematoxylin and eosin-stained permanent sections. Immunohistochemistry was performed for confirmation of the diagnosis, using 5- μ m sections from paraffin-embedded tissue blocks. The staining was performed by the standard avidin-biotin-conjugate technique using antibodies against AE1/AE3 (Zymed, South San Francisco, CA), vimentin (DAKO, Carpinteria, CA), S-100 (DAKO), epithelial membrane antigen (EMA; DAKO) and smooth muscle actin (DAKO).

RESULTS

Case Report

A full-term boy was born by normal spontaneous vaginal delivery. His mother had had no prenatal care. No difficulties were noted immediately after delivery. He weighed 2835 g (6.2 lbs), and APGAR scores were 8 and 9 at 1 minute and 5 minutes, respectively. He presented to the outpatient pediatrics clinic with his mother on day of life 4 for weight follow-up. The mother reported breastfeeding the child without difficulty. Physical examination revealed nasal congestion. He again presented for evaluation on day of life 11. His mother was concerned about his nasal congestion, and complained that he

From the *Department of Otolaryngology-Head and Neck Surgery, Temple University School of Medicine, Philadelphia, Pennsylvania; ‡Department of Pathology and Laboratory Medicine, Temple University Hospital, Philadelphia, Pennsylvania; §Department of Pediatrics, Temple University Children's Medical Center, Philadelphia, Pennsylvania.

Received for publication Nov 5, 2002; accepted Mar 4, 2003.

Reprint requests to (G.L.) Department of Otolaryngology, Temple University School of Medicine, 3400 N Broad St, Kresge West Building, Suite 102, Philadelphia, PA 19140. E-mail: glenn@ent.temple.edu

PEDIATRICS (ISSN 0031 4005). Copyright © 2003 by the American Academy of Pediatrics.

had been spitting up his feedings since day of life 5. He had no history of fever or ill contacts.

During this outpatient visit with his pediatrician (D.S.), pediatric otolaryngology consultation was obtained in the outpatient pediatric clinic. On initial examination, the patient was found to have normal external ears and craniofacial structure. Anterior rhinoscopy was within normal limits. The oral cavity and oropharynx were without clefts or other lesions. The neck had no palpable masses or lymphadenopathy. There was no respiratory distress or stridor noted at rest; however, the patient was mouth breathing.

A flexible suction catheter was then inserted into the nose to rule out choanal atresia. Its passage was anticipated with a finger in the oropharynx. Mild resistance was encountered in the posterior nasal cavity, followed by a burst of bleeding from the nose and mouth. A finger sweep of the pharynx produced a 1.5-cm spherical mass. Bleeding slowed and then stopped spontaneously after several minutes. Immediate resolution of mouth-breathing and improved feeding was seen. The mass was then sent to pathology for frozen section analysis, as well as routine pathologic examination.

An unenhanced computed tomography (CT) scan

of the head and neck was then obtained. There were no defects in the skull base, nor was any residual mass seen in the nasopharynx.

The patient has done well since the mass was removed. A follow-up CT scan of the head revealed no evidence of recurrence or abnormality at 20 months of age.

Pathology

The tumor was a single, firm, roughly spherical mass of tan-yellow tissue with a smooth surface. It measured 1.5 cm in greatest dimension. The cut surface was also firm and tan-yellow. Microscopically, the surface was of thin, nonkeratinizing squamous epithelium; the underlying stroma was composed of spindled cells of variable cellularity (Fig 1A). Embedded in this stroma were squamous islands and duct-like structures, which often blended in with the stroma (Fig 1, B and C). Areas of dense cellularity were occasionally seen (Fig 1D). Mitoses were present, but not prominent. There was no necrosis and no significant pleomorphism. On immunohistochemical studies, the epithelial component was positive for broad-spectrum keratin (AE1/AE3) and EMA. The stromal component was positive for vimentin and smooth muscle actin, with scattered in-

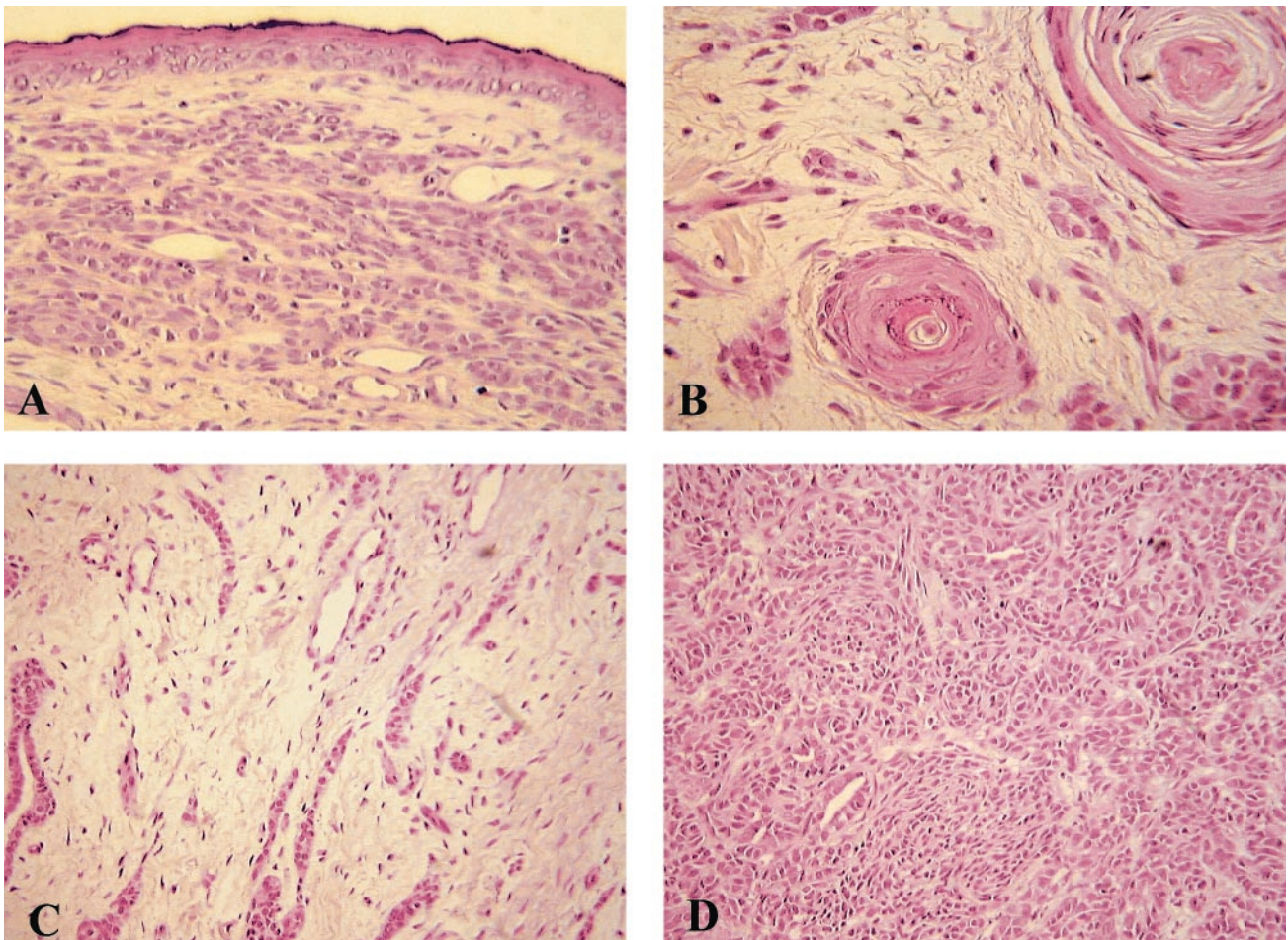


Fig 1. Histopathology of SGAT. A, Surface squamous epithelium with underlying epithelial and stromal elements (magnification 200 \times , hematoxylin and eosin stain). B, The underlying stroma with squamous islands (magnification 200 \times , hematoxylin and eosin stain). C, Loosely cellular stroma with small duct-like structures (magnification 100 \times , hematoxylin and eosin stain). D, Densely cellular area with epithelial and spindled cells (magnification 100 \times , hematoxylin and eosin stain).

dividual cells positive for S-100 protein. The stromal cells also showed patchy staining for AE1/AE3 and EMA.

DISCUSSION

The term, "salivary gland anlage tumor" was introduced in a report by Dehner et al,¹ in 1994. They reported 9 cases involving lesions of the nasopharynx with similar histologic appearance presenting in the neonatal period. One mass was expelled during resuscitation during an episode of respiratory distress, although most cases presented with respiratory and/or feeding difficulties. Several other cases have been reported in the English language literature.²⁻⁴ The first reported case, described as a congenital pleomorphic adenoma, was reported by Har-El et al⁵ in 1985. An earlier report of a squamous proliferative lesion presented in strikingly similar fashion to the current case report, and may represent the same type of lesion.⁶

Clinical features of the published cases of SGAT are summarized in Table 1. Thirteen of 15 cases (87%) have been reported in males. The large majority of cases have presented within the first 2 weeks of life. SGATs have been reported as smooth or nodular, midline nasopharyngeal masses. A narrow pedicle may be attached to the nasopharyngeal mucosa^{1,5} or to the mucosa of the posterior nasal septum.^{1,2,4} No recurrences have been reported after simple excision with 6 months to 6 years follow-up.¹⁻⁶

The pathologic and immunohistochemistry features of the SGAT, as described by Dehner et al,¹ were constant between cases in that report and similar to the case presented here. The histology of the SGAT suggests that of a normally developing sali-

vary gland, with invaginating surface epithelium into mesenchymal tissue, suggesting that SGAT may be a hamartoma, rather than a neoplasm.¹

Symptoms of nasal obstruction from SGAT are similar to nasal obstruction from other causes, and may include sleeping difficulty, feeding problems, episodes of respiratory distress and/or cyanosis, and nasal discharge. Neonates with complete nasal obstruction may have severe respiratory distress which is relieved by crying⁷; however, neonates with even partial nasal obstruction may be symptomatic.⁸ Retractions, stridor, a weak or breathy cry, or respiratory distress not relieved or worse with crying may indicate laryngotracheal abnormalities.

The cause of neonatal nasal obstruction may sometimes be revealed by careful history and physical examination. Maternal history including medication use, substance abuse, and infectious diseases should be elicited. Family history of congenital or childhood abnormalities should be elicited as well.

A child's general appearance may reveal evidence of a congenital abnormality. Neonates with bilateral choanal atresia may have severe respiratory distress and ~75% have other features of the CHARGE association.⁹ Patients with unilateral atresia have associated abnormalities less frequently, but usually present later in life.^{9,10} Patients with nasal pyriform aperture stenosis may have a single, medial upper incisor, and may have midfacial abnormalities and forms of holoprosencephaly.¹¹ Abnormalities such as mandibulofacial dysostosis (eg, Treacher Collins syndrome and Crouzon disease), coronal craniosynostosis, and midfacial and nasal hypoplasia associated with fetal alcohol syndrome may be apparent on

TABLE 1. Clinical Features of Published Cases of SGATs

| Case ^{Reference} | Age | Gender | Clinical Presentation | Size | Procedure | Outcome |
|---------------------------|---------|--------|--|--------------------|-----------------------------------|-------------------------------|
| 1* | 11 d | Male | Nasal congestion, feeding difficulty | 1.5 × 1.5 × 1.5 cm | Expelled during nasal cannulation | NED at 20 mo |
| 2 ⁴ | Newborn | Male | Respiratory and feeding difficulty | 4 × 3 × 2 cm | Transpalatal excision | NED at 5 y |
| 3 ^{1,2} | 8 d | Male | Respiratory distress | 3 × 2 cm | Simple excision | NED at 3 y |
| 4 ² | 2 d | Male | Respiratory and feeding difficulty | 2 × 2 cm | Simple excision | NED at 2 y |
| 5 ² | 1 d | Male | Respiratory distress | 2 × 2 cm | Simple excision | NED at 8 mo |
| 6 ³ | 7 d | Male | Not reported | 3 × 2 × 2 cm | Excision | NED at 2 y |
| 7 ¹ | 6 wk | Male | Respiratory difficulty | 1.5 cm | Simple excision | NED at 5 y |
| 8 ¹ | 7 d | Male | Respiratory difficulty, nasal obstruction | 2.5 × 1.9 × 1.2 cm | Simple excision | NED at 4 y |
| 9 ^{1,5} | 7 d | Male | Respiratory and feeding difficulty | 3 × 2.5 × 1.5 cm | Simple excision | Dead from sepsis at 6 mo, NED |
| 10 ¹ | 6 d | Male | Upper respiratory obstruction | 2.5 × 1.5 × 1.5 cm | Simple excision | NED at 2 y |
| 11 ¹ | 7 d | Male | Upper respiratory obstruction | 3 × 1.8 cm | Simple excision | NED at 6 y |
| 12 ¹ | Newborn | Female | Respiratory difficulty, bleeding | Not reported | Expelled during resuscitation | No follow-up |
| 13 ¹ | 3.5 mo | Female | Respiratory and feeding difficulty | 1.5 × 1 × 0.5 cm | Simple excision | NED at 1 y |
| 14 ¹ | Newborn | Male | Facial plethora, respiratory distress | 1.3 × 1 × 0.5 cm | Simple excision | NED at 3.5 y |
| 15 ⁶ | 1 d | Male | Respiratory difficulty, bleeding after nasal cannulation | 2 × 1.5 cm | Simple excision | NED at 1.5 y |

NED indicates no evidence of disease.

* Current case.

initial inspection, and can cause nasal obstruction.^{12,13}

Anterior rhinoscopy may reveal nasal pyriform aperture stenosis or traumatic septal deviation, which may occur in as many as 1% of newborns.¹⁴ Nasolacrimal duct cysts can also be seen, and may be associated with epiphora.¹⁵ Lack of response of the nasal mucosa to decongestion may indicate rhinitis medicamentosa with chronic use of topical decongestants in the child or vasoactive medications by the mother. Mucopurulent rhinorrhea may indicate congenital syphilis ("snuffles"), whereas *Chlamydial* infection may cause also cause rhinorrhea and obstruction.¹⁰

Neonates with gliomas or skull base defects of the anterior neuropore, eg, meningocele, encephalocele, or meningoencephalocele may present with nonspecific symptoms of nasal obstruction,¹⁶ and may have a normal anterior rhinoscopy. Neonates with hamartomas (eg, SGAT), benign neoplastic lesions (eg, hemangiomas), or rarely, malignant lesions (eg, rhabdomyosarcoma) involving the nasopharynx, may also have nonspecific symptoms of nasal obstruction,^{12,16} and frequently have normal anterior rhinoscopy.

Passage of a soft, flexible suction catheter through the nose, at least 32 mm, can be performed to exclude choanal atresia,¹⁶ as was performed in this case. However, the inability to pass a catheter is not diagnostic of choanal atresia.⁸

Fiber-optic endoscopy after topical decongestion can be useful in visualizing lesions of the posterior nasal cavity and nasopharynx. Radiographic imaging with CT scan can offer valuable information regarding bony anatomy of the skull base and posterior nasal cavity if the diagnosis is unclear. Magnetic resonance imaging can be used selectively to evaluate connections of intranasal lesions with intracranial contents, and other intracranial or soft tissue abnormalities before diagnostic or therapeutic procedures. Endoscopy under general anesthesia may be performed if the diagnosis remains uncertain.

In this case, SGAT was not suspected because it is a relatively uncommon cause of nasal obstruction. A flexible catheter was passed to evaluate patency of the nasal cavity. It is wise to place an index finger in the oropharynx when passing catheters. If the catheter is palpated in the nasopharynx, choanal atresia is definitively ruled-out (ie, the catheter is not coiled in the nose). In addition, masses or foreign bodies will be felt before they can fall into the airway.

SGATs are attached only by a thin, delicate vascular pedicle which may be easily torn, even with gen-

tle probing. These lesions are of sufficient size to cause complete upper airway obstruction. Should passage of nasal catheters result in bleeding and/or respiratory distress, the possibility of a displaced mass lesion acting as an airway foreign body must be considered immediately to institute prompt intervention.

CONCLUSIONS

Nasal obstruction in the neonatal period may be caused by a wide variety of disorders. SGAT is a recently described hamartoma of the nasopharynx, which presents with symptoms that are difficult to differentiate from other causes of nasal obstruction. Potential for dislodgement of this mass from its delicate pedicle with resultant airway obstruction should be considered when assessing the patency of the posterior choanae.

REFERENCES

1. Dehner LP, Valbuena L, Perez-Atayde A, Reddick RL, Askin FB, Rosai J. Salivary gland anlage tumor ("congenital pleomorphic adenoma"): a clinicopathologic, immunohistochemical and ultrastructural study of nine cases. *Am J Surg Pathol*. 1994;18:25-36
2. Boccon-Gibod LA, Grangeponde MC, Boucheron S, Josset PP, Roger G, Berthier-Falissard ML. Salivary gland anlage tumor of the nasopharynx: a clinicopathologic and immunohistochemical study of three cases. *Pediatr Pathol Lab Med*. 1996;16:973-983
3. Michal M, Sokol L, Mukensnabl P. Salivary gland anlage tumor. A case with widespread necrosis and large cyst formation. *Pathology*. 1996;28:128-130
4. Bondeson L, Andreasson L, Olsson M, Rausing A. Salivary gland anlage tumor: cytologic features in a case examined by fine-needle aspiration. *Diagn Cytopathol*. 1997;160:518-521
5. Har-El G, Zirkin HY, Tovi F, Sidi J. Congenital pleomorphic adenoma of the nasopharynx (report of a case). *J Laryngol Otol*. 1985;99:1281-1287
6. Stillwater L, Fee WE. Squamous cell proliferative lesion of the nasopharynx in a newborn. *Otolaryngol Head Neck Surg*. 1980;88:240-247
7. Fearon B, Dickson J. Bilateral choanal atresia in the newborn: plan of action. *Laryngoscope*. 1968;78:1487-1498
8. Shott SR, Myer III CM, Willis R, Cotton RT. Nasal obstruction in the neonate. *Rhinology*. 1989;27:91-96
9. Duncan NO, Miller RH, Catlin FI. Choanal atresia and associated anomalies: the CHARGE association. *Int J Pediatr Otolaryngol*. 1988;15:129-135
10. Coates H. Nasal obstruction in the neonate and infant. *Clin Pediatr*. 1992;31:25-28
11. Van Den Abbeele T, Triglia JM, Francois M, Narcy P. Congenital nasal pyriform aperture stenosis: diagnosis and management of 20 cases. *Ann Otol Rhinol Laryngol*. 2001;110:70-75
12. Bluestone CD, Stool SE, Kenna MA. *Pediatric Otolaryngology*. 3rd ed. Philadelphia, PA: W B Saunders Co; 1996
13. Usowicz AG, Golabi M, Curry C. Upper airway obstruction in infants with fetal alcohol syndrome. *Am J Dis Child*. 1986;140:1039-1041
14. Jaffee BF. Classification and management of anomalies of the nose. *Otolaryngol Clin NA*. 1981;14:989-1004
15. Lusk RP, Muntz HM. Nasal obstruction in the neonate secondary to nasolacrimal duct cysts. *Int J Pediatr Otolaryngol*. 1987;13:315-322
16. Myer III CM, Cotton RT. Nasal obstruction in the pediatric patient. *Pediatrics*. 1983;72:766-777

Congenital Salivary Gland Anlage Tumor of the Nasopharynx
Erik G. Cohen, Michael Yoder, Rebecca M. Thomas, Denise Salerno and Glenn
Isaacson
Pediatrics 2003;112:e66
DOI: 10.1542/peds.112.1.e66

Updated Information & Services

including high resolution figures, can be found at:
<http://pediatrics.aappublications.org/content/112/1/e66>

References

This article cites 15 articles, 1 of which you can access for free at:
<http://pediatrics.aappublications.org/content/112/1/e66#BIBL>

Subspecialty Collections

This article, along with others on similar topics, appears in the following collection(s):
Hematology/Oncology
http://www.aappublications.org/cgi/collection/hematology:oncology_sub

Permissions & Licensing

Information about reproducing this article in parts (figures, tables) or in its entirety can be found online at:
<http://www.aappublications.org/site/misc/Permissions.xhtml>

Reprints

Information about ordering reprints can be found online:
<http://www.aappublications.org/site/misc/reprints.xhtml>

American Academy of Pediatrics

DEDICATED TO THE HEALTH OF ALL CHILDREN™



PEDIATRICS®

OFFICIAL JOURNAL OF THE AMERICAN ACADEMY OF PEDIATRICS

Congenital Salivary Gland Anlage Tumor of the Nasopharynx

Erik G. Cohen, Michael Yoder, Rebecca M. Thomas, Denise Salerno and Glenn Isaacson

Pediatrics 2003;112:e66

DOI: 10.1542/peds.112.1.e66

The online version of this article, along with updated information and services, is located on the World Wide Web at:

<http://pediatrics.aappublications.org/content/112/1/e66>

Pediatrics is the official journal of the American Academy of Pediatrics. A monthly publication, it has been published continuously since 1948. Pediatrics is owned, published, and trademarked by the American Academy of Pediatrics, 141 Northwest Point Boulevard, Elk Grove Village, Illinois, 60007. Copyright © 2003 by the American Academy of Pediatrics. All rights reserved. Print ISSN: 1073-0397.

American Academy of Pediatrics

DEDICATED TO THE HEALTH OF ALL CHILDREN™

