

Kyphosis in a Turner Syndrome Population

Deborah A. Elder, MD*; Mary Gwyn Roper, MD‡; Richard C. Henderson, MD§;
and Marsha L. Davenport, MD‡

ABSTRACT. *Objective.* The purpose of this study was to determine the prevalence of kyphosis in a Turner syndrome (TS) population.

Methods. Standing lateral thoracic spine and standing anterior-posterior (A-P) scoliosis radiographs were obtained on all girls with TS between the ages of 5 and 18 years seen in a TS clinic between July 2000 and March 2001. Medical histories were reviewed, and a pediatric orthopedic surgeon evaluated the radiographs of each patient ($N = 25$). Excessive kyphosis was defined as an A-P curvature $>40^\circ$, vertebral wedging as any A-P deformity $>5^\circ$ at an individual vertebral body, and scoliosis as a lateral curvature $>10^\circ$.

Results. Fifteen (60%) of 25 patients were found to have abnormal radiographic findings: 10 (40%) of 25 with excessive kyphosis, 10 (40%) of 25 with vertebral wedging, and 5 (20%) of 25 with scoliosis. Forty-eight percent of the girls had both excessive kyphosis and/or vertebral body wedging. Two girls had kyphosis $\geq 55^\circ$, and 5 had scoliosis $\geq 25^\circ$. Girls with excessive kyphosis and/or vertebral body wedging were older (13.6 ± 3.9 years vs 10.6 ± 2.8 years).

Conclusions. The prevalence of excessive kyphosis and vertebral body wedging seems to be increased in girls with TS and corresponds with advancing age. Routine radiologic surveillance may facilitate detection of developing deformities so that treatment with a brace can be considered to prevent or slow the process. *Pediatrics* 2002;109(6). URL: <http://www.pediatrics.org/cgi/content/full/109/6/e93>; *Turner syndrome, Scheuermann's disease, kyphosis, scoliosis, skeletal, orthopedics, radiography, spine.*

ABBREVIATIONS. TS, Turner syndrome; A-P, anterior-posterior; BMI, body mass index; GH, growth hormone.

Turner syndrome (TS) is used to describe girls with abnormalities of the X chromosome and associated phenotypic features such as short stature and ovarian failure. Although short stature is the most obvious skeletal abnormality, others such as scoliosis, short neck, cubitus valgus, short fourth metacarpals, and high-arched palate have been well-described.^{1,2} In contrast, kyphosis has rarely been described in TS,^{3,4} and its incidence is unknown. The purpose of this study was to determine the preva-

lence of kyphosis and to explore risk factors for its development in a clinic population of girls with TS.

METHODS

Standing lateral thoracic spine and standing anterior-posterior (A-P) scoliosis radiographs were obtained on girls with TS between the ages of 5 and 18 years seen at the University of North Carolina TS Clinic between July 2000 and March 2001. Eighty-three percent (25/30) of the eligible patients were evaluated. A single pediatric orthopedic surgeon reviewed the radiographs of each patient. Excessive kyphosis was defined as an A-P curvature $>40^\circ$, vertebral wedging as an A-P deformity $>5^\circ$ at any individual vertebral body, and scoliosis as a lateral curvature $>10^\circ$. The presence of either excessive kyphosis or vertebral body wedging was referred to as excessive kyphosis/wedging. A chart review was performed to ascertain the following information: karyotype, age, height, weight, body mass index (BMI), BMI percentile for age, and use and duration of growth hormone (GH), oxandrolone, and/or estrogen treatments. BMI was calculated as weight/height² (kg/m²) and BMI percentiles from charts provided in 2000 by the Centers for Disease Control and Prevention.

Descriptive data are expressed as mean \pm standard deviation. Stepwise logistic regression was performed on the above variables (karyotype, BMI percentile for age, and use or duration of GH, oxandrolone, and estrogen treatments) to determine whether they were significant predictors of kyphosis or kyphosis/wedging. A linear regression analysis was used to determine whether the same variables were significant predictors of degrees of kyphosis. For the latter analysis, 2 girls who had previously undergone bracing for scoliosis were excluded. Analyses were performed using the SAS program (Cary, NC).

RESULTS

The study population ($N = 25$) had a mean age of 12.0 ± 3.6 years. Sixty percent of these girls with TS had a 45X karyotype. Eighty percent of the participants had received GH therapy, 40% had received oxandrolone, and 36% had been exposed to estrogens (Tanner II breasts or exogenous). The mean ages at initiation of GH, oxandrolone, and estrogens were 6.7 years, 11.8 years, and 13.3 years, respectively. BMI percentile increased with age. Fifty-two percent of the overall population were overweight (BMI percentile $\geq 85\%$), and 28% were obese (BMI percentile $\geq 95\%$).

Sixty percent of the girls with TS (15/25) had abnormal radiographic findings. Forty percent (10/25) had excessive kyphosis, 40% (10/25) had vertebral wedging, and 20% (5/25) had scoliosis (Table 1). Forty-eight percent (12/25) of the girls had excessive kyphosis/wedging. Two girls had kyphosis $\geq 55^\circ$ and were treated with anterior-posterior spinal fusion (Figs 1 and 2). All 5 girls with scoliosis had curves $\geq 20^\circ$; 2 were treated with a brace, and 1 with spinal fusion. Of the 5 individuals with scoliosis, 2 had excessive kyphosis/wedging and 3 did not.

Girls who had excessive kyphosis/wedging were

From the *Division of Endocrinology, Children's Hospital Medical Center, Cincinnati, Ohio; and the Departments of ‡Pediatrics and §Orthopaedics, University of North Carolina at Chapel Hill, Chapel Hill, North Carolina. Received for publication Oct 30, 2001; accepted Feb 20, 2002.

Reprint requests to (M.L.D.) University of North Carolina at Chapel Hill, Department of Pediatrics, Division of Endocrinology, CB 7220 509 Burnett-Womack, Chapel Hill, NC 27599. E-mail: mld@med.unc.edu
PEDIATRICS (ISSN 0031 4005). Copyright © 2002 by the American Academy of Pediatrics.

TABLE 1. Spinal Abnormalities by Age

Patient Number	Age (Years)	BMI Percentile	Kyphosis (Degrees)	Wedging	Scoliosis (Degrees)
1	5.3	95	35	-	-
2	5.9	56	41	T7, T8	-
3	6.1	58	35	T7, T8	-
4	6.4	85	30	-	-
5	7.9	7	28	-	-
6	9.2	44	36	-	-
7*	9.8	82	8	-	33
8	10.0	81	34	-	-
9	10.8	45	35	-	-
10*†	11.5	58	19	-	65
11	11.6	99	43	T4, T6, T7	-
12	13.1	92	22	-	25
13	13.3	80	27	-	-
14	13.4	90	29	-	-
15	13.4	94	41	-	-
16	13.5	87	36	-	-
17	13.5	96	25	-	-
18#	14.2	95	59	T10-L1	-
19	14.4	75	43	T6, T8, T12, L1	-
20	14.7	92	43	T12, L1	-
21	15.1	98	33	T12, L1	20
22	16.4	81	47	T11, T12	-
23	17.0	58	41	-	23
24	17.1	97	55	T11, T12	-
25†	17.4	98	60	T10-L1	-

* Scoliosis treated with brace, resulting in a decreased kyphotic curvature.

† Spinal abnormality treated with surgery.

older (13.6 ± 3.9 vs 10.6 ± 2.8 years) than those who did not. All girls older than 14 years of age ($N = 8$) had excessive kyphosis/wedging (Table 1). Seventy-five percent (9/12) of the girls with excessive kyphosis/wedging had a 45,X karyotype versus 46% (6/13) who did not.

Logistic regression revealed that chronological age alone was predictive of the presence of excessive kyphosis/wedging ($P = .053$). By stepwise linear regression analysis, chronological age was also predictive of the degrees of kyphosis ($P = .032$; $r^2 = 0.24$). No other variables (karyotype, BMI percentile for age, presence of scoliosis, use and duration of GH, oxandrolone, and estrogen treatments) were predictive of the presence of excessive kyphosis/wedging or degree of kyphosis (Table 2).

DISCUSSION

Our study suggests that the prevalence of vertebral wedging and excessive kyphosis in the TS population is high. Irregular vertebral epiphyseal growth rings and anterior vertebral wedging in TS

were first reported in the Polish medical literature in the late 1950s.⁵ In 1968, additional reports appeared in the American⁶ and German orthopedic literature.³ In these studies, 22 of 39 subjects with TS ages 12 to 50 years (mean age: 27 years)⁶ and 11 of 22 subjects with TS older than 12 years of age,³ respectively, were reported to have abnormalities of the vertebral epiphyseal rings ("Scheuermann-like disease"). In the latter study, 5 of the patients were reported to have kyphosis. More recent orthopedic reviews of TS state that abnormalities of the vertebral epiphyseal rings rarely cause significant kyphosis or pain,^{7,8} and general reviews of TS rarely mention vertebral wedging or kyphosis at all.

In the present study, 48% of girls with TS in a population ranging in age from 5 to 18 had kyphosis $>40^\circ$, a prevalence markedly increased compared with the reported prevalence of 3% in a general population of school-aged children.⁹ The cause and natural history of structural kyphosis remain controversial, even in the general population. However, most researchers agree that mechanical factors, osteoporosis, and the adolescent growth spurt are major determinants.^{10,11} In TS, the cause of kyphosis seems to be multifactorial and is likely to include the above factors, an intrinsic bone defect, and hormonally induced growth spurts.

Individuals with TS have bone growth abnormalities that result in short stature, abnormal body proportions, growth plate and epiphyseal irregularities, abnormal fusion of bones, variably delayed maturation of bones, and osteopenia.^{7,12} These skeletal disturbances are attributable, at least in part, to haploinsufficiency of pseudoautosomal genes on the X chromosome, such a SHOX, a transcription factor that is expressed in the developing limbs,¹³ the first

TABLE 2. Comparison of Potential Risk Factors in Girls With Kyphosis/Wedging and Those Without Kyphosis/Wedging

Variable	Girls With Kyphosis/Wedging Mean \pm SD ($n = 12$)	Girls Without Kyphosis/Wedging Mean \pm SD ($n = 13$)
Age (y)	13.6 \pm 3.9	10.6 \pm 2.8
BMI for age (%)	83.4 \pm 17.3	72.5 \pm 26.5
Duration of estrogen (y)	1.0 \pm 1.3	0.4 \pm 0.1
Duration of GH (y)	4.14 \pm 3.6	3.3 \pm 2.2
Duration of oxandrolone (y)	1.4 \pm 1.5	0.4 \pm 1.0

SD indicates standard deviation.

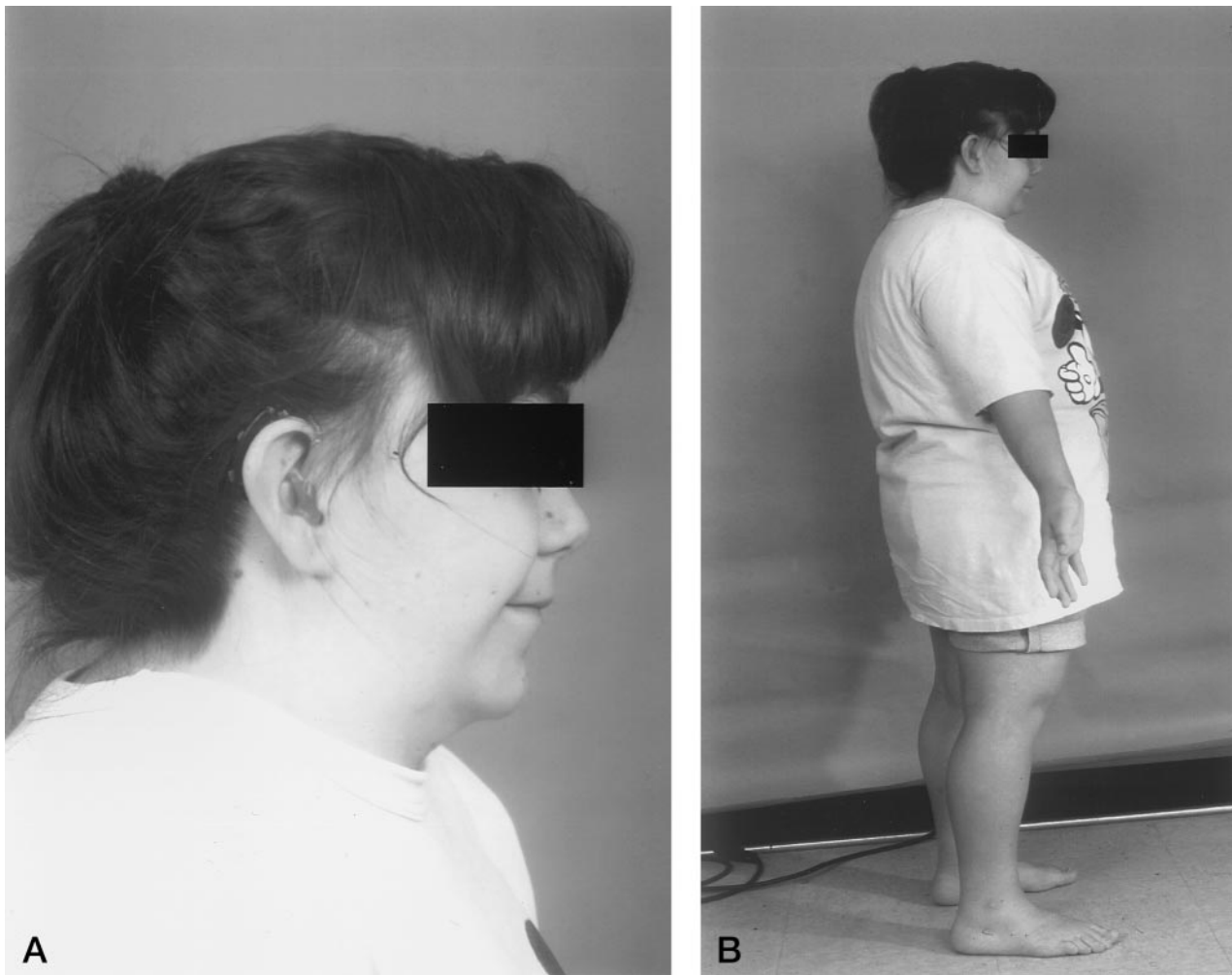

Fig 1. Lateral views of an adolescent with TS and excessive kyphosis.

and second pharyngeal arches, and in bone marrow.¹⁴

In TS, body proportions of the torso are abnormal, because there is a greater relative reduction in body height than in body width.¹⁵ Developmental abnormalities of individual bones that may affect the spine include hypoplasia of cervical vertebrae, coalition of vertebrae and hemivertebrae, although these were not found in our study population. One might also hypothesize that variability in rate of bone maturation, a phenomenon well documented for bones in the hand,¹⁶ may also occur in the spine and lead to abnormal mechanical stresses. Finally, osteoporosis is more common in individuals with TS.¹² Even in the prepubertal years, many girls have a coarse trabecular bone pattern and decreased bone deposition at primarily cortical sites. During adolescence, there is increased bone turnover with osteopenia predominantly at trabecular sites such as the vertebrae.¹⁷ Abnormally low levels of estrogens secondary to gonadal dysgenesis and delays in estrogen replacement therapy no doubt contribute to this increased bone turnover state. Abnormalities of bone content and structure can alter the strength and mechanics of the spine, predisposing individuals to kyphosis as well as scoliosis.

Although most girls with TS undergo a blunted adolescent growth spurt, growth velocity is increased with GH therapy. Although one might predict that kyphosis would progress with increased growth-enhancing therapies, GH might have a protective effect by increasing bone mineral density.^{17,18}

In the present study, girls with structural kyphosis and vertebral wedging were older (average age: 13.6 years) than those without these abnormalities (average age: 10.6 years). However, this study was unable to determine the role of age and hormonal therapies in the development of kyphosis because of the small number of subjects, most of whom had received GH with or without estrogen and oxandrolone.

Early detection and treatment of kyphosis are important. Possible sequelae of excessive kyphosis include progressive deformity, back pain, and embarrassment about physical appearance. In extreme cases, impairment of neurologic and cardiopulmonary function can occur. Although treatment recommendations vary, bracing is generally recommended for progressive kyphosis $\geq 50^\circ$ in a skeletally immature patient.¹⁹ Surgical correction is considered for larger curves, particularly if the deformity is expected to worsen with continued growth.

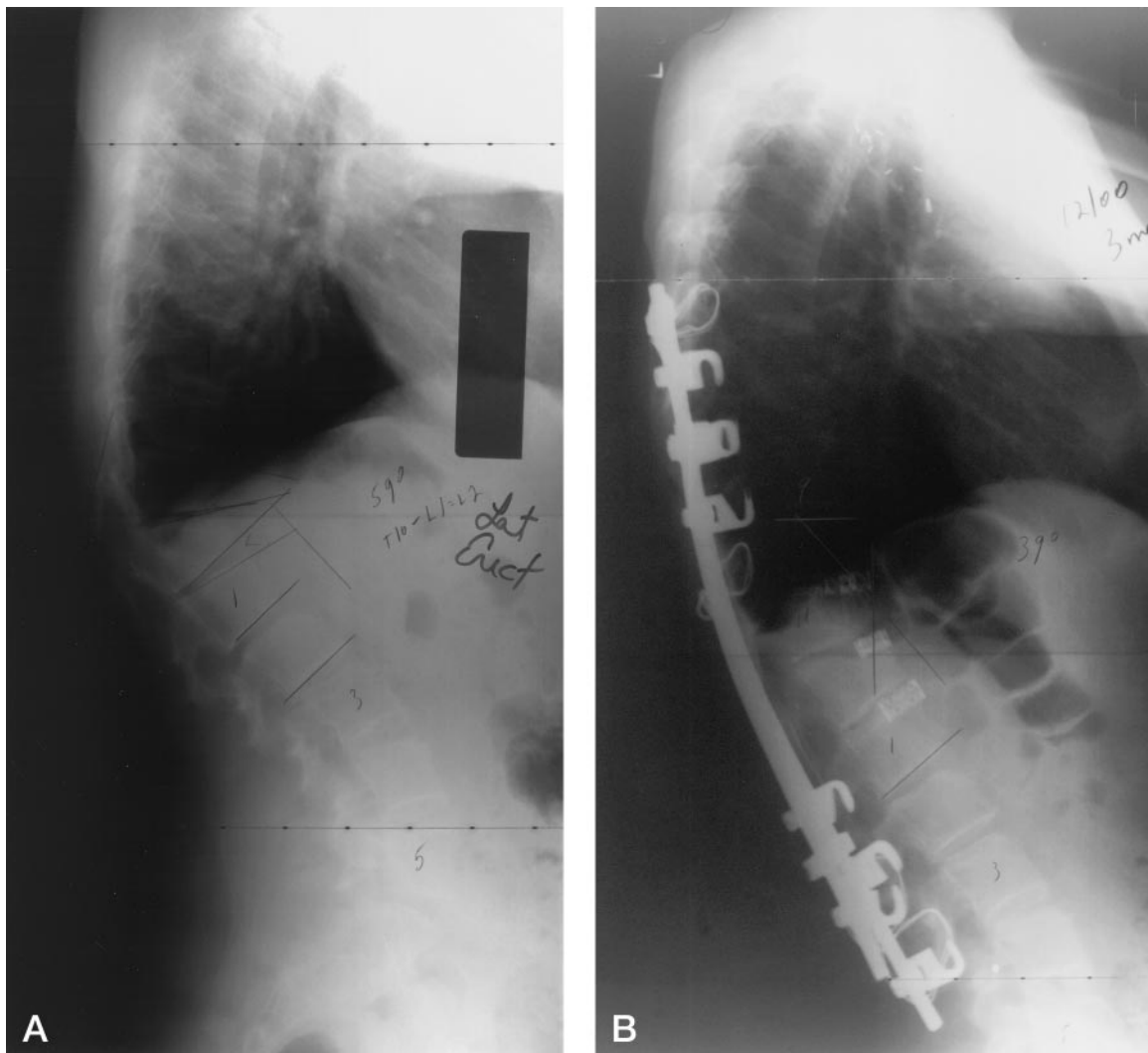


Fig 2. A, Kyphosis of 60°. B, After anterior and posterior spinal fusion.

CONCLUSION

The prevalence of excessive kyphosis and vertebral body wedging seems to be increased in TS and to correlate with advancing age in childhood. Larger, longitudinal studies are needed to determine the relative roles that intrinsic bone defects, obesity, osteopenia, growth-promoting agents, and sex steroid therapy play in the development of excessive kyphosis. The phenotype (short neck, stocky build) of many girls with TS may hinder the clinical diagnosis of kyphosis. Routine radiologic surveillance may be indicated to aid in its early detection and allow for timely implementation of bracing. Although such radiographs seem to be most informative during adolescence, optimal timing of radiologic surveillance has yet to be established.

ACKNOWLEDGMENTS

We thank Dr Ali S. Calikoglu for his insightful comments and editing of this manuscript, and Lauren Lindblad, BS, and Paul W. Stewart, PhD, for statistical expertise.

REFERENCES

1. Lippe BM. Turner syndrome. In: Sperling MA, ed. *Pediatric Endocrinology*. Philadelphia, PA: WB Saunders Co; 1996:387–421
2. Saenger P. Turner's syndrome. *N Engl J Med*. 1996;335:1749–1754
3. Muller G, Gschwend N. Endocrine disorders and Scheuermann's disease. *Arch Orthop Unfallchir*. 1969;65:357–362
4. al Attas RA, Rahi AH, Ahmed E. Common variable immunodeficiency with CD4+ T lymphocytopenia and overproduction of soluble IL-2 receptor associated with Turner's syndrome and dorsal kyphoscoliosis. *J Clin Pathol*. 1997;50:876–879
5. Kosowicz J. Skeletal changes in Turner's syndrome and their significance in differential diagnosis. *Polish Med Hist Sc Bull*. 1959;2:23–26
6. Preger L, Steinbach HL, Moskowitz P, Scully AL, Goldberg MB. Roentgenographic abnormalities in phenotypic females with gonadal dysgenesis. *AJR Am J Roentgenol*. 1968;104:899–910
7. Beals RK. Orthopedic aspects of the XO (Turner's) syndrome. *Clin Orthop*. 1973;97:19–30
8. Lubin MB, Gruber HD, Rimoin DL, Lachman RS. Skeletal abnormalities in Turner syndrome. In: Rosenfeld RG, Grumbach MM, eds. *Turner Syndrome*. New York, NY: Marcel Dekker Inc; 1990:281–300
9. Ascani E, Salsano V, Giglio G. The incidence and early detection of spinal deformities. A study based on the screening of 16,104 schoolchildren. *Ital J Orthop Traumatol*. 1977;3:111–117
10. Wenger DR, Frick SL. Scheuermann kyphosis. *Spine*. 1999;24:2630–2639
11. Nissinen M. Spinal posture during pubertal growth. *Acta Paediatr*. 1995; 84:308–312
12. Gravholt CH, Juul S, Naeraa RW, Hansen J. Morbidity in Turner syndrome. *J Clin Epidemiol*. 1998;51:147–158
13. Blaschke RJ, Rappold GA. SHOX: Growth, Leri-Weill and Turner syndromes. *Trends Endocrinol Metab*. 2000;11:227–230
14. Clement-Jones M, Schiller S, Rao E, et al. The short stature homeobox

- gene SHOX is involved in skeletal abnormalities in Turner syndrome. *Hum Mol Genet.* 2000;9:695–702
15. Gravholt CH, Naeraa RW. Reference values for body proportions and body composition in adult women with Ullrich-Turner syndrome. *Am J Med Genet.* 1997;72:403–408
 16. Even L, Bronstein V, Hochberg Z. Bone maturation in girls with Turner's syndrome. *Eur J Endocrinol.* 1998;138:59–62
 17. Rubin K. Turner syndrome and osteoporosis: mechanisms and prognosis. *Pediatrics.* 1998;102(suppl):481–485
 18. Sato N, Nimura A, Horikawa R, Katumata N, Tanae A, Tanaka T. Bone mineral density in Turner syndrome: relation to GH treatment and estrogen treatment. *Endocrinol J.* 2000;47(suppl):S115–S119
 19. Freeman BLI. Scoliosis and kyphosis. In: Canale ST, ed. *Campbell's Operative Orthopaedics.* St Louis, MO: Mosby Inc; 1998:2941–2947

Kyphosis in a Turner Syndrome Population

Deborah A. Elder, Mary Gwyn Roper, Richard C. Henderson and Marsha L. Davenport

Pediatrics 2002;109:e93

DOI: 10.1542/peds.109.6.e93

Updated Information & Services

including high resolution figures, can be found at:
<http://pediatrics.aappublications.org/content/109/6/e93>

References

This article cites 16 articles, 2 of which you can access for free at:
<http://pediatrics.aappublications.org/content/109/6/e93#BIBL>

Subspecialty Collections

This article, along with others on similar topics, appears in the following collection(s):
Genetics
http://www.aappublications.org/cgi/collection/genetics_sub
Rheumatology/Musculoskeletal Disorders
http://www.aappublications.org/cgi/collection/rheumatology:musculoskeletal_disorders_sub

Permissions & Licensing

Information about reproducing this article in parts (figures, tables) or in its entirety can be found online at:
<http://www.aappublications.org/site/misc/Permissions.xhtml>

Reprints

Information about ordering reprints can be found online:
<http://www.aappublications.org/site/misc/reprints.xhtml>

American Academy of Pediatrics

DEDICATED TO THE HEALTH OF ALL CHILDREN™



PEDIATRICS®

OFFICIAL JOURNAL OF THE AMERICAN ACADEMY OF PEDIATRICS

Kyphosis in a Turner Syndrome Population

Deborah A. Elder, Mary Gwyn Roper, Richard C. Henderson and Marsha L. Davenport

Pediatrics 2002;109:e93

DOI: 10.1542/peds.109.6.e93

The online version of this article, along with updated information and services, is located on the World Wide Web at:

<http://pediatrics.aappublications.org/content/109/6/e93>

Pediatrics is the official journal of the American Academy of Pediatrics. A monthly publication, it has been published continuously since 1948. Pediatrics is owned, published, and trademarked by the American Academy of Pediatrics, 141 Northwest Point Boulevard, Elk Grove Village, Illinois, 60007. Copyright © 2002 by the American Academy of Pediatrics. All rights reserved. Print ISSN: 1073-0397.

American Academy of Pediatrics

DEDICATED TO THE HEALTH OF ALL CHILDREN™

