

# Severe Nutritional Deficiencies in Toddlers Resulting From Health Food Milk Alternatives

Norman F. Carvalho, MBChB; Richard D. Kenney, MD; Paul H. Carrington, MMSc, PA-C; and David E. Hall, MD

**ABSTRACT.** It is widely appreciated that health food beverages are not appropriate for infants. Because of continued growth, children beyond infancy remain susceptible to nutritional disorders. We report on 2 cases of severe nutritional deficiency caused by consumption of health food beverages. In both cases, the parents were well-educated, appeared conscientious, and their children received regular medical care. Diagnoses were delayed by a low index of suspicion. In addition, nutritional deficiencies are uncommon in the United States and as a result, US physicians may be unfamiliar with their clinical features.

Case 1, a 22-month-old male child, was admitted with severe kwashiorkor. He was breastfed until 13 months of age. Because of a history of chronic eczema and perceived milk intolerance, he was started on a rice beverage after weaning. On average, he consumed 1.5 L of this drink daily. Intake of solid foods was very poor. As this rice beverage, which was fallaciously referred to as rice milk, is extremely low in protein content, the resulting daily protein intake of 0.3 g/kg/day was only 25% of the recommended dietary allowance. In contrast, caloric intake was 72% of the recommended energy intake, so the dietary protein to energy ratio was very low.

A photograph of the patient after admission illustrates the typical features of kwashiorkor: generalized edema, hyperpigmented and hypopigmented skin lesions, abdominal distention, irritability, and thin, sparse hair. Because of fluid retention, the weight was on the 10th percentile and he had a rotund sugar baby appearance. Laboratory evaluation was remarkable for a serum albumin of 1.0 g/dL (10 g/L), urea nitrogen <0.5 mg/dL (<0.2 mmol/L), and a normocytic anemia with marked anisocytosis. Evaluation for other causes of hypoalbuminemia was negative.

Therapy for kwashiorkor was instituted, including gradual refeeding, initially via a nasogastric tube because of severe anorexia. Supplements of potassium, phosphorus, multivitamins, zinc, and folic acid were provided. The patient responded dramatically to refeeding with a rising serum albumin and total resolution of the edema within 3 weeks. At follow-up 1 year later he continued to do well on a regular diet supplemented with a milk-based pediatric nutritional supplement.

The mortality of kwashiorkor remains high, because of complications such as infection (kwashiorkor impairs cellular immune defenses) and electrolyte imbalances

with ongoing diarrhea. Children in industrialized countries have developed kwashiorkor resulting from the use of a nondairy creamer as a milk alternative, but we were unable to find previous reports of kwashiorkor caused by a health food milk alternative. We suspect that cases have been overlooked.

Case 2, a 17-month-old black male, was diagnosed with rickets. He was full-term at birth and was breastfed until 10 months of age, when he was weaned to a soy health food beverage, which was not fortified with vitamin D or calcium. Intake of solid foods was good, but included no animal products. Total daily caloric intake was 114% of the recommended dietary allowance. Dietary vitamin D intake was essentially absent because of the lack of vitamin D-fortified milk. The patient lived in a sunny, warm climate, but because of parental career demands, he had limited sun exposure. His dark complexion further reduced ultraviolet light-induced endogenous skin synthesis of vitamin D.

The patient grew and developed normally until after his 9-month check-up, when he had an almost complete growth arrest of both height and weight. The parents reported regression in gross motor milestones. On admission the patient was unable to crawl or roll over. He could maintain a sitting position precariously when so placed. Conversely, his language, fine motor-adaptive, and personal-social skills were well-preserved. Generalized hypotonia, weakness, and decreased muscle bulk were present. Clinical features of rickets present on examination included: frontal bossing, an obvious rachitic rosary (photographed), genu varus, flaring of the wrists, and lumbar kyphoscoliosis. The serum alkaline phosphatase was markedly elevated (1879 U/L), phosphorus was low (1.7 mg/dL), and calcium was low normal (8.9 mg/dL). The 25-hydroxy-vitamin D level was low (7.7 pg/mL) and the parathyroid hormone level was markedly elevated (114 pg/mL). The published radiographs are diagnostic of advanced rickets, showing diffuse osteopenia, frayed metaphyses, widened epiphyseal plates, and a pathologic fracture of the ulna. The patient was treated with ergocalciferol and calcium supplements. The published growth chart demonstrates the dramatic response to therapy. Gross motor milestones were fully regained within 6 months. The prominent neuromuscular manifestations shown by this patient serve as a reminder that rickets should be considered in the differential diagnosis of motor delay.

Nutritional rickets remained a major pediatric health scourge in the United States until the late 1920s, when vitamin D fortification of commercially prepared milk was introduced. Milk remains the main source of exogenous vitamin D for toddlers. It is prudent to ensure that any beverage given to a toddler in place of milk is fortified with vitamin D. These nutritional diseases, which are associated with considerable morbidity and possible

From Scottish Rite Pediatric and Adolescent Consultants, Children's Healthcare of Atlanta, Atlanta, Georgia.

Received for publication Jul 17, 2000; accepted Dec 19, 2000.

Reprint requests to (N.F.C.) Children's Healthcare of Atlanta at Scottish Rite, 1001 Johnson Ferry Rd, Atlanta, GA 30342-1600. E-mail: drnorm@aol.com

PEDIATRICS (ISSN 0031 4005). Copyright © 2001 by the American Academy of Pediatrics.

mortality, are entirely preventable. A dietary history and, when necessary, dietary counseling remains an essential component of health maintenance visits. The health food beverages used by these families stated on the container that they were not intended for use as infant formulas. We contend that beverages not containing appropriate quantities of protein, vitamins, and minerals for toddlers, which could be reasonably perceived as milk alternatives by the public, should carry a warning label as to their inappropriateness for this age group. *Pediatrics* 2001; 107(4). URL: <http://www.pediatrics.org/cgi/content/full/107/4/e46>; rickets, kwashiorkor, nutrition disorders, deficiency diseases, soy proteins, rice, beverages, health food, specialized foods, milk.

ABBREVIATIONS. CRP, C-reactive protein; RDA, recommended dietary allowance.

Severe nutritional deficiencies are common in developing countries.<sup>1,2</sup> In the United States, although poverty occurs, social nutritional programs ensure the availability of food. As a result, nutritional ignorance rather than simple food deprivation is involved in a significant proportion of reported cases of severe undernutrition in the United States.<sup>3-5</sup> By providing regular screening, nutritional education, and supplemental nutrition, the Special Supplemental Nutrition Program for Women, Infants, and Children has successfully reduced the prevalence of undernutrition.<sup>6</sup> US physicians may now be unfamiliar with the clinical features of specific nutritional deficiencies. Cases described in the literature are often diagnosed at an advanced stage, after they were initially overlooked.<sup>3,7,8</sup> The 2 patients reported below were detected at a late stage despite regular medical care. Although the relative rarity of these conditions is a welcome situation, these conditions are not yet extinct in our society.<sup>3-5,7-14</sup> A heightened level of vigilance is required so that nutritional deficiency, which may result in severe life-threatening complications, is not overlooked.

## CASE REPORTS

### Case 1

A 22-month-old male child was admitted with a diagnosis of kwashiorkor. He had had intermittent eczema since 2 weeks of age. He came from a middle-class, well-educated family with a stable social environment.

He was almost exclusively breastfed until ~13 months of age. Soft foods, such as cereal and vegetables, were offered starting at 5 months of age, but typically, he ate only 1 or 2 teaspoonfuls a day. After weaning, he was given whole cow's milk. His mother attributed several episodes of vomiting to the milk. Furthermore, she was concerned that the milk would worsen his eczema. Therefore, she discontinued the whole milk and started a rice beverage, which she inaccurately named rice milk.

On average he consumed 1.5 L of the rice drink daily but continued to typically eat only 2 teaspoonfuls of solid foods per day. His daily protein intake was estimated to be 3 g (2.6 g of protein from the rice drink and 0.4 g of protein from other sources). Average daily caloric intake was 790 calories per day (780 calories from the rice drink and 10 calories from other sources).

The patient reportedly grew well during infancy, but poor weight gain had been noted during the second year of life. At ~21 months of age, he developed intermittent periorbital swelling, which later progressed to anasarca. He developed worsening skin lesions (assumed to be worsening of his eczema). His hair became thinner and sparse. Two weeks before admission, he became increasingly irritable, less active, and started drinking poorly. The

mother denied any history of diarrhea or bulky, greasy stools. In fact, she reported that he tended to be constipated and had hard, formed stools. Several episodes of vomiting occurred during the 3 days before admission. There was no fever.

On admission, he had typical features of kwashiorkor: generalized edema, hyperpigmented and hypopigmented skin lesions, irritability, and thin, sparse hair (Fig 1). The patient was afebrile on admission (37.3°C rectally) and remained normothermic throughout the hospitalization. Bilateral otitis media with effusion was present on examination. Weight was 10.8 kg (10th percentile) and height was 81 cm (5th percentile). Hepatomegaly was not detected; however, edema of the abdominal wall and generalized abdominal distention complicated the abdominal examination. The rest of the examination was normal.

Serum albumin was 1.0 g/dL (10 g/L). Other serum laboratory findings included: potassium, 3.4 mmol/L; urea nitrogen, <0.5 mg/dL (<0.2 mmol/L); phosphorus, 2.2 mg/dL (0.71 mmol/L); alkaline phosphatase, 104 U/L; and zinc, 32.2 µg/dL (4.9 mmol/L; normal range: 60-130 µg/dL). C-reactive protein (CRP) was <4 mg/L (<0.4 mg/dL). The hematologic findings were as follows: white blood cell count, 11 500 cells/mm<sup>3</sup> with normal differential count; hemoglobin, 8.0 g/dL (80 g/L); mean cell volume, 78.4 fL; red blood cell distribution width, 16.7%; and marked anisocytosis.

The patient was evaluated for other causes of hypoproteinemia. Except for hypoalbuminemia, the liver function tests were normal. Prothrombin time was not prolonged. In view of the absence of signs of systemic inflammation (no fever, normal CRP, normal white blood cell count), cytokine-induced hypoalbuminemia was considered unlikely. There was no proteinuria. Stool α-1-antitrypsin was not elevated, thus ruling out protein-losing enteropathy. Stool was negative for occult blood and no white blood cells were seen on a stool smear.

Therapy for kwashiorkor was instituted, including gradual refeeding, initially via nasogastric tube because of severe anorexia. Supplements of potassium, phosphorus, multivitamins, zinc, and folic acid were provided. The zinc dose used was 1 mg of elemental zinc per kg per day. The zinc level had normalized (69.0 µg/dL [10.6 µmol/L]) after 5 weeks of supplementation. Normal zinc levels were documented 6 and 12 months later without continued zinc supplementation.

The patient received a 10-day course of oral cotrimoxazole for his otitis media with effusion. Initially a nasogastric electrolyte infusion was commenced. This was well-tolerated; thus, a soy-

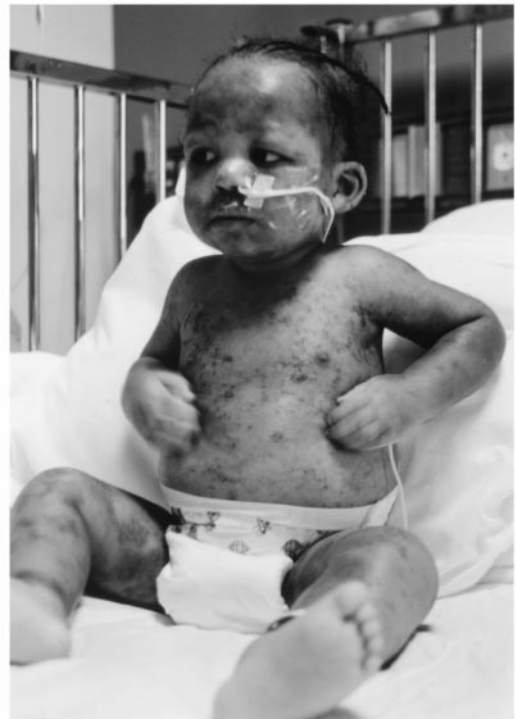

Fig 1. A 21-month-old with generalized edema, skin lesions, and hair loss because of kwashiorkor.

based toddler formula was started on the second day at 80 mL/kg/day. Subsequently, this was increased to 120 mL/kg/day on the fifth day. The nasogastric feeds were tapered as oral intake improved. The patient was later switched to a milk-based pediatric nutritional supplement. Animal proteins are a better choice for refeeding because soybeans are deficient in methionine. The patient responded dramatically. On day 11, serum albumin had increased to 1.8 g/dL (18 g/L), with mild residual edema (a trace of peripheral edema and mild periorbital edema on awakening). He was drinking 1 L of the milk-based pediatric formula daily and had started eating solid foods. He was discharged from the hospital and continued to make an uncomplicated recovery. He had no apparent physical sequelae at follow-up at 24 months of age, when his weight was 11.5 kg (20th percentile) and his height was 83 cm (5th percentile).

### Case 2

A 17-month-old black male was diagnosed with rickets. He was born at term (birth weight: 4.18 kg) and was initially breastfed. Vegetable infant foods were introduced at 4 months of age. At 10 months of age, he was weaned from the breast and began a soy

beverage, which his parents drank in place of milk, because of their taste preferences. The patient consumed a vegan diet, without intake of any animal products. Foods regularly eaten included tofu, sweet potatoes, potatoes, spaghetti, fig bars, infant cereal, bananas, strawberries, and other fruits and vegetables. On an average day, he drank 900 mL of the soy beverage, which was not fortified with vitamin D or calcium. Total daily caloric intake was estimated at 1530 calories, which is 114% of the recommended dietary allowance (RDA).<sup>15</sup> The diet was also adequate in fat and carbohydrate content (108% and 117% RDA, respectively) and was high in protein (335% RDA). Additional analysis showed that vitamin D was essentially absent (0% RDA) because of the lack of vitamin D-fortified milk. The only significant source of calcium came from the infant cereal, which provided ~450 mg daily (57% RDA).

The parents were well-educated and the home environment was stable. The mother worked long hours at her home business and spent very little time outdoors. As a result, opportunities for sun exposure for her child were limited.

The child was seen on a regular basis by his pediatrician and was growing normally until his 9-month checkup (Fig 2). There-

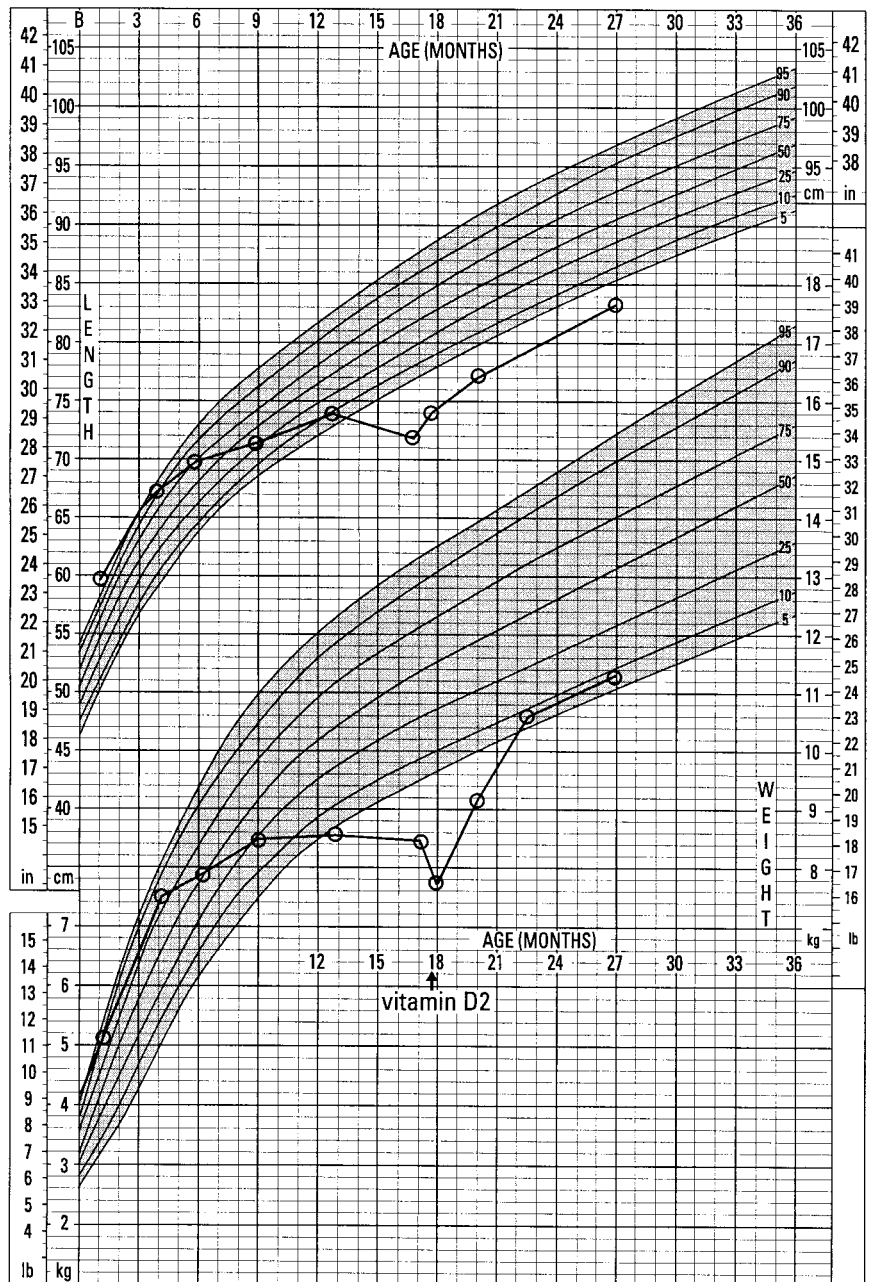


Fig 2. Growth chart illustrating almost complete growth arrest after 9 months of age in a child with nutritional rickets. The response to vitamin D2 supplementation is demonstrated.

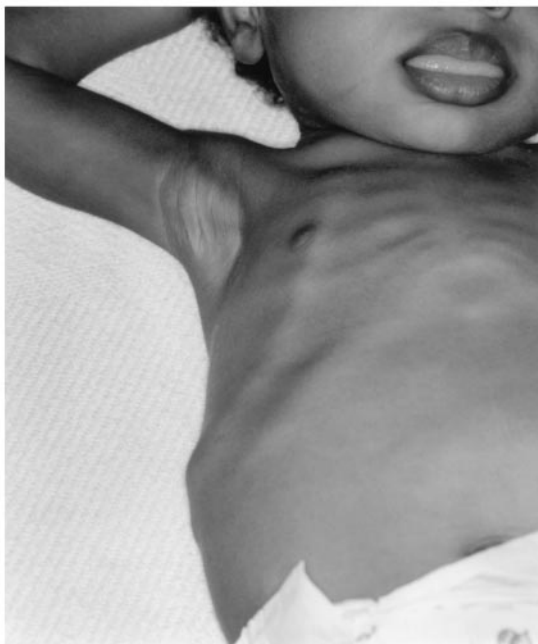after, he demonstrated an almost complete arrest in growth (both height and weight).

At the time of presentation at Children's Healthcare of Atlanta at Scottish Rite, his parents' main concern was related to a deformity of his spine, a marked lumbar kyphoscoliosis. His parents also described a loss of gross motor milestones. At 12 to 13 months old, he was able to walk with support. Subsequently, he lost the ability to cruise and by the time of presentation, he was unable to crawl or roll over. When placed in a sitting position, he could maintain that position precariously with poor posture and trunk stability. He was noted to have head lag when pulled to sit. Conversely, his language, fine motor-adaptive, and personal-social skills were well-preserved. He had a pincer grasp, was able to scribble, used a cup and spoon, and had started sorting shapes. He said 4 to 5 words and understood and followed 1-step commands.

The patient appeared thin and wasted. He was fully conscious and engaging. Temperature was 36.8°C (axillary) and vital signs were within normal limits. The weight (7.64 kg) and length (73.7 cm) were both well below the 5th percentile (Fig 2), although the head circumference (47 cm) was above the 10th percentile. Frontal bossing was evident, as was an impressive rachitic rosary (Fig 3). He had mild genu varus, flaring of the wrists, lumbar kyphoscoliosis, and a bony protuberance arising from his left ulna. Neurologic examination revealed generalized hypotonia, weakness, and decreased muscle bulk. He was able to move his extremities against gravity but not his trunk. Reflexes were present and equal bilaterally. Plantar reflexes were down-going. There was no clonus or fasciculations. Cranial nerves and sensation were intact. The remainder of his examination was normal.

The serum alkaline phosphatase was markedly elevated, phosphorus was low, and calcium was in the low normal range (Table 1). The rest of the complete metabolic profile was normal. The 25-hydroxy-vitamin D level was low, despite the initiation of 30% of the recommended dose of multivitamins 1 month before admission. Parathyroid hormone level was considerably elevated and, in view of the low normal calcium level, was consistent with secondary hyperparathyroidism. Radiologic evaluation revealed a diffuse profound osteopenia and osteomalacia. The metaphyses of the long bones were frayed and the epiphyseal plates were widened (Fig 4). In addition, he had a pathologic fracture of the left ulna (Fig 5). These findings are diagnostic of advanced rickets. The low 25-hydroxy-vitamin D level along with the history of a deficient diet supported a nutritional cause.

Pertinent negative laboratory findings included a normal complete blood count and differential, normal erythrocyte sedimenta-



**Fig 3.** The rachitic rosary (a row of beading at the junction of the ribs with their cartilages) is clearly seen.

tion rate and CRP, normal thyroid panel, and normal plasma ammonia and lactic acid. The possibility of malabsorption was discounted by a normal stool fat estimation. Neuroimaging was considered because of the marked gross motor retardation. However, because the fine motor and cognitive aspects of development were well-preserved, a coexisting neurodegenerative process was thought unlikely, particularly in view of the confirmed diagnosis of severe rickets. Neuroimaging, therefore, was deferred pending evaluation of response to therapy.

The patient was started on ergocalciferol (vitamin D2) and a diet rich in calcium and vitamin D. After his calcium level decreased to 7.6 mg/dL (1.89 mmol/L), he was started on calcium supplements. Follow-up radiograph studies 10 weeks after the institution of treatment showed markedly improved osseous mineralization with reappearance of provisional zones of calcification. Furthermore, within 1 week of vitamin D and calcium therapy, he began rolling over, began crawling within 2 months of therapy, and was walking after 6 months of therapy.

## DISCUSSION

In both of these cases, the nutritional deficiencies were caused by intake of a milk alternative purchased from the health food section of a supermarket. The families involved do not fit the stereotypic profile in which malnutrition would be anticipated. The parents were well-educated, seemed knowledgeable and responsible, and had at least average family incomes. Both families made the mistaken assumption that foods labeled as natural are always a healthy and appropriate nutritional choice. Both of the milk alternative beverages stated on the container that they were not intended for use as infant formulas. However, these products are not labeled with a caution regarding their use in toddlers.

In case 1, the parents fed their toddler the enriched version of a rice-based beverage, which is fortified with vitamins A and D and calcium. They assumed that they were providing their toddler with superior nutrition, because of the fortified status and relatively high cost of the beverage. Unfortunately, the protein content of this rice beverage (1.7 g/L) was very low compared with the protein content of cow's milk (33 g/L).<sup>16</sup> The RDA for toddlers is 1.2 g/kg/day. Thus, the average (13-kg) toddler would have to consume 9.4 L of rice beverage per day to meet his/her daily protein allowance. Because the child drank 1.5 L of the rice drink daily and ate little else, this resulted in a protein intake of 0.3 g/kg/day (25% RDA). In comparison, the child's caloric intake of 790 calories per day is 72% of the recommended energy intake of 1100 calories per day. The ratio of protein to energy in this diet, thus, is very low. It is this imbalance in the dietary ratio of protein to energy that has been implicated in the pathogenesis of kwashiorkor.<sup>17</sup> In contrast, the diets of children who develop marasmus are markedly deficient in both protein and energy content.

It is noteworthy that this patient's weight was at the 10th percentile for age, which may have delayed his diagnosis, because a nutritional cause was not promptly considered. This misleading phenomenon occurs because of fluid retention. Children with kwashiorkor often have a rotund sugar baby appearance. This child had the classic features of kwashiorkor. The hallmark of kwashiorkor is a low serum albumin of dietary origin. The primary clinical fea-

tures include generalized edema, weight between 60% and 80% of standard, misery and decreased activity, hyperpigmented and hypopigmented skin lesions, hepatomegaly, and thinned and depigmented hair.

Children in industrialized countries have developed kwashiorkor because of the use of nondairy creamer as a milk alternative.<sup>11,12</sup> We were unable to find previous reports of kwashiorkor caused by a health food milk alternative, but because kwashiorkor is not a notifiable disease in the United States, cases may have occurred and may have not been reported. It is also possible that mild cases may have been overlooked and resolved when a more varied diet was adopted spontaneously. Because the use of health foods is common, a good dietary history and high index of suspicion for nutritional conditions is needed to ensure that cases are not overlooked.

The mortality of kwashiorkor remains high.<sup>5,18,19</sup> Infection, exacerbated by underlying cellular immunodeficiency,<sup>1</sup> contributes to the high mortality. Electrolyte imbalances with ongoing diarrhea are also problematic. A recent randomized, double-blind, placebo-controlled clinical trial performed in Malawi found that high potassium supplementation (7.7 mmol/kg/day) reduced the mortality from 41% to 27%.<sup>18</sup> Severe hypophosphatemia has been linked to a high mortality.<sup>19</sup> Magnesium and zinc deficiencies are also frequently present in kwashiorkor.

The cornerstone of treatment for kwashiorkor is the gradual introduction of enteral feeds. Severely affected patients are usually anorexic, and nasogastric feedings will be required. In industrialized countries, children diagnosed with kwashiorkor are frequently thought by their families to be allergic to milk. In this setting it is usually the intentional exclusion of milk from the diet that causes kwashiorkor. In most instances the milk sensitivity is not subsequently confirmed<sup>3,11,12</sup> as was the case in this report. Cow's milk feeds are the mainstay of dietary therapy for kwashiorkor in developing countries. No benefit has been achieved by reducing lactose intake.<sup>20</sup> If milk sensitivity cannot be reasonably excluded, then initial refeeding with a protein hydrolysate formula would be the safest approach.

In case 2, the toddler was on a soy preparation, a fair source of protein, but lacking any added vitamin A and D or calcium. Rickets associated with health food milk alternatives has been reported previously.<sup>9</sup> A high prevalence of rickets has been reported in infants who consume macrobiotic diets (organic, whole-grain foods that are not chemically processed).<sup>21</sup> The absence of vitamin D-fortified milk in a vegan diet results in inadequate vitamin D and calcium intake. In addition, the high fiber content in a vegetarian/vegan diet also reduces the absorption of calcium and, thus, further predisposes one to rickets. It is likely that both vitamin D and calcium deficiency contributed to the genesis of this child's rickets.

This infant was breastfed until 10 months of age without receiving supplemental vitamin D. This likely contributed to the development of rickets. Breast milk does not provide enough vitamin D<sup>22,23</sup>

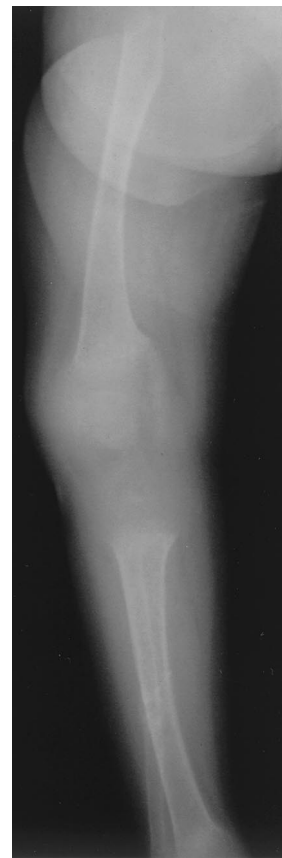

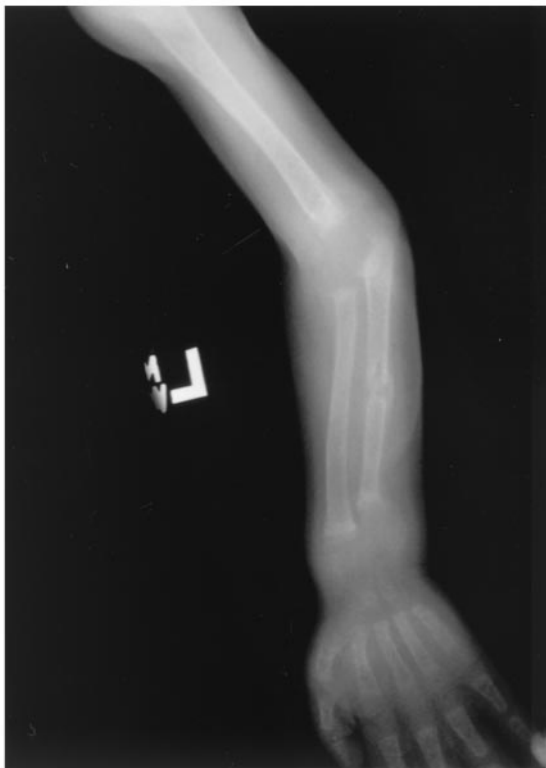Fig 4. Anteroposterior radiograph of the right leg showing osteopenia and osteomalacia. Widening of the epiphyseal plate, cupping, and fraying of the metaphyses are also seen.

to meet the requirements of an infant in the absence of sufficient sun exposure. Recommendations regarding the circumstances that necessitate vitamin D supplementation in breastfed infants vary widely.<sup>22,24–26</sup>

Humans are able to synthesize vitamin D in the skin with the aid of exposure to ultraviolet light.<sup>27</sup> Dietary sources are thought to be important only in the absence of adequate sun exposure. It may seem surprising, therefore, that this case of advanced rickets occurred in Atlanta, Georgia, which averages 217 days of sunshine annually<sup>28</sup> and is just 34 degrees latitude north of the equator. Reports of rickets in black, breastfed infants occurring in relatively sunny climates<sup>7,14</sup> strengthen the arguments in favor of universal vitamin D supplementation in this population. Individuals with darkly pigmented skin require more sun exposure to synthesize vitamin D,<sup>29</sup> thus, placing this dark-skinned patient at higher risk. Secular lifestyle changes may also decrease the amount of time infants and children are outdoors during sunlight hours. These include factors such as both parents working long hours, increased sedentary indoor lifestyle (eg, computer games), poor outdoor air quality (smog), lack of sidewalks, and outdoor heat and humidity with available indoor air conditioning. Perhaps because of these lifestyle changes, physicians need to be even more attentive to high-risk groups of children (ie, darkly pigmented, breastfeeding, or vegetarian/vegan infants and children).

**TABLE 1.** Case 2—Laboratory Results

Laboratory Parameter	Conventional System Measurements (Normal Range)	Equivalent Système International Measurements (Normal Range)
Alkaline phosphatase	1879 U/L (150–420)	1879 U/L (150–420)
Phosphorus	1.7 mg/dL (4.5–6.9)	0.55 mmol/L (1.35–2.25)
Calcium	8.9 mg/dL (8–10.3)	2.22 mmol/L (2.00–2.58)
25-hydroxy-vitamin D	7.7 pg/mL (8.9–46.7)	19.2 pmol/L (22.2–116.6)
Parathyroid hormone	114 pg/mL (10–65)	114 ng/L (10–65)



**Fig 5.** Radiograph of the left forearm showing a pathologic fracture of the ulna and disuse atrophy in addition to the features of rickets noted in Fig 4.

Nutritional rickets was once a major pediatric health scourge in the United States. To combat rickets, commercially prepared milk has been fortified with vitamin D since the late 1920s. This practice has been so successful that this malady is now rare. In 1999 the Food and Drug Administration authorized the use of health claims regarding the role of soy protein in reducing the risk of coronary heart disease.<sup>30</sup> Soy beverages have become a favored alternative to milk for many consumers. All the arguments in favor of vitamin D fortification of milk apply equally well to any beverage that replaces milk. In Canada, where fortification of all forms of milk (fluid, dried, and evaporated) with vitamin D was not universal until the late 1960s, rickets continued to be a significant problem<sup>31</sup> until universal fortification became standard practice. If we are to avoid relearning the lessons of the past, we should ensure that beverages that replace milk are also fortified with vitamin D and calcium to prevent a resurgence of rickets and osteomalacia.

This patient presented with prominent neuromus-

cular manifestations of rickets—hypotonia, weakness, and regression in motor milestones. The neuromuscular consequences are well-described in the literature<sup>32</sup> and may precede the skeletal manifestations. Although most pediatricians are familiar with the skeletal manifestations of rickets, many may be unaware of the neuromuscular clinical features, because these are generally not emphasized in standard pediatric texts. Rickets should be in the differential diagnosis of infants and children with motor delay.

Nutritional diseases are entirely preventable. Complex interventions are not required. A good dietary history is necessary and should include inquiry about the use of milk alternatives. Knowledge regarding nutrient composition of food and beverages consumed by children is important. If a dietary inadequacy is identified, parental education should be conducted. Physicians who, because of time or other constraints, are unable to provide detailed counseling should be willing to refer families to a registered and/or licensed dietitian. Additionally, milk alternative beverages not containing appropriate quantities of protein and/or vitamins and minerals for toddlers should carry a warning label as to their inappropriateness for this age group.

#### ACKNOWLEDGMENTS

We thank Kay M. Tomashek, MD, MPH, from the Pregnancy and Infant Health Branch at the Centers for Disease Control and Prevention; formerly with the Georgia Department of Human Resources, Division of Public Health, for her support and critical review of the manuscript. We also thank William H. Dietz, MD, PhD, Division of Nutrition and Physical Activity, Centers for Disease Control and Prevention, and Kelley S. Scanlon, PhD, RD, Maternal and Child Nutrition Branch, Centers for Disease Control and Prevention, for their critical review of the manuscript.

#### REFERENCES

1. Work T, Ifekwunigwe A, Jelliffe D, et al. Tropical problems in nutrition. *Ann Intern Med.* 1979;70:701–711
2. Karrar ZA. Vitamin D deficiency rickets in developing countries. *Ann Trop Paediatr.* 1998;18(suppl):S89–S92
3. Lozoff B, Fanaroff AA. Kwashiorkor in Cleveland. *Am J Dis Child.* 1975;129:710–711
4. Berkelhamer JE, Thorp FK, Cobb S. Kwashiorkor in Chicago. *Am J Dis Child.* 1975;129:1240
5. Chase HP, Kumar V, Caldwell RT, O’Brein D. Kwashiorkor in the United States. *Pediatrics.* 1980;66:972–976
6. Rush D, Leighton J, Sloan NL, et al. The National WIC Evaluation: evaluation of the Special Supplemental Food Program for Women, Infants, and Children. VI. Study of infants and children. *Am J Clin Nutr.* 1988;48(suppl):484–511
7. Bhowmick SK, Johnson KR, Rettig KR. Rickets caused by vitamin D deficiency in breast-fed infants in the southern United States. *Am J Dis Child.* 1991;145:127–130
8. Sills IN, Skuza KA, Horlick MN, Schwartz MS, Rapaport R. Vitamin D

- deficiency rickets: reports of its demise are exaggerated. *Clin Pediatr*. 1994;33:491-493
9. Edidin DV, Levitsky LL, Schey W, Dumbovic N, Campos A. Resurgence of nutritional rickets associated with breast-feeding and special dietary practices. *Pediatrics*. 1980;65:232-235
  10. Duplechin RY, Nadkarni M, Schwartz RP. Hypocalcemic tetany in a toddler with undiagnosed rickets. *Ann Emerg Med*. 1999;34:399-402
  11. Schreiber R, Adelson JW. Kwashiorkor in an urban Canadian child. *Can Med Assoc J*. 1985;133:888-889
  12. Sinatra FR, Merritt RJ. Iatrogenic kwashiorkor in infants. *Am J Dis Child*. 1981;135:21-23
  13. Albers SE, Brozena SJ, Fenske NA. A case of kwashiorkor. *Cutis*. 1993; 51:445-446
  14. Kreiter SR, Schwartz RP, Kirkman HN Jr, Charlton PA, Calikoglu AS, Davenport ML. Nutritional rickets in African American breast-fed infants. *J Pediatr*. 2000;137:153-157
  15. Committee on Dietary Allowances, National Research Council, Food and Nutrition Board. *Recommended Dietary Allowances*. 10th ed. Washington DC: National Academy Press; 1989
  16. American Academy of Pediatrics. *Pediatric Nutrition Handbook*. 4th ed. Elk Grove Village, IL: American Academy of Pediatrics; 1998:631
  17. Rossouw JE. Kwashiorkor in North America. *Am J Clin Nutr*. 1989;49: 588-592
  18. Manary MJ, Brewster DR. Potassium supplementation in kwashiorkor. *J Pediatr Gastroenterol Nutr*. 1997;24:194-201
  19. Manary MJ, Hart CA, Whyte MP. Severe hypophosphatemia in children with kwashiorkor is associated with increased mortality. *J Pediatr*. 1998; 133:789-791
  20. Solomons NW, Torun B, Caballero B, Flores-Heurta S, Orozco G. The effect of dietary lactose on the early recovery from protein-energy malnutrition: clinical and anthropometric indices. *Am J Clin Nutr*. 1984; 40:591-600
  21. Dagnelie PC, Vergote FJ, van Staveren WA, et al. High prevalence of rickets in infants on macrobiotic diets. *Am J Clin Nutr*. 1990;51:202-208
  22. Finberg L. Human milk feeding and vitamin D supplementation. *J Pediatr*. 1981;99:228-229
  23. Fourman D, Royer P. In: *Calcium Metabolism and the Bone*. 2nd ed. Philadelphia, PA: FA Davis Co; 1968:113
  24. Birbeck JA, Scott HF. 25 Hydroxy-cholecalciferol serum levels in breast-fed infants. *Arch Dis Child*. 1980;55:691-695
  25. Greer FR, Marshall S. Bone mineral content, serum vitamin D metabolite concentration and ultraviolet B light exposure in infants fed human milk with and without vitamin D2 supplements. *J Pediatr*. 1989;114: 204-212
  26. Work Group on Breastfeeding. Breastfeeding and the use of human milk. *Pediatrics*. 1997;100:1035-1039
  27. Holick MF, MacLaughlin JA, Clark MB, et al. Photosynthesis of previtamin D in human skin and its physiological consequences. *Science*. 1980;210:203-205
  28. National Climatic Data Center. *Comparative Climatic Data for the United States Through 1998*. Asheville, NC: National Climatic Data Center; 1999
  29. Clemens TL, Adams JS, Henderson SL, Holick MF. Increased skin pigmentation reduces the capacity of skin to synthesize vitamin D3. *Lancet*. 1982;1:74-76
  30. Food and Drug Administration. Food labeling: health claims—soy protein and coronary heart disease. *Federal Register*. 1999;64:57699-57733
  31. Anonymous. Evidence in support of the desirability of the addition of vitamin D to milk. *Can J Public Health*. 1968;59:328
  32. Torres CF, Forbes GB, Decancq GH. Muscle weakness in infants with rickets: distribution, course and recovery. *Pediatr Neurol*. 1986;2:95-98

## Severe Nutritional Deficiencies in Toddlers Resulting From Health Food Milk Alternatives

Norman F. Carvalho, Richard D. Kenney, Paul H. Carrington and David E. Hall

*Pediatrics* 2001;107:e46

DOI: 10.1542/peds.107.4.e46

### Updated Information & Services

including high resolution figures, can be found at:  
<http://pediatrics.aappublications.org/content/107/4/e46>

### References

This article cites 28 articles, 9 of which you can access for free at:  
<http://pediatrics.aappublications.org/content/107/4/e46#BIBL>

### Subspecialty Collections

This article, along with others on similar topics, appears in the following collection(s):  
**Chapters Views & News**  
[http://www.aappublications.org/cgi/collection/chapters\\_views\\_news](http://www.aappublications.org/cgi/collection/chapters_views_news)  
**Fetus/Newborn Infant**  
[http://www.aappublications.org/cgi/collection/fetus:newborn\\_infant\\_sub](http://www.aappublications.org/cgi/collection/fetus:newborn_infant_sub)  
**Nutrition**  
[http://www.aappublications.org/cgi/collection/nutrition\\_sub](http://www.aappublications.org/cgi/collection/nutrition_sub)

### Permissions & Licensing

Information about reproducing this article in parts (figures, tables) or in its entirety can be found online at:  
<http://www.aappublications.org/site/misc/Permissions.xhtml>

### Reprints

Information about ordering reprints can be found online:  
<http://www.aappublications.org/site/misc/reprints.xhtml>

American Academy of Pediatrics

DEDICATED TO THE HEALTH OF ALL CHILDREN™





# PEDIATRICS®

OFFICIAL JOURNAL OF THE AMERICAN ACADEMY OF PEDIATRICS

## **Severe Nutritional Deficiencies in Toddlers Resulting From Health Food Milk Alternatives**

Norman F. Carvalho, Richard D. Kenney, Paul H. Carrington and David E. Hall

*Pediatrics* 2001;107:e46

DOI: 10.1542/peds.107.4.e46

The online version of this article, along with updated information and services, is located on the World Wide Web at:

<http://pediatrics.aappublications.org/content/107/4/e46>

Pediatrics is the official journal of the American Academy of Pediatrics. A monthly publication, it has been published continuously since 1948. Pediatrics is owned, published, and trademarked by the American Academy of Pediatrics, 141 Northwest Point Boulevard, Elk Grove Village, Illinois, 60007. Copyright © 2001 by the American Academy of Pediatrics. All rights reserved. Print ISSN: 1073-0397.

American Academy of Pediatrics

DEDICATED TO THE HEALTH OF ALL CHILDREN™

