

Prepubertal Gynecomastia: Indirect Exposure to Estrogen Cream

Eric I. Felner, MD, and Perrin C. White, MD

ABSTRACT. *Objective.* To describe the clinical course of 3 prepubertal boys who presented with gynecomastia resulting from indirect exposure to a custom-compounded preparation of estrogen cream used by each child's mother.

Methodology. Each child was initially referred to the Children's Medical Center of Dallas' Endocrinology Center and followed for over 1 year.

Results. All 3 boys presented with gynecomastia and elevated estradiol levels. Two had accelerated growth and advanced bone ages. Within 4 months after each child's mother discontinued use of the topical estrogen preparation, each child's gynecomastia regressed and estradiol levels returned to normal.

Conclusion. Indirect exposure to excessive amounts of topical estrogen may cause gynecomastia, rapid changes in growth, and advanced bone age in prepubertal children. Because custom-compounded topical estrogen preparations are not regulated by the Food and Drug Administration and may contain high concentrations of estrogen, we recommend that women requiring estrogen use an alternate form of estrogen delivery if they are in frequent close contact with children. *Pediatrics* 2000; 105(4). URL: <http://www.pediatrics.org/cgi/content/full/105/4/e55>; estradiol, custom-compounded.

Women who give birth at an advanced age may develop perimenopausal symptoms while their children are prepubertal. Oral or transdermal estrogen replacement therapy is often used to relieve these symptoms. We report 3 cases of prepubertal male gynecomastia as a result of indirect exposure to high concentrations of estrogen contained in a custom-compounded topical cream used by each child's mother.

CASE REPORTS

Three white boys (33 months old, 28 months old, and 8 years old) were referred to the Endocrinology Center at the Children's Medical Center of Dallas for the evaluation of gynecomastia.

Patient A was a 33-month-old boy who presented with a 6-month history of bilateral breast enlargement and a recent rapid increase in growth. An initial history revealed that he had no previous medical or surgical history and that he had not been using any medications or cosmetic ointments since birth.

His birth weight was 7 lb 11 oz. Other than a maternal age of 47 years at the time of conception, prenatal and birth history were uncomplicated. He achieved developmental milestones appropriately and had no recent history of illness. There was no family history of gynecomastia or early puberty.

From the Department of Pediatrics, Division of Endocrinology, University of Texas Southwestern Medical Center, Dallas, Texas
Received for publication Aug 9, 1999; accepted Dec 1, 1999.
Reprint requests to (E.I.F.) Department of Pediatrics/Endocrinology, 5323 Harry Hines Blvd, Dallas, TX 75235. E-mail: efelne@childmed.dallas.tx.us
PEDIATRICS (ISSN 0031 4005). Copyright © 2000 by the American Academy of Pediatrics.

On physical examination, he was a large, active, and healthy boy. His height, weight, and bone age were advanced (Table 1). Records from his general pediatrician revealed that his height was at the 75th percentile 6 months before his visit. Examination of his chest revealed Tanner II breast development with 2 cm of glandular breast tissue bilaterally. There was no areolar pigmentation. The nipples were everted but without erythema, discharge, or tenderness. He had no pubic or axillary hair, body odor, acne, or penile enlargement. His testes were prepubertal and without masses. He had no thyromegaly or hepatosplenomegaly, and the remainder of his examination was normal. The family agreed to have hormone studies collected at an outside facility, but despite attempts to contact and remind the family, they failed to follow-up with the laboratory.

The patient returned to the Endocrine Center 6 months later with signs of continued rapid growth (Table 2) and increasing breast size. On obtaining further history, it was discovered that the child's mother was using a custom-compounded topical estrogen cream (Estradiol-K) containing 9 mg of estradiol per 1 g of cream. She had applied 1 g of the cream to her thighs twice daily for the previous 8 months, beginning 2 months before the patient's initial presentation. At this second visit, the patient's height and weight were well above the 95th percentile and his bone age was further advanced to 8 years at a chronological age of 39 months. His physical examination was significant for Tanner III breasts, with 3 cm of glandular breast tissue bilaterally. The remainder of his examination was unchanged. Hormone studies performed at this visit were normal, with the exception of an elevated estradiol level (Table 3).

After consultation with her gynecologist, the mother switched to a transdermal estrogen patch and was instructed to thoroughly wash her hands after applying the patch. Four months later, patient A's estradiol level had returned to normal (.6 ng/mL) and his breasts had begun to regress (1.5 cm of breast tissue). He was seen again 1 year later, and his breast examination was significant for slightly everted nipples and only .5 cm of breast tissue. His bone age was 8 years and 10 months at a chronological age of 4 years and 3 months, and his growth rate had decreased (Table 2). He has now been followed for 2 years since his initial presentation without recurrence of gynecomastia.

Patient B was a 28-month-old boy who also presented with a 6-month history of bilateral breast enlargement and a recent rapid increase in growth. He had not been using any medications or cosmetic ointments since birth. However, his mother was using the identical estrogen preparation (Estradiol-K) from the same pharmacy as patient A's mother. She had also applied 1 g of cream to her thighs twice daily over the previous 8 months.

Patient B's birth weight was 7 lb. Other than gestational diabetes mellitus in his mother, prenatal and birth history were uncomplicated. His mother was 40 years old at the time of delivery. His past medical history and family history were unremarkable.

His height, weight, and bone age were advanced (Table 1) and he was growing rapidly (Table 2). He had Tanner stage II-III breasts with 2.5 cm of glandular breast tissue but no areolar pigmentation. The nipples were everted but without erythema, discharge, or tenderness (Fig 1). He was otherwise prepubertal and the remainder of his examination was normal. Hormone studies were normal with the exception of an elevated estradiol level (Table 3). The mother was instructed to discontinue the estrogen cream or use an alternate delivery mode and return for follow-up 6 months later. The mother chose to discontinue the estrogen cream.

On follow-up, his examination revealed only a minimal amount of breast tissue and his estradiol level was undetectable (<.5

TABLE 1. Physical Characteristics at Presentation

	Patient A	Patient B	Patient C
Age (y)	2.75	2.33	8
Height (cm)	102.2	95.8	131.0
Height (percentile)	>95	90	75
Height age (y)	4	3.33	9
Weight (kg)	17.1	16.1	23.4
Weight (percentile)	>95	95	45
Weight age (y)	4	3.5	7.5
Bone age (y)	4	5	8.5

TABLE 2. Patient Growth Velocities

Patient	Period 1 (cm/Year)	Period 2 (cm/Year)	Period 3 (cm/Year)
A	19	7.4	2
B	16	8	4
C	5*	4	5

Period 1 indicates growth velocity from 6 months before presentation to time estrogen source removed (* patient C—from 1 year before presentation to time estrogen source removed); period 2, growth velocity from time estrogen source removed to 6 months after estrogen source removed; period 3, growth velocity from 6 months after estrogen source removed to 1 year after estrogen source removed.

ng/dL). He has been followed for 16 months since his initial presentation without recurrence of gynecomastia.

Patient C was an 8-year-old boy who presented with a 2-month history of gynecomastia. Other than Ritalin, taken twice daily for attention deficit hyperactivity disorder for the previous 2 years, he had been on no medications or cosmetic creams in the previous year. However, his mother, who was 34 years old, was having irregular menstrual cycles and had been applying 1 g of a custom-compounded, nonformulary estrogen preparation (Estrad-licit) to her abdomen twice daily for the previous 4 months. The preparation contained 24 mg of estradiol per 1 g of cream.

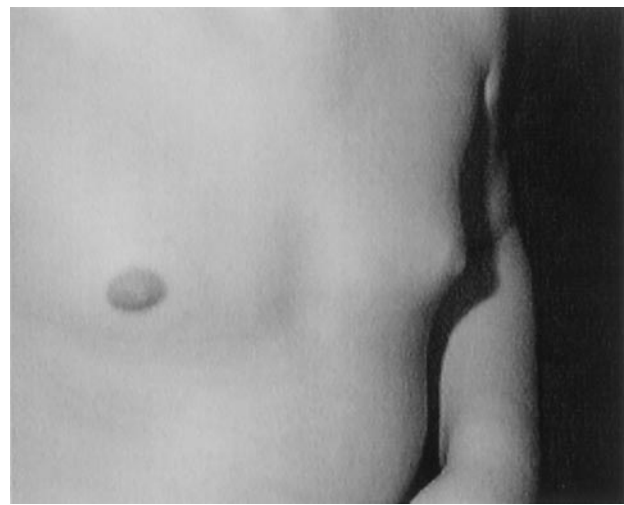
Birth history was uneventful and growth and developmental milestones were achieved appropriately. Past medical history, review of systems, and family history were noncontributory.

His height, weight, and bone age were normal (Table 1). Breasts were Tanner II with 1.5–2 cm of bilateral glandular breast tissue. The nipples were slightly everted, without areolar pigmentation, erythema, discharge, or tenderness. He was otherwise prepubertal and the remainder of his examination was normal. Initial hormone studies revealed an elevated estradiol level (Table 3). The mother decided to discontinue the cream.

On follow-up 4 months later, the patient had minimal glandular breast tissue. His genitalia were prepubertal and the remainder of his examination was normal. His repeat estradiol level was undetectable (<.5 ng/dL). He has been followed for 1 year since his initial presentation without recurrence of gynecomastia.

DISCUSSION

Gynecomastia occurs frequently in newborn and adolescent boys but rarely in prepubertal boys. Gynecomastia of the newborn usually occurs around 3 to 5 days of life and is probably related to the surge

**Fig 1.** A 28-month-old child with gynecomastia.

of maternal hormones released during delivery.¹ Adolescent gynecomastia is usually seen during the early stages of puberty, probably as a result of low testosterone in relation to estradiol levels.² Prepubertal females with no other signs of pubertal or rapid growth advancement may also have early breast development termed premature thelarche.³ These conditions are usually normal variants and rarely require treatment.

In contrast, gynecomastia in prepubertal boys is often a sign of pathology and its presence should prompt a thorough history, physical examination, and appropriate radiologic and laboratory testing to discover its cause. The history should establish the time course over which signs of abnormal hormone production developed including gynecomastia, body odor, pubic or axillary hair, and accelerated growth. Possible sources of exogenous estrogen exposure should be identified. In addition to the breasts, the physical examination should document height, weight, presence or absence of pubic or axillary hair or penile enlargement, and should include a careful examination of the testes.

Gynecomastia is usually caused by exposure to estrogens such as estradiol.⁴ Estrogens have extremely high affinities for their receptors and are the most potent natural steroids in the body. Their effects on growth and skeletal maturation are especially apparent in prepubertal children. Moreover, estrogens are more likely to cause gynecomastia in prepubertal boys in whom their effects are unopposed by the high testosterone levels seen in adult men.

TABLE 3. Plasma Hormones at Presentation

	Patient A	Patient B	Patient C	Normal Values for Age
Estradiol (ng/dL)	3.5	4.8	10	<1.5
Testosterone (ng/dL)	<3	3	10	3–10
Follicle-stimulating hormone (μ IU/mL)	<.4	.5	.6	.2–.6
Luteinizing hormone (μ IU/mL)	<.5	<.5	<.5	.2–.6
Dehydroepiandrosterone (μ g/dL)	<10	<10	60	20–275
Human chorionic gonadotropin (μ IU/mL)	<5	<5	<5	<5

Increased estrogen production may occur as a result of a testicular tumor, such as a germ cell, stromal cell, or choriocarcinoma, or an adrenocortical tumor.⁵⁻⁸ Germ cell tumors secrete human chorionic gonadotropin, which may stimulate estradiol or testosterone synthesis by the uninvolved areas of the testes,⁵ whereas stromal cell tumors such as Leydig or Sertoli cell tumors may secrete estradiol autonomously.⁶ Most feminizing adrenal tumors are associated with massive increases in the production of adrenal androgens, androstenedione, and dehydroepiandrosterone. Estrogen production is enhanced by the increased availability of these androgens to serve as substrates for extraglandular aromatization or rarely, the tumor itself secretes estrogen.⁸

Thus, initial laboratory evaluation of gynecomastia in a prepubertal boy should include determination of serum estradiol, dehydroepiandrosterone, androstenedione, testosterone, and the β -subunit of human chorionic gonadotropin. Estrogens usually accelerate skeletal maturation and a radiograph of the left hand and wrist should be obtained for bone age determination. Depending on the history and physical examination and the results of these tests, ultrasonography of the testes or magnetic resonance imaging of the adrenals may be required to localize a tumor.

With the exception of gynecomastia, each of our patient's examinations was normal and prepubertal. A history of estrogen exposure and an isolated elevation in estradiol with prepubertal levels of all other steroids helped uncover the cause in each case. After the mothers stopped using estrogen cream, the boys' estradiol levels returned to normal and the gynecomastia regressed, confirming the diagnosis.

Several cases of prepubertal male gynecomastia have resulted from direct application of dermal⁹ and hair preparations containing estrogen^{10,11} or from ingestion of milk and meat from cows treated with estrogen¹² or diethylstilbesterol.¹³

As regards indirect or second-person exposure, prepubertal gynecomastia occurred in children of workers in a diethylstilbesterol manufacturing plant, who absorbed the drug from the clothing of their fathers.¹⁴ Indirect exposure to estrogen caused gynecomastia in a man having sexual intercourse with a woman who was using a vaginal estrogen preparation.¹⁵ To our knowledge, no reported cases of prepubertal gynecomastia have been caused by indirect exposure to a mother's use of an estrogen preparation. Although the exact route by which the topical estrogen cream was transferred to each patient is not certain, the cream was applied to sites that are normally clothed. Thus, it seems most likely that it was spread from traces remaining on the mothers' hands after applying the cream, possibly via food preparation.

Estrogen replacement therapy for women experiencing menopausal or perimenopausal symptoms is usually recommended either as a transdermal, con-

tinuous delivery system such as an estrogen patch (.05-.1 mg of estradiol each week) or as an oral tablet (eg, .625 mg of oral equine estrogen daily).¹⁶ There are no published recommendations for cutaneous application of estrogen-containing creams; the doses used by the mothers of our patients (~20-50 mg daily) are considerably higher than those recommended for the usual modes of estrogen replacement therapy.

CONCLUSION

In evaluating gynecomastia in children, not only should the use or exposure of the child to medications or cosmetics be questioned, but also the use of the same products by the parents, caregivers, and siblings should be assessed. Nonformulary, custom-compounded estrogen preparations are not subject to Food and Drug Administration regulation and may contain high concentrations of active steroids. Keeping these points in mind when encountering a boy with prepubertal gynecomastia may forestall an extensive laboratory and radiologic investigation.

ACKNOWLEDGMENTS

This work was supported by National Institutes of Health Grants T32 DK07307 (to E.M.F.) and R37 DK37867 (to P.C.W.). We thank Dr Jean Wilson for reading the manuscript.

REFERENCES

- McKiernan JF, Hudd D. Breast development in the newborn. *Arch Dis Child.* 1981;56:525-529
- Moore DC, Schlaepfer LV, Paunier L, et al. Hormonal changes during puberty. V. Transient pubertal gynecomastia: abnormal androgen-estrogen ratios. *J Clin Endocrinol Metab.* 1984;58:492-499
- Van Winter JT, et al. Natural history of premature thelarche in Olmsted County, Minnesota, 1940 to 1984. *J Pediatr.* 1990;116:278-280
- Frantz AG, Wilson JD. Endocrine disorders of the breast. In: Foster DW, Wilson JD, eds. *Williams Textbook of Endocrinology.* Philadelphia, PA: WB Saunders Co; 1992:962-968
- Cochran JS, et al. The endocrinology of human chorionic gonadotropin-secreting testicular tumors: new methods in diagnosis. *J Urol.* 1975;114:549-555
- Bercovici JP, et al. Hormonal profile of Leydig cell tumors with gynecomastia. *J Clin Endocrinol Metab.* 1984;59:625-630
- Whitcomb RW, et al. Endocrine studies in a male patient with choriocarcinoma and gynecomastia. *Am J Med.* 1986;81:917-920
- Desai MB, Kapadia SN. Feminizing adrenocortical tumors in male patients: adenoma vs carcinoma. *J Urol.* 1988;139:101-103
- Beas F, Vargas L, Spada RP, Merchak N. Pseudoprecocious puberty in infants caused by a dermal ointment containing estrogens. *J Pediatr.* 1969;75:127-130
- Gabrilove JL, Luria M. Persistent gynecomastia resulting from scalp inunction of estradiol. *Arch Dermatol.* 1978;114:1672-1673
- Edidin DV, Levitsky LL. Prepubertal gynecomastia associated with estrogen-containing hair cream. *Am J Dis Child.* 1982;136:587-588
- Kimball AM, et al. Gynecomastia among children in Bahrain. *Lancet.* 1981;1:671-672
- Fava GM, et al. Epidemic of breast enlargement in an Italian school. *Lancet.* 1979;2:295-297
- Pacynski A, Budzynska A, Przylecki S. Hiperestrogenizm v pracownikow zakladow farmaceutycznych I ich dzieci jako choroba zawodowa. *Endokrynol Pol.* 1971;22:149-154
- Diraimondo CV, Roach AC, Meador CK. Gynecomastia from exposure to vaginal estrogen cream. *N Engl J Med.* 1980;302:1089-1090
- Lufkin EG, Ory SJ. Relative value of transdermal and oral estrogen therapy in various clinical situations. *Mayo Clin Proc.* 1994;69:131-135

Prepubertal Gynecomastia: Indirect Exposure to Estrogen Cream

Eric I. Felner and Perrin C. White

Pediatrics 2000;105:e55

DOI: 10.1542/peds.105.4.e55

Updated Information & Services

including high resolution figures, can be found at:
<http://pediatrics.aappublications.org/content/105/4/e55>

References

This article cites 15 articles, 1 of which you can access for free at:
<http://pediatrics.aappublications.org/content/105/4/e55#BIBL>

Subspecialty Collections

This article, along with others on similar topics, appears in the following collection(s):
Pediatrician Wellness
http://www.aappublications.org/cgi/collection/pediatrician_wellness
Endocrinology
http://www.aappublications.org/cgi/collection/endocrinology_sub

Permissions & Licensing

Information about reproducing this article in parts (figures, tables) or in its entirety can be found online at:
<http://www.aappublications.org/site/misc/Permissions.xhtml>

Reprints

Information about ordering reprints can be found online:
<http://www.aappublications.org/site/misc/reprints.xhtml>

American Academy of Pediatrics

DEDICATED TO THE HEALTH OF ALL CHILDREN™



PEDIATRICS®

OFFICIAL JOURNAL OF THE AMERICAN ACADEMY OF PEDIATRICS

Prepubertal Gynecomastia: Indirect Exposure to Estrogen Cream

Eric I. Felner and Perrin C. White

Pediatrics 2000;105:e55

DOI: 10.1542/peds.105.4.e55

The online version of this article, along with updated information and services, is located on the World Wide Web at:

<http://pediatrics.aappublications.org/content/105/4/e55>

Pediatrics is the official journal of the American Academy of Pediatrics. A monthly publication, it has been published continuously since 1948. Pediatrics is owned, published, and trademarked by the American Academy of Pediatrics, 141 Northwest Point Boulevard, Elk Grove Village, Illinois, 60007. Copyright © 2000 by the American Academy of Pediatrics. All rights reserved. Print ISSN: 1073-0397.

American Academy of Pediatrics

DEDICATED TO THE HEALTH OF ALL CHILDREN™

