Evolution in the Recognition of Infantile Hypertrophic Pyloric Stenosis

Frieda Hulka, MD‡; Timothy J. Campbell, MD§; John R. Campbell, MD*; and Marvin W. Harrison, MD*

ABSTRACT. *Purpose.* **To analyze changes in the clinical condition at presentation and methods of establishing the diagnosis of infantile hypertrophic pyloric stenosis (IHPS).**

Methods. **Retrospective review of patients who underwent pyloromyotomy (PM) for suspected IHPS at two institutions from 1969 through 1994 was performed. For the purposes of comparison, the population was divided into five equal time periods.**

Results. **Over the 25-year period, 901 infants underwent PM. Patients presented at a younger age, weighed more, and had a shorter length of illness in the most recent time period. Hypochloremic alkalosis was found half as frequently in the most recent time period compared to the earliest group. A palpable pyloric tumor was present in 79% of patients in the earliest time period compared with 23% in the most recent time period. Sixty-one percent of patients in the earliest group and 96% in the latest group underwent an imaging study, reflecting the referring physician's evaluation before referral to the surgeon.**

Conclusions. **Currently, patients with IHPS less frequently present with the clinical hallmarks of the disease. The use of imaging studies to establish the diagnosis has become common practice. The result has been the diagnosis of IHPS before alkalosis has developed, a shorter clinical course, less morbidity, and a shorter postoperative hospital stay.** ***Pediatrics*** **1997;100(2). URL: http://www.pediatrics.org/cgi/content/full/100/2/e9;** ***pyloric stenosis, pyloromyotomy, diagnosis, hypochloremic alkalosis, upper gastrointestinal series, abdominal ultrasonography.***

ABBREVIATIONS. IHPS, infantile hypertrophic pyloric stenosis; UGI, upper gastrointestinal series; U/S, ultrasound; PM, pyloromyotomy; PLOS, preoperative length of stay; TLOS, total length of stay.

Traditionally, the diagnosis of infantile hypertrophic pyloric stenosis (IHPS) is based on a history of projectile, nonbilious vomiting, and palpation of a pyloric tumor.[1,2] The presence of hypochloremic alkalosis has also been associated with IHPS.[3] Infants with historical but not physical findings consistent with IHPS undergo radiologic evaluation by either upper gastrointestinal series (UGI) or, more recently, abdominal ultrasound (U/S) to establish the diagnosis. The increased reliance of radiologic tests to diagnose IHPS has been ascribed to inexperienced examiners not palpating a pyloric tumor and subsequently proceeding with further evaluation.[4–6] To evaluate temporal trends in the presentation and methods of diagnosis of IHPS, we performed a review of patients who underwent pyloromyotomy (PM) in the past 25 years.

From the *Division of Pediatric Surgery, the ‡Department of Surgery, School of Medicine, Oregon Health Sciences University, and §Emanuel Hospital, Portland, Oregon.

Received for publication Feb 5, 1997; accepted Mar 24, 1997.

Reprint requests to (J.R.C.) Division of Pediatric Surgery—L223, Oregon Health Sciences University, 3181 SW Sam Jackson Park Rd, Portland, OR 97201.

PEDIATRICS (ISSN 0031 4005). Copyright © 1997 by the American Academy of Pediatrics.

PATIENTS AND METHODS

A retrospective chart review of patients who underwent PM for suspected IHPS at two teaching institutions between 1969 and 1994 was performed. All patients were examined and subsequently operated on by one of the authors (T.J.C., J.R.C., M.W.H.). Only patients with confirmed IHPS at the time of surgery were included in this analysis. Data included demographic information, history of illness, physical findings, admission laboratory values, and results of any imaging study performed. The preoperative and total length of stay were calculated in hours from the dates and times of admission, operation, and discharge. For the purposes of comparison, the study population was divided into five groups representing 5-year increments. When appropriate, values were expressed as a mean with standard deviation. All five groups were compared using analysis of variance. Comparison of the earliest with the most recent group was performed with the Student's t test for continuous variables and the χ^2 test for categorical variables. A P value of less than .05 was considered statistically significant. All tests were performed using the SPSS for Windows version 6.1 statistical program (SPSS Inc, Chicago, IL).

RESULTS

Over the 25-year period, 901 infants underwent PM for IHPS. Overall, 81% of patients were male infants. The mean age was 38 days (range 0 to 171 days) and the mean weight was 3934 g (range 2040 to 6840 g). A family history of pyloric stenosis was found in 12% of patients. Prematurity was present in 4% of patients. Congenital anomalies were found in 11% of patients. Only 1 infant underwent a negative exploration.

Analysis of the five time periods demonstrated that patients presented at a younger age, weighed more, and had a shorter length of illness in the most recent interval (Table 1). The prevalence of prematurity and positive family history of pyloric stenosis did not vary over time. The frequency of palpation of a pyloric tumor by the pediatric surgical staff decreased significantly over time ($P < .001$).

Electrolytes including sodium, potassium, and chloride were assessed at the time of admission in 98% of patients. Blood gas analysis was obtained in 10% of patients. Serum bicarbonate was added to the standard electrolyte panel in 1981 at one hospital and 1983 at the second hospital; therefore, analysis including bicarbonate is limited to the later half of the study. Metabolic derangements at admission were found less frequently over time (Table 2). Hypochloremia (defined as a serum chloride of less than 90 mEq/L) or alkalosis (defined as a pH of greater than 7.46) decreased in frequency in the later years (Fig 1).

Downloaded from by guest on August 30, 2016

TABLE 1. Demographic and Physical Characteristics

	1969–1974 (n = 118)	1975–1979 (n = 179)	1980–1984 (n = 186)	1985–1989 (n = 197)	1990–1994 (n = 221)	
Sex						
M	100 (85%)	138 (77%)	155 (83%)	159 (81%)	178 (81%)	
F	18 (15%)	41 (23%)	31 (17%)	38 (19%)	43 (19%)	
Age (days)	40.9 ± 22.3	39.1 ± 20.5	34.7 ± 18.7	39.1 ± 21	38.3 ± 19.6	
Weight (g)	3746 ± 724.8	3890 ± 687	3963 ± 727	4009 ± 732	3978 ± 836	$P = .02$
Palpable pyloric tumor	93 (79%)	93 (52%)	80 (43%)	50 (25%)	32 (23%)	$P < .001$
Length of illness (days)	12.3 ± 12	16 ± 19.7	7.2 ± 9.0	8.9 ± 10	7.68 ± 7.3	

TABLE 2. Admission Laboratory Data

	1969–1974 (n = 118)	1975–1979 (n = 179)	1980–1984 (n = 186)	1985–1989 (n = 197)	1990–1994 (n = 221)	
Sodium (mEq/L)	129.6 ± 32.9	138.5 ± 10.9	135.8 ± 17.8	134.9 ± 17.4	137 ± 9.8	$P < .001$
Potassium (mEq/L)	4.43 ± 1.49	4.76 ± .96	4.59 ± 1.0	4.66 ± 99	4.74 ± .87	$P = .048$
Chloride (mEq/L)	87.1 ± 25.2	96.4 ± 11.8	96.0 ± 15.8	95.6 ± 16.3	93.9 ± 21.8	$P < .001$
Bicarbonate (mEq/L)	30.2 ± 10.4	21.9 ± 6.3	27.1 ± 7.2	26.6 ± 5.4	26.1 ± 5.1	$P < .001$
Blood pH	7.50 ± .09	7.48 ± .07	7.52 ± .10	7.46 ± .10	7.49 ± .07	

An imaging study, either an UGI or abdominal U/S was performed in 90% of the entire study population. Eighty percent of these tests were ordered by the referring physician, not by the pediatric surgeon. UGI was used exclusively until 1983 when U/S was introduced to both hospitals as an alternative diagnostic test in patients with suspected IHPS. One imaging study was performed in 61% of patients in the earliest time period compared with 96% in the most recent time period (Fig 2). Diagnostic imaging was ordered by the referring physician increasingly over time, ranging from 74% in the earliest time period to 86% in the most recent time period.

Preoperative length of stay (PLOS) varied throughout the study (Fig 3). The PLOS was initially greater than 1 day; however, it declined to .68 days during the middle portion of the study period. An increase in the PLOS to greater than 1 day was found again in the most recent time frame. The total length of stay (TLOS) initially declined then remained stable.

DISCUSSION

The clinical hallmarks of IHPS include a male infant between 2 and 3 weeks of age with nonbilious, projectile vomiting.[3] In the past, a palpable pyloric tumor was detected in 70% to 90% of patients with IHPS.[1,2,7–10] Persistent vomiting of gastric contents can lead to the development of dehydration and hypochloremic alkalosis. The number of infants with IHPS and marked electrolyte abnormalities requiring treatment varies from 13% to 25% in several series.[11–13] The degree of electrolyte abnormalities has been associated with the length of illness.[12–15]

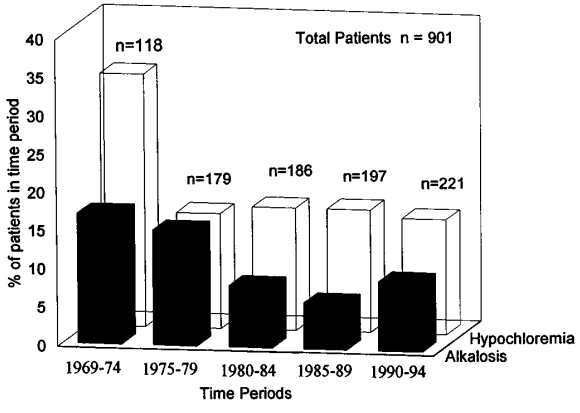

Fig 1. The proportion of infants in each time period with hypochloremia, Cl <90 mEq/L and alkalosis, pH >7.46.

This analysis demonstrates that the aforementioned classical features of IHPS have decreased in frequency over time. The length of illness before admission declined during this study. Weight loss, dehydration, and metabolic abnormalities became less common. Physical examination yielded positive findings in only 23% of infants in the last 5 years of inquiry compared with 79% in the first 5 years. Presumably, palpating a pyloric tumor in healthier, less emaciated, vigorous infants was more difficult, decreasing the sensitivity of the physical examination. Macdessi[5] also found a significant decline in palpable pyloric tumors over time, but an association with duration of illness was not established.

Imaging studies were routinely used to diagnose IHPS in the last 10 years of this study. Studies published before 1975 reported between 8% and 38% of infants with IHPS undergoing radiologic evaluation before surgical intervention.[1,2,7–10,16–18] However, diagnostic imaging was utilized increasingly in more recent series.[5,6]

The referring physician ordered the majority of diagnostic tests performed before referral. Others have demonstrated a similar pattern.[6,9,14] Presumably, a pyloric tumor was not palpated by the referring physician and this prompted further evaluation of the patient's vomiting. Increased usage of imaging modalities to diagnose IHPS has raised the concern that physical examinations by inexperienced physicians has lead to the performance of unnecessary tests.[4–6,19,20] During the earlier periods of this study, 72% of UGIs ordered by referring physicians subsequently had a pyloric tumor palpated by the pediatric surgeon. However, in the last 5 years of study, only 21% of imaging studies ordered

Downloaded from by guest on August 30, 2016

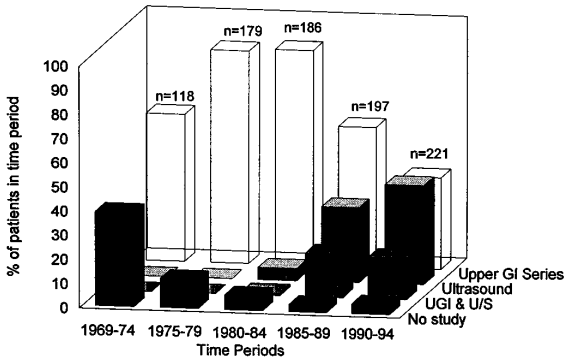

Fig 2. The proportion of infants who had diagnostic studies in each time period. The use of UGI declined as U/S was more commonly utilized. Both UGI and U/S in combination have become common. Less than 10% of infants had only physical examination as the sole diagnostic study.

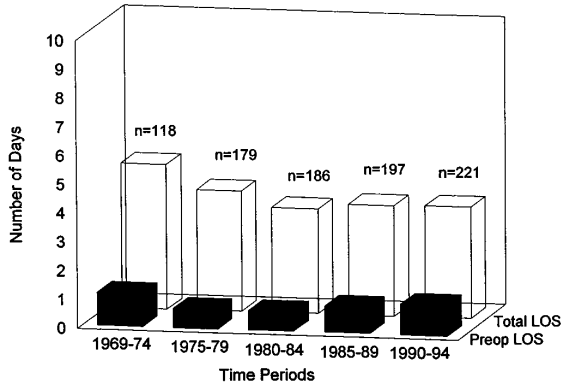

Fig 3. Length of stay for infants with IHPS has changed little since the 1975–1979 period. The preoperative length of stay increased as UGI and U/S were used more frequently.

by referring physicians were performed in infants with a palpable pyloric tumor. As palpable pyloric tumors became less frequent, an imaging study was necessary for diagnosis.

PLOS is an indicator of the patient's clinical status. It can also be a measure of the uncertainty of the diagnosis. In the earlier years, when patients presented more frequently with metabolic derangements, rehydration and electrolyte replacement were more often necessary before surgery. PLOS decreased during the middle period of the review. However, over the last 10 years, PLOS increased again correlating with the more routine use of imaging studies and the time required to perform one or more imaging studies for diagnosis. An increase in PLOS and diagnostic studies being performed have coincided with these changes in the presentation and diagnosis of infants with IHPS. Nevertheless, the TLOS decreased over the study period.

One question this study raises is why the change in presentation of IHPS over time? This study demonstrates that over time, infants were not as ill when they presented. The most probable reason for this is the earlier usage of imaging studies in an outpatient setting to ensure the diagnosis of IHPS. Infants were diagnosed with IHPS before they had significant metabolic abnormalities, weight loss, or the pathonomonic finding of a pyloric tumor.

Is the early use of an imaging study necessary? Is it more cost-effective to obtain an UGI or U/S in an infant who has been vomiting for a few days to rule out IHPS or risk the infant becoming dehydrated from persistent vomiting and require hospitalization for electrolyte abnormalities? If we use PLOS as an indicator of the patient's clinical status to determine the cost of hospitalization for dehydration, an estimated .52 days are needed to correct metabolic abnormalities. (This calculation reflects the difference between the PLOS during the earliest time period of this study [1.2 days] when more patients had metabolic derangements, and the middle portion of the study [.68 days] when fewer metabolic derangements were encountered). The current charge of an UGI or U/S at our hospitals is less than a half-day of hospitalization.

We recommend the following algorithm to diagnose IHPS: when an infant presents with vomiting, attempts to palpate a pyloric tumor should be made. If the primary physician is unable to palpate a pyloric tumor but has a high index of suspicion, a pediatric surgeon should examine the patient. If a pyloric tumor is palpated, the patient should undergo PM. If no tumor is palpated or a pediatric surgeon is not available, an imaging study should be performed.

REFERENCES

1. Pollock WF, Norris WJ, Gordon HE. The management of hypertrophic pyloric stenosis at the Los Angeles Children's Hospital. *Am J Surg.* 1957;94:335–349
2. Scharli A, Sieber WK, Kiesewetter WB. Hypertrophic pyloric stenosis at the Children's Hospital of Pittsburgh from 1912 to 1967. *J Pediatr Surg.* 1969;4:108–114
3. Shandling B. Congenital and perinatal anomalies of the gastrointestinal tract and intestinal obstruction. In: Behrman RE, ed. *Nelson Textbook of Pediatrics.* Philadelphia, PA: WB Saunders; 1992:948–950, chap 13
4. Forman HP, Leonidas JC, Kronfeld GD. A rational approach to the diagnosis of hypertrophic pyloric stenosis: do the results match the claims? *J Pediatr Surg.* 1990;25:262–266
5. Macdessi J, Oates RK. Clinical diagnosis of pyloric stenosis: a declining art? *Br Med J.* 1933;306:553–555
6. Breaux CW, Georgeson KE, Royal SA, et al. Changing patterns in the diagnosis of hypertrophic pyloric stenosis. *Pediatrics.* 1988;81:213–217
7. Grimes OF, Bell HG, Olney MB. Congenital hypertrophic pyloric stenosis. *J Pediatr.* 1950;37:522–529
8. Prosser R. Infantile hypertrophic pyloric stenosis. *Surgery.* 1965;58: 881–883
9. Benson CD, Lloyd JR. Infantile pyloric stenosis. *Am J Surg.* 1964;107: 429–433
10. Gibbs MK, Van Heerden JA, Lynn HB. Congenital hypertrophic pyloric stenosis. *Mayo Clin Proc.* 1975;50:312–316
11. Bell MJ. Infantile pyloric stenosis: experience with 305 cases at Louisville Children's Hospital. *Surgery.* 1968;64:983–989
12. Touloukian RJ, Higgins E. The spectrum of serum electrolytes in hypertrophic pyloric stenosis. *J Pediatr Surg.* 1983;18:394–397
13. Beasley SW, Hudson I, Yuen HP, et al. Influence of age, sex, duration of symptoms and dehydration of serum electrolytes in hypertrophic pyloric stenosis. *Aust Paediatr J.* 1986;22:193–197
14. Mackay AJ, Mackellar A. Infantile hypertrophic pyloric stenosis: a review of 222 cases. *Aust N Z J Surg.* 1986;56:131–133
15. Breaux CW, Hood JS, Georgeson KE. The significance of alkalosis and hypochloremia in hypertrophic pyloric stenosis. *J Pediatr Surg.* 1989;24: 1250–1252
16. Larsen GL. Limitations of roentgenographic examination in the diagnosis of infantile hypertrophic pyloric stenosis. *Surgery.* 1966;60:768–772
17. Shuman FI, Darling DB, Fisher JH. The radiographic diagnosis of congenital pyloric stenosis. *J Pediatr.* 1967;71:70–74
18. Feldtman RW, Andrassy RJ, Larsen GL, et al. Pyloric stenosis: a 13-year experience in operative management. *Am Surg.* 1976;42:551–553
19. Hoekelman RA. Pyloric stenosis is a pediatrician's diagnosis. *Pediatr Ann.* 1994;23:181–182
20. Golladay ES, Broadwater JR, Molitt DL. Pyloric stenosis: a timed perspective. *Arch Surg.* 1987;122:825–826

Downloaded from by guest on August 30, 2016

Evolution in the Recognition of Infantile Hypertrophic Pyloric Stenosis
Frieda Hulka, Timothy J. Campbell, John R. Campbell and Marvin W. Harrison
Pediatrics 1997;100;e9
DOI: 10.1542/peds.100.2.e9

Updated Information & Services	including high resolution figures, can be found at: /content/100/2/e9.full.html
References	This article cites 19 articles, 1 of which can be accessed free at: /content/100/2/e9.full.html#ref-list-1
Subspecialty Collections	This article, along with others on similar topics, appears in the following collection(s): **Surgery** /cgi/collection/surgery_sub
Permissions & Licensing	Information about reproducing this article in parts (figures, tables) or in its entirety can be found online at: /site/misc/Permissions.xhtml
Reprints	Information about ordering reprints can be found online: /site/misc/reprints.xhtml

PEDIATRICS is the official journal of the American Academy of Pediatrics. A monthly publication, it has been published continuously since 1948. PEDIATRICS is owned, published, and trademarked by the American Academy of Pediatrics, 141 Northwest Point Boulevard, Elk Grove Village, Illinois, 60007. Copyright © 1997 by the American Academy of Pediatrics. All rights reserved. Print ISSN: 0031-4005. Online ISSN: 1098-4275.

American Academy of Pediatrics
DEDICATED TO THE HEALTH OF ALL CHILDREN™

Downloaded from by guest on August 30, 2016

PEDIATRICS®
OFFICIAL JOURNAL OF THE AMERICAN ACADEMY OF PEDIATRICS

Evolution in the Recognition of Infantile Hypertrophic Pyloric Stenosis

Frieda Hulka, Timothy J. Campbell, John R. Campbell and Marvin W. Harrison

Pediatrics 1997;100;e9
DOI: 10.1542/peds.100.2.e9

The online version of this article, along with updated information and services, is located on the World Wide Web at:
/content/100/2/e9.full.html

PEDIATRICS is the official journal of the American Academy of Pediatrics. A monthly publication, it has been published continuously since 1948. PEDIATRICS is owned, published, and trademarked by the American Academy of Pediatrics, 141 Northwest Point Boulevard, Elk Grove Village, Illinois, 60007. Copyright © 1997 by the American Academy of Pediatrics. All rights reserved. Print ISSN: 0031-4005. Online ISSN: 1098-4275.

American Academy of Pediatrics
DEDICATED TO THE HEALTH OF ALL CHILDREN™

Downloaded from by guest on August 30, 2016